



**The anatomy of the pudendal nerve
and its branches and the clinical
implications thereof**

by

Sonè van der Walt

Thesis submitted in fulfilment of the requirements for the
degree of

MASTER OF SCIENCES

in the

FACULTY OF HEALTH SCIENCES

Department of Anatomy

University of Pretoria

2013

Declaration

I declare that the dissertation that I am hereby submitting to the University of Pretoria for the MSc degree in Anatomy is my own work and that I have never before submitted it to any other tertiary institution for any degree.

Sonè van der Walt

_____ day of _____ 2013

Table of Contents

Summary.....	v
Abstract	vii
Acknowledgements.....	viii
List of figures.....	ix
List of tables.....	xii
Chapter 1: Introduction and literature review	1
1.1 Anatomy of the pudendal nerve (PN)	2
1.2 Branches of the pudendal nerve.....	2
1.2.1 Inferior rectal nerve (IRN)	2
1.2.2 Perineal nerve.....	2
1.2.3 Dorsal nerve of the penis or clitoris (DNP/C)	3
1.3 Perineal procedures	3
1.3.1 Transvaginal sacrospinous colpopexy/Richter’s procedure.....	3
1.3.2 Tension-free vaginal tape (TVT) procedure in females.....	7
1.3.3 Transobturator Tape (TOT) procedure in females.....	10
1.3.4 Transobturator tape (TOT) procedure in males	13
1.3.5 Mini slings: MiniArc sling.....	14
1.3.6 Perineal procedures for faecal incontinence	16
1.3.7 Pudendal nerve blocks	17
1.3.8 Anorectal (Ischioanal) abscess and anal fistula drainage	18
1.3.9 Dorsal penile nerve block	19

1.3.10 Radical perineal prostatectomy.....	20
1.4 Aim:	23
Chapter 2: Materials and methods	25
2.1 Pudendal nerve dissection and measurements	25
2.2 Predicting safe areas	35
2.3 Perineal procedures performed	36
2.3.1: Female perineal procedures performed	37
2.3.2: Male perineal procedures performed	43
2.4 Ethical considerations	46
Chapter 3: Results	48
3.1 Pudendal nerve dissection and measurements	48
3.1.1 Description of the course and branches of the pudendal nerve.....	48
3.1.2 Distances from the pudendal nerve and its branches to important landmarks	54
3.2 Predicting safe areas	59
3.2.1 Analysis of intergroup variations	59
3.2.2 Predicting safe areas for perineal procedures	65
3.2.2.1 Richter’s procedure	65
3.2.2.2 Tension-free vaginal tape (TVT)	66
3.2.2.3 Transobturator Tape: outside-in (TOT) and inside-out (TVT-O) in females	66
3.2.2.4 Transobturator Tape (outside-in and inside-out) in males	67
3.2.2.5 Pudendal nerve block.....	68
3.2.2.6 Anorectal (Ischioanal) abscess and anal fistula drainage	68
3.2.2.7 Dorsal penile nerve block	69
3.3 Perineal procedures performed	70

3.3.1 Female tape procedures	72
3.3.2 Richter’s procedure	76
3.3.3 Male tape procedures	78
Chapter 4: Discussion	83
4.1 Pudendal nerve dissection and measurements	83
4.2 Predicting safe areas	87
4.2.1 Richter’s procedure	87
4.2.2 Tension-free vaginal tape procedure (TVT).....	88
4.2.3 Transobturator Tape: outside-in (TOT) and inside-out (TVT-O) in females	89
4.2.4 Transobturator Tape (outside-in and inside-out) in males	91
4.2.5 Pudendal nerve block:.....	91
4.2.6 Ischioanal abscess and anal fistula drainage	92
4.2.7 Dorsal penile nerve block	93
4.3 Perineal procedures performed	93
4.3.1 Richter’s procedure	94
4.3.2 Tension-free vaginal tape procedure (TVT):.....	95
4.3.3 Transobturator Tape: outside-in (TOT) and inside-out (TVT-O) in females	95
4.3.4 Transobturator Tape: inside-out (TOT) in males	96
Chapter 5: Conclusion	99
Chapter 6: References	102

Summary

Knowledge of the anatomy of the pudendal nerve, specifically its course, branches and variations, is of great importance when performing perineal surgery. The pudendal nerve (PN) and inferior rectal nerve (IRN), both related to the sacrospinous ligament, could be injured during the Richter's procedure. The course of the IRN branches, on the other hand, is applicable in ischioanal procedures, whilst the dorsal nerve of the clitoris/penis (DNC/P) is implicated in other perineal procedures. The aim of this study was to re-evaluate the PN, its branches and relationships as it is implicated in various perineal procedures in South African groups.

The course and branches of the PN were dissected in 15 black and 27 white males, and 16 black and 13 white female cadavers. Landmarks were identified and distances were measured. Findings were evaluated to predict safe areas for the procedures considered. Perineal procedures were performed on 15 male and 15 female cadavers. After embalment, the cadavers were dissected and measurements taken.

In black individuals, the IRN mostly entered the gluteal region separately, the PN and IRN were more often medial to the ischial spine, and the sacrospinous ligament was shorter than in white individuals. The IRN was more superficial in white females but deeper in white males. The dorsal nerve of the clitoris or penis (DNC/DNP) was closer to the inferior pubic ramus, and the DNP was deeper in white individuals.

The following predictions were made: The Richter's procedure could involve the PN/IRN in black females and during a PN block the anaesthetic should be injected more medial and proximal to the ischial spine. During the transobturator outside-in procedure, in obese patients, the needle might exit closer to the inferior pubic ramus and the DNC/P. The perineal nerve might be vulnerable near the bulb of the penis. The IRN might be damaged during ischioanal procedures, especially in white females and leaner individuals. Fat pads might hinder the effectiveness of the anaesthetic during a dorsal penile nerve block.

Perineal procedures were performed to evaluate the predictions made. The PN and IRN were more vulnerable in black females during the Richter's procedure. The tension-free vaginal tape procedure was safe. During the outside-in procedure the needle exited closer to the inferior pubic ramus, putting the DNC/P in white or obese individuals more at risk. Black or leaner individuals were at risk during the inside-out procedure, as the DNC was more exposed.

In black females a PN block should be administered more proximally and medially and the Richter's stitch should be placed at least 20 mm from the ischial spine. Inside-out procedures are preferable in white or obese individuals and outside-in procedures in black or leaner individuals. Dissections within 10 mm from the lateral border of the bulb of the penis should be avoided. During ischioanal procedures, care should be taken in white females not to damage the IRN. The dorsal penile nerve block should be administered deeper in white and obese individuals. The above-mentioned implications should be verified in a clinical setting.

Abstract

Knowledge of the course of the pudendal nerve (PN) is important when performing perineal surgery. Distances between landmarks were measured after PN dissections in 71 cadavers and after perineal procedures on 30 cadavers. Separate inferior rectal nerve (IRN) entry and medial position of the PN/IRN with shortened sacrospinous ligaments were often seen in black individuals. A PN block should therefore be placed more proximally and medially. The Richter's stitch should be placed further from the ischial spine. During ischioanal procedures the IRN is at risk in white females, as it was more superficial. The dorsal nerve of the clitoris/penis (DNC/DNP) is in danger during the outside-in procedures in white or obese individuals, as it was closer to the inferior pubic ramus. The dorsal penile nerve block should be administered deeper in white and obese individuals, as the DNP was deeper. The above-mentioned findings should be verified in a clinical setting.

Keywords: Pudendal nerve, perineal surgery, inferior rectal nerve, dorsal nerve of the clitoris/penis, transobturator tape procedures, pudendal nerve block, Richter's stitch, dorsal penile nerve block, ischioanal procedures, inferior pubic ramus

Acknowledgements

This project would not have been possible without the support and guidance of the various people at the Departments of Anatomy, University of Pretoria and University of Limpopo (Medunsa campus).

I am grateful to all the individuals who helped, encouraged and supported me throughout the past two years. Firstly, I would like to thank my supervisor, Dr AC Oettlè for her guidance, motivation, endurance and assistance throughout the duration of this project. Her uncompromising enthusiasm and positivity made it a great pleasure to work with her, and made all facets of this research a delight.

I would like to thank Dr F van Wijk and Dr Z Abdool for their time and skills used, to perform the incontinence sling procedures and Richter's procedures on the fresh unembalmed cadavers. Additionally, I would like to thank Prof. PJ Becker who played a valuable role in the statistical analysis of the data.

To my family, thank you for your support, optimism and understanding.

List of figures

Figure 1: Right lateral view of a midsagittal section demonstrating the first incision in the anterior vaginal wall.....	4
Figure 2: The distal end of the Capiro suturing device.....	5
Figure 3: Palpation of the middle- to outer third of the sacrospinous ligament	6
Figure 4: The tension-free vaginal tape (TVT) kit	8
Figure 5: Right lateral view of a midsagittal section of the pelvis demonstrating the position of the tension-free vaginal tape	9
Figure 6: Trajectory of the transobturator needle in transobturator sling placement	11
Figure 7: The gluteal approach	26
Figure 8: Perineal approach in females.....	27
Figure 9: Measurements (a) and (b) indicated on a female pelvis	29
Figure 10: Measurement (f).....	29
Figure 11: Measurements (g) and (j) indicated on the female pelvis.....	30
Figure 12: Measurements (h) and (i) indicated on a female pelvis	31
Figure 13: Measurements (g) to (j) indicated on the anterior view of a female pelvis	32
Figure 14: Measurements (g) and (j) indicated on a male pelvis	33
Figure 15: Measurements (h) and (i) indicated on a male pelvis	34
Figure 16: Measurements (g) to (j) indicated on an anterior view of a male pelvis	35

Figure 17: Right midsagittal section demonstrating the first incision in the anterior vaginal wall from the level of the bladder neck to the vaginal apex.....38

Figure 18: Right midsagittal section of the pelvis demonstrating the position of the tension-free vaginal tape.....39

Figure 19: The inside-out female transobturator sling40

Figure 20: Position of the exit points of the TVT-O40

Figure 21: Plane created for blunt dissection towards inferior pubic ramus42

Figure 22: The four arms of the Virtue male TOT sling44

Figure 23: Position of the entry point of the male TOT introducer45

Figure 24: Gluteal dissection with IRN and PN exiting the pelvis separately.....48

Figure 25: The course and branching patterns of the PN and IRN in the gluteal region as set out in Table 450

Figure 26: Gluteal dissection indicating the superficial and deep perineal nerves.....52

Figure 27: DNP and its accompanying vessels as seen from lateral53

Figure 28: DNC as seen from lateral53

Figure 29: Measurements (a) to (c) indicated on a female pelvis54

Figure 30: Measurement (f) indicated in a male cadaver55

Figure 31: Measurements between landmarks and the DNC on a perineal view of the female pelvis.....56

Figure 32: Measurements between landmarks and DNP on a perineal view of the male pelvis .58

Figure 33: Distance between the DNC and the TOT tape (white) in females73

Figure 34: Distances from the DNC to the TOT tape	73
Figure 35: Distance between the DNC and the TVT tape (blue)	74
Figure 36: Distances from the DNC to the TVT tape in white females	74
Figure 37: Distance between the DNC and the TVT-O tape (blue).....	75
Figure 38: Distances from the DNC to the TVT-O in white females	75
Figure 39: The position of the Richter’s stitch.....	76
Figure 40: Distances from the PN to the Richter’s stitch	77
Figure 41: Distances from the IRN to the Richter’s stitch	77
Figure 42: Distance between the perineal branches and the body of the TOT tape (white)	80
Figure 43: Distance between the DNP and the prepubic arms of the TOT tape (white mesh)	81
Figure 44: Prepubic arm exiting through the spermatic cord	81
Figure 45: Anterior perineal view indicating the distance between the DNP and the obturator arm of the TOT tape (white mesh).....	82

List of tables

Table 1: Distances from landmarks to implicated nerves and their clinical applications.....	28
Table 2: Distances measured from identified landmarks and the PN and its branches in females, and their clinical applications	43
Table 3: Distances measured between the TOT mesh and the PN and its branches in males	46
Table 4: The proportion of individuals with defined course and branching patterns of the PN and IRN in the gluteal region by ancestry and sex	49
Table 5: Minimum and maximum distances in mm between the PN or IRN and bony landmarks or between landmarks in the gluteal region	55
Table 6: Minimum and maximum distances in mm between the DNC and bony landmarks	57
Table 7: Minimum and maximum distances in mm between the DNP and identified landmarks	59
Table 8: Basic descriptive statistics for distances measured in mm from the PN and its branches to identified landmarks	60
Table 9: Proportion of the PN or its branches adjacent to the bony landmarks versus a distance separated from the bony landmarks	62
Table 10: Comparison between the different population groups of the proximity of the PN and its branches to identified landmarks or between landmarks	64
Table 11: Comparison between the sexes of the proximity of the PN and its branches to identified landmarks or between landmarks	65
Table 12: Cadaver BMI and distances (in mm) between the PN or its branches to the tape/suture amongst various procedures in females.....	71

Table 13: Cadaver BMI classification and mean distances (in mm) for procedures in females ...	72
Table 14: Cadaver BMI and the distances (in mm) between the branches of the PN to the four arms of the TOT tape in males.....	79
Table 15: Cadaver BMI classification and mean distances (in mm) for procedures in males.....	80
Table 16: Variations of the PN and IRN in the researched literature compared to the current study.....	84

Chapter 1: Introduction and literature review

Knowledge of the anatomy of the pudendal nerve, and more specifically its course, branches and variations, is of great importance when performing perineal surgery such as sacrospinous colpopexy, better known as the Richter's procedure. The Richter's procedure is indicated for the treatment of vaginal and uterine prolapse,¹⁻³ and the tension-free vaginal tape (TVT) for the treatment of female stress urinary incontinence.⁴ The placement of transobturator tapes for the treatment of urinary incontinence is a newer procedure and can be performed on females as well as males.⁵⁻⁷ Other procedures which might involve the pudendal nerve, include male perineal procedures such as the dorsal penile nerve block and nerve-sparing radical perineal prostatectomy.⁸⁻¹¹

Many conflicting terminologies and descriptions of the course of the pudendal nerve exist even in recent publications and amongst populations. A thorough re-evaluation of the pudendal nerve, its branches and relationships, as it is implicated in various perineal procedures, was deemed necessary. The landmarks used during the performance of procedures, the position of the incisions made and the trajectory of the needles/ instruments were considered.

Various perineal procedures in which the PN and its branches are implicated were performed by a registered gynecologist and urologist to evaluate the predictions made.

Other aspects that need to be considered include the variation amongst populations, sexes and body variations, regarding the relative position of the pudendal nerve to identified landmarks and to the trajectories of the needles in perineal procedures performed. As the pelvic skeletal frame has known variations amongst individuals, between sexes, populations and with body variations, the relative position of the pudendal nerve may also vary.¹²⁻¹⁶

It is therefore beneficial to compare findings amongst these groups in order to develop adaptations to the considered perineal procedures. As the trocar needle used during sling procedures has a standardized curve, variations in the body mass index (BMI) might be clinically

important. It is thus necessary to determine the safety margins for each weight category, and to propose a certain procedure for each group.

In this chapter the known anatomy of the pudendal nerve, as well as perineal procedures considered, are discussed.

1.1 Anatomy of the pudendal nerve (PN)

The PN supplies motor and sensory innervation to the perineum.^{1,17} It originates from the ventral primary rami of spinal cord segments S2, S3 and S4 of the sacral plexus and exits the pelvis through the greater sciatic foramen to descend posterior to the sacrospinous ligament.¹⁷⁻²⁰ It then passes anterior to the lateral third of the sacrotuberous ligament and medial or posterior to the ischial spine before it enters the perineum through the lesser sciatic foramen via the pudendal canal (Alcock's canal).²¹ The pudendal canal is a fascial sheath formed medially by the obturator internus muscle and laterally by the obturator internus fascia.

1.2 Branches of the pudendal nerve

1.2.1 Inferior rectal nerve (IRN)

As the PN enters the pudendal canal, it gives rise to the IRN, which runs through the medial wall of the canal.^{22,23} The IRN crosses the ischioanal fossa where it occupies approximately the inferior half of the fossa.²⁴ It may also arise from the pudendal trunk before it enters the pudendal canal.²⁰ The IRN supplies the external anal sphincter and the peri-anal skin²¹ and also plays an important role in faecal continence.¹

1.2.2 Perineal nerve

Towards the distal end of the pudendal canal the pudendal nerve bifurcates, giving rise to two terminal branches, the perineal nerve and the dorsal nerve of the penis or clitoris.^{22,24} The perineal nerve is the larger and inferior terminal branch and runs forward below the internal pudendal artery. It is mostly found in the superficial perineal pouch. This pouch is a potential space between the subcutaneous tissue and the perineal membrane. In males it contains the bulb of the penis (the posterior expanded portion of the corpus spongiosum surrounded by the ischiocavernosus muscle) and proximal part of the spongy urethra. In females the superficial

perineal pouch contains the clitoris and bulbs of the vestibule. In both sexes, the superficial transverse perineal muscles can be found in this perineal pouch.^{22,23}

The perineal nerve divides into posterior scrotal or labial branches and muscular branches. The posterior scrotal or labial branches supply the skin of the scrotal area or labia majora, overlapping with the distribution of the perineal branch of the posterior femoral cutaneous nerve and IRN.²² The muscular branches supply the bulbospongiosus, ischiocavernosus, superficial and deep transverse perineal muscles, levator ani muscle, as well as the urethral sphincter and anterior parts of the external anal sphincter.^{17,20,23}

1.2.3 Dorsal nerve of the penis or clitoris (DNP/C)

This nerve runs anteriorly above the internal pudendal artery, along the inferior pubic ramus in the deep perineal pouch. This pouch is bounded inferiorly by the perineal membrane, and superiorly by the inferior fascia of the pelvic diaphragm. It contains the deep transverse perineal muscles in both sexes, as well as the urogenital diaphragm. In males, it contains the bulbourethral glands and dorsal neurovascular structures of the penis. In females, it contains the dorsal neurovasculature of the clitoris. The nerve lies posterior to the perineal membrane and exits the pouch through a gap between the inferior pubic ligament and the anterior end of the perineal membrane. The nerve courses through the suspensory ligament of the penis or clitoris.²⁴ The DNP/C is the primary sensory nerve that serves the male or female organs, especially the sensitive glans at the distal end.²²

1.3 Perineal procedures

1.3.1 Transvaginal sacrospinous colpopexy/Richter's procedure

The transvaginal sacrospinous colpopexy or Richter's procedure is indicated for vaginal vault prolapse, a complication which occurs in 0.2 – 43% of patients that undergo a hysterectomy.²³ The cumulative risk rises from 1%, three years after a hysterectomy to 5%, 15 years after a hysterectomy. The risk also increases with the number of vaginal child births and advancing age.²⁵ Richter first described the transvaginal sacrospinous colpopexy in 1968 for the management of vaginal vault prolapse.^{26,27} During colpopexy procedures, the pudendal

neurovascular structures, sciatic nerve and the inferior gluteal vessels are at risk when performing suspension of the anterior or posterior vaginal wall to the sacrospinous ligament.^{23,25,28,29}

Transvaginal sacrospinous colpopexy is performed via an anterior or posterior approach.

Anterior approach:

The patient is placed in a standard high lithotomy position. A single vertical incision is made in the anterior vaginal wall. The incision is made in the upper 1/3 of the vagina, extending from the level of the bladder neck to the apex of the vagina (Fig. 1). The pubocervical fascia is dissected away from the vaginal skin. Sharp dissection is continued until the descending pubic ramus can be palpated laterally. From this point onwards, blunt dissection is performed until the ischial spine can be palpated. By palpation of the ischial spine, the position of the sacrospinous ligament can be determined.³

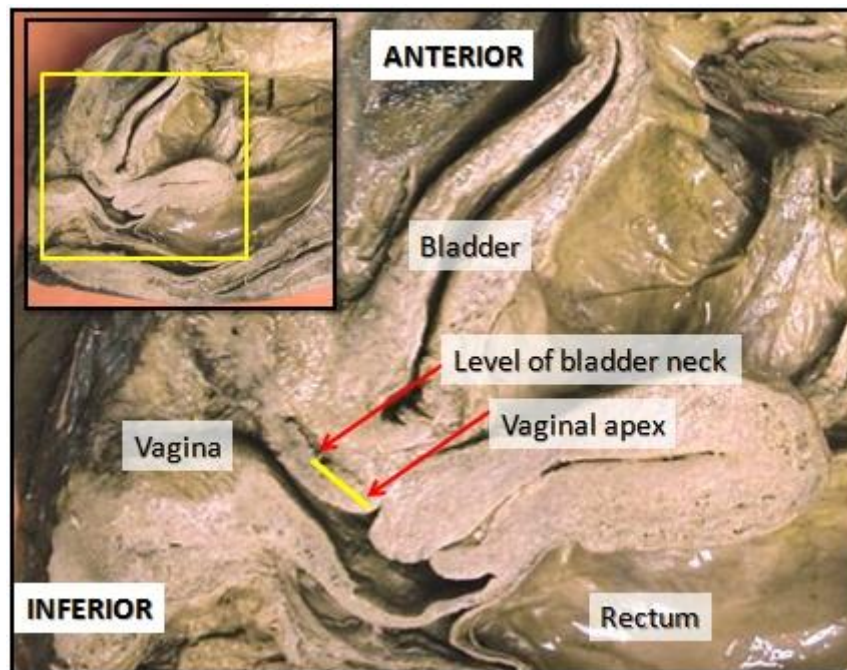


Figure 1: Right lateral view of a midsagittal section demonstrating the first incision in the anterior vaginal wall

The sacrospinous ligament is traced to its origin on the sacrum. By using the index finger, the paravesical tissues and bladder is retracted medially and with the free hand, a Capio device is advanced between the middle and outer thirds of the ligament. When the head of the Capio device is secured against the ligament, the suture can be deployed.³

The Capio suturing device (Fig. 2) is a one-step suturing device that allows for the placement of sutures by palpation without the use of trocars and with less dissection.³

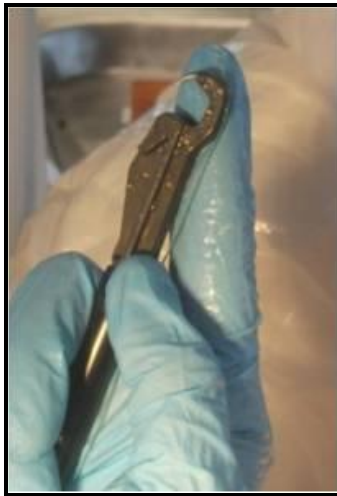

Figure 2: The distal end of the Capio suturing device

The Capio device has also transformed the procedure into a quick, easy and efficient repair of vaginal prolapse.³

Posterior approach:

The patient is placed in a standard high lithotomy position. An incision is made in the perineal skin and posterior vaginal mucosa to open the rectovaginal space. The right rectal pillar, overlying the right pararectal space, can now be exposed and be penetrated. The right ischial spine is palpated through the dissected plane. For proper suture placement, a window has to be opened by blunt penetration of the surgeon's finger, through the descending rectal septum over the ischial spine. The sacrospinous ligament can be palpated by using lateral sweeping movements.

As the PN and IRN are closely related to the ischial spine and sacrospinous ligament, these nerves may be vulnerable during this procedure, giving rise to complications of perineal pain and paraesthesia. A suture is therefore placed 2 cm medial to the ischial spine to avoid the pudendal neurovascular bundle when penetrating the sacrospinous ligament^{2,30} (Fig. 3). This recommendation was also expressed by Verdeja *et al.* who recommend the placement of the sutures medial and superficial to the sacrospinous ligament to minimise the risk of complications associated with the Richter's procedure.²⁹

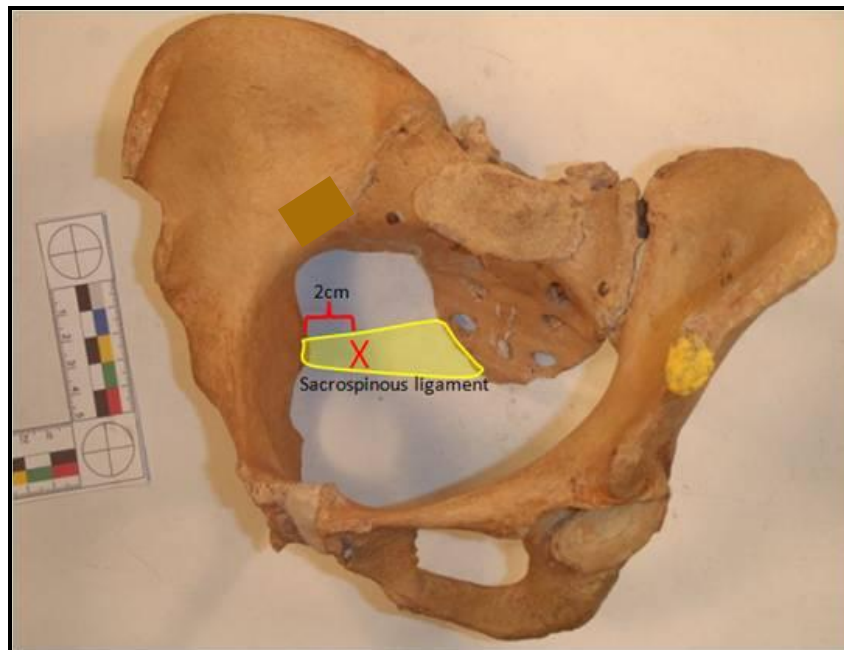


Figure 3: Palpation of the middle- to outer third of the sacrospinous ligament

1.3.1.1 Possible complications of the Richter's procedure

Buttock pain is a common post-operative symptom after sacrospinous colpopexy. This may result from the dissection in the pararectal space, but resolves spontaneously.³¹ Flexion injury of nerves due to inappropriate positioning of patients during surgery can also cause postoperative pain. Another recognized complication when the fixation is too deep or too close to the ischial spine, is nerve entrapment syndromes. This results in loss of motor and/or sensory function, as well as chronic pain syndromes.^{32,33}

Alevizon *et al.* reported a case of a 62 year old female who complained of postoperative right buttock and perineal pain. The diagnosis of PN entrapment was made two years after the procedure, and the inserted suture was removed. The removal of the stitch resulted in immediate relief.³¹

Branches of the PN that supply the coccygeus and levator ani muscles are also in danger during the placement of the stitch. In a study performed by Roshanravan *et al.*, 21 female cadavers were dissected to expose these branches supplying the coccygeus and levator ani muscles respectively. It was found that in 89% of the dissections, these branches coursed over the middle of the coccygeus muscle-sacrospinous ligament complex, in the same area where the sutures are placed.³⁴ As these branches cannot be visualized through the dissected plane, their position should be taken into account before the placement of the stitch.

In addition to the significance of the course and relationship of the PN and its branches to the ischial spine, the available space between the sacrum and the ischial spine for performing the Richter's procedure should be verified amongst patients with various BMI's and different population groups.

1.3.2 Tension-free vaginal tape (TVT) procedure in females

The tension-free vaginal tape is one of the first mesh tape suburethral sling procedures introduced to treat stress urinary incontinence in females. Urinary incontinence affects 15 - 50% of woman of all ages. It is one of the most prevalent chronic conditions.^{35,36} Population based studies in the United States of America (USA) indicated that as many as 75% of women reported at least some urinary leakage and 20 - 50% reported frequent leakage. Approximately one in ten women in the USA undergo surgery for urinary incontinence.³⁵

A high BMI was found to be more frequently associated with the occurrence of urinary incontinence.³⁷⁻³⁹ Danforth *et al.* found that middle aged women with a low to normal BMI (lower than 22kg/m²) were significantly less likely to develop incontinence when compared to woman with a higher BMI. They also reported a lower incidence of urinary continence in black African-American and Asian-American females compared to white American and Hispanic

females.³⁸ Mommsen and Foldspang described increased frequency in the development of stress urinary incontinence starting at a BMI of 25-30 kg/m². The result of this increase may be caused by a higher perineal and abdominal wall tone which will cause an increase in the intrapelvic pressure in obese woman, especially nulliparous women. It was also found that stress urinary incontinence was the type of incontinence most closely related to increased BMI.³⁷

Ulmsten *et al.* described the tension-free vaginal tape (TVT) in 1996 as a minimally invasive procedure to treat stress urinary incontinence in females.^{40,41} The TVT kit (Fig. 4) consists of two curved stainless steel needles attached to a 1 cm wide polypropylene mesh tape, sheathed in plastic.




Figure 4: The tension-free vaginal tape (TVT) kit

The device has a detachable handle to facilitate passage of the needles through the retropubic space.^{42,43} The procedure is performed with the patient in the lithotomy position. Three small incisions are made: two suprapubic and one 1.5 cm proximal to the mid-urethra in the anterior vaginal wall. By using the two trocar needles, the polypropylene sling is introduced under the mid-urethra. The trocars are passed from the vaginal entry point through the retropubic space to exit through the two suprapubic incisions. The plastic sheath, which facilitates the initial placement of the sling is removed, and the excess mesh is excised suprapubically^{41,42} (Fig. 5).

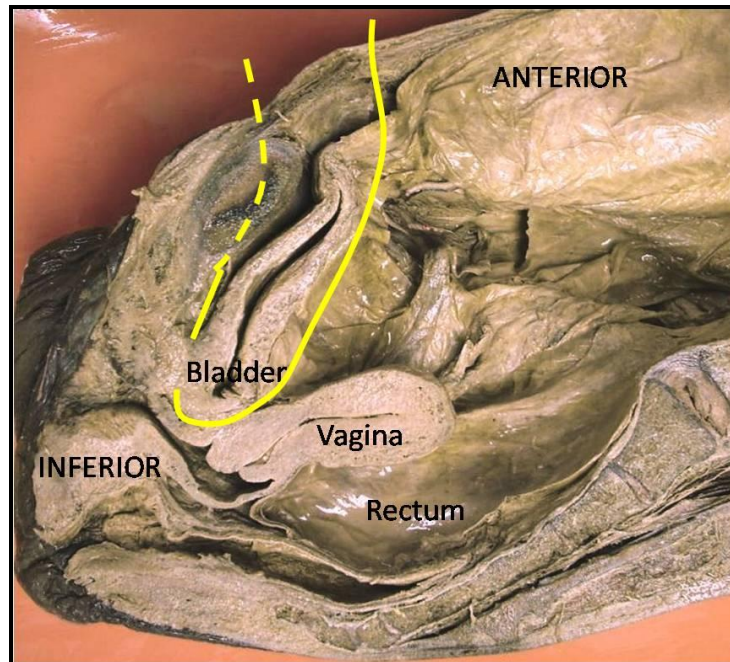


Figure 5: Right lateral view of a midsagittal section of the pelvis demonstrating the position of the tension-free vaginal tape

Known complications of the TVT procedure include the perforation of the bladder and bowel, damage to the urethra, retropubic haematoma, damage to the internal iliac vessels and post-operative voiding difficulty.^{5-7,41,42,44-46}

Achtari *et al.* studied the course of the dorsal nerve of the clitoris (DNC) and the distance between it and the mesh of the TVT. The DNC crossed under the pubic bone at a distance of about $14 \text{ mm} \pm 5 \text{ mm}$ from the midline. At that location the DNC could be damaged during the insertion of the TVT under the pubic bone as well as during the dissection from medial to lateral for the insertion of the inside-out transobturator tape (TVT-O)⁴³, which will be discussed later.

Pudendal nerve damage could lead to local pelvic and perineal pain. In a case study, 17 patients with previous TVT procedures underwent a transperitoneal laparoscopic procedure to remove the tape due to chronic perineal or pelvic pain. Forty one percent (7/17) of patients with previous TVT procedures presented with pudendal neuropathic pain. In the majority of cases, the TVT tape was found piercing the levator ani muscle. After tape removal, the pain

subsided.⁴⁷ In cases where the trocar needles were pushed in too deep, the tape pierced the levator ani muscle, putting the underlying muscular branches of the perineal nerve at risk. Damage to these nerves result in pain in the perineum and vagina.^{48,49}

Fisher and Lotze described a case of a 52 year old female who previously underwent a TVT procedure, complaining of severe left peri-urethral pain extending to the left labia majora. A PN block was performed and the pain disappeared. Left PN entrapment was diagnosed and the tape was removed. After removal, the pain subsided.⁵⁰ Perineal nerve branches which innervate the striated muscles of the urethral sphincter are at risk of direct entrapment or injury with perforation of the peri-urethral tissue when the trocar passes under the mid-urethra.⁵¹

It is therefore useful to determine the course and relationships of the perineal nerve and the DNC as implicated in TVT procedures.

1.3.3 Transobturator Tape (TOT) procedure in females

Before 2001, the surgical treatment of choice for female stress urinary incontinence was the tension-free vaginal tape (TVT) procedure. Although these tapes have proved to be efficient, their insertion via the retropubic space has been associated with a number of perioperative and postoperative complications.^{5-7,45,46}

The transobturator mid-urethral sling procedure was developed in 2001 by Delorme, to minimize the complications of the TVT procedure, by not traversing the retropubic space. In this procedure, the tape is introduced from the genitofemoral fold, through the obturator foramen and exits at the level of the mid-urethra from the outside to the inside (TOT), sparing the retropubic space.⁵² In 2003, the procedure was modified by de Leval, who used an inside-out approach in females (TVT-O) in which the needle tip is pushed through an incision in the vaginal mucosa from the level of the mid-urethra, through the obturator foramen, exiting in the genitofemoral fold⁸ (Fig. 6).

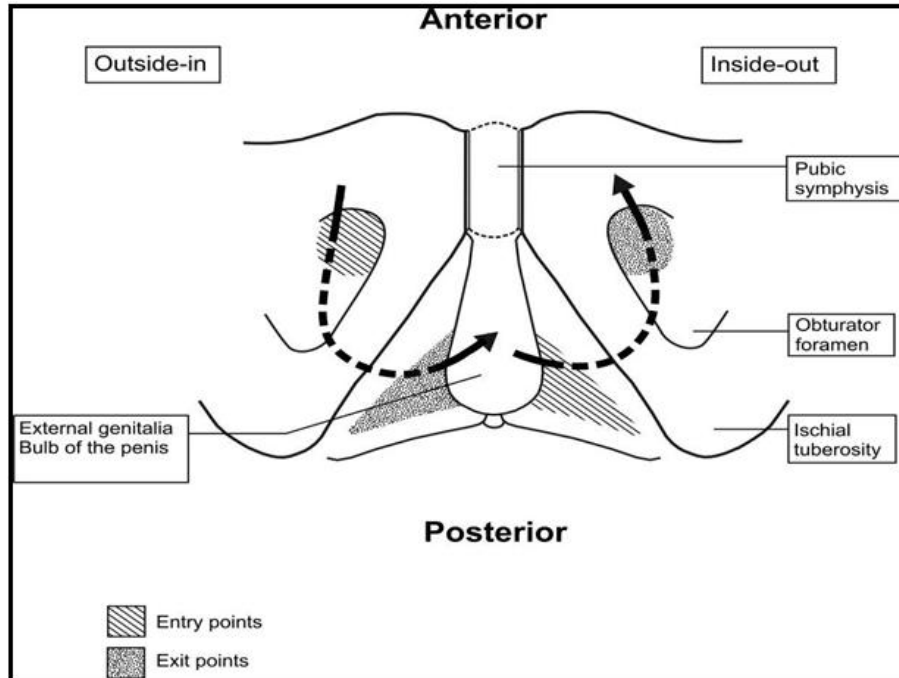


Figure 6: Trajectory of the transobturator needle in transobturator sling placement

According to the recommended application of the TVT-O procedure (inside-out) as described by de Leval, and Whiteside and Walters, the procedure is performed in females as follows: Exit points are marked laterally by tracing a horizontal line at the level of the urethral meatus. A second line is traced 2 cm above and parallel to the first. The exit points are marked on the second line, 2 cm lateral to the genitofemoral folds. A 1 cm midline incision is made in the vaginal mucosa, starting 1 cm proximal to the urethral meatus. Blunt dissection is now performed towards the palpable junction between the body of the pubic bone and the inferior pubic ramus. A wing guide is placed into the dissected tract and the curved trocar is placed into the tract around the inferior pubic ramus and through the obturator foramen. The trocars should exit at the exit points previously marked. The tape should be placed loosely and flat under the mid-urethra. At this stage a cough test can be performed to allow adjustment of the tape so that only a few drops of urine are lost during the cough reflex.^{46,53-55}

Ridgeway *et al.* explained the outside-in TOT procedure in females as follows: A synthetic mesh tape is placed through the obturator foramen by a trocar which courses from the genitofemoral fold to the vagina at the level of the mid-urethra.¹² A metal introducer is used to allow minimal

para-urethral dissection by guiding the trocar in the transobturator passage inferolateral to the bladder.^{12,52}

In a comparative study done by Lee *et al.*, no significant difference was found in the success rates between the TOT and TVT-O procedures. The success rates varied between 91.1 - 92% for the TOT procedure and 86 - 94% for the TVT- O procedure.^{6,56,57} Dyrkorn *et al.* on the other hand, found that when comparing the outcome values for the 24-h pad test, the women in the TVT-O group had significantly more leakage than those in the TOT group.⁵⁸

Cho *et al.* listed the postoperative complications found in the two surgical procedures respectively. Postoperative complications found in both groups included urinary retention, urinary tract infection and de novo urgency. Vulvar haematoma and vaginal erosion occurred in the TOT group, and dyspareunia and thigh pain, only in the TVT-O group.⁵⁹

Dyspareunia following vaginal mesh surgery has commonly been described. Rates may vary and can reach up to 16.7%. Causes may include mesh shrinkage, anatomical distortion or over-tensioned mesh.³³ Entrapment of the DNC against the inferior pubic ramus as it courses along the posteromedial border of the inferior pubic ramus may be implicated in the causes listed for dyspareunia. Over-tensioning of the obturator arms can aggravate the pain and should the sling not be repositioned, it may cause permanent damage to the DNC. However, studies on sexual discomfort experiences by patients after mid-urethral sling placement are inconclusive.^{50,60,61}

In a systematic review and meta-analysis, Latthe *et al.* established a higher rate of thigh and perineal pain in the TOT/TVT-O group compared to the TVT group.⁶² In a study on functional results after tape removal for chronic pelvic pain, Ringaud *et al.* described 15 cases where TOT tapes were removed transvaginally. Twenty percent (3/15) of patients were diagnosed with pudendal neuralgia. In all 15 patients, the TOT tape passed through the obturator internus fascia. Pain was associated with indirect nerve compression due to incorrect placement of the tape.⁴⁷ The PN or its terminal branches could thus be damaged in the pudendal canal should the tape not be placed in the correct position.

Five cases of de novo pudendal neuropathy following TVT-O surgery were described by Paulson and Baker. All five patients fulfilled Nantes criteria for the diagnosis of pudendal neuropathy. The pudendal neuropathy could be diagnosed by a positive anaesthetic response during PN block. Anaesthetic agents were administered over time and with the continuation of these nerve blocks, the discomfort decreased.⁶³

Zhan *et al.* performed a study to compare the TVT-O and TOT tape methods regarding the proximity of the tape to the obturator canal and inferior pubic ramus. They found that the TVT-O tape was further away from the inferior pubic ramus, with a mean distance of 3.9 mm \pm 4.4 mm compared to the TOT tape, which was found 0.4 mm \pm 1.3 mm away from the inferior pubic ramus.⁶⁴

As perineal incontinence procedures vary regarding the proximity of the tape to the inferior pubic ramus, it has implications for the involvement of the DNC and needs to be investigated amongst different population and BMI groups.

1.3.4 Transobturator tape (TOT) procedure in males

The transobturator tape procedure can also be performed in males for the treatment of urinary incontinence. Following radical prostatectomy, urinary incontinence is a common occurrence, with 5 - 20% of patients reporting this condition. Post-prostatectomy stress urinary incontinence has been a factor attributed to intrinsic sphincter dysfunction and/or bladder dysfunction.^{65,66} In a study done by Ficazzola and Nitti involving 60 patients, 67% reported the incidence of incontinence due to intrinsic sphincter dysfunction and 23% reported intrinsic sphincter dysfunction along with bladder dysfunction.⁶⁷ Recently, the placement of a TOT was introduced as surgical treatment of choice in male stress urinary incontinence following radical prostatectomy.^{65,66}

Rehder and Gozzi described the inside-out TOT procedure in males as follows: The bulbospongiosus muscle is exposed by a vertical midline perineal incision. The muscle is then split centrally and retracted laterally. Dissection is extended to the perineal body to expose the urethral bulb. The bulbospongiosus muscle is partially removed from the perineal body to allow

ventral urethral elevation and compression by the sling. Blunt finger dissection is used to identify the space between the corpus cavernosum laterally and the corpus spongiosum medially. A skin incision is made in the genitofemoral fold to mark the exit point, lateral to the scrotum, the height corresponding to the base of the penis when it is reflected onto the lower abdomen. The trocar is then inserted through the space between the bulb and the ischiocavernosus muscle. It is guided through the upper medial border of the obturator foramen, slightly below the tendon of the adductor longus muscle to exit at the marked exit points.^{65,68}

Rapp *et al.* described the outside-in TOT approach in males as follows: The inferior pubic ramus is palpated and a skin incision is made just lateral to it. The trocar is advanced under manual guidance through the obturator foramen from outside to inside, and exits lateral to the bulb of the penis.⁶⁹

No studies comparing the inside-out and outside-in procedures in males could be found.

The perineal nerve and its posterior scrotal branches might be at risk to injury during the dissection around the bulb of the penis and the insertion of the trocar in the space created between the bulb of the penis and the corpus cavernosum. It is therefore of great importance to know exactly where to find these branches so that damage can be avoided during the dissection in this area.

The DNP may be in danger when the inside-out procedure is performed by an inexperienced surgeon. The inferior pubic ramus may be scraped to ensure that the trocar exits at the correct exit point, as the trocar follows a blind passage around the inferior pubic ramus, putting the DNP at risk, which can be found posteromedial to the inferior pubic ramus.

1.3.5 Mini slings: MiniArc sling

The MiniArc is the most recent mini-sling, first introduced in 2007 as a third generation suburethral sling to treat female stress urinary incontinence (SUI).⁷⁰ This device is considered to be less invasive, due to a shorter insertion trajectory. Complications are reduced by avoiding

blind passage through the retropubic space. Postoperative pain in the adductor region is also reduced.⁷¹⁻⁷⁴

The MiniArc is a single incision sling from American Medical Systems. The sling kit consists of an 8.5 cm monofilament macroporous polypropylene mesh, with self-fixating polypropylene tips. The curved needle fits into the self-fixating tip for placement of the sling and can be removed once the correct positioning is achieved.⁷⁵

Surgical procedure:

The MiniArc procedure can be performed under general, monitored anaesthesia care (MAC) or local anaesthesia in a hospital or outpatient setting. The patient is placed in the lithotomy position, supine, with the hips and knees flexed and the thighs abducted and rotated laterally. The sling is introduced through a single anterior incision of 1.5 cm below the external urethral orifice. The para-urethral tissue is dissected to create a tunnel towards the posterior surface of the inferior pubic ramus. The tunnel created should be wide enough for the mesh to lie flat under the urethra. The sling's self-fixating tip is attached to the curved needle tip to advance the sling into its position. Once attached, the needle is placed into the dissected tunnel, towards the obturator internus muscle, at an angle of 45°. The sling is advanced to penetrate the obturator internus muscle and obturator internus membrane below the inferior pubic ramus. The needle is removed by simply sliding it out of the fixating tip. The same steps are repeated on the contralateral side.^{70,71,76}

Tension to the sling, once it is placed, could be adjusted by a re-docking feature that provides access to the implanted tip placed on the initial side. Tensioning of the sling is used as per surgeon's discretion, or if a patient is under local anaesthesia, a cough test can be performed so that adjustment of the sling can be completed.^{70,71,76}

As the MiniArc sling is positioned similarly to that of the transobturator tape, the DNC is also potentially at risk.

1.3.6 Perineal procedures for faecal incontinence

The use of perineal sling procedures is not limited to treat urinary incontinence only and has been applied for faecal incontinence. Faecal incontinence, also known as anal incontinence, can be defined as the unintentional loss of gas, or solid or liquid stool. True anal incontinence is the loss of control of the anal sphincter leading to the unintentional release of gas or faeces. Faecal continence has a negative impact on self-confidence, personal image and the ability to interact socially. Exact data on the prevalence of faecal incontinence are difficult to obtain because of the personal nature of the problem.^{77,78}

Faecal incontinence is more frequent in females than in males, and has been estimated to affect between 1% and 16% of females. Numerous studies point to a common cause for the development of urinary incontinence, anal incontinence and pelvic organ prolapse. The prevalence increases with age, obstetric injury, connective tissue disorders and pelvic surgery.

Childbirth remains the major contributory factor for the development of urinary or anal incontinence and genital prolapse. Genital prolapse is associated with anatomical and functional alterations in the muscles, nerves and connective tissue of the pelvic floor during childbirth.⁷⁷⁻⁸¹ More specifically, the PN may be involved and manifest as PN neuropathy.^{77,82} Snooks *et al.* describe that PN terminal motor latency is increased in faecal incontinent patients, while nerve conduction to the sacral roots is normal. This suggests a distal lesion in the IRN. This injury can occur because of stretch injury to the pudendal nerves during perineal descent, injury sustained during childbirth, PN entrapment or a combination of these factors.⁸²

Sir Allan Parks emphasized the importance of an adequate anorectal angle (ARA) to maintain continence. Tension-free vaginal tapes, designed for the treatment of stress urinary incontinence, can be used to reduce the ARA. Based on this theory, a new sling, the perineal puborectalis sling, which is similar to the TVT, was developed. The sling is placed as a hammock around the rectum.⁸³ Yamana *et al.* observed some improvement of semi-liquid barium holding in the resting phase and defaecography after the surgery. The ARA in the straining phase was also significantly reduced, which means that the sling can prevent leakage at the moment of increased intra-abdominal pressure, such as coughing, heavy lifting or during exercise.⁸³ There is

a risk of possible intra-operative complications, which include rectal injury, bladder or urethral injury, vaginal injury or intractable bleeding. These injuries can be prevented by staying clear of the median plane while performing the surgery.⁸³⁻⁸⁵

More research is needed to determine the effectiveness of this sling and to determine all the complications which can occur during the procedure. Damage to the IRN during the placement or tightening of the sling is possible, as dissection in the intersphincteric plane and -space is performed.

1.3.7 Pudendal nerve blocks

The PN can be blocked by the injection of local anaesthetic. It is used for minor surgeries of the perineum and vagina and also for vaginal deliveries.⁸⁶ Blocking the PN relieves pain in the second stage of labour. Pain experienced during the second stage of labour results from the distension of the pelvic floor muscles, vagina and perineum by the presenting part of the foetus. The pain sensation travels via the sensory branches of the PN.^{86,87}

The patient is placed in the lithotomy position. The ischial spine is palpated transvaginally, but can also be palpated through the rectum. The PN is blocked bilaterally in the pudendal canal, where the nerve lies medial to the internal pudendal vessels, just lateral and inferior to the sacrospinous ligament.^{86,88,89} The nerve can be accessed by two approaches, transvaginal or transcutaneous (perineal). The anatomical basis for both approaches is to block the nerve proximal to its terminal branches.⁸⁶

The anaesthesia takes 5-10 minutes to infiltrate the area and to take effect. Most obstetricians perform PN block immediately prior to delivery, since it is only effective for 20-60 minutes, depending on the agent used, and whether it is used with or without epinephrine. Efficacy depends on the experience of the obstetrician.

Bilateral or unilateral failure is common, with a success rate of only 50% with the transvaginal route and 25% with the transperineal route.⁸⁶ It is therefore important not only to determine the course and relationship of the PN and its branches, but also to take note of the level at which the terminal branches split off from the main trunk.

1.3.8 Anorectal (Ischioanal) abscess and anal fistula drainage

Anorectal abscesses and anal fistulae present as the same disease process at different stages. The abscesses will be seen first, sometimes followed by fistulae. Abscesses are the acute manifestation, whereas fistulae present as a chronic condition. Perineal abscesses are found in all ages but are four to five times more common in males than in females.^{90,91} Anorectal fistulae occur in 30 - 60% of patients with anorectal abscesses.⁹²

Perineal and anorectal abscesses are drained by making a cruciate incision at the site of maximal swelling. At that site, pus is drained and cultured. The ischioanal fossa is then probed with a haemostat or finger to disrupt loculations and to facilitate drainage.^{90,92}

Upon entering the ischioanal fossa, the cutaneous branches of the IRN can be found close to the skin as they terminate at the external anal sphincter. The IRN can also be found in the lower third of the fossa. Therefore, during incision of an anorectal abscess or surgery to drain an anorectal fistula, these branches of the PN are liable to injury in this area. Shafik and Doss hypothesize that faecal incontinence, which may occur after fistula operations, could be due to injury to the IRN rather than sphincteric injury.²⁴

Anorectal abscesses are classified by their location in the potential anorectal spaces in which they might occur. Peri-anal is the most common location, followed by ischioanal, intersphincteric and supralelevator, which is the least common. When the infection is connected circumferentially through all of the above mentioned spaces, it can result in a horseshoe abscess. As surgical treatment is dependent on the type of abscess it is important to classify it beforehand.^{90,92}

Before an abscess can be drained, the origin should first be determined. Failure to manage a supralelevator abscess may result in fistula formation. Should the origin be intersphincteric, the abscess should be drained through the rectal mucosa and not through the ischioanal fossa, as it would result in the formation of a suprasphincteric fistula. If the abscess originates from the ischioanal fossa, it should be drained through the fossa and not through the rectal mucosa, as it will result in the formation of an extrasphincteric fistula.^{81,83}

A horseshoe abscess which extends on either side of the midline, can be drained adequately by a radially placed posterior incision with counter-incisions over each ischioanal fossa lateral to the anal sphincter. The counter-incisions are kept open with Penrose drains which encircle the skin bridges that have been created.⁹²

To avoid injury to the branches of the IRN, it is important to gain an understanding of the course and direction of these nerves, and how they may possibly differ amongst population and gender groups.

1.3.9 Dorsal penile nerve block

Neonatal circumcision is one of the oldest and most commonly performed surgical procedures in the United States of America.^{8,9} Most neonates are circumcised for religious or cultural reasons. Dorsal penile nerve block (DPNB) was first described in 1978 for providing pain relief during neonatal circumcision.^{8,9,93} In adults a dorsal penile nerve block is used in preparation to perform various procedures including phimosis and paraphimosis reduction, circumcision, dorsal slit of the foreskin and in the repair of penile lacerations.⁹⁴

The penis is innervated by branches of the PN (S2-S4). The PN branches into bilateral, dorsal penile nerves which are sensory branches to the foreskin, glans and the shaft of the penis. The nerves are located between Buck's fascia and the corpora cavernosa at the 10-o'clock (left supero-lateral) and 2-o'clock (right supero-lateral) positions on the penile shaft, where the 12-o'clock position is directly superior in the midline to the penile shaft. These nerves are located approximately 3-5 mm beneath the skin and course distally towards the glans where they become more superficial (1-3 mm beneath the skin).^{93,94}

Technique:

The penile root is palpated to identify the 10-o'clock and 2-o'clock areas. The identification is important because it will dictate the point distal to the penile root into which the infiltration is made. Gentle traction at an angle of about 20-25 degrees, secures and straightens the penile shaft. The skin is pierced with a 27-ga needle at the 10-o'clock position, slightly distal to where the pubic skin and penile skin meet. The needle is advanced postero-medially at an angle of 25

degrees into the subcutaneous tissue. The needle should not be inserted deeper than 0.25-0.5 cm. After confirming that the tip of the needle is freely movable (an indication that the tip of the needle is located in Buck's fascia), 0.2-0.4 ml of 1% lidocaine is injected at that point. The procedure is then repeated on the opposite side of the penile shaft at the 2-o'clock position. Since the penis is small in neonates, DPNB is accomplished in a circular lidocaine ring. The injections should be made three minutes before performing the procedure.^{8,9,93,94}

The most common complication is the penetration of the superficial dorsal vein, which is situated alongside the dorsal penile nerve. Penetration of the vein will cause some bruising and bleeding.

Partial block may also occur, in which only partial anaesthesia of the foreskin is obtained. As it was found that the occurrence of a partial block is greater when performed by an inexperienced surgeon, it seems probable that improved knowledge of the position and relationships of the DNP would be advantageous in these cases.^{9,93}

1.3.10 Radical perineal prostatectomy

Radical prostatectomy is an accepted option of treatment for patients with prostate cancer. A significant drawback of this surgery is the high risk of postoperative urinary incontinence and impotence. Although only a few patients develop urinary incontinence, significant leakage is seen in a number of patients.^{10,11,95} Apart from the neurovascular bundles that lie adjacent to the sides of the prostate capsule which are responsible for autonomic functions, such as urinary continence, somatic PN branches of the pelvic plexus are involved in the urinary continence mechanism. The importance of these nerves is the location of the branches and the potential sites of injury during radical prostatectomy.^{10,11} Branches from the DNP that supply the urethral sphincter, are closely related to the prostatic apex at the level of the inferior margin of the pubic symphysis. These branches are therefore vulnerable to injury during this procedure.

The branches of the PN can be damaged in several ways. It could be included in one of the many stitches inserted in the tissue around the prostatic apex, or it could be included in the deep stitches before dividing the dorsal vein complex. The delicate branches could be torn or

stretched by excessive traction on the prostate before it is separated from the urethra. Sphincteric branches are liable to direct injury if wedge pubectomy is performed. Lastly, the nerves may be injured during extensive apical dissection for cancer involving the area around the prostate. The branches are not bilaterally symmetrical and may even be unilateral. This emphasizes the need for avoiding damage to them during radical prostatectomy.¹¹ Damage to these sphincteric branches in a patient in whom they are present bilaterally would result in partial urinary incontinence, while severance of unilateral branches would result in significant weakness of the external urethral sphincter.¹⁰

Nerve-sparing radical prostatectomy is a modified technique to avoid or limit damage to the branches of the pelvic plexus responsible for the innervation of the corpus cavernosum.⁹⁶ In a study done by Talcott, *et al.* on impotence and incontinence after nerve-sparing radical prostatectomy, 83% of patients who had unilateral nerve-sparing surgery, were impotent. The results were identical for patients who underwent non-nerve-sparing surgery. Fewer cases of complete postoperative impotence in bilateral nerve preservation prostatectomy were reported. Urinary incontinence was also found more commonly in the unilateral nerve-sparing and non-nerve-sparing group than the bilateral nerve-sparing group.⁹⁷

A standardized technique for the nerve-sparing procedure should be used. However, even with a standardized technique, a learning curve exists. Better functional results will be achieved by a more experienced surgeon.⁹⁵

In previous studies, variations in the anatomy of the PN and its branches were found, and an accessory nerve has been described.^{1,12,24} At the periphery, lateral to the bulbospongiosus muscles, superficially located perineal branches were found which could be damaged, resulting in sensory skin deficits. In 20% of cadaveric studies, a PN plexus with interconnecting branches with the IRN and perineal nerves were found in the ischioanal fossa in close proximity of the external anal sphincters. This plexus could be injured during radical perineal prostatectomy, resulting in faecal incontinence.^{1,98}

The course and branches of the PN have implications for the procedures considered and will be investigated in this study to enable the clinician to do these procedures with more safety, precision and confidence.

1.4 Aim:

The aim of this study was to re-evaluate the pudendal nerve, its branches and relationships, as it is implicated in various pelvic and perineal procedures in South African population and sex groups.

Research objectives

Part 1:

1. To dissect out the course and branches of the pudendal nerve in adult embalmed cadavers of each sex (male and female) and population (black and white) groups, in order to give a thorough account of the anatomy of this nerve.
2. To identify landmarks used when various procedures are performed, including the position of the incisions made and the trajectory of the needles/instruments.
To establish important relationships of these landmarks that need to be considered, as they involve the pudendal nerve and branches.
3. To measure and note distances between the identified landmarks and the course and branches of the pudendal nerve.

Part 2:

1. To apply this knowledge to predict safe areas in each surgical procedure, taking into account population group or body variations if applicable.

Part 3:

1. To perform various newer procedures on 15 male and 15 female fresh, unembalmed cadavers.

Procedures performed on females included tension-free vaginal tape (TVT), outside-in transobturator tape (TOT), inside-out transobturator tape (TVT-O) and the Richter's procedure.

The inside-out transobturator tape (TOT) procedure was performed on males.

2. To measure distances from the pudendal nerve at crucial points to the trajectory of the needle or the position of the incision made.
3. To calculate the cadaveric body mass index and note its influence on these measurements.

Chapter 2: Materials and methods

The following dissections and procedures were done on a South African sample and for the purposes of this study were divided into a black and white population groups. According to genetic constitution, the South African black population is considered broadly alike, with strong genetic affinities with the Negroid people of west and central Africa. The South African Black population group is the main population group to consider when dealing with South African patients, because they have long been the predominant inhabitants of South Africa.⁹⁹ The white South Africans comprise of descendants of European countries, primarily from the Netherlands, Germany, Great Britain, France and Portugal. Temporal change, founder's effect and admixture added to the genetic composition of the white South African group.¹⁰⁰⁻¹⁰²

2.1 Pudendal nerve dissection and measurements

This part of the descriptive study sets out to give a thorough account of the anatomy of the pudendal nerve and its branches and to note distances between the established landmarks.

Sample and methodology:

A total of 71 adult cadavers were available for dissections and consisted of 15 white males, 27 black males, 16 white females and 13 black females. The cadavers were dissected in the dissection halls of the Department of Anatomy, School of Medicine, Faculty of Health Sciences, University of Pretoria and University of Limpopo (Medunsa Campus).

Dissections of the right gluteal and perineal areas were performed on embalmed cadavers to demonstrate the course and branching pattern of the PN. Landmarks commonly used in previously considered procedures were marked and the closest distances from these landmarks to the PN and its branches were measured.

For the dissection of the PN and its branches, two approaches were used: a gluteal approach from posterior and perineal approach from anterior. For the gluteal approach (Fig. 7) a superior oblique incision through the skin and subcutaneous tissue was made, starting at the posterior

superior iliac spine (PSIS) and terminating at the greater trochanter (GT). A medial incision was made connecting the PSIS to the tip of the coccyx. The medial incision was extended circularly around the anus, terminating a few centimetres along the root of the penis (bulb of corpus spongiosum), where the scrotal sac commences when drawn anteriorly. In females this incision was extended around the anus and along the external border of the labia majora. In both sexes the incision terminated at the pubic symphysis.

The medial skin incision was deepened to detach the underlying gluteus maximus muscle from its origin to the sacrum, coccyx and sacrotuberous ligament. This flap was reflected laterally to expose the underlying structures. Once the sacrotuberous ligament was visible, it was detached from the sacrum and reflected laterally and downwards, in order to expose the underlying pudendal neurovascular bundle, ischial spine and sacrospinous ligament. The PN was followed posterior to the sacrospinous ligament through the lesser sciatic foramen and into the pudendal canal down to its branches in the ischioanal fossa. The ischioanal fat pad was cleared out via blunt dissection so that the IRN could be identified which crosses the fossa from lateral to medial. The perineal and dorsal nerves of the penis/clitoris were also dissected and traced anteriorly towards the penis/clitoris.

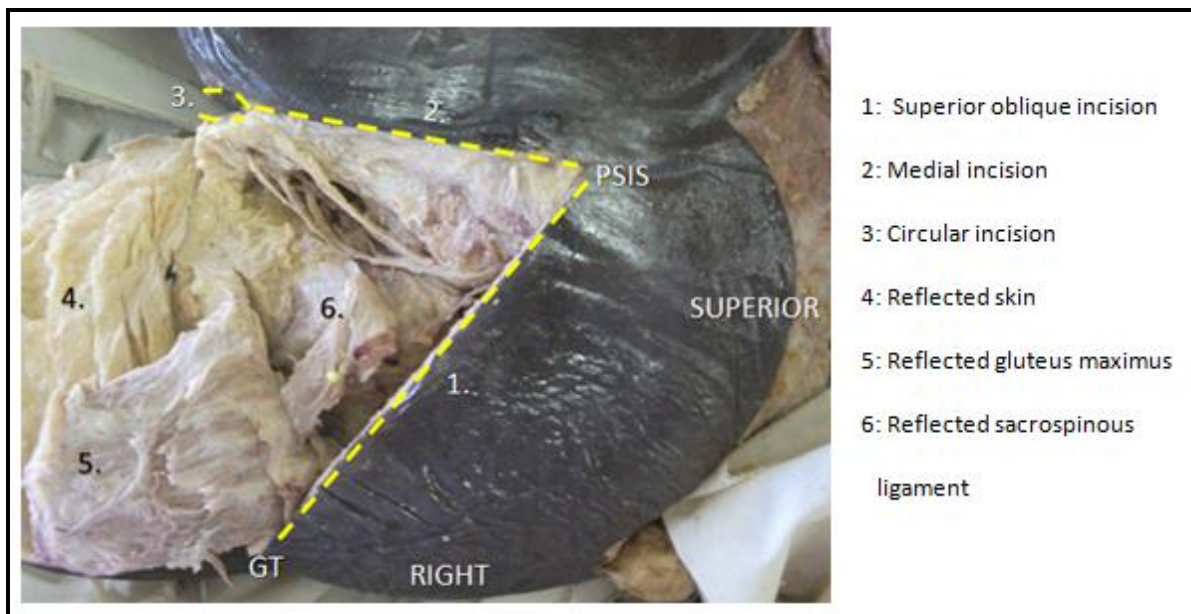


Figure 7: The gluteal approach

For the perineal approach (Fig. 8), a curved incision was made from the superior border of the pubic symphysis, along the pubic arch towards the ischial tuberosity. A second incision extended circularly around the anus and along the external border of the labia majora, terminating at the pubic symphysis in females. In males it extended circularly around the anus.

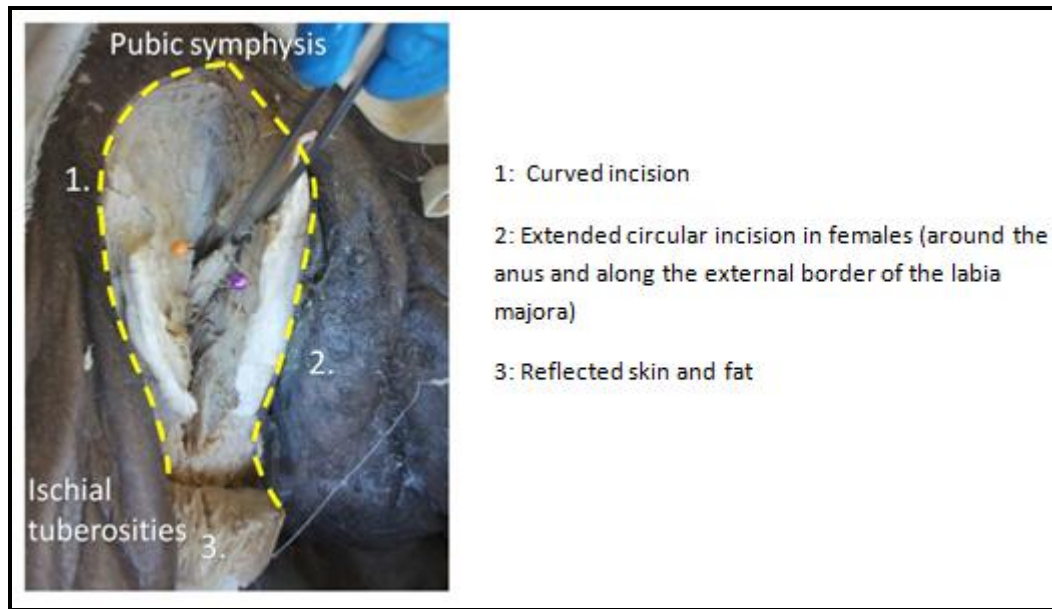


Figure 8: Perineal approach in females

In Table 1, the distances from various landmarks to the implicated nerves are set out along with their clinical applications. These distances are illustrated diagrammatically in Figure 9 – 16.

Table 1: Distances from landmarks to implicated nerves and their clinical applications

Measurement:	Clinical application:
<p>a. Ischial spine to the closest point of the pudendal nerve (PN) or its branches (Fig. 9)</p>	<p>Richter's procedure Pudendal nerve block</p>
<p>b. Distance between the superior attachments of the sacrospinous ligament</p> <p>c. Distance between the inferior attachments of the sacrospinous ligament (Fig. 9)</p>	<p>Richter's procedure</p>
<p>d. Closest point from the anal verge to the entry point of the deepest branch of the inferior rectal nerve into the external anal sphincter</p> <p>e. Closest point from the anal verge to the entry point of the intermediate branch of the inferior rectal nerve into the external anal sphincter</p> <p>f. Closest point from the anal verge to the entry point of the most superficial branch of the inferior rectal nerve into the external anal sphincter (Fig. 10)</p>	<p>Ischioanal abscess and fistula drainage</p>
<p>g. Most inferior point of the pubic symphysis to the dorsal nerve of the clitoris/penis (DNC/DNP) (Fig. 11/12)</p>	<p>Tension-free vaginal tape (TVT) Dorsal penile nerve block</p>
<p>h. The shortest distance from the junction of the body of the pubis and inferior pubic ramus to the DNC/P</p> <p>i. Shortest distance from the inferior pubic ramus to the DNC/P</p> <p>j. Distance of the midline to the DNC/P at the level of the inferior border of the pubic symphysis (Fig. 11/12)</p>	<p>Transobturator sling in males and females</p>
<p>k. Soft tissue points to the pudendal nerve: Bulb of the penis in males</p>	<p>Transobturator sling in males</p>

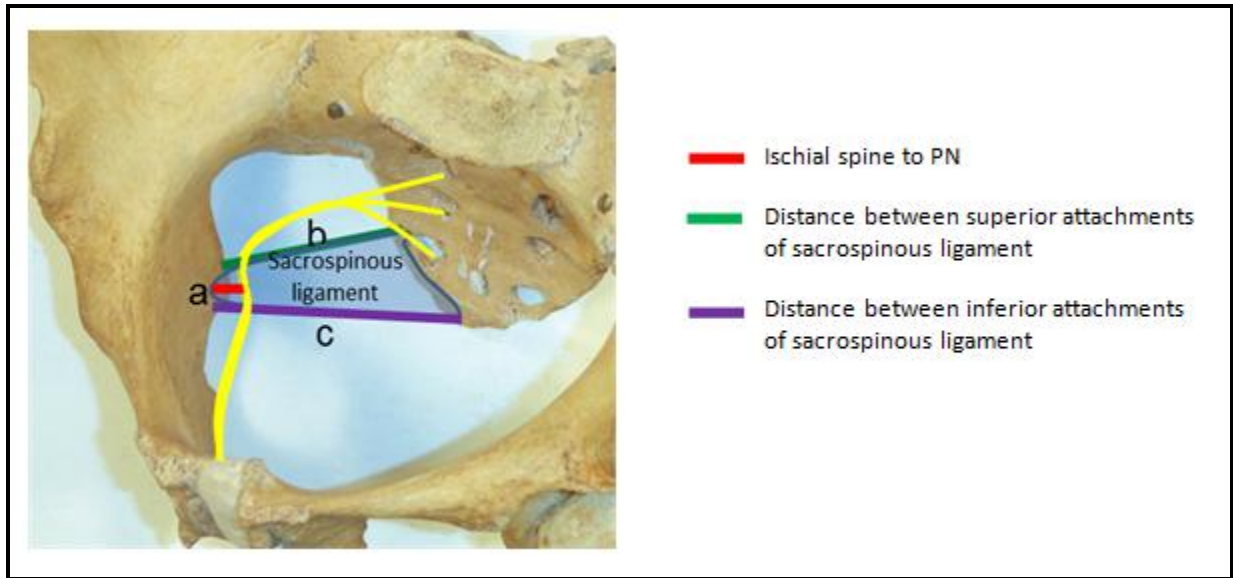


Figure 9: Measurements (a) and (b) indicated on a female pelvis




Figure 10: Measurement (f)

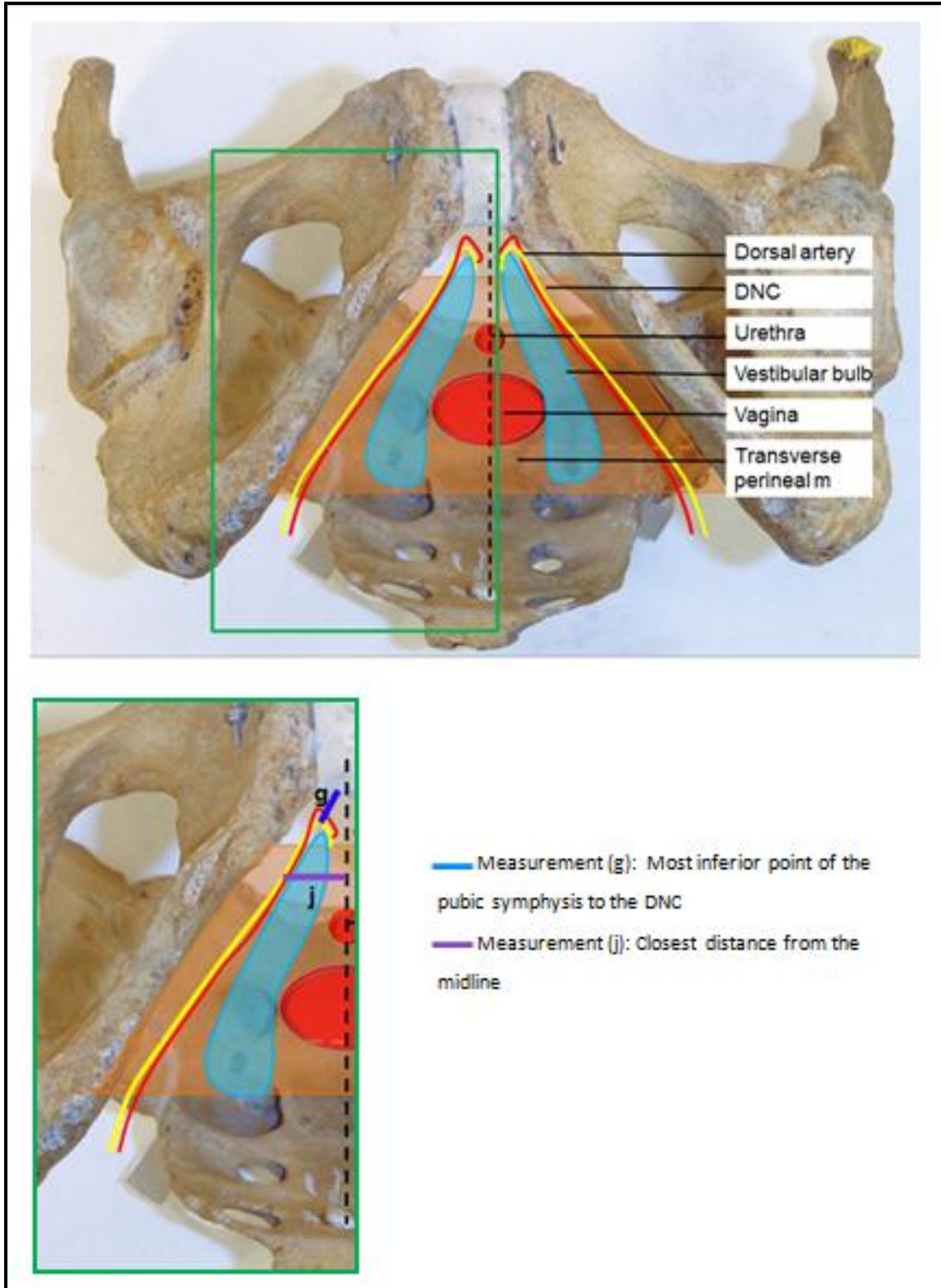


Figure 11: Measurements (g) and (j) indicated on the female pelvis

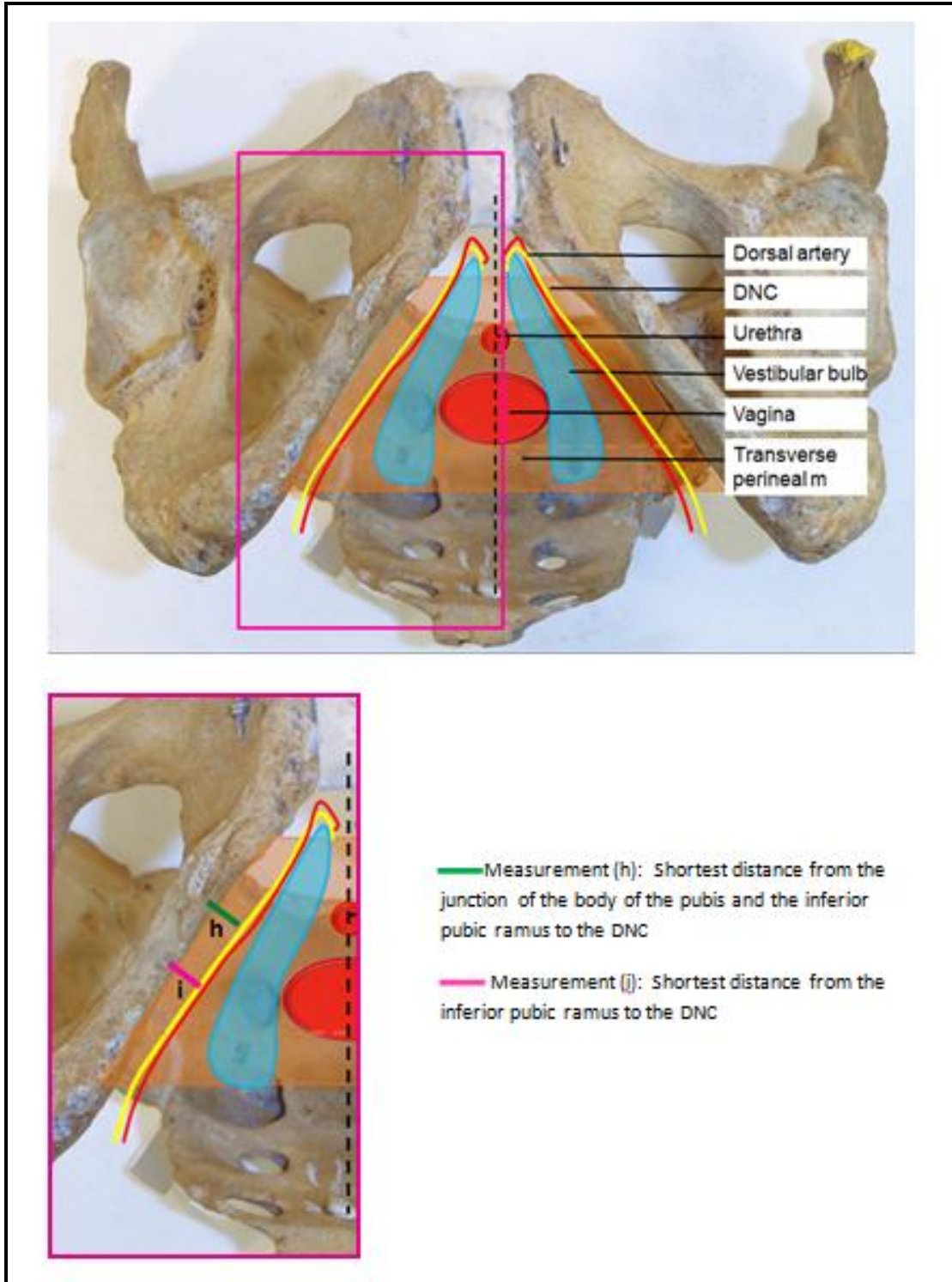


Figure 12: Measurements (h) and (i) indicated on a female pelvis

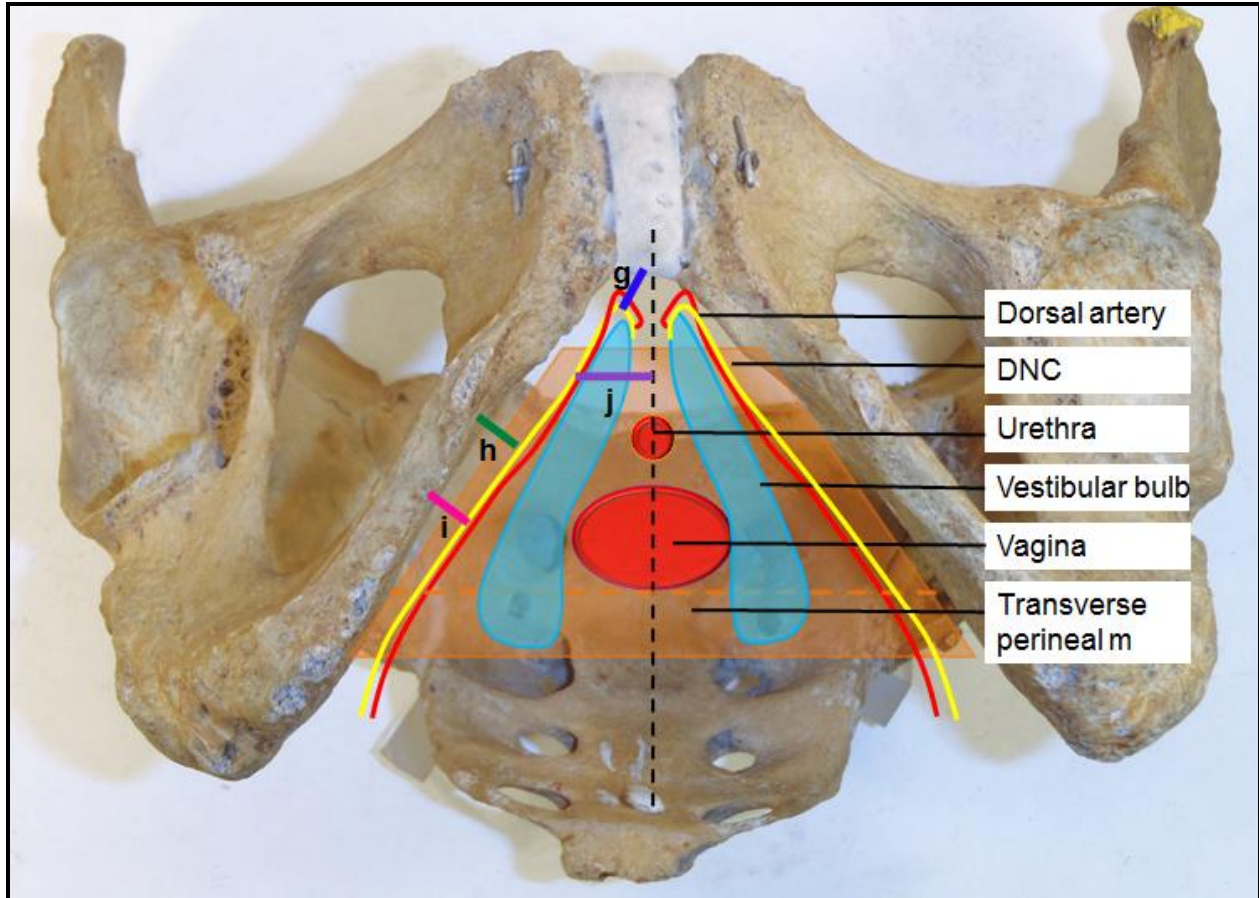


Figure 13: Measurements (g) to (j) indicated on the anterior view of a female pelvis

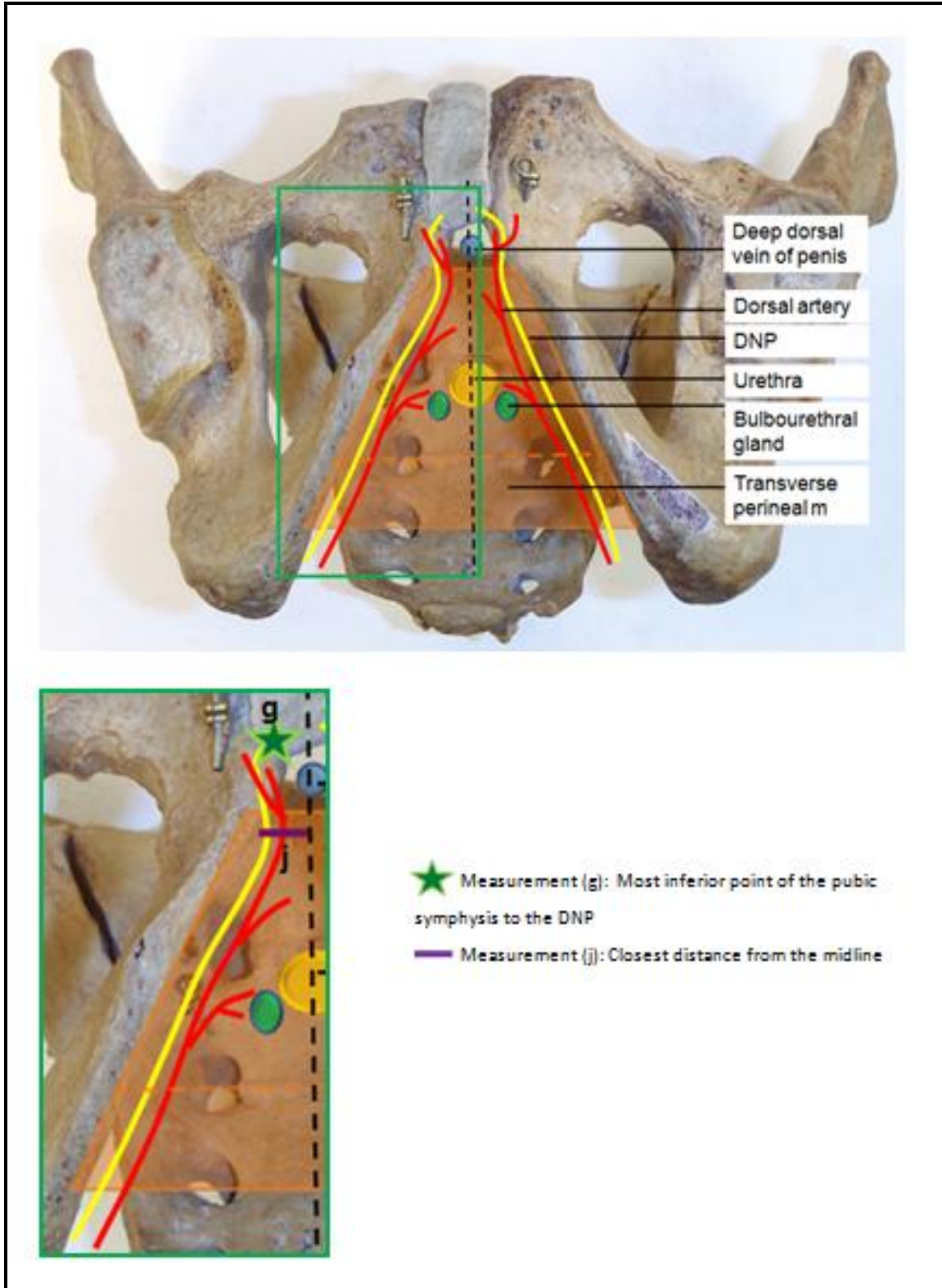


Figure 14: Measurements (g) and (j) indicated on a male pelvis

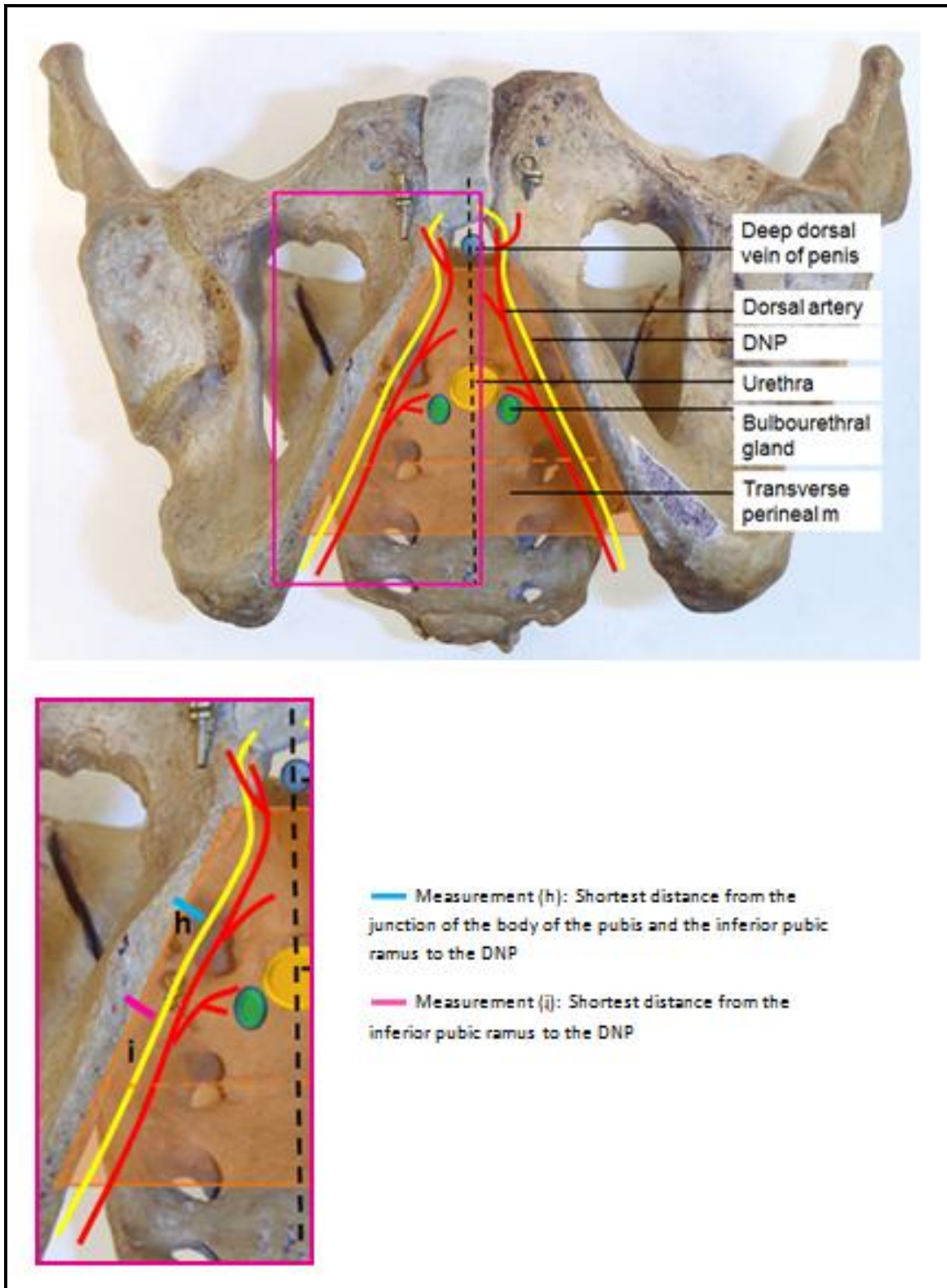


Figure 15: Measurements (h) and (i) indicated on a male pelvis

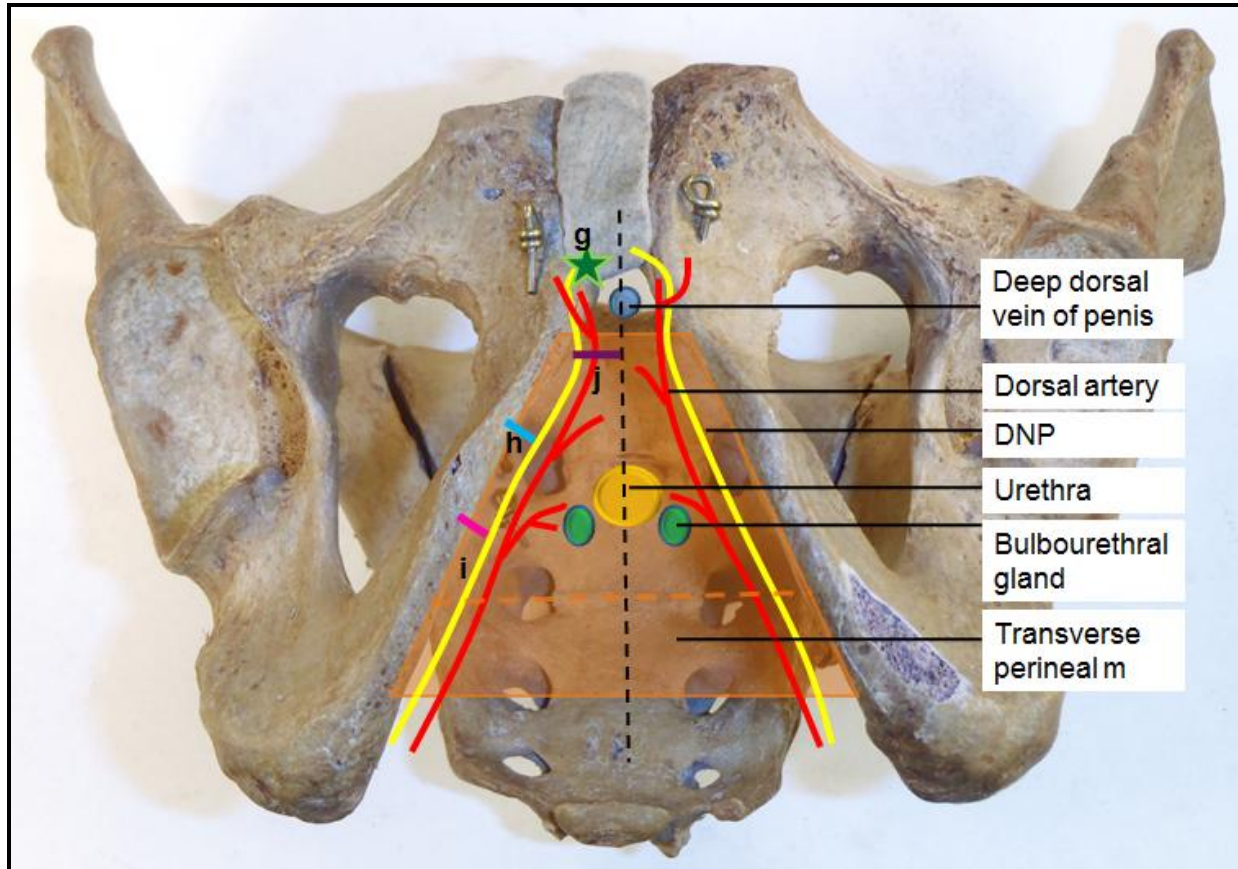


Figure 16: Measurements (g) to (j) indicated on an anterior view of a male pelvis

2.2 Predicting safe areas

Statistical analyses of the findings on the variations in the course and branches of the PN and distances to bony and soft tissue landmarks were done and integrated to predict safe areas for the procedures considered.

Statistical analysis was done with the assistance of Prof. PJ Becker from the Medical Research Council (MRC), Pretoria. Basic descriptive statistics such as summary statistics (mean, standard deviation, range and median) were presented for the parameters. After basic descriptive statistics were done, comparisons between groups were done using analysis of covariance (ANOVA) correcting for interactions amongst groups if found.

All the cadavers were included in the same regression analysis from which prediction intervals were derived to define safe areas.

Safe areas in each surgical procedure were established, taking into account population group and body variation differences where applicable. All measurements and findings were integrated and considered in the following procedures: The Richter's procedure for the treatment of vaginal vault prolapse, tension-free vaginal tape (TVT) and transobturator tape (inside-out and outside-in) for the treatment of stress urinary incontinence, pudendal nerve block, anorectal (ischioanal) abscess and anal fistula drainage and dorsal penile nerve block.

2.3 Perineal procedures performed

Various newer procedures were performed on fresh unembalmed female and male cadavers by a registered gynaecologist and urologist at the University of Pretoria, Prinshof campus, to evaluate the predictions made. After the procedures were performed, the bodies were embalmed. Dissections were done to determine the exact distance between crucial points of the PN and its branches to the sutures placed during Richter's procedures and/or the mesh tape which followed the trajectory of the needle during obturator procedures.

The cadaveric body mass index (cBMI) was calculated using the length and weight of the cadavers which were measured upon arrival of the unembalmed bodies at the University of Pretoria. The following formula: $\text{weight (kg)} / [\text{length (m)}]^2$ was used to calculate the cBMI for each individual. The cBMI, although not a true reflection of the BMI (body mass index), was useful for the purposes of this study. The cBMI categories were based on the BMI categories used for male and female patients, namely: lean (≤ 18.5), normal (18.6-24.9), overweight (25-29.9) or obese (>30.0).^{103,104} These four BMI categories for patients were pooled into three cBMI groups: those with a cBMI ranging from ≤ 18.5 -21.5 kg/m^2 were grouped together in the low to normal cBMI group and the cadavers with a cBMI ranging from 21.5 to 25.5 kg/m^2 were grouped together in a normal to high cBMI group. Cadavers with a cBMI exceeding 25.5 kg/m^2 were grouped together in the high cBMI to obese group. The influence of the cBMI on any measurements was determined.

2.3.1: Female perineal procedures performed

Sample and methodology

The Richter's procedure, tension-free vaginal tape (TVT), inside-out transobturator tape (TVT-O) or outside-in transobturator tape (TOT) procedures were conducted on 15 randomly selected female bodies, not preserved in formalin, by a registered gynaecologist and a registered urologist.

- The Richter's procedure was performed by using the Capiro suturing device as described by Goldberg.³
- The TVT procedure was performed according to the technique described by Ulmsten *et al.*⁴⁰⁻⁴²
- The TVT-O (inside-out transobturator tape) was inserted according to the technique described by Whiteside and Walters.^{46,54}
- The TOT (outside-in transobturator tape) was inserted according to the technique described by Ridgeway *et al.*^{12,52}

The Richter's procedure:

The Richter's procedure was performed on a total of ten female bodies, two black and eight white females. The bodies were placed in the lithotomy position, the position assumed by the cadaver lying supine with the hips and knees flexed and the thighs abducted and rotated laterally. An anterior approach was followed in the performance of the Richter's procedure in this study. A vertical incision was made in the anterior vaginal wall. This incision extended from the level of the bladder neck to the apex of the vagina (Fig. 17).

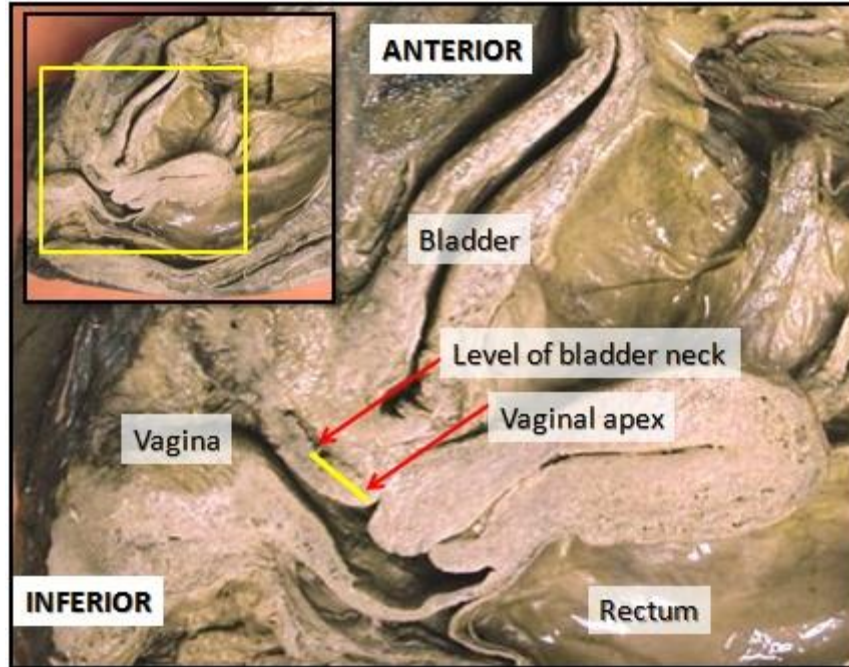


Figure 17: Right midsagittal section demonstrating the first incision in the anterior vaginal wall from the level of the bladder neck to the vaginal apex

A plane was established between the pubocervical fascia and the vaginal skin with sharp dissection. The dissection was continued until the descending pubic ramus could be palpated laterally, from which blunt dissection was performed until the ischial spine could be palpated. The position of the sacrospinous ligament could then be determined by tracing it from its insertion on the ischial spine to its origin on the sacrum. The Capio device was advanced 2 cm (two fingers' width) medial to the ischial spine where the suture was placed, penetrating the sacrospinous ligament.³

TVT Procedure:

The TVT procedure was performed on six white female cadavers. The tape used in the TVT procedures consists of two blue polypropylene mesh arms constructed of knitted filaments of extruded polypropylene stands, covered in a plastic sheath.

Prior to the performance of the procedures, the cadavers were placed in the lithotomy position. Three small incisions were made: two suprapubic and one 1.5 cm proximal to the mid-urethra

in the anterior vaginal wall. By using the two trocar needles, the polypropylene sling was introduced under the mid-urethra. As described by Ulmsten *et al.*, the trocars were passed from the vaginal entry point via the retropubic space to exit through the two suprapubic incisions^{41,42} (Fig. 18).

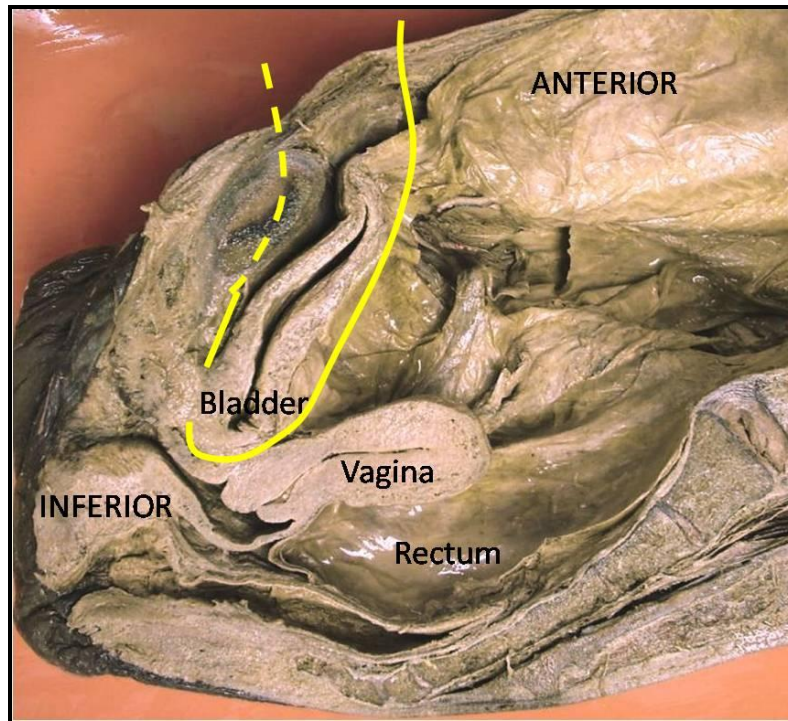


Figure 18: Right midsagittal section of the pelvis demonstrating the position of the tension-free vaginal tape

TVT-O Procedure:

The TVT-O procedure was performed on seven white, unembalmed, female cadavers. The tape used in TVT-O procedures is a blue polypropylene mesh, constructed of knitted filaments of extruded polypropylene strands. The sling consists of two arms (Fig. 19).

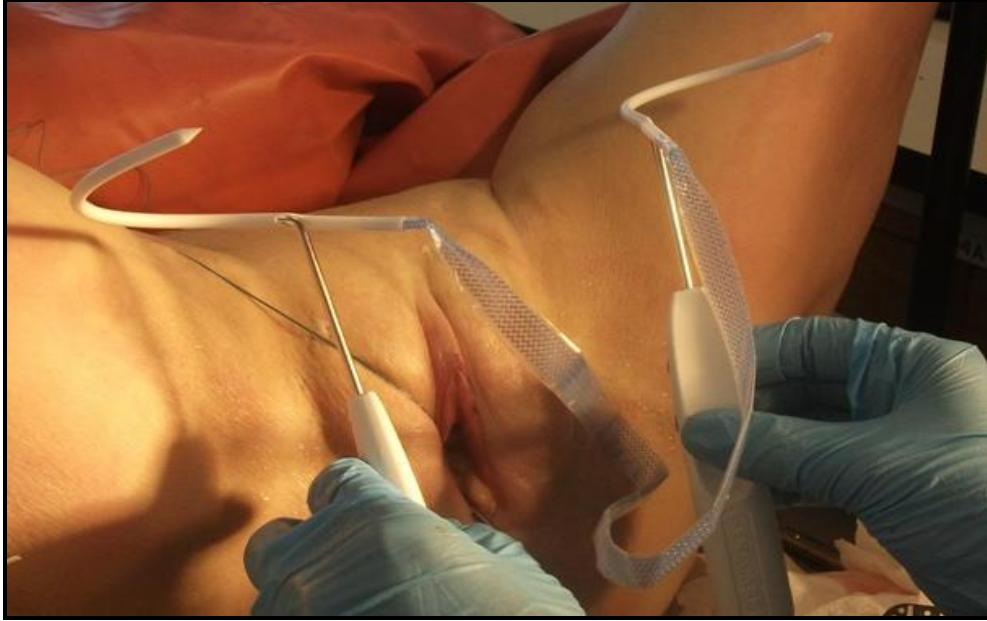

Figure 19: The inside-out female transobturator sling

Prior to the performance of the procedure, exit points were marked by tracing a horizontal line, 2cm superior to the level of the urethral meatus and 2cm lateral to the genitofemoral folds (Fig. 20).

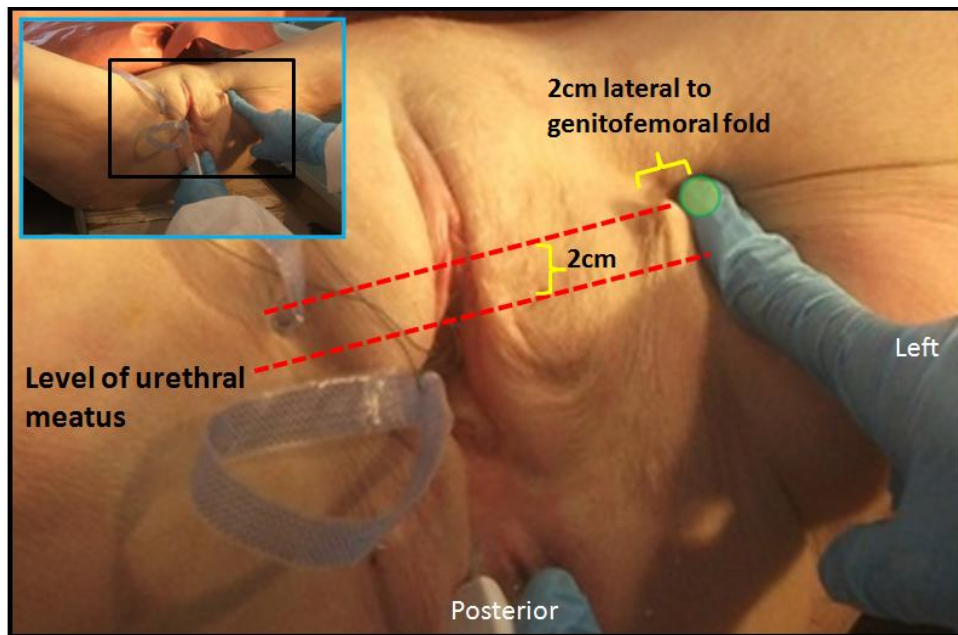


Figure 20: Position of the exit points of the TVT-O

A 1 cm midline incision was then made in the vaginal mucosa, 1 cm proximal to the urethral meatus. Blunt dissection was performed towards the palpable junction of the body of the pubic bones and inferior pubic ramus. A wing guide was placed into the dissected tract and the curved trocar was placed into the tract running around the inferior pubic ramus and through the obturator foramen. The trocars were anticipated to exit through the points previously marked. The tape was positioned loosely and flat under the mid-urethra.^{46,53-51}

TOT procedure:

The TOT procedure was performed on nine unembalmed, female cadavers (three black and six white individuals). Before positioning the tape for the TOT procedure, the cadaver was placed in a lithotomy position.

The tape used for transobturator tape placement is a permanent, synthetic suburethral sling made from knitted monofilament polypropylene and has low elasticity. This structure gives resistance to traction, allows tissue colonisation and facilitates positioning during surgery. The sling consists of two transobturator arms.

An incision was made on the anterior vaginal wall at the junction of the middle- and lower thirds of the urethra. Blunt peri-urethral dissection was performed through the anterior vaginal wall incision to the level of the inferior pubic ramus (Fig. 21). The inferior pubic ramus and obturator foramen were located manually: an index finger was placed in the vaginal groove and a thumb on the internal surface of the thigh. By pressing them together, the pathway around the inferior pubic ramus could be felt. A small vertical incision was made directly above the obturator foramen at the level of the clitoris, 1 cm beyond the inferior pubic ramus. The introducer needle was placed through the obturator incision until it perforated the obturator membrane.

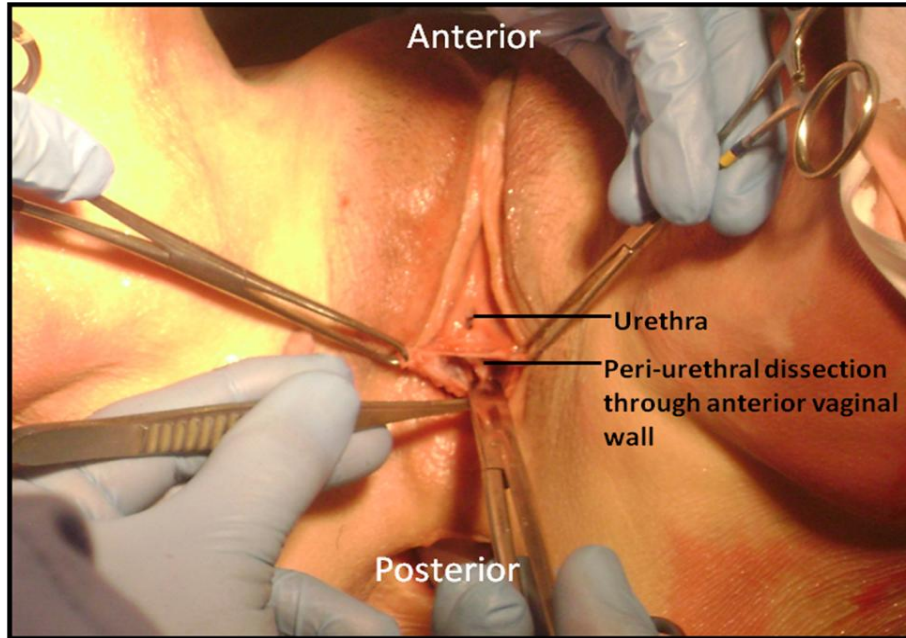


Figure 21: Plane created for blunt dissection towards inferior pubic ramus

The introducer was rotated to direct the tip to exit at the vaginal incision by using an index finger for guidance. The tape was attached to the introducer by threading it through the eye of the introducer. The tape was pulled through the eyelet and the introducer was reversed through the incision tunnel to secure the tape in the correct position. To prevent over-tensioning, a visible space should remain between the tape and the urethra.^{12,52}

After the procedures were performed, the bodies were embalmed for a minimum period of one month before dissection of the area, and measurements commenced. Measurements taken after the bodies had been embalmed are summarized in Table 2.

Table 2: Distances measured from identified landmarks and the PN and its branches in females, and their clinical applications	
Measurements taken:	Clinical application:
a. From the Richter's stitch to the PN, and where applicable, to the IRN.	Richter's procedure
b. From the TVT mesh to the DNC, posterior to the pubic symphysis.	Tension-free vaginal tape
c. From the TVT-O mesh to the DNC, as it ascends on the inferior pubic ramus.	Inside-out transobturator tape in females
d. From the TOT mesh to the DNC, as it ascends on the inferior pubic ramus.	Outside-in transobturator tape in females

2.3.2: Male perineal procedures performed

Sample and methodology

The transobturator tape (TOT) procedure was conducted by a registered urologist on 15 randomly selected, unembalmed male cadavers, (eight white and seven black individuals). The sling system used in this procedure is a permanent suburethral sling, made from knitted, monofilament polypropylene, which provides traction, facilitating proper positioning during surgery and allows for tissue in-growth. This sling consists of four arms: two transobturator arms and two prepubic arms (Fig. 22).

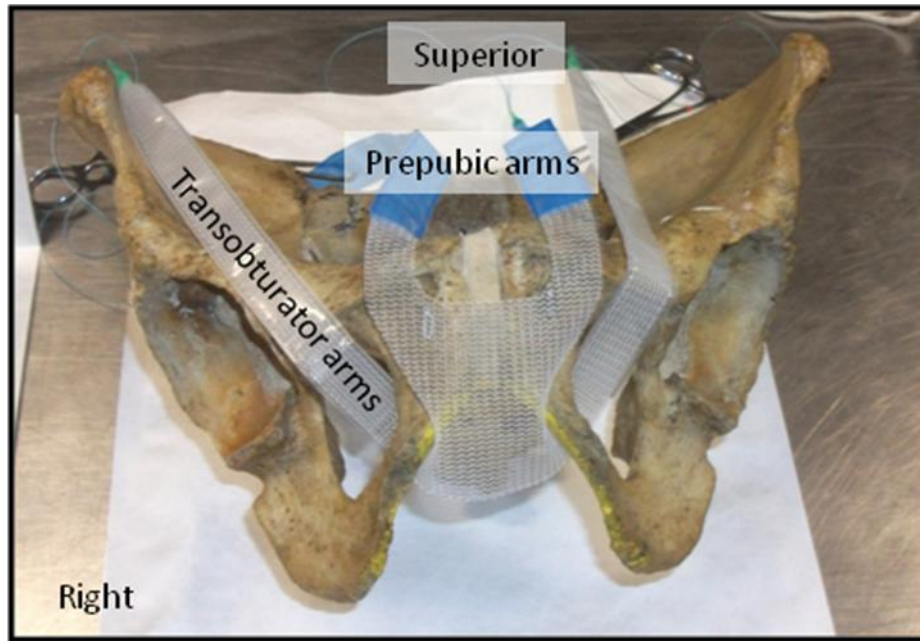


Figure 22: The four arms of the Virtue male TOT sling

The surgical procedure was similar to that described by Rehder and Gozzi which was in line with the package insert instructions.^{65,68} The transobturator arms were placed from medial to lateral through the obturator foramen as an inside-out procedure. To ensure correct exit of the needle in the genitofemoral fold, a slightly higher entry point of between 1-1.5 cm below the triangular junction of the corpus cavernosum and corpus spongiosum on each side was chosen (Fig. 23). In the package insert a distance of 2 cm was indicated.

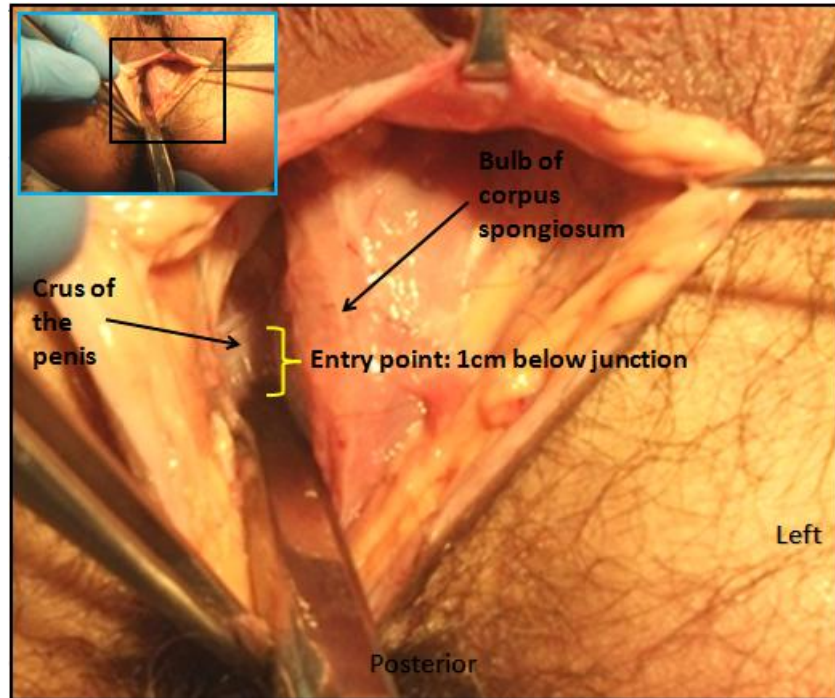


Figure 23: Position of the entry point of the male TOT introducer

The prepubic arms were placed subcutaneously by passing the introducer prepubically through the pubic incision (initially created for the placement of the transobturator arms), and out at an exit point 2 cm above the pubic symphysis and 2 cm lateral to the midline on either side. The introducer was passed anterior to the pubic bone to minimize the risk of urethral or bladder perforation, and medially, to prevent injury to the spermatic cord.

As tensioning and fixation of the arms should occur progressively and in succession, moderate tension was placed on the transobturator arms by simultaneously pulling both arms to elevate the bulbous urethra. Then, moderate tension was placed on the prepubic arms by pulling both superiorly in the same manner to compress the bulbous urethra. After the sling was placed in the correct position, maximum tension was placed, firstly, on the transobturator arms, followed by tensioning of the prepubic arms, to ensure proper placement.^{65,68}

Following the performance of the procedures, the bodies were embalmed. Dissections and measurements proceeded after a minimum period of one month of embalming. Measurements taken after the bodies had been embalmed are summarized in Table 3.

Table 3: Distances measured between the TOT mesh and the PN and its branches in males	
Measurements taken:	
a.	The closest distance from the mesh tape to the perineal branches running towards the bulb of the penis.
b.	The closest distance from the prepubic arm of the mesh tape to the DNP, when in danger.
c.	The closest distance from the obturator arm of the mesh tape to the DNP.
d.	The closest distance from the lateral border of the spermatic cord to the prepubic arm of the mesh tape.

The data was collected and variations amongst sex, population group and the cBMI for each group were tabulated. Relations were noted and predictions were made regarding safety and choice of each procedure for a specific group.

2.4 Ethical considerations

The skeletal material originates from two sources: donations and unclaimed bodies. In South Africa, under the National Health Act No. 61 of 2003,¹⁰⁵ anyone may donate his/her body for tissue transplants, medical training and research. This act also provides for any destitute individual who dies in a public hospital, to have the body donated. If an individual dies in a public institution and is not removed for burial by a spouse, a relative or a friend within 24 hours after death, the body may be handed over to an institution such as the University, for the purpose of medical research. The body is registered as unclaimed, even though the identity of the individual may be known. Alternatively, an individual can register as a 'whole body' donor at the Tissue Bank of the Faculty of Health Sciences at the University of Pretoria, prior to death. After death, a spouse or family member is also permitted to donate the body, provided that the deceased did not specifically state that his/her body is not to be donated. Donated bodies of individuals over 65 years of age, or individuals who had a disease (such as cancer) cannot be

used for tissue transplants. These bodies are automatically handed over to the Department of Anatomy for medical training and research.

Ethics approval from the Research Committee of the Faculty of Health Sciences of the University of Pretoria was obtained for this MSc degree (Protocol no: S56/2012), titled: 'The anatomy of the pudendal nerve and its branches and the clinical implications thereof'.

Chapter 3: Results

3.1 Pudendal nerve dissection and measurements

3.1.1 Description of the course and branches of the pudendal nerve

The pudendal nerve (PN) exits the pelvis through the greater sciatic foramen to enter the gluteal region. In 29.63% of black males, 38.64% of black females and 6.25% of white females, the inferior rectal nerve (IRN) exits the pelvis separately, without branching from the PN in the gluteal area, as seen in Figure 24. This branching pattern was not observed in white males. The IRN arose from the PN in the gluteal region in all white males.

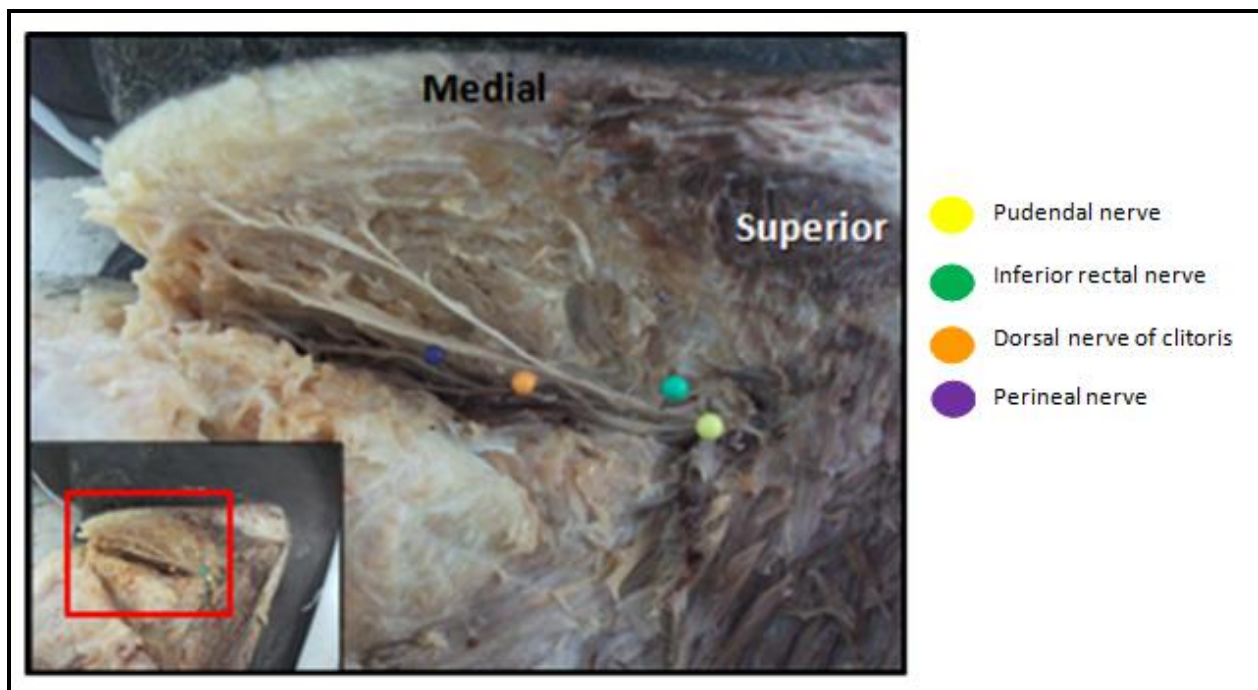


Figure 24: Gluteal dissection with IRN and PN exiting the pelvis separately

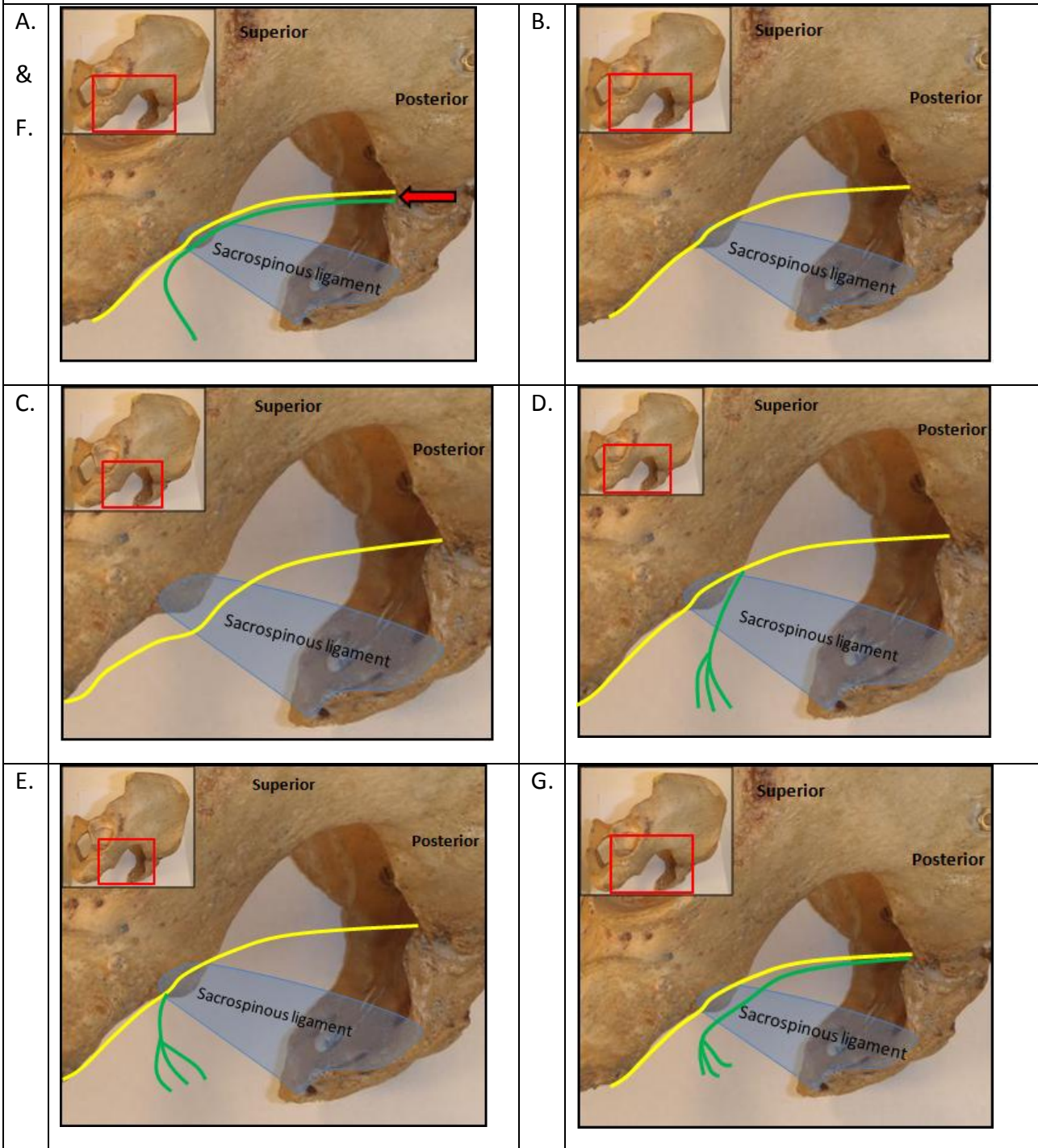
The following table depicts the course and various branching patterns of the PN and IRN in the gluteal region. The ratios and percentages within each sex-population group are given for variations described and labelled A to G. In Figure 25, diagrams are used to illustrate these variations.

Table 4: The proportion of individuals with defined course and branching patterns of the PN and IRN in the gluteal region by ancestry and sex

	Course and branches	1. n=27	2. n=15	3. n=13	4. n=16
A.	Separate exit of IRN from pelvis	29.63% 8/27	0% 0/15	38.46% 5/13	6.25% 1/16
B	PN passed posterior to the ischial spine	22.22% 6/27	66.67% 10/15	7.69% 1/13	62.5% 10/16
C	PN passed medial to the ischial spine	77.78% 21/27	33.33% 5/15	92.31% 12/13	37.5% 6/16
D	IRN originated at superior border of sacrospinous ligament	55.56% 15/27	73.33% 11/15	53.85% 7/13	68.75% 11/16
E.	IRN originated at inferior border of sacrospinous ligament	14.81% 4/27	26.67% 4/15	7.69% 1/13	25% 4/16
F	IRN and PN passed posterior to the ischial spine	0 0/27	33.33% 5/15	7.69 % 1/13	62.5% 10/16
G	IRN passed medial to the ischial spine	100% 27/27	66.67% 10/15	92.31% 12/13	37.5% 6/16

The four sex-population groups are abbreviated in Table 4 as follows: 1= black males, 2= white males, 3= black females, 4= white females. The sample size is indicated by n values.

Figure 25: The course and branching patterns of the PN and IRN in the gluteal region as set out in Table 4



● : Course of the PN

● : Course of the IRN

A-G: Variations as set out in Table 4

The PN (before, or after giving off the IRN branch) coursed medial to the internal pudendal vessels. It descended posterior to the sacrospinous ligament and anterior to the lateral third of the sacrotuberous ligament. In the white population group (66.67% in males and 62.5% in females), the PN more often passed posterior the ischial spine, as compared to the black population group (22.22% in males and 7.69% in females) (Table 4B/Fig. 25B). It was mostly found medial to the ischial spine in the black population group (77.78% in males and 92.31% in females) as compared to in the white population group (33.33% in males and 37.5% in females) (Table 4C/Fig. 25C).

Separate exit of the IRN from the pelvis occurred more often in the black population group (29.63% in males and 38.46% in females) compared to the white population group (0% in males and 6.25% in females) (Table 4A /Fig. 25A). It was more commonly seen in the white population group (73.33% in males and 68.7% of females), that the IRN was given off at the superior border of the sacrospinous ligament compared to the black population group (55.56% in males and 53.85% in females). This meant that the IRN and the PN crossed the ligament as two separate structures (Table 4D/Fig. 25D). In the remaining 26.67% of white males and 25% of white females, and 14.81% of black males and 7.69% of black females, the IRN was given off from the PN at the inferior border of the sacrospinous ligament, thus crossing the ligament as one structure (Table 4E/Fig. 5E).

The IRN often passed posterior to the ischial spine with the PN in white females (62.5%) (Table 4F/Fig. 25F). The IRN was mostly found medial to the ischial spine in white males (66.67%), black males (100%) and black females (92.31%) (Table 4G/Fig. 25G). It was noted that the PN and IRN was found further from the ischial spine and closer to the midline in the black population group compared to the white population group.

The IRN passed, in all cases, through the posterior third of the ischioanal fossa towards the external anal sphincter, where it split into its terminal branches, supplying the external anal sphincter.

After crossing over the inferior border of the sacrospinous ligament, the PN entered the pudendal canal. Upon its entry, the PN split into its two terminal branches, the dorsal nerve of the penis/clitoris (DNP/C) and the perineal nerve. The perineal nerve was the larger and more superficial terminal branch. The perineal nerve divided into a deep and superficial branch (Fig. 26). The deep perineal nerve supplied the perineal muscles and the superficial perineal nerve supplied the posterior labial/scrotal skin.

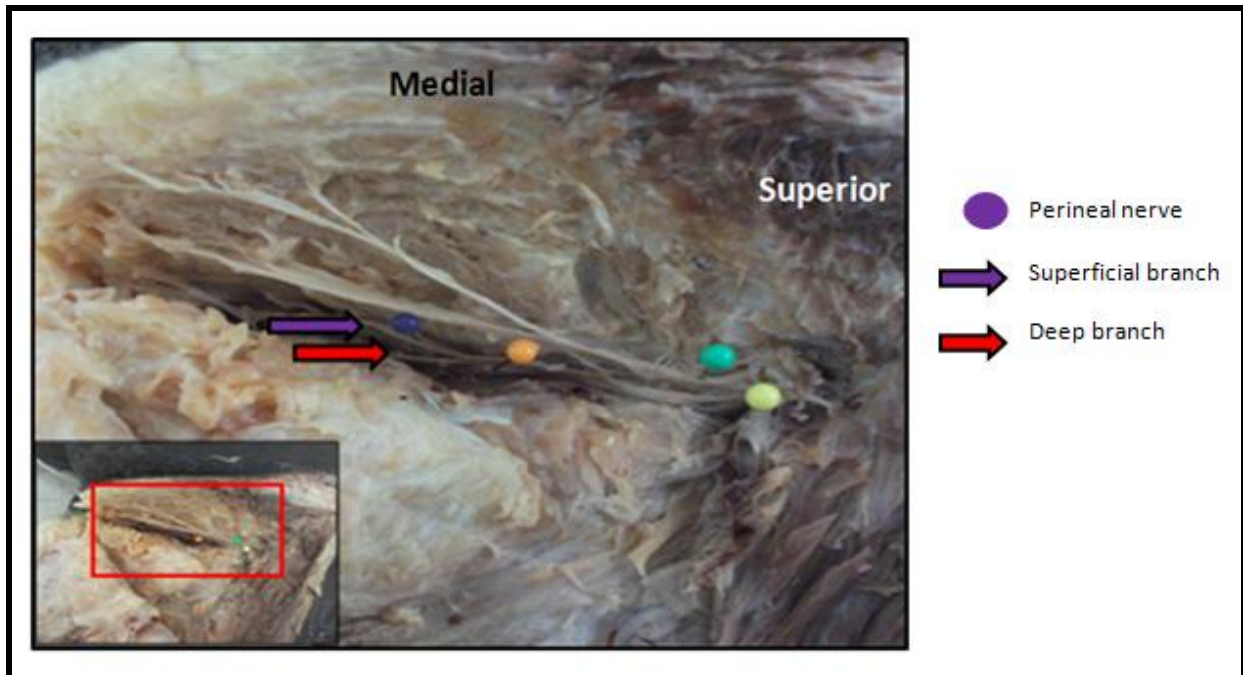


Figure 26: Gluteal dissection indicating the superficial and deep perineal nerves

The DNP/C passed deep to the perineal membrane and the perineal muscles in the deep perineal pouch. It ascended posterolateral to the origin of the ischiocavernosus muscle. It was found medial to the internal pudendal artery. It ran on the medial, and later the posterior surface of the inferior pubic ramus and ascended between the fibres of the suspensory ligament of the penis/clitoris, inferior to the pubic symphysis. It ascended on the dorsal surface of the penis/clitoris and terminated at the glans. As it ascended, it crossed over the internal pudendal artery to lie lateral to it (Fig. 27 and Fig. 28).

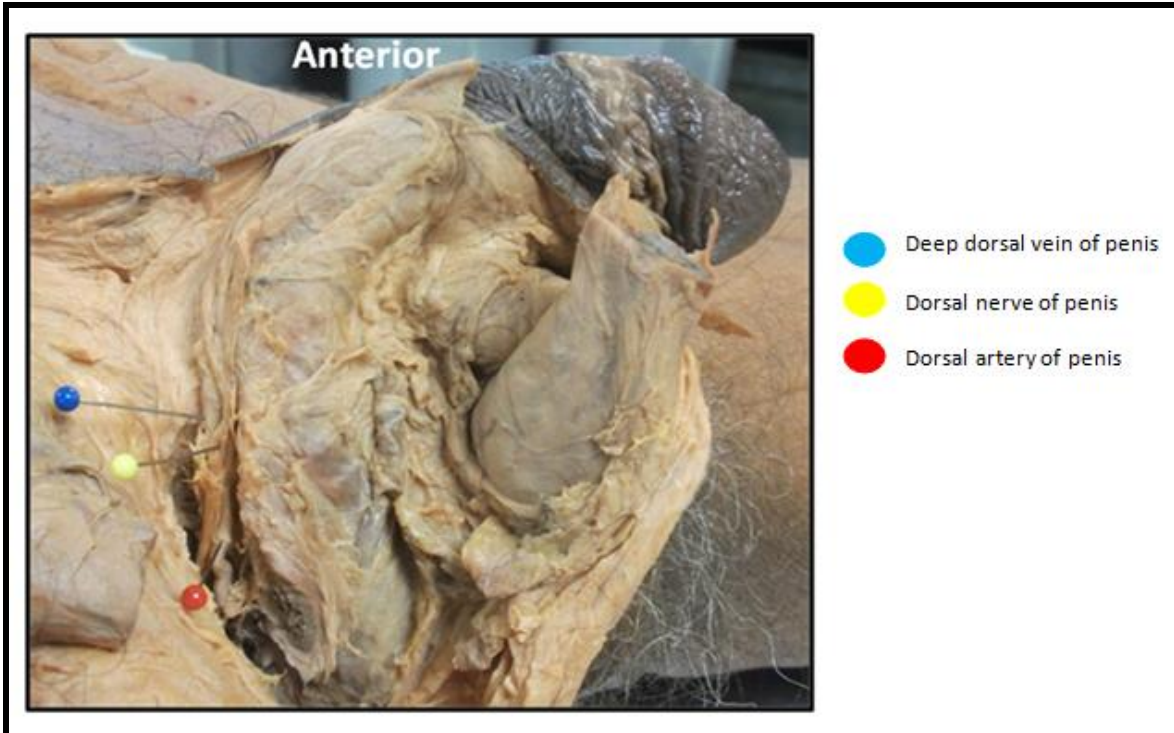


Figure 27: DNP and its accompanying vessels as seen from lateral

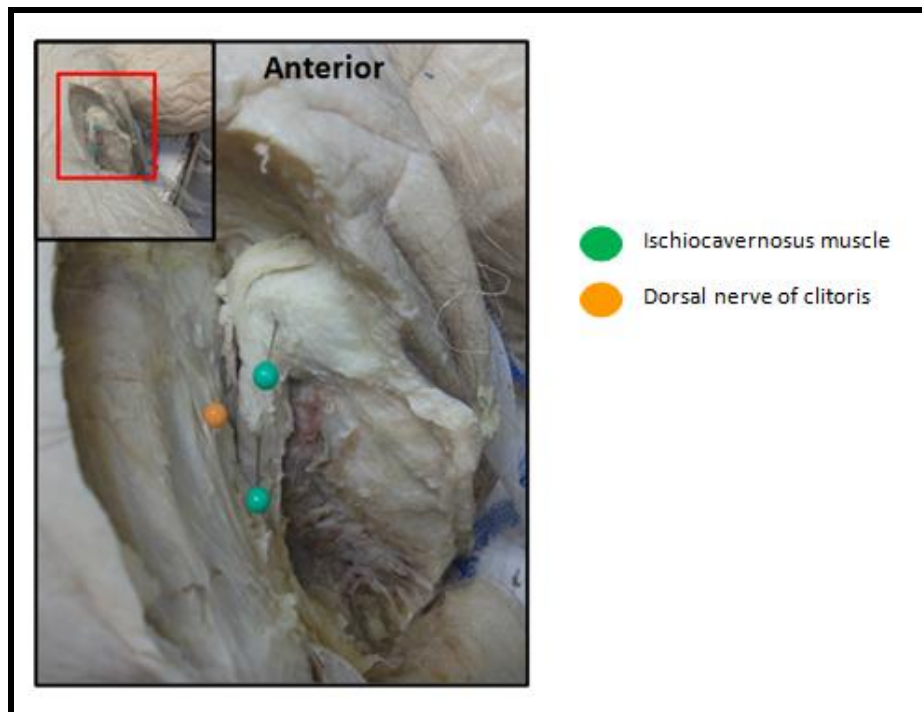


Figure 28: DNC as seen from lateral

Some variations noted in the branching patterns associated with the separate entry of the PN and the IRN into the gluteal region, included the fusion of the PN and IRN after it crossed over the ischial spine and within 15 mm, an accessory IRN branched from the PN. An accessory IRN was also found in one black female. In one black male, an inferior rectal branch was given off from the PN to fuse with the separate IRN at the inferior border of the sacrospinous ligament. In some cases the IRN received an accessory branch from the perineal nerve.

3.1.2 Distances from the pudendal nerve and its branches to important landmarks

The following figures and tables reflect the distances between the PN and its branches and identified landmarks. Each figure illustrates the measurements taken and the consecutive table displays the minimum and maximum distances from the indicated landmarks. These distances were used to predict safe areas for the perineal procedures considered.

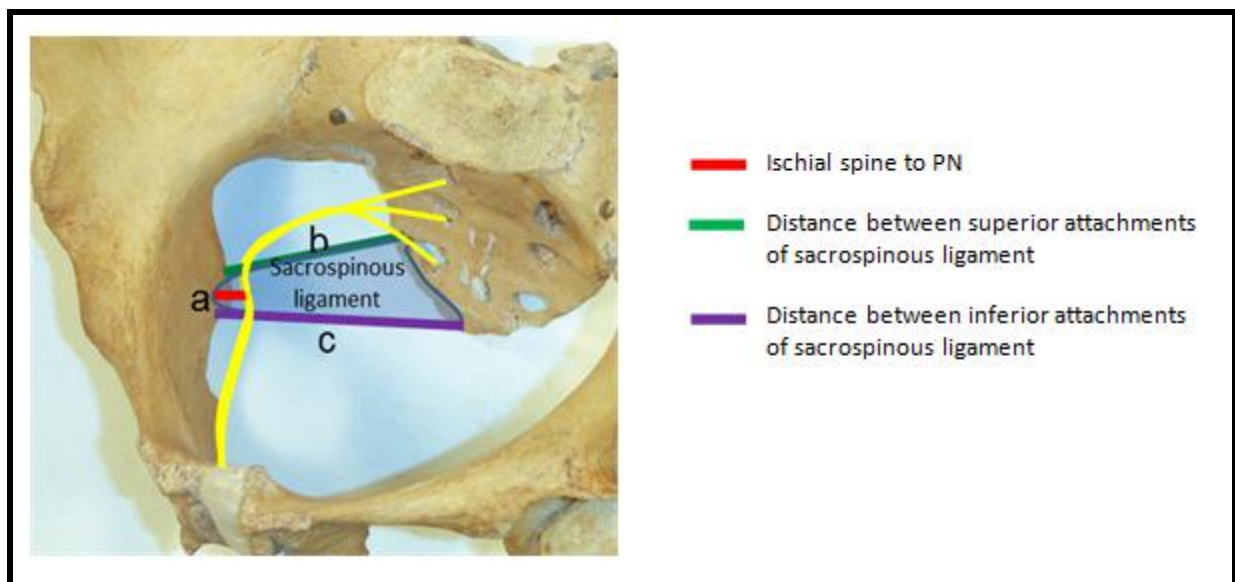


Figure 29: Measurements (a) to (c) indicated on a female pelvis




Figure 30: Measurement (f) indicated in a male cadaver

Table 5: Minimum and maximum distances in mm between the PN or IRN and bony landmarks or between landmarks in the gluteal region

Measurements taken:	1. (n=27)	2. (n=15)	3. (n=13)	4. (n=16)
a1 Ischial spine to PN	0.00–7.40	0.00-7.40	0.00-8.40	0.00-5.90
a2 Ischial spine to IRN	2.30-18.05	0.00-8.60	3.05-14.45	0.00-12.66
b. Distance between the superior attachments of the sacrospinous ligament	29.35-48.55	31.45-54.70	38.80-57.93	43.45-57.20
c. Distance between inferior attachments of sacrospinous ligament	33.49-56.60	40.70-57.80	46.85-59.85	48.97-65.30
d. External anal skin to IRN (minimum value)	9.05-24.00	10.50-23.00	6.45-20.90	3.25-24.10
e. External anal skin to IRN (intermediate value)	15.85-28.90	15.90-25.10	7.55-22.45	8.50-25.50
f. External anal skin to IRN (maximum value)	16.55-26.40	20.80-27.80	10.50-26.70	13.24-25.60

The four sex-population groups are abbreviated in Table 5 as follows: 1= black males, 2= white males, 3= black females, 4= white females. The sample size is indicated by n values.

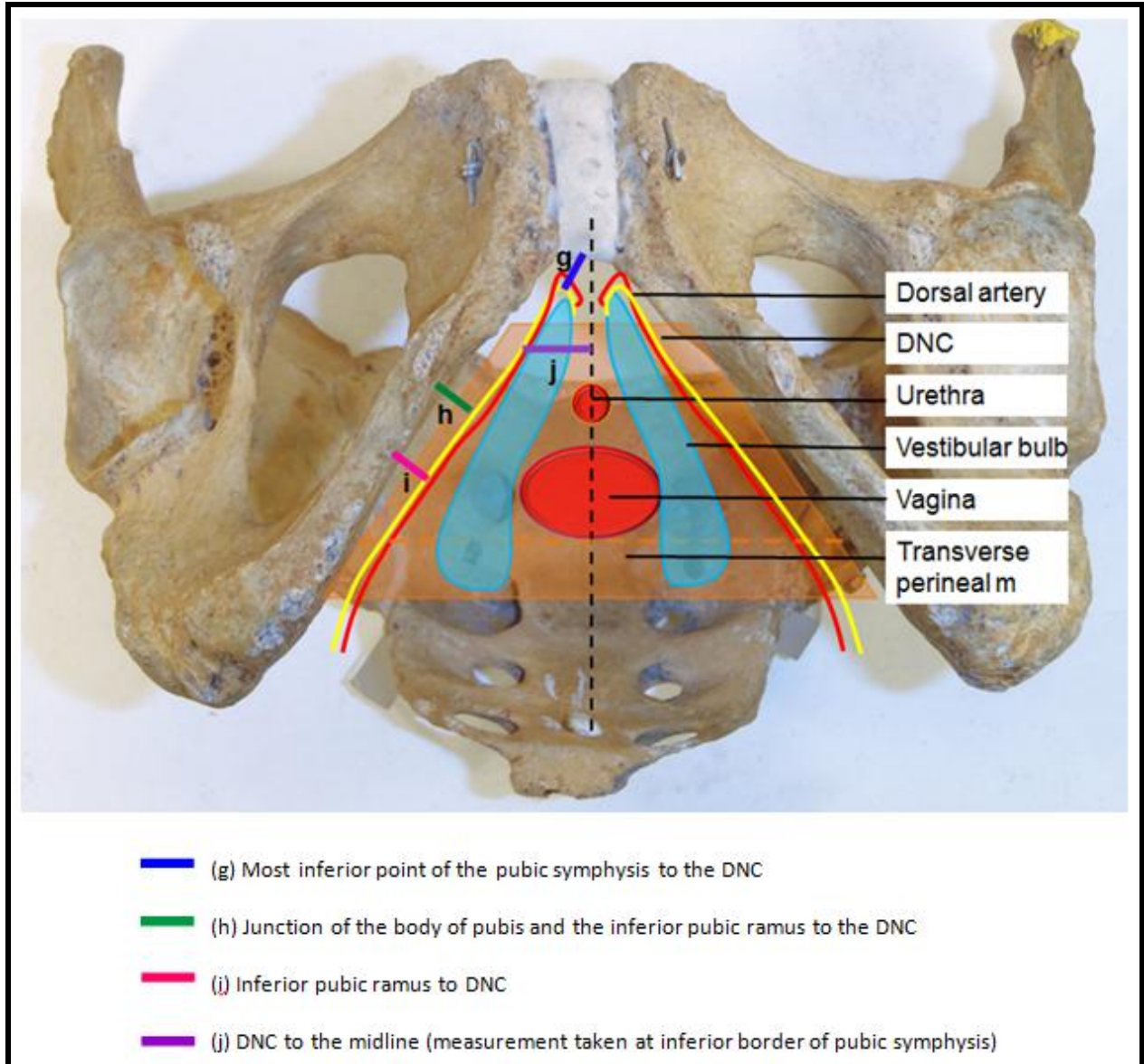


Figure 31: Measurements between landmarks and the DNC on a perineal view of the female pelvis

Table 6: Minimum and maximum distances in mm between the DNC and bony landmarks

Measurements taken:		3. (n=13)	4. (n=16)
g.	Most inferior point of pubic symphysis to DNC	0.00-3.45	0.00-2.38
h.	Junction between body of pubis and inferior pubic ramus to DNC	2.96-5.86	2.80-5.42
i.	Inferior pubic ramus to DNC	0.50-4.75	1.30-4.05
j.	DNC to the midline at inferior border of pubic symphysis	9.20-12.75	8.30-12.75

The two population groups are abbreviated in Table 6 as follows: 3= black females, 4= white females. The sample size is indicated by n values.

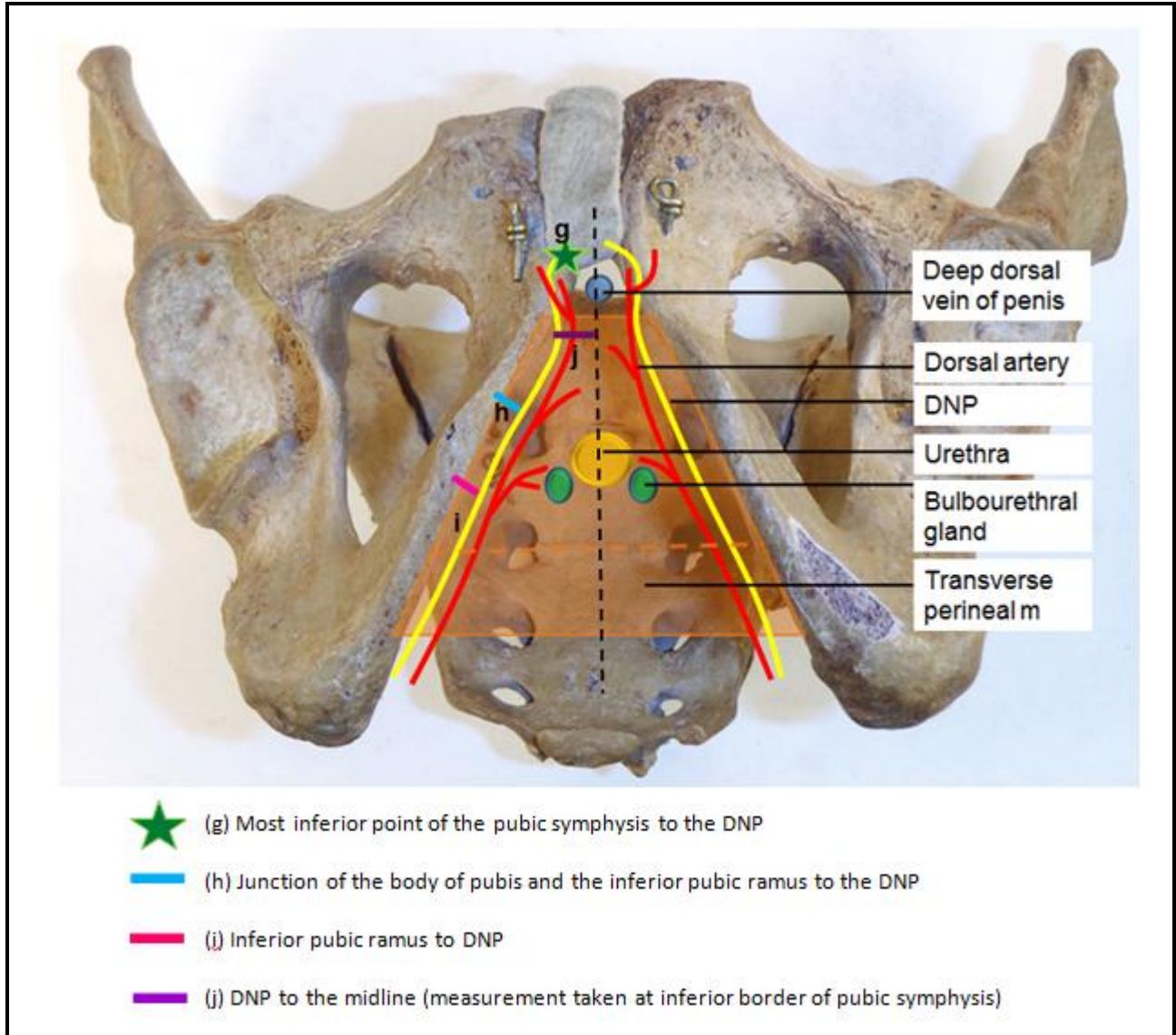


Figure 32: Measurements between landmarks and DNP on a perineal view of the male pelvis

Table 7: Minimum and maximum distances in mm between the DNP and identified landmarks

Measurements taken:		1. (n=27)	2. (n=15)
g.	Most inferior point of pubic symphysis to DNP	0.00-3.40	0.00-4.10
h.	Junction between body of pubis and inferior pubic ramus to DNP	4.03-6.24	2.89-5.75
i.	Inferior pubic ramus to DNP	0.00-4.87	1.05-3.90
j.	DNP to the midline at inferior border of pubic symphysis	7.26-14.46	5.20-14.80
k.	Bulb of penis to perineal nerve (minimum value)	0.00-8.25	0.00-8.70
l.	Bulb of penis to perineal nerve (maximum value)	5.95-15.48	2.53-19.60

The two population groups are abbreviated in Table 7 as follows: 1= black males, 2= white males. The sample size is indicated by n values.

3.2 Predicting safe areas

Safe areas for procedures considered were predicted from the measured distances between the PN and its branches and important landmarks, as well as between landmarks.

3.2.1 Analysis of intergroup variations

The basic descriptive statistics done on the distances between the PN and its branches to the identified landmarks, or between landmarks are summarized in Table 8. The section that follows, emphasises the differences between the four sex-population groups. These factors were expected to influence the prediction of safe areas for the perineal procedures listed.

Table 8: Basic descriptive statistics for distances measured in mm from the PN and its branches to identified landmarks

	Parameter	1. (n=27)	2. (n=15)	3. (n=13)	4. (n=16)	Intersex p-value	Interpo- pulation p-value
a.	Distance between superior sacrospinous ligament attachments	37.11 4.80 (29.35-48.55)	39.69 5.64 (31.45-54.70)	46.21 5.03 (38.80-57.93)	49.69 3.62 (43.45-57.20)	<0.001	0.013
b.	Distance between inferior sacrospinous ligament attachments	46.07 5.18 (33.49-56.60)	46.69 4.53 (40.70-57.80)	52.78 3.90 (46.85-59.85)	57.85 4.83 (48.97-65.30)	<0.001	<0.001
c.	External anal skin to IRN (minimum value)	16.6 3.83 (9.05-24.00)	17.89 3.41 (10.50-23.00)	14.54 5.04 (6.45-20.90)	12.9 5.82 (3.25-24.10)	0.003	0.969
d.	External anal skin to IRN (intermediate value)	20.69 3.48 (15.85-28.90)	20.93 2.73 (15.90-25.10)	17.13 4.57 (7.55-22.45)	17.10 5.91 (8.50-25.50)	<0.001	0.907
e.	External anal skin to IRN (maximum value)	22.13 3.07 (16.55-26.40)	24.45 2.51 (20.80-27.80)	19.79 5.94 (10.50-26.70)	22.09 4.48 (13.24-25.60)	0.067	0.059
f.	Junction between body of pubis and inferior pubic ramus to DNP/C*	5.1 0.66 (4.03-6.24)	4.22 0.68 (2.89-5.75)	3.92 0.76 (2.96-5.86)	3.79 0.61 (2.80-5.42)	<0.001	0.003
g.	Inferior pubic ramus to DNP/C	2.23 1.46 (0-4.87)	2.12 0.78 (1.05-3.90)	1.96 1.05 (0.50-4.75)	2.21 0.84 (1.30-4.05)	0.889	0.550

h.	DNP/C to midline at inferior border of pubic symphysis	10.41 <i>2.09</i> (7.26-14.46)	11.50 <i>2.16</i> (5.2-14.8)	11.22 <i>1.18</i> (9.2-12.75)	10.9 <i>1.18</i> (8.3-2.75)	0.737	0.276
i.	Bulb of the penis to perineal nerve branch (minimum value)	4.47 <i>2.50</i> (0-8.25)	6.28 <i>2.38</i> (0-8.70)	-	-	-	0.028
j.	Bulb of the penis to perineal nerve branch (maximum value)	9.90 <i>2.19</i> (5.95-15.48)	8.88 <i>3.95</i> (2.53-19.60)	-	-	-	0.285
<p>The four sex-population groups are abbreviated in Table 8 as follows: 1= black males, 2= white males, 3= black females, 4= white females. The sample size is indicated by n values. The mean (mm) values are indicated in bold. The standard deviation is indicated in <i>italics</i>, the range is shown within the (round brackets).</p>							
<p>* Indicates an interaction between population and sex groups</p>							

The interaction ($p = 0.026$) between sex and population noted in the distance from the junction of the body of the pubis and the inferior pubic ramus to the DNC/P, is a result of high values for the distance found in black males. The interaction is likely to have affected the significant mean effects of sex and population group.

For some parameters the intrapopulation variation was to such an extent that the standard deviation exceeded the mean value. This could have been caused by the large number of zero values reported in some groups. The distance was recorded as zero where the nerve was found flush against the bony landmark. The following table (Table 9) displays the parameters involved and the proportion of cases where the nerve or its branches were found adjacent to the bony landmark, as opposed to a distance separated from the bony landmark. In cases where it was a distance away, the ranges are reported.

Table 9: Proportion of the PN or its branches adjacent to the bony landmarks versus a distance separated from the bony landmarks

Parameter	1. (n=27)	2. (n=15)	3. (n=13)	4. (n=16)
PN adjacent to ischial spine	22.22% 6/27	66.67% 10/15	7.69% 1/13	62.50% 10/16
PN a distance from the ischial spine	77.78% 21/27 (2.3-7.4)	33.33% 5/15 (1.5-7.4)	92.31% 12/13 (2.24 - 8.4)	37.50% 6/16 (2.73- 5.95)
IRN adjacent to ischial spine	0% 0/15	45.45% 5/11	0% 0/7	18.18% 2/11
IRN a distance from the ischial spine	100% 15/15 (2.3-18.05)	54.54% 6/11 (1.6-8.6)	100% 7/7 (3.05-14.45)	81.82% 9/11 (0.45-12.66)
DNP/C adjacent to most inferior point of the pubic symphysis	25.93% 7/27	13.33% 2/15	69.23% 9/13	93.75% 15/16
DNP/C a distance from the most inferior point of the pubic symphysis	74.07% 20/27 (0.5-3.4)	86.67% 13/15 (0.5-4.1)	30.77% 4/13 (0.5- 3.45)	6.25% 1/16 (2.38)

The four sex-population groups are abbreviated in Table 9 as follows: 1= black males, 2= white males, 3= black females, 4= white females. The sample size is indicated by n values. Ranges for distances measured in mm from the PN and its branches to identified landmarks are indicated in brackets.

In the gluteal region, the PN was often found adjacent to the ischial spine in the white population group (66.67% of white males and 62.5% of white females), and further away in a medial direction from the ischial spine, in the black population group (77.78% of black males and 92.31% of black females). In the cases where the PN and IRN were noted as two separate structures at the level of the ischial spine, both were mostly found a distance from the ischial

spine in all population groups, except in white males, where the nerves were found flush against the bone in 45.45% of cases.

In the perineum, it was noted that the DNC was more commonly found directly adjacent to the inferior border of the pubic symphysis (69.23% of black females and 93.75% of white females). A space was noticed between the inferior border of the pubic symphysis and the DNP in males. In 74.07% of black males and 86.67% of white males, a fat pad was observed between the DNP and the pubic symphysis.

An integrative analysis of the abovementioned findings was made in the comparisons between population groups (represented in Table 10) and sex groups (represented in Table 11).

Five of the ten measurements were significantly different in the black population group when compared to the white population group. These five measurements are presented in Table 10.

Table 10: Comparison between the different population groups of the proximity of the PN and its branches to identified landmarks or between landmarks	
Measurements taken:	In black South Africans as opposed to white South Africans:
Distance between the superior attachments of the sacrospinous ligament	Shorter distance, thus a shorter sacrospinous ligament
Distance between the inferior attachments of the sacrospinous ligament	Shorter distance, thus a shorter sacrospinous ligament
External anal skin to IRN maximum value	Black males: more superficial compared to white males Black females: deeper compared to white females
Junction between body of pubis and inferior pubic ramus to DNP/C	Further away/more medially situated
Bulb of the penis to perineal nerve branch (minimum value)	Closer situated to the bulb of the penis

Thus, the sacrospinous ligament was significantly shorter in the black population group. The most superficial sphincteric branches were found more superficial in black males, compared to white males, but deeper in black females, compared to white females. In the perineum, the DNP/C was situated more medially and further away from bony landmarks compared to the white population group. The perineal nerve branches were also found closer to the bulb of the penis in the black population group.

In the comparison between sexes, six of the eight measurements were significantly different in females when compared to males. These six measurements are presented in Table 11.

Table 11: Comparison between the sexes of the proximity of the PN and its branches to identified landmarks or between landmarks	
Measurements taken:	In females as opposed to males:
Distance between the superior attachments of the sacrospinous ligament	Longer distance, thus a longer sacrospinous ligament
Distance between the inferior attachments of the sacrospinous ligament	Longer distance, thus a longer sacrospinous ligament
External anal skin to IRN (minimum value)	More superficial
External anal skin to IRN (intermediate value)	More superficial
Most inferior point of pubic symphysis to DNP/C	Closer related
Junction between body of pubis and inferior pubic ramus to DNP/C	Closer related/ more lateral

Thus, the sacrospinous ligament is longer in females, especially in the white population group. The branches of the IRN are more superficial and can be damaged more easily in females compared to males, especially in white individuals. The DNC is more closely related to the junction of the body of the pubis and the inferior pubic ramus, as well as the inferior border of the pubic symphysis in females. This might be a site of PN entrapment in females, especially in the white population group.

3.2.2 Predicting safe areas for perineal procedures

On the basis of the abovementioned findings regarding the variations in the course and branches of the PN and their distances from important landmarks, safe areas for perineal procedures were predicted.

3.2.2.1 Richter's procedure

During the Richter's procedure, a stitch is placed 20 mm medial to the ischial spine into the sacrospinous ligament to repair vaginal vault prolapse.

The results showed that the sacrospinous ligament was significantly shorter in black females when compared to white females. The PN and IRN were more often located more medially to the ischial spine, especially in black females, instead of posterior to the ischial spine, as more commonly seen in white females. It was also found that in the black female group, the IRN entered the gluteal region as a separate structure in almost 39% of cases. Branches of the PN entered the region at the superior border of the sacrospinous ligament in almost 54% of cases. Resulting from this proximal branching pattern, the IRN as well as the PN were almost always (92.3%) located medial to the ischial spine. Therefore, these structures encroached more into the shortened area available for the placement of the stitch in black females. When this procedure is performed on black females, the stitch should be placed further than 20 mm away from the ischial spine to stay clear of the PN and /or IRN.

3.2.2.2 Tension-free vaginal tape (TVT)

During the TVT procedure, two trocar needles are used to introduce a polypropylene sling under the mid-urethra. The trocars pass from a vaginal entry point, 1.5 cm inferior to the mid-urethra, through the retropubic space to exit through two suprapubic incisions.

A significant difference was found between population groups when the distance between the junction of the body of the pubis and inferior pubic ramus to the DNC was compared. The DNC was found more medial, and thus further away from this junction in the black female group, where they might be at risk during superficial mesh tape placement. On the other hand, when inserting the TVT tape, surgeons should avoid pushing the trocar needles too deep, as the perineal branches are found just below the levator ani muscle. The tape should thus be placed just lateral/closer to the urethra, and not too superficial, to avoid damage to the DNC. To avoid damage to the perineal nerve branches, the tape should neither be placed too deep.

3.2.2.3 Transobturator Tape: outside-in (TOT) and inside-out (TVT-O) in females

During the TVT-O and TOT transobturator tape procedures, a curved needle/trocar passes around the inferior pubic ramus, to exit either in the genitofemoral fold (inside-out), or via an incision made in the vaginal wall at the level of the mid-urethra (outside-in). It was found that

the DNC was very closely related, or postero-inferior to the junction of the body of the pubis and the inferior pubic ramus. It might be damaged during these procedures, should the trocar be introduced too close to the bone, scratching it during its trajectory.

During the TOT (outside-in) procedure, the DNC might be more easily damaged in obese patients, as was noted in white individuals, because of the standard size and curve of the trocar needle. Surgeons might over compensate when the procedure is performed on obese patients, by exiting the needle closer to the inferior pubic ramus, where it could damage the DNC. In white females, the DNC was situated closer to the bony framework, thereby putting this nerve at risk even more. The risk of damaging the nerve is therefore predicted to be greater when this relation to the bony framework is associated with obesity.

During the performance of the TVT-O (inside-out) procedure, the DNC, which is situated close to the inferior pubic ramus, might be at risk in both groups if the inferior pubic ramus is scraped to ensure correct exit of the trocar needle.

3.2.2.4 Transobturator Tape (outside-in and inside-out) in males

During the outside-in procedure, the inferior pubic ramus is palpated, and a skin incision is made just lateral to it. The trocar is advanced under manual guidance through the obturator foramen from outside, to exit lateral to the bulb of the penis. The DNC can be damaged during the guidance of the trocar through the retropubic space.

In black males especially, where the DNC is situated further from the bony frame, the DNC might be more at risk during the outside-in procedure, as less control can be applied over the course of the trocar needle as it passes blindly through the retropubic space. On the other hand, when the trocar needle passes too close to the medial border of the inferior pubic ramus, the DNC may be entrapped by the sling as it is 'hugging' the inferior pubic ramus.

In individuals with a higher BMI, the needle may exit closer to the medial border of the inferior pubic ramus than intended, or even scrape it, to compensate for the standardized size and

curve of the trocar needle. The DNP might therefore be at risk during the insertion of the needle, as well as the tensioning process of the obturator arms.

During the inside-out procedure an incision is made 1.5 cm below the triangular junction of the corpus cavernosum and corpus spongiosum, as entry point for the trocar needle. The trocar follows a blind passage through the obturator membrane to exit in the genitofemoral fold. In males, the DNP is situated a few millimetres more medial to the junction of the body of the pubis and inferior pubic ramus and runs posterior to the ischiocavernosus muscle as it ascends to the inferior border of the pubic symphysis. The same theory applies as in the TVT-O procedure in females. The DNP might be more at risk in individuals where the DNP is situated closer to the junction of the body of the pubis and the inferior pubic ramus, as is more commonly seen in the white male group.

3.2.2.5 Pudendal nerve block

The PN can be blocked by the injection of local anaesthetic bilaterally, proximal to its terminal branches at the pudendal canal.

During this procedure the different branching patterns of the PN should be taken into account. The IRN entered the gluteal region as a separate structure in 38.46% of cases in the black female group and in 92.31% of these cases, the PN and the IRN was found medial to the ischial spine, compared to only 37.5% of cases in the white female group. To ensure that both terminal branches are anaesthetized in the black female group, the anaesthetic should be injected more medial and proximal to the ischial spine as the PN crosses over the sacrospinous ligament, medial to the ischial spine.

3.2.2.6 Anorectal (Ischioanal) abscess and anal fistula drainage

Perineal and anorectal abscesses are drained through a cruciate incision at the site of maximal swelling. The ischioanal fossa is then probed with a haemostat or finger to disrupt loculations and to facilitate drainage. The IRN crosses through the lateral third of the ischioanal fossa and then splits into three to five terminal branches which supply the external anal sphincter. To protect these terminal branches, the cruciate incision should not be made too deep. Faecal

incontinence may occur after fistula drainage operations, due to injury to these sphincteric branches.

It was found that there was a significant difference in the depth of the terminal branches of the IRN in males and females. The sphincteric branches lie most superficial in white females and also more superficial in black females than in all males. The minimum distance between the external anal skin and the most superficial branch in females ranged between 3.25 – 6.45 mm, where in males, it ranged between 9.05 – 10.5 mm. According to these findings, the safety margin for the depth of the cruciate incision was very narrow, but increased when the procedure was performed on males, especially white males.

3.2.2.7 Dorsal penile nerve block

During the dorsal penile nerve block procedure, local anaesthetic is injected at the 10-o'clock and 2-o'clock (superolateral to the midline of the root of the penis) areas, which are the points distal to the penile root where infiltration is needed.

No significant difference was found between the distances from the DNP to the midline at the level of the inferior border of the pubic symphysis in different population groups. The mean distance between the DNP and the midline ranged between 10.41 mm and 11.5 mm in adult males. The safe zone for both black and white adult males is thus the same.

3.3 Perineal procedures performed

Once the tape procedures were completed on the fresh cadavers, they were embalmed. The PN and its branches were dissected at least a month after embalming. Distances were measured between the various branches of the PN and the mesh tape or sutures placed. These measurements regarding the performed procedures were used to verify the safe areas predicted before. The cBMI (cadaveric body mass index) was also determined, and correlations between a high cBMI and findings regarding the PN and its branches were established. For this purpose, the sample group was divided into three groups. Cadavers with a cBMI ranging from $\leq 18.5 - 1.5 \text{ kg/m}^2$ were grouped together in the low to normal cBMI group, the cadavers with a cBMI ranging from 21.5 to 25.5 kg/m^2 were grouped together in a normal to high cBMI group, and those with a cBMI exceeding 25.5 kg/m^2 were grouped together in the high cBMI to obese group. Table 12 contains the exact distances measured during the dissections. The limited number of individuals involved in each procedure precluded tests for statistical significance. Predictions were therefore based on mean values or impressions of individual measurements in a group.

Table 12: Cadaver BMI and distances (in mm) between the PN or its branches to the tape/suture amongst various procedures in females

Sex-Population groups		cBMI	Procedures done:				
			TOT to DNC (n=9)	TVT to DNC (n=5)	TVT-O to DNC (n=7)	PN to stitch (n=9)	IRN to stitch (n=5)
1.	White female	22.97			7		
2.	White female	16.69			16.1	19.41	11.93
3.	White female	32.25*		>30	22.8		
4.	White female	21.83		21.9	19.1	6.85	
5.	White female	17.12		>30	20.4	9.61	3.05
6.	White female	22.44	4.9	>30			
7.	White female	21.68		15.7	20.4		
8.	White female	25.65*	7.4				
9.	White female	17.19	20.1		18.9	13	6.5
10.	White female	24.57	21.5			23.5	
11.	White female	15.81	7.1			4.1	
12.	White female	23.09	23.4	22.4		18.1	17.8
13.	Black female	18.68	22.9			15.7	
14.	Black female	15.38	15.2			6.9	0
15.	Black female	21.63	7.6				
Basic statistical analysis for procedures			14.46 <i>7.71</i> (4.9-23.4)	20.0** <i>3.73</i> (15.7-22.4)	17.81 <i>5.18</i> (7.0-22.8)	13.02 <i>6.62</i> (4.1-23.5)	7.86 <i>7.02</i> (0-17.8)

A cBMI $\geq 25.5\text{kg/m}^2$ is indicated by a * (high cBMI to obese group). The sample size is indicated by the n value. The mean (mm) values are indicated in **bold**. The standard deviation is indicated in *italics*, the range is shown within brackets. ** excludes distances greater than 30 mm.

Table 13: Cadaver BMI classification and mean distances (in mm) for procedures in females					
Procedure →	TOT to DNC	TVT to DNC	TVT-O to DNC	PN to stitch	IRN to stitch
BMI (kg/m ²) ↓	(n=9)	(n=5)	(n=7)	(n=9)	(n=5)
Low –normal cBMI	16.33	>30	18.47	11.45	5.12
Normal – high cBMI	14.35	>22.5	15.93	16.15	17.8
High cBMI to obese	7.4	>30	22.8	-	-

3.3.1 Female tape procedures

It was noted that on average, the white female group presented with a higher cBMI than the black female group. The distances between the position of the tape inserted and the PN and its branches are tabulated above. The figures below illustrate the distance between the DNC and the various tapes inserted or the Richter's stitch placed. The distances measured for each procedure are represented the following figures and corresponding column graphs.

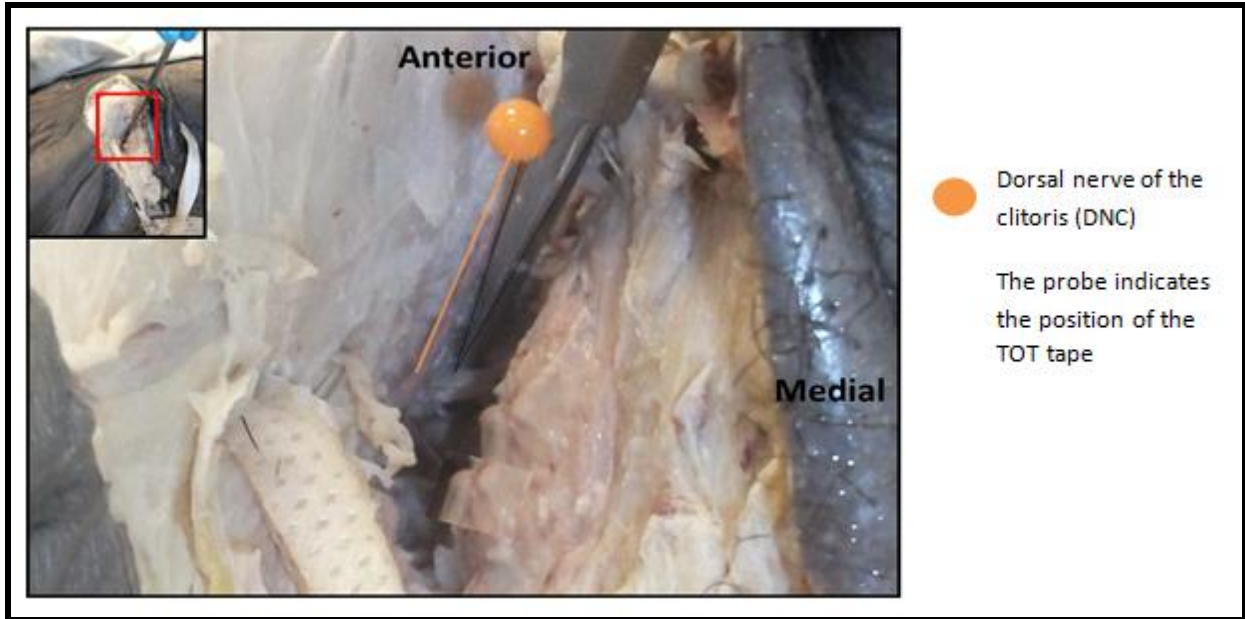


Figure 33: Distance between the DNC and the TOT tape (white) in females

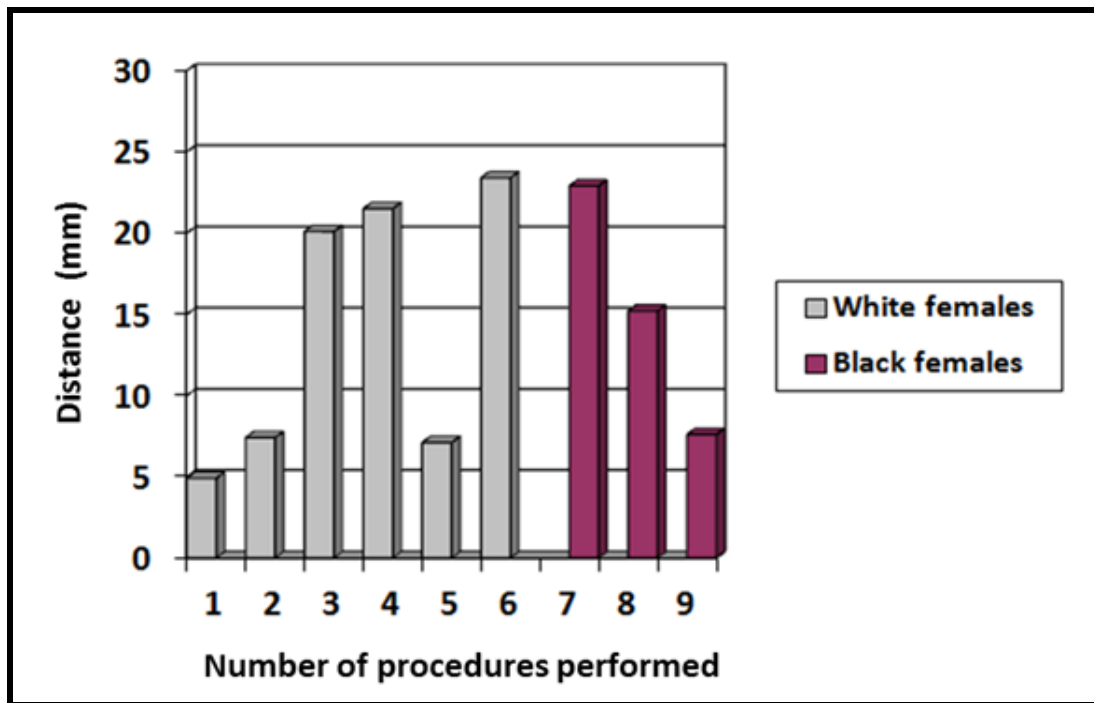


Figure 34: Distances from the DNC to the TOT tape

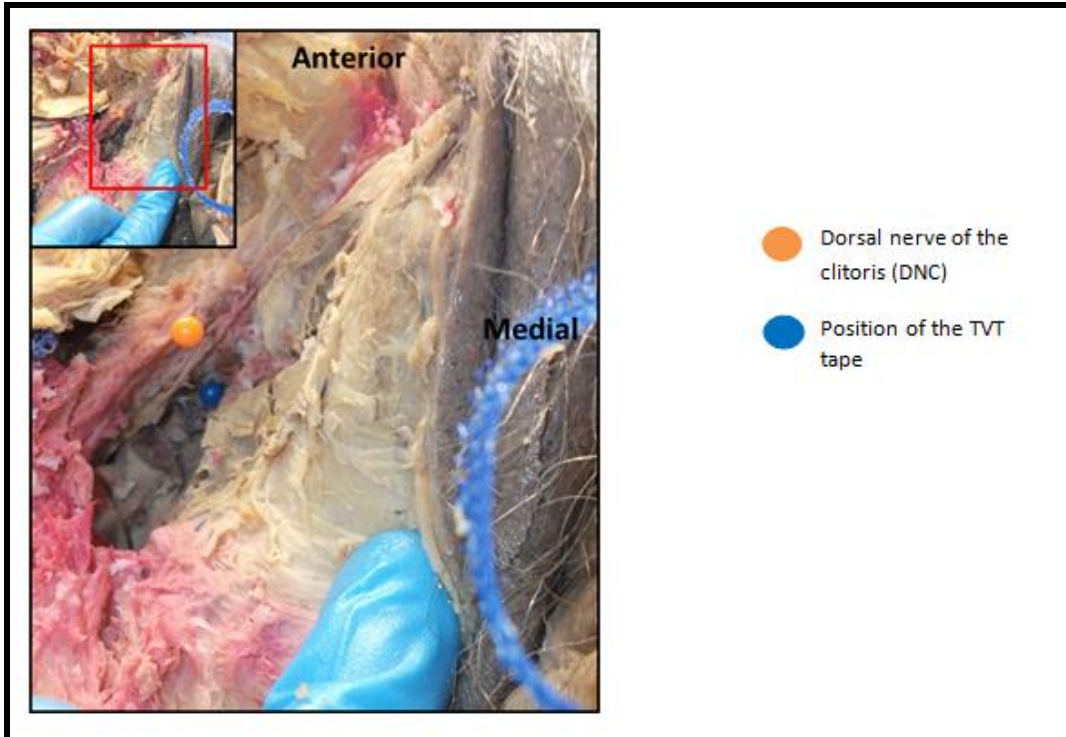


Figure 35: Distance between the DNC and the TVT tape (blue)

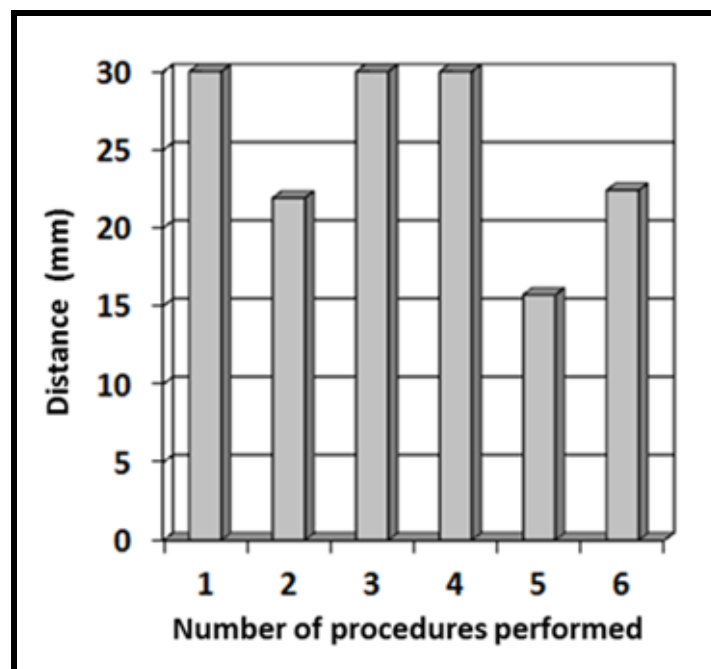


Figure 36: Distances from the DNC to the TVT tape in white females

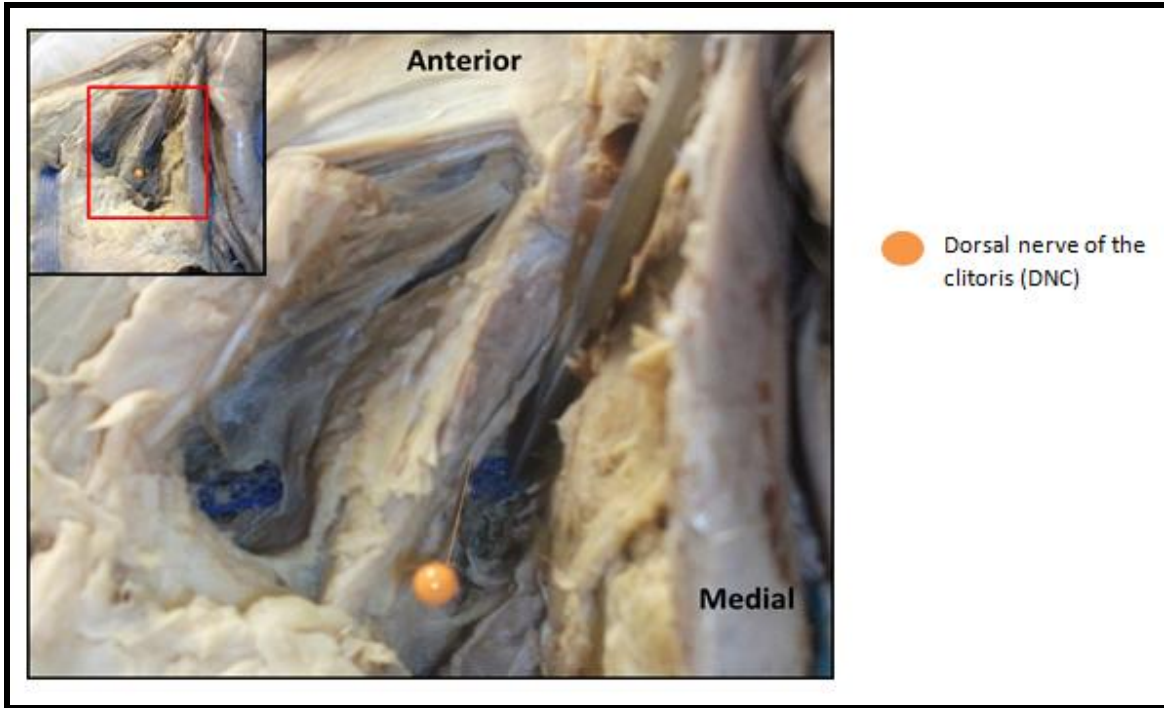


Figure 37: Distance between the DNC and the TVT-O tape (blue)

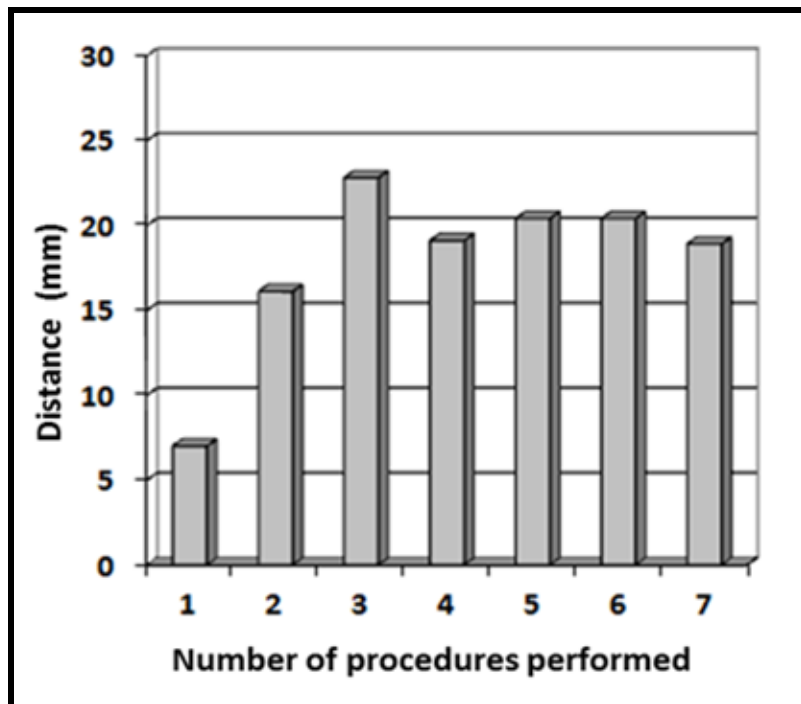


Figure 38: Distances from the DNC to the TVT-O in white females

It was evident that the TOT tape (outside-in) was often closer to the DNC than the other tapes placed. This might be due to a closer trajectory of the needle around the inferior pubic ramus, even though passage of the TOT tape (outside-in) is guided through the dissected tunnel, in contrast to the TVT-O (inside-out) where the needle travels through a blind passage to exit in the genitofemoral fold.

In all female cadavers on whom the TVT procedure was performed, the trocar needle passed very deep to the DNC and thereby keeping a safe distance from it. Deeper dissections to determine the distance from the TVT tape to perineal branches deep to the levator ani muscle were not executed.

3.3.2 Richter's procedure

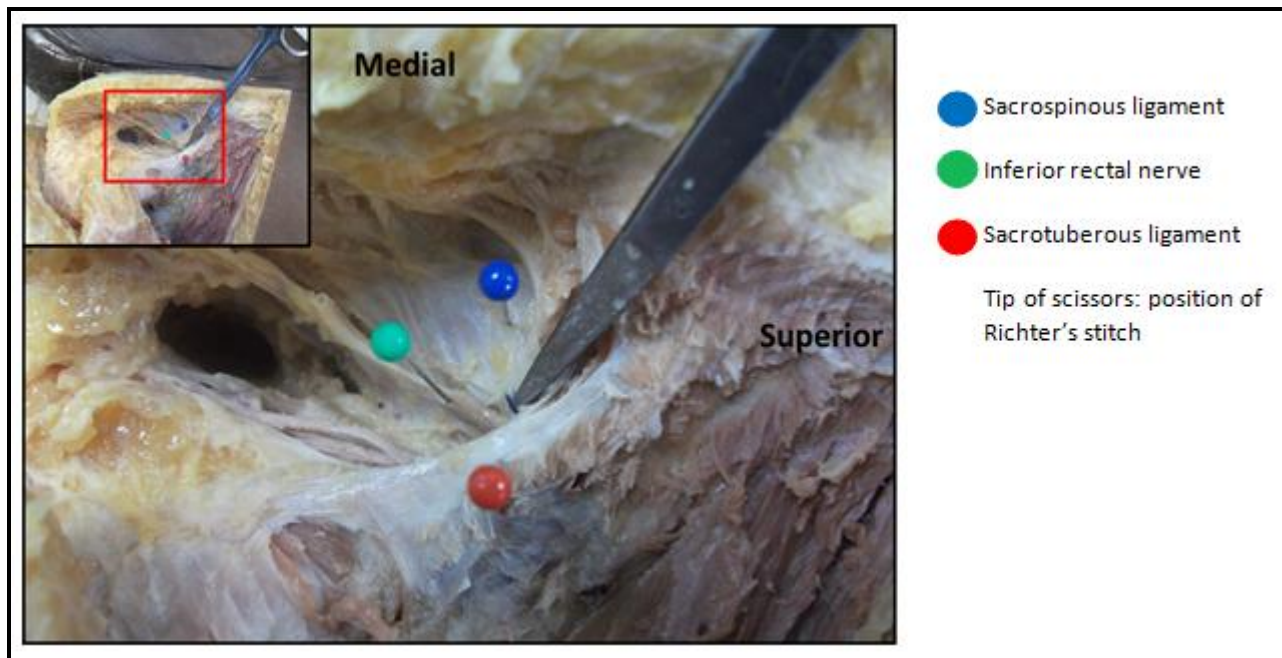


Figure 39: The position of the Richter's stitch

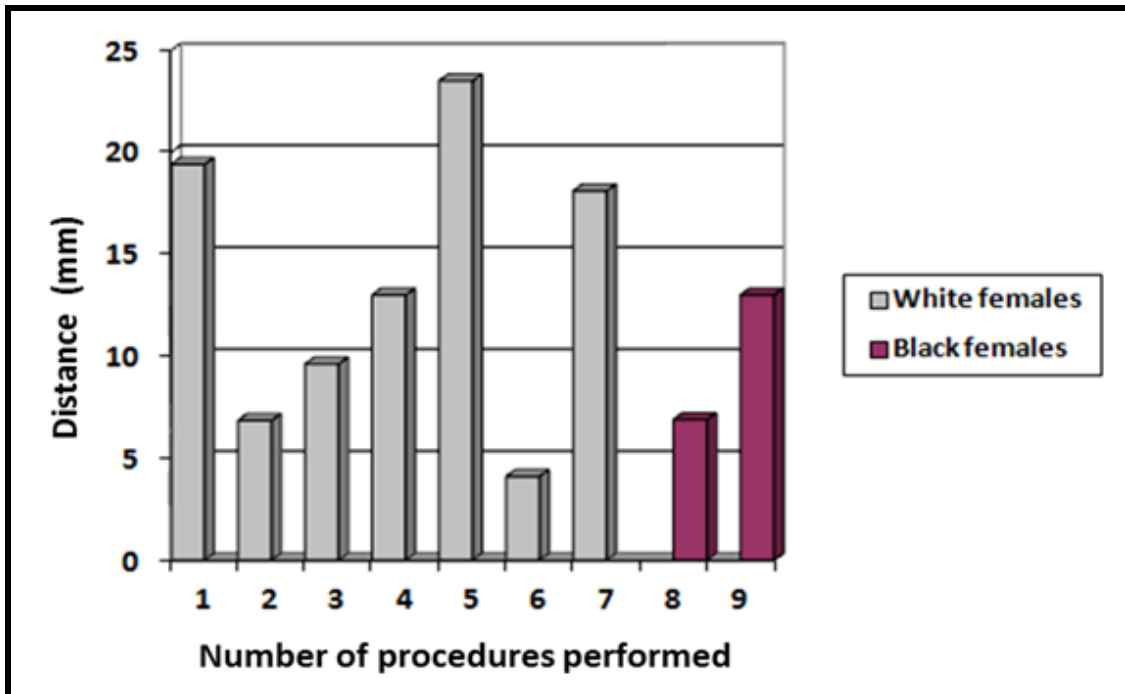


Figure 40: Distances from the PN to the Richter's stitch

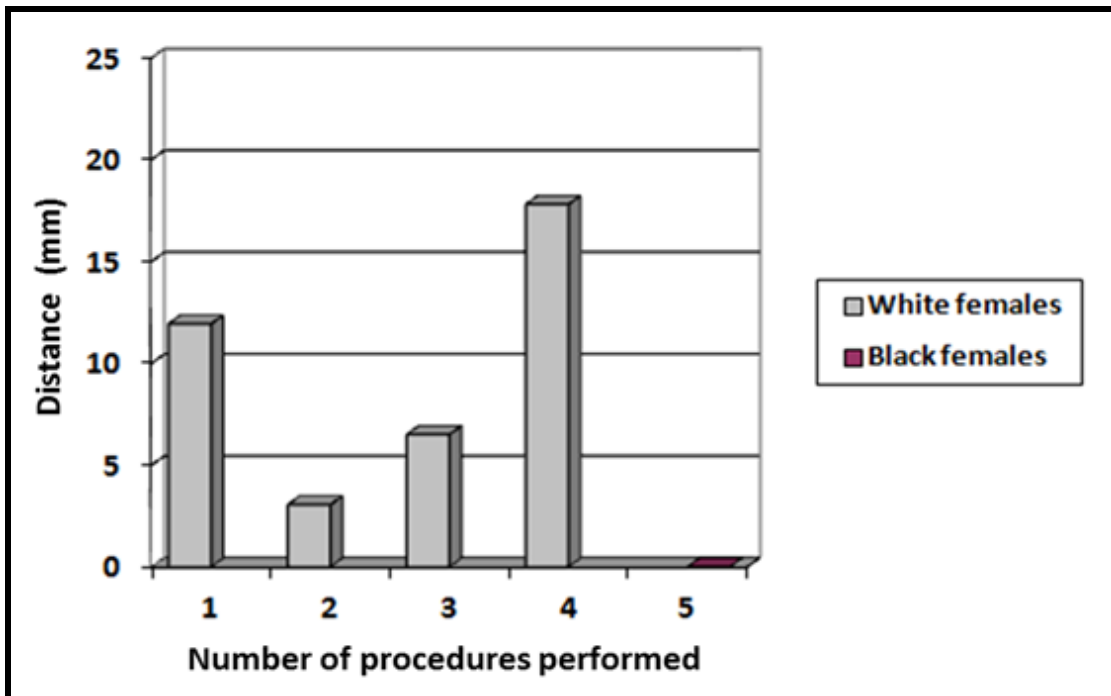


Figure 41: Distances from the IRN to the Richter's stitch

It was seen that in black females, the stitch placed during the Richter's procedure was often closer to the PN and IRN than in the procedures performed on white females. In one of the black females, the Richter's stitch was placed through the IRN.

3.3.3 Male tape procedures

It was noted that on average, the white males presented with a higher cBMI than the black males. The cBMI ranged between 15.43 – 19.86 kg/m² in black males and 18.08 – 30.79 kg/m² in white males. In white males, and in those with a higher cBMI, a greater distance between the DNP and the obturator arm was noted. The following table, Table 11, indicates the differences between the proximity of the DNP and perineal nerve to various parts of the TOT tape.

Table 14: Cadaver BMI and the distances (in mm) between the branches of the PN to the four arms of the TOT tape in males

Sex-Population groups:		cBMI	Parameters:				
			Perineal nerve (branch #1) to tape (n=15)	Perineal nerve (branch #2) to tape (n=10)	DNP to the prepubic arm (n=8)	DNP to obturator arm (n=15)	Spermatic cord to prepubic arm (n=9)
1.	White male	18.08	0			8.1	
2.	White male	22.43	0			3.4	3.1
3.	White male	25.05*	0			0	3.7
4.	White male	20.49	0		9.1	0	2.6
5.	White male	30.79*	0		5.5	4.1	
6.	White male	28.47*	0	4.1		2.1	7
7.	White male	24.75	0	1.5	16.5	0	0
8.	White male	23.53	4.2	7.1	13.5	3.3	8.4
9.	Black male	19.86	0	0	6.1	0	
10.	Black male	22.3	0	2.3	16.1	0	
11.	Black male	16.37	1.9	4.5		0	
12.	Black male	15.43	0	3.8		0	
13.	Black male	19.81	0	3.4		3.9	0
14.	Black male	17.58	0	0	11.9	0	2
15.	Black male	15.77	0	2.5	6.8	0	12.5
Basic statistical analysis for procedures			0.41 <i>1.16</i> (0-4.2)	2.96 <i>2.16</i> (0-7.1)	10.69 <i>4.44</i> (5.5-16.5)	1.66 <i>2.44</i> (0-8.1)	4.37 <i>4.16</i> (0-12.5)
High cBMI is indicated with a *. The sample size is indicated by the n value. The mean (mm) values are indicated in bold . The standard deviation is indicated in <i>italics</i> . The range is shown within the brackets.							

Table 15: Cadaver BMI classification and mean distances (in mm) for procedures in males					
Procedure → cBMI (kg/m ²) ↓	Perineal nerve (branch #1) to tape (n=15)	Perineal nerve (branch #2) to tape (n=10)	DNP to the prepubic arm (n=8)	DNP to obturator arm (n=15)	Spermatic cord to prepubic arm (n=9)
Low – normal cBMI (<18.5-21.5)	0.24	1.95	8.48	1.5	4.28
Normal – high cBMI (21.5-25.5)	0.84	3.63	15.37	1.34	5.07
High cBMI to obese (>25.5)	0	4.1	5.5	3.1	7

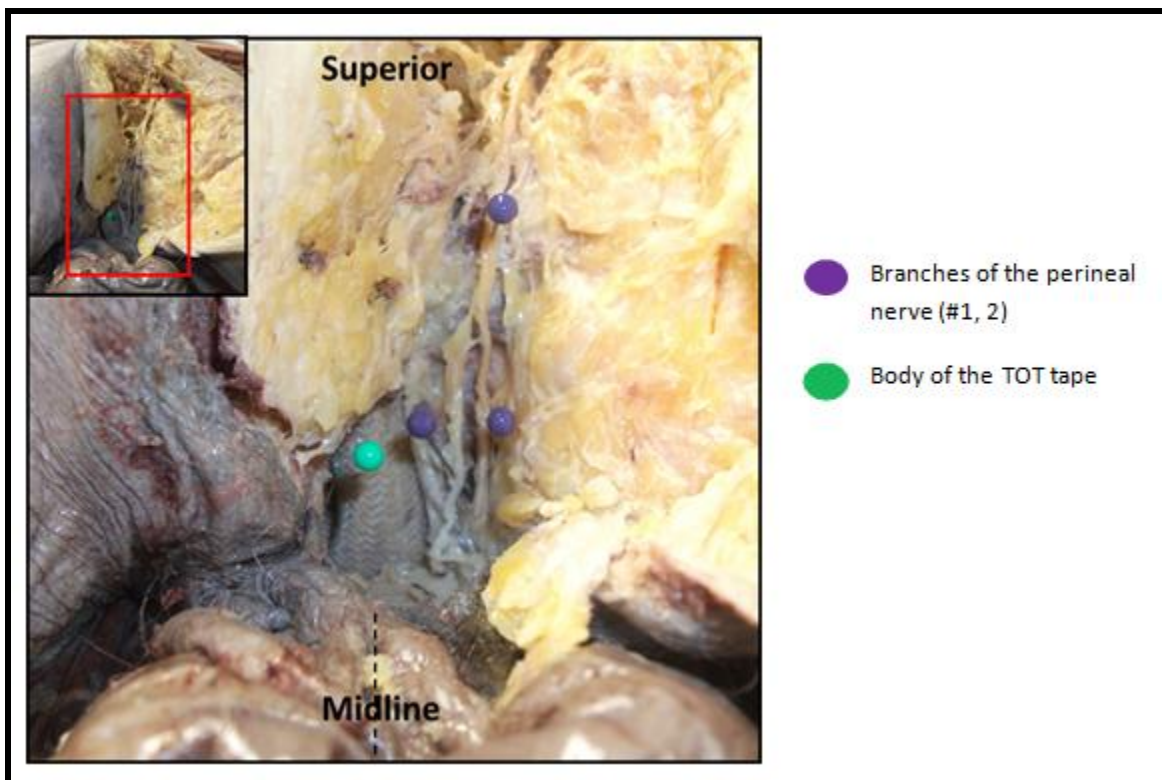


Figure 42: Distance between the perineal branches and the body of the TOT tape (white)

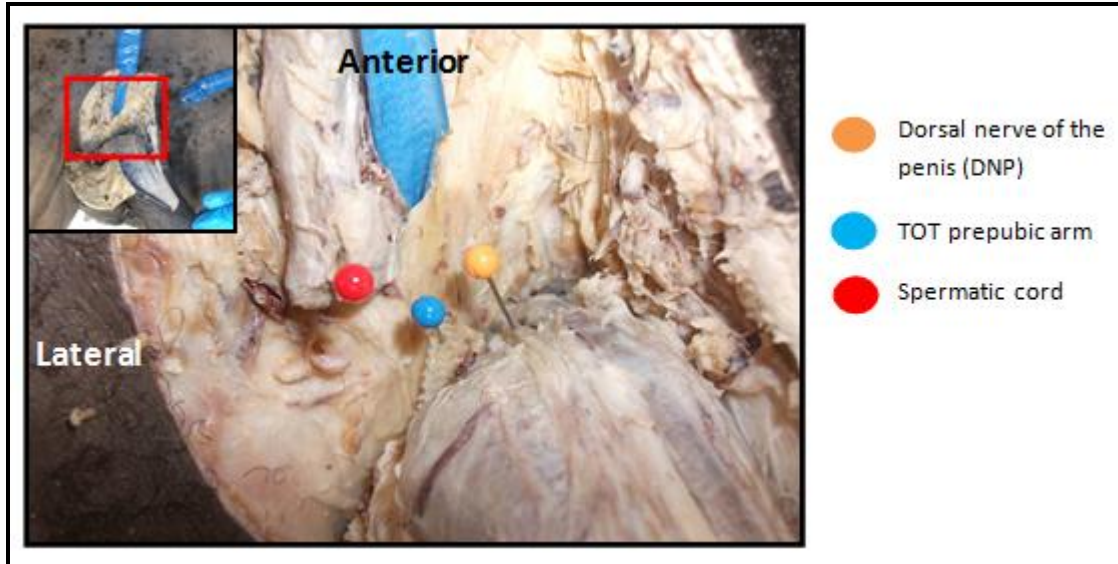


Figure 43: Distance between the DNP and the prepubic arms of the TOT tape (white mesh)

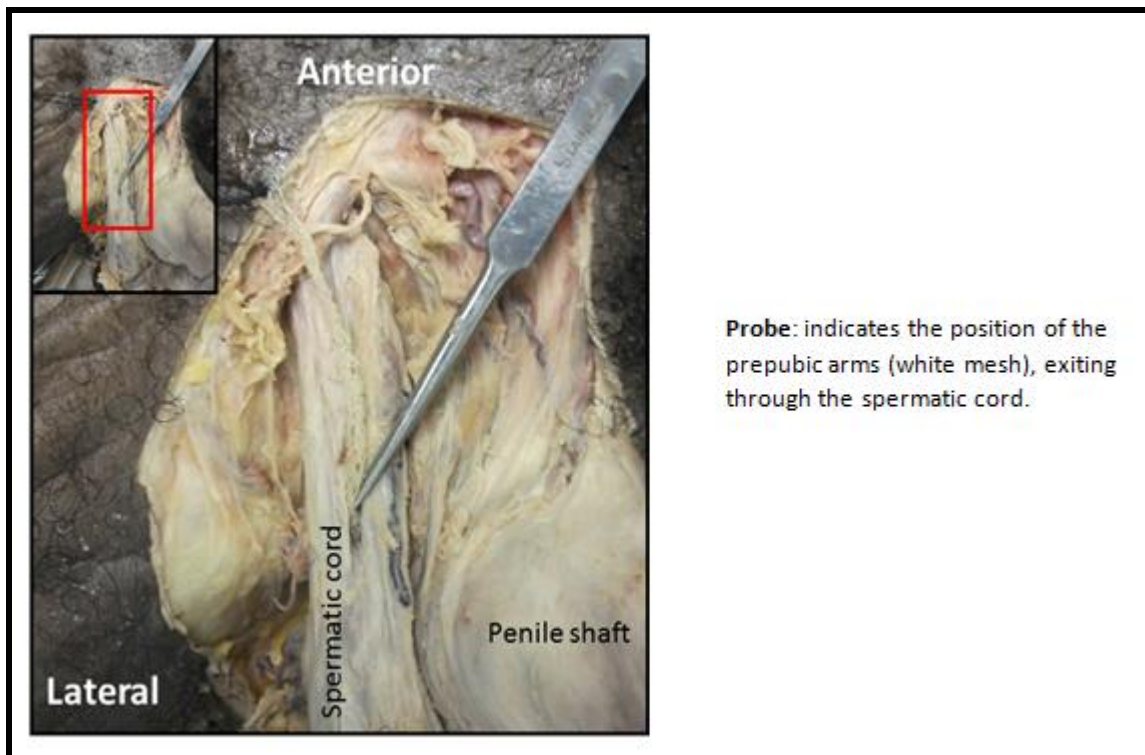


Figure 44: Prepubic arm exiting through the spermatic cord

It was noted that the prepubic arms exited just medial to the spermatic cord in nine cases and in two of these cases, it pierced the spermatic cord (Fig. 44). The average distance between the medial border of the spermatic cord and the prepubic arms was 4.37 mm.

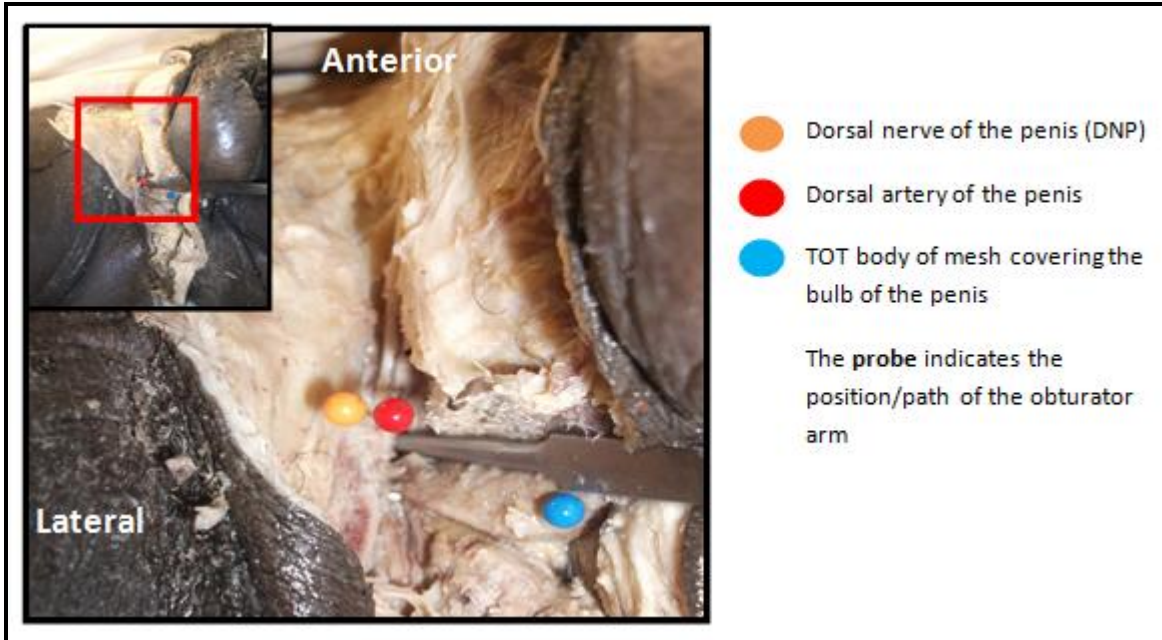


Figure 45: Anterior perineal view indicating the distance between the DNP and the obturator arm of the TOT tape (white mesh)

In some cadavers the DNP was found adjacent to the tape. In these cases, the tape was “hugging” the inferior pubic ramus and thereby compressing the DNP against the bone. It was clear that the obturator arm was closer to the DNP in the black male population group (with an average distance of 0.56 mm) than in the white population group (with an average distance of 2.63 mm).

In most cases, the widest part of the transobturator tape was covering the perineal branches coursing alongside, or crossing over the bulb of the penis. The branches of the perineal nerve may be entrapped or damaged during the tensioning process in which the mobilised urethra is retracted posteriorly by the obturator arms, and flattened by tensioning the prepubic arms.

Chapter 4: Discussion

4.1 Pudendal nerve dissection and measurements

In perineal surgery, knowledge of the anatomy of the pudendal nerve (PN), more specifically its course, branches and variations, is of great importance to avoid complications. As many conflicting terminologies and descriptions of the course of the PN in various population groups have been described, even in recent publications, the aim of the first part of the study was to describe the course and anatomy of the PN and its branches in South African population groups.

Table 16 summarizes the variations described by various other authors. Population groups and sample sizes are mentioned as it may have a substantial effect on results found.

Table 16: Variations of the PN and IRN in the researched literature compared to the current study

Study	Population	PN variations	IRN variations
This study, 2013	South Africa BF: 13; WF: 16 BM: 27 WM:15	Mostly medial to IS in black individuals:BF (92.31%) and BM (77.78%) and mostly posterior to IS in white individuals: WF (62.5%); WM (66.67%)	Separate gluteal entry: BF (38.46%); WF (6.25%); BM (29.63%) and WM: none
Pirro <i>et al.</i> , 2009 ¹⁰⁶	France M: 20	More than 2 trunks: 27.5% 80% medial to IS; 15% posterior to IS; 5% both (multiple trunks)	12.5% separate gluteal entry
Lazarou <i>et al.</i> 2008 ¹⁰⁷	New York F:15	80% medial to IS 20% posterior to IS	40% separate gluteal entry (1.9 ±0.7cm medial to IS)
Achtari <i>et al.</i> , 2006 ⁴³	Australia F: 10		10% separate gluteal entry
Mahakkanukrauh <i>et al.</i> , 2005 ¹⁹	Thailand F: 16 M: 21	More than 2 trunks: 33.3 %	20.5% separate gluteal entry IRN piercing SSL:11%; IRN not piercing SSL: 9.5%
Schraffordt <i>et al.</i> , 2004 ¹	Australia F: 16 M:13	Majority medial to IS	3.6% separate gluteal entry accessory IRN: F (25%); M (6.3%); accessory perineal nerves: F (37.5%); M (38.5%)
Sagsoz <i>et al.</i> , 2002 ²⁸	Turkey F:9	66.6% posterior to IS 33.4% medial to IS (1.48 ±2.29mm)	
Gruber <i>et al.</i> , 2001 ¹⁰⁸	Austria F:29; M:29	More than 2 trunks: 40.5% PN was found 13.4mm medial to 7.4 mm lateral to IS	4.3% pierce sacrotuberous ligament before terminating at the external anal sphincter
Shafik & Doss, 1999 ²⁴	Egypt Adults and Neonates F: 7; M: 5		Emerge from the medial wall of the pudendal canal in all cases
Robert <i>et al.</i> , 1998 ²⁰	France F:6;M:6	Majority medial to IS unless IS elongated	% separate gluteal entry not stated
Verdeja <i>et al.</i> , 1995 ²⁹	Louisiana F: 24	Mean distance from IS: 24.0mm medial to IS	
Shafik <i>et al.</i> , 1995 ¹⁷	Egypt Adults F: 7; M: 3 Neonates F: 6; M: 4	All posterior to the SSL and medial to the IS	20% separate gluteal entry Accessory IRN: ALL males, no females
BF: Black female, WF: White female, BM: Black male, WM: White male, F: Female, M: Male, Trunks: Separate trunks of the PN/IRN in gluteal region, SSL: Sacrospinous ligament, IS: Ischial spine			

Separate entry of the IRN into the gluteal region is not uncommon and varies between populations and studies done. The results of this study show that the inferior rectal nerve (IRN) entered as a separate structure in 29.63% of black males and 38.46% of black females. This branching pattern was observed in only 6.25% of white females and in no white males. The separate entry of the IRN into the gluteal region was also described by Mahakkanukrauh *et al.* on Asian cadavers, where the IRN entered the gluteal region in 20.5% of cases and Shafik *et al.* on Egyptian cadavers, where the IRN entered the gluteal region in 20 % of cases .^{17,19}

Lazarou *et al.* reported separate entry of the IRN in 40% of cases in their dissections of 15 female cadavers¹⁰⁷, which were more in line with the South African black female group presenting with 38.46%. This percentage was often higher compared to others e.g. white females in the current study, and in only one of the ten females studied by Ahtari *et al.*, from Australia.⁴³ On the other hand, the studies did not report a complete absence of a separate entry of the IRN as seen in the South African white male group.

Gruber *et al.* found pudendal nerves with multiple trunks crossing over the sacrospinous ligament. It was not clear whether these trunks represented a separate IRN which did not branch from the PN. This study was performed on 58 Austrian cadavers and in 8.6% (5 cases), an accessory IRN was found piercing the sacrotuberous ligament and terminating at the external anal sphincter.¹⁰⁸ An accessory IRN was noted in 17.9% of cases in an Australian study performed by Schraffordt *et al.*¹ No study could be found that was performed on a sub-Saharan African population group to compare these results to.

Montoya *et al.* performed detailed dissections on four embalmed and 14 unembalmed females in Texas. Separate entry of the IRN into the gluteal region was not reported, but in 44.4% of the dissections, the IRN arose from the PN before it entered the pudendal canal. It was not stated whether the IRN was given off at the superior or inferior border of the sacrospinous ligament.⁵¹ In this study it was found that the IRN was given off at the superior border of the sacrospinous ligament in 55.56% of black males, 53.85% of black females, 73.33% of white males and 68.75% of white females.

The PN and/or IRN passed between the sacrotuberous ligament and crossed over the sacrospinous ligament, where it was found significantly further away (medial) from the ischial spine in the black population group as reflected in the majority of cases in the researched literature presented in Table 16.^{1,17,28,106} Gruber *et al.* and Sagsoz *et al.*, also found the PN mostly medial to the ischial spine, but did report positions between 13.4 mm medial to 7.4 mm lateral (posterior) to the ischial spine and 1.48 ± 2.29 mm medial to the ischial spine respectively.^{28,108} The PN was found posterior to the ischial spine in 66.67% of white males and 62.5% of white females in the current study study.

In cases where the IRN did not enter the gluteal region as a separate structure, it branched from the PN at the superior border or the inferior border of the sacrospinous ligament. In the current study it was never found that the IRN branched from the PN in the pudendal canal as described by Shafik and Doss, who had a sample group of six adult and six neonatal cadavers.²⁴ The age difference between the studied groups may explain the lack of similarity between the different studies. An accessory IRN was noted in this study as it branched from the perineal nerve. An accessory IRN was also noted by Shafik *et al.*¹⁷

The length of the sacrospinous ligament varied significantly between sex-population groups. The sacrospinous ligament was significantly longer in white individuals, especially in white females. Verdeja *et al.*²⁹ measured the distance from the ischial spine to the medial border of the sacrum in 24 American females to determine the length of the midline of the sacrospinous ligament. The average midline width of 54.2mm corresponded with a distance between that of the mean inferior border (49.69 mm) and mean superior border (57.85mm) in white females. The distance between the mean inferior border (46.21 mm) and mean superior border (52.78 mm) in black females were significantly shorter than what was found by Verdeja *et al.*

An average length of 43.04 mm at the midline of the sacrospinous ligament of nine Turkish females, determined by Sagsoz *et al.*²⁸, was much shorter than the averages found in the South African sex-population groups.

After crossing over the inferior border of the sacrospinous ligament, the PN entered the pudendal canal. Just after entry, the PN split into its two terminal branches, the dorsal nerve of the clitoris/penis (DNC/P) and the larger, more superficial branch, the perineal nerve. The DNC/P travelled in the deep perineal pouch to enter the perineum postero-medial to the inferior pubic ramus. It was found 10.41 - 11.5 mm from the midline in females. In males, the DNC/P was found closer to the inferior pubic ramus and thus further from the midline. Ahtari *et al.* studied the course of the DNC in ten Australian females and found that the DNC crosses under the pubic bone at a distance of about 14 ± 5 mm from the midline.⁴³

The perineal nerve divided into a superficial and deep branch. The superficial perineal nerves in males ran in close proximity to the bulb of the penis. The perineal nerve supplied the posterior scrotal/labial skin. The deep perineal nerve supplied all the perineal muscles.

4.2 Predicting safe areas

In the second part of the study, safe areas for various perineal procedures were predicted, including the Richter's procedure for the treatment of vaginal vault prolapse, obturator sling procedures in males and females for the treatment of stress urinary incontinence, pudendal nerve block and dorsal penile nerve block, as well as ischioanal abscess / ischioanal fistula drainage.

4.2.1 Richter's procedure

During the Richter's procedure, a stitch is placed through the sacrospinous ligament to repair vaginal vault prolapse. The length of the sacrospinous ligament and the location and branching patterns of the PN posterior to this ligament are therefore clinically relevant.

Various anatomical variations amongst black and white South African females have been noted in this study. These findings are clinically important, as most research on landmarks used and safety zones has been done on white European or American females, and the possible anatomical variations amongst population groups have not been taken into account.^{23,29,34,51,106,107}

The sacrospinous ligament was significantly shorter in the black female group. The mean distances between the superior and inferior attachments of the ligament varied from the white female group with 3.48 mm and 5.07 mm respectively.

In females, the IRN entered the gluteal region as a separate structure in 38.46% of black females, and 6.25% of white females. It branched from the PN at the superior border of the sacrospinous ligament in 53.85% of black females, and 68.75% of white females. The remaining 7.69% of black females, and 25% of white females, the IRN branched from the inferior border of the sacrospinous ligament. The IRN could thus almost always be found as a separate structure when it passed posterior (62.5% of white females) or as reported in the literature, medial (92.31% of black females) to the ischial spine.^{17,20,106,108}

The PN and/or IRN might therefore be more at risk in black females as it encroached into the area available for the placement of the stitch. The stitch should be placed more than 20 mm from the ischial spine in this population group, to ensure that it will miss the PN and/or IRN. If it is placed only 20 mm from the ischial spine, it will miss the IRN by only 5.55 mm in some cases. This relates to the proposal of Sagsoz *et al.* and Pirro *et al.* that the stitch should be placed in the medial portion of the ligament, closer to the sacrum and as superficial as possible to avoid damage to the PN and its branches.^{28,106}

4.2.2 Tension-free vaginal tape procedure (TVT)

During placement of the TVT tape, the trocars are passed retropubically where the DNC is potentially in danger. Although a significant difference was found between population groups when the distance between the junction of the body of the pubis and inferior pubic ramus to the DNC was compared, this difference was less than 1 mm and should not have an impact on the relative risk for nerve injury. It might be a safer procedure in South African populations compared to those studied by Ahtari *et al.* who found that the DNC was further away from the midline than in this study. Damage to the DNC could lead to orgasmic function impairment.^{43,109}

The tape should thus be placed closer to the urethra and not too superficial, to avoid damage

to the DNC, neither too deep, to avoid damage to the perineal nerve branches which course deep to the levator ani muscle.

4.2.3 Transobturator Tape: outside-in (TOT) and inside-out (TVT-O) in females

During these procedures the tape is introduced from the genitofemoral fold, through the obturator foramen, and exits at the level of the mid-urethra, from the outside to the inside (TOT) or inside-out (TVT-O), sparing the retropubic space.

The DNC is exposed to injury during transobturator tape procedures as the initial segment of the nerve passes deep to the dorsal portion of the perineal membrane.⁵¹ Damage to the PN can be expressed as dysaesthesia in the area of the nerve.¹¹⁰

Contradicting findings, regarding the proximity of the tape to the DNC, were reported by various researchers when comparing transobturator tape procedures. Delorme *et al.* used an anatomic model to study the passage of the trocar needles in the TOT, TVT-O and TVT procedures. They predicted a higher risk of injury to the DNC during the TVT-O procedure as well as the TVT procedure when the pathways were compared to the TOT procedure.¹¹⁰ Delmas inserted transobturator tapes in ten French female cadavers. The DNC was described to lie close to the inferior pubic ramus. He speculated that the DNC will be more at risk during the TVT-O (inside-out) procedure while trying to locate the inferior border of the obturator foramen.⁴

These results contradict findings by Zahn *et al.* who reported that the TOT (outside-in) tape was found closer to the inferior pubic ramus compared to those placed from inside to outside (TVT-O). The TOT was found $0.04 \text{ cm} \pm 0.13 \text{ cm}$ from the inferior pubic ramus, compared to $0.3 \text{ cm} \pm 0.4 \text{ cm}$ from the TVT-O tape. The TOT was consistently found closer to the inferior pubic ramus and further from the obturator canal compared to the TVT-O approach.⁶⁴ These results coincide with the results of this study. The TOT tape (outside-in) was overall closer to the DNC than the other tapes placed. Although it had a guided passage through the dissected tunnel to exit under the mid-urethra, it was still found closer to the inferior pubic ramus than in the TVT-O (inside-out) procedure. Contributing to this finding could be that the procedures done on white

females, with overall greater pelvic dimensions, outnumbered the procedures performed on black females with smaller pelvic dimensions.

Ridgeway *et al.* studied and measured 96 disarticulated pelves and commented that variations in the size of the obturator foramina and the subpubic angle are clinically important for obturator procedures as kits consist of needles with fixed sizes and angles, which may pose a danger to soft tissue structures related closely to these landmarks.¹² They suggested that modifications of the trocar needles to adapt to variations amongst individuals are necessary to minimise the risk of damage to the DNC and the branches of the obturator nerve.

As females with a higher BMI develop urinary incontinence more frequently and patients that will need tape procedures will most likely be older females with a high BMI, deductions made on white females in the current study population will be highly relevant.³⁷⁻³⁹ The DNC might be more at risk in patients with a high BMI, considering that it will be more challenging to manipulate a standard trocar needle, to exit far away enough from the inferior pubic ramus to miss the DNC during the TOT (outside-in) procedure.

It can be speculated that during the TVT-O (inside-out) procedure, the trocar will exit closer to the lateral border of the inferior pubic ramus and further from the obturator foramen in patients with a high BMI. In patients with a low BMI, the needle may scrape the inferior pubic ramus, because of smaller pelvic dimensions, which might damage the DNC as it is located close to the postero-medial surface of the inferior pubic ramus. It will exit further away from the lateral border of the inferior pubic ramus and thus closer to the obturator canal.

During the TOT (outside-in) procedure, the trocar will enter the genitofemoral fold to exit under the mid-urethra. In patients with a high BMI, the needle will enter at the correct entry point, but might exit just medial to the inferior pubic ramus, where the DNC will be found, to compensate for the subcutaneous fat in this area. When this procedure is performed on patients with a low BMI, the needle will exit more medially, under the mid-urethra, and will not put the DNC at risk. The TVT-O (inside-out) procedure might be safer for patients with a high BMI provided that the inferior pubic ramus is not scraped, whereas the TOT (outside-in)

procedure might be safer for patients with a low BMI. Safety margins for each weight category and advice on certain procedures for each group may so be established.

4.2.4 Transobturator Tape (outside-in and inside-out) in males

The use of suburethral slings for the treatment of urinary incontinence in males is still a new procedure. Urinary incontinence is not a common occurrence in males, but develops frequently after prostatectomy.

During these procedures, the trocar is placed through the space between the bulb and the ischiocavernosus muscle and courses through the obturator foramen, and guided to exit in the genitofemoral fold (inside-out) or in the opposite direction (outside-in).

The perineal nerve and its posterior scrotal branches were found within 1 cm from the bulb of the penis. During dissection around the bulb of the penis, and the insertion of the trocar in the space created between the bulb of the penis and the corpus cavernosum, the perineal nerve and its branches are at risk. Dissections should therefore not be performed too close to the bulb of the penis, in order to avoid injury to these nervous structures.

In males with a high BMI, the trocar may exit closer to the inferior pubic ramus than intended, to compensate for the standardized curve of the trocar needle. When the trocar needle passes too close to the medial border of the inferior pubic ramus, the DNP may be entrapped by the sling as it 'hugs' the inferior pubic ramus.

No studies could be found in the literature where the inside-out and outside-in procedures were compared in males.

4.2.5 Pudendal nerve block:

The accurate location of the PN, before it gives off its branches, is important in the positioning of the needle for a PN block.¹⁷ During this procedure the different branching patterns of the PN should be taken into account in order for the PN to be anaesthetized completely. In 92.31% of cases in the black female group, the PN and the IRN was found medial to the ischial spine, thus further away, compared to only 37.5% of cases in the white female group. To ensure that both

terminal branches are anaesthetized in the black female group, the anaesthetic should be injected more medial and proximal to the ischial spine, before the PN crosses over the sacrospinous ligament. Mahakkanukrauh *et al.* described a two trunked PN, with one trunk representing the IRN passing through the sacrospinous ligament. They suggested that in these cases the anaesthetic would not be effective, especially when the trunks are found 10 mm medial to the ischial spine.¹⁹

4.2.6 Ischioanal abscess and anal fistula drainage

When entering the ischioanal fossa for drainage of an abscess, the cutaneous sphincteric branches, and the IRN in the lower part of the fossa are liable to injury in this area.

The results confirmed that there is a significant difference in the depth of the branches of the IRN terminating at the external anal sphincter, which it supplies. These sphincteric branches were situated most superficial in the white female group when compared to all other groups, and more superficial in the black female group when compared to the black males. The minimum distance between the external anal skin and the most superficial sphincteric branch in females, ranged between 3.25 mm - 6.45 mm, where in males, it ranged between 9.05 mm - 10.5 mm. These results illustrate the narrow safety margin for the depth of the cruciate incision when performing ischioanal abscess and fistula drainage.

It was noted that in the cadavers with a high cBMI, the sphincteric branches were found deeper compared to the cadavers with a low or normal cBMI. The white male group appeared to have the highest cBMI when compared to the other groups. This may explain why the sphincteric branches were located deepest in this group. The safety margin might increase when the procedure is performed on males, especially white males and individuals with a high BMI. The outcome of the procedure may be improved by taking into account the direction of the course of these sphincteric branches. A horizontal cut along its course, instead of a cruciate cut, may prevent damage to the sphincteric branches.

4.2.7 Dorsal penile nerve block

A dorsal penile nerve block is performed to anaesthetise the shaft and foreskin of the penis during the performance of a circumcision. The skin is pierced laterally at the 10-o'clock position, slightly distal to where the pubic skin and penile skin meet.

No significant difference was found between the distances from the DNP to the midline at the level of the inferior border of the pubic symphysis in the different population groups. The mean distance between the DNP and the midline ranged between 10.41 mm \pm 2.09 mm and 11.5 mm \pm 2.16 mm in black and white males respectively. The safety zone for both black and white males was thus the same.

However, it was observed that the distance between the most inferior point of the pubic symphysis and the DNP was greater in the cadavers that had a higher cBMI and appeared overweight during the dissections. A fat pad was noted between the inferior border of the pubic symphysis and the DNP that was not observed in the lean cadavers. This may have an influence on the effectiveness of the anaesthetic during a dorsal penile nerve block, as the anaesthetic might be injected further from the DNP than intended.

4.3 Perineal procedures performed

The third part of the study was performed by a registered urologist and gynaecologist, to verify the safe areas for various perineal procedures predicted in the previous section. The stitch used during sacrospinous ligament fixation (Richter's procedure) and the tapes placed during the retropubic/transobturator tape procedures were placed in 15 unembalmed female cadavers. The inside-out transobturator tape (TOT) was placed in 15 unembalmed male cadavers.

The course of the PN and its branches was then dissected without disturbing the stitch or tape inserted. Distances between the tape/stitch and the course of the PN and its branches were measured in order to establish safe areas for each procedure. These findings were also compared to those reported in the literature.

Tests for statistical significance in this part of the study was not of value as the sample sizes in some groups were limited. Comparisons to predictions made on the PN/branches in the previous section were based on the impressions and findings of the performed procedures for verification purposes in this section.

4.3.1 Richter's procedure

The Richter's procedure was performed on nine unembalmed female cadavers (seven white and two black). The position of the stitch and the branching pattern of the PN were noted after a gluteal dissection. In five of the nine cases, four white and one black female, a separate IRN was found passing medial to the ischial spine between 4.1 mm and 23.5 mm from the PN. The distance between the placed stitch and the IRN ranged from immediately adjacent to 17.8 mm. In one black female, the stitch was placed at the inferior border of the sacrospinous ligament, entrapping the IRN. This could have led to faecal incontinence in a live patient. The white females presented with an overall higher cBMI when compared to the black females. The distances between the stitch and the PN/IRN were greater in the cadavers with a higher cBMI. The risks of entrapment might be lower in patients with a high BMI, as 'fat pads' were observed between the pudendal neurovascular structures, and between the sacrospinous and sacrotuberous ligaments.

From the results it was clear that the PN and IRN are more at risk in black females, as the separate entry of the IRN into the gluteal region, and the more medially placed PN and/or IRN encroached more into the area available for the placement of the stitch. These results concurred with the predictions made in the previous section. The Richter's stitch should thus be placed at a minimum distance of 20 mm from the ischial spine, especially in black females, to avoid nerve damage. The stitch should also be placed through the middle portion and not at the inferior border, as it may entrap the PN and/or the IRN when branching from the PN before entering the pudendal canal. If a second stitch is placed, it should be placed as close as possible to the first stitch.

4.3.2 Tension-free vaginal tape procedure (TVT):

The TVT procedure was performed on six unembalmed white female cadavers. The distance between the DNC and the TVT tape was noted after a perineal dissection.

The TVT tape procedure has been associated with various complications including bladder and bowel perforation, retropubic haematoma and damage to the urethra.^{5-7,41,42,44-46} In more recent studies, pudendal neuropathies were found and the tapes had to be removed.⁴⁷

Achtari *et al.* found that the DNC crossed under the pubic bone at a distance of about 14 mm \pm 5 mm from the midline. After insertion of the TVT tape, the distance between the DNC and the TVT tape was only 10.7 mm \pm 4.8 mm.⁴³ In this study, the distance between the DNC and the tape had a mean value of 20 mm \pm 3.73 mm, not taking into account the three cases where the tape was found more than 30 mm from the DNC. These results showed that the TVT procedure might be safer in a South African population group compared to an Australian population group. Damage to the bladder and bowel were not investigated.

4.3.3 Transobturator Tape: outside-in (TOT) and inside-out (TVT-O) in females

The TOT procedure was performed on nine unembalmed female cadavers, six white females and three black females. The distance between the DNC and the TOT tape was noted after a perineal dissection. The TVT-O procedure was performed on seven unembalmed white female cadavers. The distance between the DNC and the TVT-O tape was noted. The safest procedure was identified, taking into account cBMI.

Achtari *et al.* found no statistical difference between the TOT and TVT-O procedures when the distances between the tapes and the DNC were measured. The distance between the tape and the DNC was 11 \pm 3 mm and 12 \pm 4 mm in the TVT-O and TOT procedures respectively.⁴³ This study found the distance between the TVT-O tape and the DNC as 17.81 mm \pm 5.18 mm and 14.64 mm \pm 7.71 mm from the TOT tape to the DNC. Both procedures may be safer to perform on a South African population group compared to an Australian population group.

It was noted that in female TOT tape procedures, as the cBMI increased, the distance between the tape and the DNC decreased. Low cBMI was sometimes associated with a further proximity of the DNC, average 16.33 mm, compared to a closer proximity, average 7.4 mm, in the high cBMI to obese group. The TVT-O tape procedure was found to be safer to perform in the low or high cBMI groups. In individuals with a normal to high cBMI, the tape was found closest, 15.93 mm, to the DNC. Overall, the TVT-O procedure was on average found further away from the DNC. The TVT-O tape was found 17.81 mm from the DNC and the TOT tape was found 14.46 mm from the DNC. The TVT-O tape should thus be safest to insert, without taking into account the BMI of the patient.

Individuals with a higher BMI, more frequently seen in white females, presented with a fat pad between the DNC and the inferior pubic ramus. This fat pad may shield the nerve from entrapment during tensioning of the obturator arms.

During the TVT-O procedure, the entry point and the distance between the needle and the inferior pubic ramus can be controlled. The standard curved needle might still exit in the genitofemoral fold, but because of the wider trajectory, will not reach as far superiorly and therefore damage to the obturator nerve branches should also be reduced. The trocar will pass at a safe distance from the DNC in those with a higher BMI, unless the technique of scraping the medial border of the inferior pubic ramus is used, in which case the DNC could be damaged.

The TOT (outside-in) procedure should be safer in patients with a low BMI. The needle will enter in the genitofemoral fold and the standardized curve trocar will exit further away from the inferior pubic ramus. This will avoid damage to the DNC which can be found just a few millimetres medial to the medial border of the inferior pubic ramus, in both white and black South African females.

4.3.4 Transobturator Tape: inside-out (TOT) in males

A four-armed transobturator sling (TOT), with two prepubic and two obturator arms, were placed in an inside to outside approach in 15 unembalmed male cadavers. This sling aims to reposition and narrow the bulbar urethra to act as an additional sphincter.

Alarming results were found regarding the distance between the DNP and the obturator arms. The average distance between the DNP and the obturator arm was 1.66 mm. In nine cases, the obturator arm was found directly adjacent to the DNP. During tensioning of these arms, the tape compressed the DNP against the inferior pubic ramus. This could result in perineal pain and decreased sexual function in live patients. To avoid such a close distance between the obturator arms and the DNP, the trocar needle should be inserted more than 1 cm inferior and more medial to the triangular junction of the corpus cavernosum and the bulb of the penis.

Another startling discovery was the distance between the body of the tape and the perineal nerve branches. The perineal nerve and its posterior scrotal branches were found within 1 cm from the bulb of the penis. During dissection around the bulb of the penis, and the insertion of the trocar in the space created between the bulb of the penis and the corpus cavernosum, the perineal nerve and its branches are at risk. Dissections should therefore not be performed too close to the bulb of the penis, in order to avoid injury to these nerve structures.

The prepubic arms were placed superficial to the superior pubic ramus and it narrowed the urethra after it was tensioned. The prepubic arms were on average located at a safer distance of 10.69 mm from the DNP. These arms pierced the spermatic cord in two cases and the average distance between the cord and the prepubic arms was only 4.37 mm. The medial border of the spermatic cord should be palpated and the exit points should be marked at least 1 cm medial to the palpated border.

A correlation between increasing cBMI and the distance between the various parts of the tape and the nerves involved was noted. The distance between the DNP and the obturator arms was 1.5 mm in the group with a low cBMI, 1.34 mm in the group with a normal to high cBMI, and 3.1 mm in those in the high cBMI to obese group. The distance between the prepubic arms and the DNP also increased from 8.45 mm in the cadavers with a lower cBMI, to 15.37 mm in the normal to high cBMI group, but decreased to 5.5 mm in the high cBMI to obese group. All other distances increased as the cBMI of the cadavers increased (Refer to Table 15). This procedure might be safer to perform on overweight or obese patients, as most commonly seen in the

white male group, compared to lean patients. The outside-in procedure should be considered in patients with a low BMI, as most commonly seen in the black male group. The surgeon would not have to compensate for the standardized curve of the needle because of the smaller dimensions of the pelvis. The trocar will exit more medial to the inferior pubic ramus and thus further away from the DNP.

Chapter 5: Conclusion

During perineal procedures the PN and its branches may be injured affecting perineal sensation, urinary and anal continence as well as normal erectile and ejaculatory functions. In order to protect the integrity of the PN and its branches, knowledge of the anatomy and course of the PN and its branches is essential when performing perineal procedures.

This study is unique in that a description of the course and branches of the PN, from its exit from the pelvis to its terminal branches in the perineum was achieved, and implications for various perineal procedures were predicted. To verify these predictions certain newer perineal procedures were performed by a registered urologist and gynaecologist and distances to identified landmarks measured.

Separate entry of the IRN into the gluteal area is common in the black population group, and a more proximal branching pattern from the PN was observed which was less common in the white population group. The PN and IRN were most commonly seen medial to the ischial spine in black individuals, but rather posterior to the ischial spine in white individuals. The sacrospinous ligament was significantly shorter in the black population group, especially black males.

The following implications of the variations in the PN and the IRN in the gluteal area were considered:

The Richter's procedure should be safer to perform in the white population group and a greater distance, at least 20 mm, from the ischial spine should be used in black females, as the PN and IRN encroached more into the area available for the placement of the stitch. This area is further limited due to the significantly shorter sacrospinous ligament.

As a separate entry of the IRN along with a medially placed PN and IRN were more often seen in black females, the anaesthetic should be injected more medial and proximal to the ischial spine during a PN block.

It should be noted during ischioanal procedures that, in especially white females and those with a low BMI, the minimum distance between the external anal skin and the most superficial sphincteric branches of the IRN were significantly more superficial and thus prone to injury.

The course of the DNP/C passed medial to the inferior pubic ramus, rather than posterior to it, in most cases. This variation is clinically relevant as the DNP/C might be at risk during urinary incontinence sling procedures.

As the DNC was closer related to the inferior pubic ramus than reported before, the TVT tape might be a safer procedure in South African populations compared to others. Population differences were not thought to have an impact on this procedure in South Africans.

White individuals with a higher BMI, might be more at risk of damage to the DNC during the TOT (outside-in) procedure as the needle may exit closer to the inferior pubic ramus than intended, thus putting the DNC at risk, while black females or patients with a lower BMI might be more at risk during the TVT-O procedure.

Similar observations were made in the male group. The trajectory in the inside-out transobturator tape procedure, performed on 15 unembalmed male cadavers, was a further distance from the DNP than the outside-in procedure and should therefore be considered in those with a higher BMI, as seen in the white population group. The outside-in procedure should be considered in cases with a low BMI.

The anaesthetic during a dorsal penile nerve block might be less effective in those with a high BMI. The anaesthetic might be injected further from the DNP than intended, because of the greater distance of the DNP from the pubic symphysis in those with a greater cBMI.

The findings of the current study on the variations in the anatomy and branching patterns of the PN and its branches should be considered when performing perineal procedures. The established safety areas should also be of value when planning and selecting surgical interventions, to minimise the risk of damage or entrapment of the PN and/or its branches.

These predicted implications of the variations in the PN and branches amongst the sex, population and BMI groups in South Africans should be verified in a clinical setting.

Chapter 6: References

1. Schraffordt SE, Tjandra JJ, Eizenberg N, Dwyer PL. Anatomy of the pudendal nerve and its terminal branches: a cadaver study. *ANZ J Surg* 2004; 74(1-2):23-6.
2. El Tohamy O. Sacrospinous Colpopexy. *ASJOG* 2006; 3:32-7.
3. Goldberg RP. Sacrospinous Ligament Suspension Using the Capiro™ Suture Capture Technique. *J Eur Genito-urinary Dis.* 2007:74-81.
4. Delmas V. Anatomical risks of transobturator suburethral tape in the treatment of female stress urinary incontinence. *Eur Urol.* 2005;48(5):793-8.
5. Bonnet P, Waltregny D, Reul O, De Leval J. Transobturator vaginal tape inside-out for the surgical treatment of female stress urinary incontinence: anatomical considerations. *J Urol.* 2005;173(4):1223-8.
6. Lee KS, Choo MS, Lee YS, Han JY, Kim JY, Jung BJ, Han DH. Prospective comparison of the 'inside-out' and 'outside-in' transobturator-tape procedures for the treatment of female stress urinary incontinence. *Int Urogynecol J.* 2008;19(4):577-82.
7. Okorochoa I, Jwarah E, Jackson S. Surgery for urinary incontinence. *Reviews in Gynaecological Practice.* 2005;5(4):251-8.
8. Butler-O'Hara M, LeMoine C, Guillet R. Analgesia for neonatal circumcision: a randomized controlled trial of EMLA cream versus dorsal penile nerve block. *Pediatrics.* 1998;101(4):e5-e.
9. Stockton MD PJ. Nerve Block, Dorsal Penile, Neonatal. [updated 8 March 2012; cited 2012, 28 January]; Available from: <http://emedicine.medscape.com/article/1355150-overview#showall>.

10. Kessler TM, Burkhard FC, Studer UE. Nerve-sparing open radical retropubic prostatectomy. *Eur Urol.* 2007;51(1):90-7.
11. Narayan P, Konety B, Aslam K, Aboseif S, Blumenfeld W, Tanagho E. Neuroanatomy of the external urethral sphincter: implications for urinary continence preservation during radical prostate surgery. *J Urol.* 1995;153(2):337.
12. Ridgeway BM, Arias BE, Barber MD. Variation of the obturator foramen and pubic arch of the female bony pelvis. *Am J Obstet Gynecol.* 2008;198(5):546. e1 - e4.
13. Loth SR, Henneberg M. Mandibular ramus flexure: a new morphologic indicator of sexual dimorphism in the human skeleton. *Am J Phys Anthropol.* 1996;99(3):473-85.
14. Patriquin ML. A comparative analysis of differences in the pelves of South African blacks and whites: University of Pretoria; 2001.
15. Patriquin M, Loth S, Steyn M. Sexually dimorphic pelvic morphology in South African whites and blacks. *HOMO.* 2003;53(3):255-62.
16. Patriquin M, Steyn M, Loth S. Metric analysis of sex differences in South African black and white pelves. *Forensic Sci Int.* 2005;147(2):119-27.
17. Shafik A, El-Sherif M, Youssef A, Olfat ES. Surgical anatomy of the pudendal nerve and its clinical implications. *Clin Anat.* 1995;8(2):110-5.
18. Ramsden CE, McDaniel MC, Harmon RL, Renney KM, Faure A. Pudendal nerve entrapment as source of intractable perineal pain. *Am J Phys Med Rehabil.* 2003;82(6):479-84.
19. Mahakkanukrauh P, Surin P, Vaidhayakarn P. Anatomical study of the pudendal nerve adjacent to the sacrospinous ligament. *Clin Anat.* 2005;18(3):200-5.

20. Robert R, Prat-Pradal D, Labat J, Bensignor M, Raoul S, Rebai R, Leborgne J, Lardoux MC, Thiodet J. Anatomic basis of chronic perineal pain: role of the pudendal nerve. *Surg Radiol Anat.* 1998;20(2):93-8.
21. Meeks GR, Grey JE. Nerve injury associated with pelvic surgery. [cited 2011, 13 August]; Available from: <http://www.uptodate.com/store>.
22. Moore KL, Dalley AF. *Clinically Orientated Anatomy*. 5 ed. Baltimore: Lippincott Williams and Wilkins; 2006.
23. Krissi H, Stanton SL. Bilateral iliococcygeus fixation technique for enterocele and vaginal vault prolapse repair. *Pelvipерineology.* 2010;29:11-4.
24. Shafik A, Doss S. Surgical anatomy of the somatic terminal innervation to the anal and urethral sphincters: role in anal and urethral surgery. *J Urol.* 1999;161(1):85-9.
25. Uzoma A, Farag K. Vaginal vault prolapse. *Obstet Gynecol Int.* 2009;2009:1-9.
26. Maher CF, Murray CJ, Carey MP, Dwyer PL, Ugoni AM. Iliococcygeus or sacrospinous fixation for vaginal vault prolapse. *Obstet Gynecol.* 2001;98(1):40-4.
27. Pohl JF, Frattarelli JL. Bilateral transvaginal sacrospinous colpopexy: preliminary experience. *Am J Obstet Gynecol.* 1997;177(6):1356-62.
28. Sagsoz N, Ersoy M, Kamaci M, Tekdemir I. Anatomical landmarks regarding sacrospinous colpopexy operations performed for vaginal vault prolapse. *Euro J Obstet Gynecol Reprod Biol.* 2002;101(1):74-8.
29. Verdeja AM, Elkins TE, Odoi A, Gasser R, Lamoutte C. Transvaginal sacrospinous colpopexy: anatomic landmarks to be aware of to minimize complications. *Am J Obstet Gynecol.* 1995;173(5):1468-9.

30. Ko-Kivok-Yun P, Monrozies X, Ayoubi J, Elghaoui A, Reme J. Vaginal sacral-spinal fixation or Richter's procedure. Experience of a surgical team with 54 cases. *Revue française de gynécologie et d'obstétrique*. 1995;90(12):525.
31. Alevizon SJ, Finan MA. Sacrospinous colpopexy: management of postoperative pudendal nerve entrapment. *Obstet Gynecol*. 1996;88(4, Part 2):713-5.
32. Barksdale P, Gasser R, Gauthier C, Elkins T, Wall L. Intraligamentous nerves as a potential source of pain after sacrospinous ligament fixation of the vaginal apex. *Int Urogynecol J*. 1997;8(3):121-5.
33. Marcus-Braun N, Bourret A, von Theobald P. Persistent pelvic pain following transvaginal mesh surgery: a cause for mesh removal. *Euro J Obstet Gynecol Reprod Biol*. 2012;162:224-8.
34. Roshanravan SM, Wieslander CK, Schaffer JI, Corton MM. Neurovascular anatomy of the sacrospinous ligament region in female cadavers: Implications in sacrospinous ligament fixation. *Am J Obstet Gynecol*. 2007;197(6):660. e1 - e6.
35. Nygaard I TD, Calhoun EA. Urinary incontinence in women. [cited 2012 5 May]; Chapter 5:[Available from: http://kidney.niddk.nih.gov/statistics/uda/Urinary_Incontinence_in_Women-Chapter05.pdf.]
36. Muller N. What Americans understand and how they are affected by bladder control problems: highlights of recent nationwide consumer research. *Urol Nurs*. 2005;25(2):109-15.
37. Mommsen S, Foldspang A. Body mass index and adult female urinary incontinence. *World J Urol*. 1994;12(6):319-22.

38. Danforth KN, Townsend MK, Lifford K, Curhan GC, Resnick NM, Grodstein F. Risk factors for urinary incontinence among middle-aged women. *Am J Obstet Gynecol.* 2006;194(2):339-45.
39. Elia G, Dye T, Scariati P. Body mass index and urinary symptoms in women. *Int Urogynecol J.* 2001;12(6):366-9.
40. Ulmsten U, Henriksson L, Johnson P, Varhos G. An ambulatory surgical procedure under local anesthesia for treatment of female urinary incontinence. *Int Urogynecol J.* 1996;7(2):81-6.
41. Ulmsten U, Falconer C, Johnson P, Jomaa M, Lanner L, Nilsson C, Olsson I. A multicenter study of tension-free vaginal tape (TVT) for surgical treatment of stress urinary incontinence. *Int Urogynecol J.* 1998;9(4):210-3.
42. Farrell S, Beckerson L, Epp A, Flood C, Lajoie F, MacMillan J, Mainprize TC, Robert M. Tension-free vaginal tape (TVT) procedure. *J Obstet Gynaecol Can.* 2003;25(8):692-4.
43. Achtari C, Mckenzie BJ, Hiscock R, Rosamilia A, Schierlitz L, Briggs CA, Dwyer PL. Anatomical study of the obturator foramen and dorsal nerve of the clitoris and their relationship to minimally invasive slings. *Int Urogynecol J.* 2006;17(4):330-4.
44. Nilsson CG, Kuuva N, Falconer C, Rezapour M, Ulmsten U. Long-term results of the tension-free vaginal tape (TVT) procedure for surgical treatment of female stress urinary incontinence. *Int Urogynecol J.* 2001;12(8):5-8.
45. Hinoul P, Vanormelingen L, Roovers JP, de Jonge E, Smajda S. Anatomical variability in the trajectory of the inside-out transobturator vaginal tape technique (TVT-O). *Int Urogynecol J.* 2007;18(10):1201-6.
46. De Leval J. Novel surgical technique for the treatment of female stress urinary incontinence: transobturator vaginal tape inside-out. *Urology.* 2003;44:724-30.

47. Rigaud J, Pothin P, Labat JJ, Riant T, Guerineau M, Normand LL, Glemain P, Robert R, Bouchot O. Functional results after tape removal for chronic pelvic pain following tension-free vaginal tape or transobturator tape. *J Urol*. 2010;184(2):610-5.
48. Bondili A, Cooper J. Pudendal neuralgia: A rare cause of pain after tension free vaginal tape. *J Obstet Gynaecol*. 2011;31(5):454-5.
49. Vervest HA, Bongers MY, van der Wurff AA. Nerve injury: an exceptional cause of pain after TVT. *Int Urogynecol J*. 2006;17(6):665-7.
50. Fisher HW, Lotze PM. Nerve injury locations during retropubic sling procedures. *Int Urogynecol J*. 2011;22(4):439-41.
51. Montoya TI, Calver L, Carrick KS, Prats J, Corton MM. Anatomic relationships of the pudendal nerve branches. *Am J Obstet Gynecol*. 2011;205(5):504. e1 - e5.
52. Delorme E. Transobturator urethral suspension: mini-invasive procedure in the treatment of stress urinary incontinence in women. *Progres en urologie: journal de l'Association francaise d'urologie et de la Societe francaise d'urologie*. 2001;11(6):1306.
53. Gynecare TVT Obturator System In: GYNECARE, editor. Switzerland 2005.
54. Whiteside JL, Walters MD. Anatomy of the obturator region: relations to a trans-obturator sling. *Int Urogynecol J*. 2004;15(4):223-6.
55. Neuman M. TVT and TVT-Obturator: comparison of two operative procedures. *Euro J Obstet Gynecol Reprod Biol* . 2007;131(1):89.
56. Debodinance P. Trans-obturator urethral sling for surgical correction of female stress urinary incontinence: Outside-in (Monarc) versus inside-out (TVT-O). Are both ways safe? *Journal de gynecologie, obstetrique et biologie de la reproduction*. 2006;35(6):571.

57. Chen Z, Chen Y, Du G, Yuan X, Wu J, Zeng X, *et al.* Comparison of three kinds of mid-urethral slings for surgical treatment of female stress urinary incontinence. *Urologia*. 2010;77(1):37-41.
58. Dyrkorn OA, Kulseng-Hanssen S, Sandvik L. TVT compared with TVT-O and TOT: results from the Norwegian National Incontinence Registry. *Int Urogynecol J*. 2010;21(11):1321-6.
59. Cho MK, Kim CH, Kang WD, Kim JW, Kim SM, Kim YH. Complications following Outside-in and Inside-out Transobturator-Tape procedures with Concomitant Gynecologic operations. *Chonnam Med J*. 2011;47(3):165-9.
60. Pauls RN, Silva WA, Rooney CM, Siddighi S, Kleeman SD, Dryfhout V, Karram MM. Sexual function after vaginal surgery for pelvic organ prolapse and urinary incontinence. *Am J Obstet Gynecol*. 2007;197(6):622. e1 - e7.
61. Maaita M, Bhaumik J, Davies A. Sexual function after using tension-free vaginal tape for the surgical treatment of genuine stress incontinence. *BJU Int*. 2002;90(6):540-3.
62. Latthe PM, Foon R, Toozs-Hobson P. Transobturator and retropubic tape procedures in stress urinary incontinence: a systematic review and meta-analysis of effectiveness and complications. *BJOG*. 2007;114(5):522-31.
63. Paulson JD, Baker J. De novo pudendal neuropathy after TOT-O surgery for stress urinary incontinence. *JSLS*. 2011;15(3):326.
64. Zahn CM, Siddique S, Hernandez S, Lockrow EG. Anatomic comparison of two transobturator tape procedures. *Obstet Gynecol*. 2007;109(3):701-6.
65. Rehder P, Gozzi C. Transobturator sling suspension for male urinary incontinence including post-radical prostatectomy. *Eur Urol*. 2007;52(3):860-7.

66. Gozzi C, Becker AJ, Bauer R, Bastian PJ. Early results of transobturator sling suspension for male urinary incontinence following radical prostatectomy. *Eur Urol*. 2008;54(4):960-1.
67. Ficazzola MA, Nitti VW. The etiology of post-radical prostatectomy incontinence and correlation of symptoms with urodynamic findings. *J Urol*. 1998;160(4):1317.
68. Virtue Male Sling System In: A/S C, editor. Minneapolis, USA 2001.
69. Rapp DE, Reynolds WS, Lucioni A, Bales GT. Surgical technique using AdVance™ Sling placement in the treatment of post-prostatectomy urinary incontinence. *Int Braz J Urol*. 2007;33(2):231-7.
70. Kennelly MJ, Moore R, Nguyen JN, Lukban JC, Siegel S. Prospective evaluation of a single incision sling for stress urinary incontinence. *J Urol*. 2010;184(2):604-9.
71. Gauruder-Burmester A, Popken G. The Miniarc® sling system in the treatment of female stress urinary incontinence. *Int Braz J Urol*. 2009;35(3):334-43.
72. Abdel-Fattah M, Ford JA, Lim CP, Madhuvrata P. Single-incision mini-slings versus standard midurethral slings in surgical management of female stress urinary incontinence: a meta-analysis of effectiveness and complications. *Eur Urol* . 2011;60(3):468-80.
73. De Ridder D, Berkers J, Deprest J, Verguts J, Ost D, Hamid D, Van der Aa F. Single incision mini-sling versus a transobutator sling: a comparative study on MiniArc™ and Monarc™ slings. *Int Urogynecol J*. 2010;21(7):773-8.
74. Basu M, Duckett J. A randomised trial of a retropubic tension-free vaginal tape versus a mini-sling for stress incontinence. *BJOG*. 2010;117(6):730-5.

75. Moore R, Serels S, Davila G, Settle P. Minimally invasive treatment for female stress urinary incontinence (SUI): a review including TVT, TOT, and mini-sling. *Surg Technol Int.* 2009;18(2):157-73.
76. Moore R, Mitchell G, Miklos J. Single-center retrospective study of the technique, safety, and 12-month efficacy of the MiniArc single-incision sling: a new minimally invasive procedure for treatment of female SUI. *Surg Technol Int.* 2009;18:175-81.
77. Ranganath S FT. Fecal incontinence. [updated 26 Oct 2012; cited 2012 18 July]; Available from: <http://emedicine.medscape.com/article/268674-overview>.
78. Meschia M, Buonaguidi A, Pifarotti P, Somigliana E, Spennacchio M, Amicarelli F. Prevalence of anal incontinence in women with symptoms of urinary incontinence and genital prolapse. *Obstet Gynecol.* 2002;100(4):719-23.
79. Nelson R, Norton N, Cautley E, Furner S. Community-based prevalence of anal incontinence. *JAMA.* 1995;274(7):559-61.
80. Johanson J, Lafferty J. Epidemiology of fecal incontinence: the silent affliction. *Am J gastroenterol.* 1996;91(1):33.
81. Faltin D, Sangalli M, Curtin F, Morabia A, Weil A. Prevalence of anal incontinence and other anorectal symptoms in women. *Int Urogynecol J.* 2001;12(2):117-21.
82. Snooks S, Henry M, Swash M. Anorectal incontinence and rectal prolapse: differential assessment of the innervation to puborectalis and external anal sphincter muscles. *Gut.* 1985;26(5):470-6.
83. Yamana T, Takahashi T, Iwaware J. Perineal puborectalis sling operation for fecal incontinence: preliminary report. *Dis Colon Rectum.* 2004;47(11):1982-9.
84. Womack N, Williams N, Morrison J. Prospective study of the effects of postanal repair in neurogenic faecal incontinence. *BJS.* 2005;75(1):48-52.

85. Tets W, Kuijpers JHC. Pelvic floor procedures produce no consistent changes in anatomy or physiology. *Dis Colon Rectum*. 1998;41(3):365-9.
86. Satpathy HK FD, Fleming AD, Fossen KA. Nerve Block, Transvaginal Pudendal. [cited 2011 20 December]; Available from: <http://emedicine.medscape.com/article/83078-overview#showall>.
87. Norwitz ER SJ. *Obstetrics and Gynecology at a glance*. 3rd ed: Blackwell publishing; 2010.
88. Vadivelu N UR, Hines RL. *Essentials of pain Management*. New York: Springer; 2011.
89. Sahay P. Pudendal nerve block. *BMJ*. 1959;1(5124):759-61.
90. Billingham RP, Isler JT, Kimmins MH, Nelson JM, Schweitzer J, Murphy MM. The diagnosis and management of common anorectal disorders. *Curr Probl Surg*. 2004;41(7):586.
91. Oliver I, Lacueva F, Perez Vicente F, Arroyo A, Ferrer R, Cansado P, Candela F, Calpena R. Randomized clinical trial comparing simple drainage of anorectal abscess with and without fistula track treatment. *Int J colorectal Dis*. 2003;18(2):107-10.
92. A H. Perineal Abscess Treatment and Management. [cited 2012 28 January]; Available from: <http://emedicine.medscape.com/article/191975-treatment#showall>.
93. Kirya C, Werthmann MW. Neonatal circumcision and penile dorsal nerve block—a painless procedure *J Pediatr*. 1978;92(6):998-1000.
94. GZ S. Dorsal Penile Nerve Block. [cited 2012 28 January]; Available from: <http://emedicine.medscape.com/article/81077-overview#showall>.
95. Graefen M, Walz J, Huland H. Open retropubic nerve-sparing radical prostatectomy. *Eur Urol*. 2006;49(1):38-48.

96. Walsh PC, Lepor H, Eggleston JC. Radical prostatectomy with preservation of sexual function: anatomical and pathological considerations. *Prostate*. 1983;4(5):473-85.
97. Talcott JA, Rieker P, Propert KJ, Clark JA, Kantoff PW, Wishnow KI, Loughlin KR, Richie JP. Patient-reported impotence and incontinence after nerve-sparing radical prostatectomy. *JNCI*. 1997;89(15):1117-23.
98. Gillitzer R, Hampel C, Wiesner C, Pahernik S, Melchior S, Thüroff J. Pudendal nerve branch injury during radical perineal prostatectomy. *Urology*. 2006;67(2):423. e1 - e3.
99. Oettlé A, Pretorius E, Steyn M. Geometric morphometric analysis of the use of mandibular gonial eversion in sex determination. *HOMO*. 2009;60(1):29-43.
100. Steyn M, İşcan MY. Osteometric variation in the humerus: sexual dimorphism in South Africans. *Forensic Sci Int*. 1999;106(2):77-85.
101. Patriquin M, Steyn M, Loth S. Metric assessment of race from the pelvis in South Africans. *Forensic Sci Int*. 2002;127(1):104-13.
102. Steyn M, İşcan MY. Sex determination from the femur and tibia in South African whites. *Forensic Sci Int*. 1997;90(1):111-9.
103. Gallagher D, Heymsfield SB, Heo M, Jebb SA, Murgatroyd PR, Sakamoto Y. Healthy percentage body fat ranges: an approach for developing guidelines based on body mass index. *Am J Clin Nutr*. 2000;72(3):694-701.
104. Kort HI, Massey JB, Elsner CW, Mitchell-Leef D, Shapiro DB, Witt MA, *et al*. Impact of body mass index values on sperm quantity and quality. *Journal Androl*. 2006;27(3):450-2.
105. Parliament SA. National Health Act No. 61 of 2003. *Government Gazette*. 2005.

106. Pirro N, Sielezneff I, Le Corroller T, Ouaiissi M, Sastre B, Champsaur P. Surgical anatomy of the extrapelvic part of the pudendal nerve and its applications for clinical practice. *Surg Radiol Anat.* 2009;31(10):769-73.
107. Lazarou G, Grigorescu BA, Olson TR, Downie SA, Powers K, Mikhail MS. Anatomic variations of the pelvic floor nerves adjacent to the sacrospinous ligament: a female cadaver study. *Int Urogynecol J.* 2008;19(5):649-54.
108. Gruber H, Kovacs P, Piegger J, Brenner E. New, simple, ultrasound-guided infiltration of the pudendal nerve. *Dis Colon Rectum.* 2001;44(9):1376-80.
109. Achtari C, Dwyer PL. Sexual function and pelvic floor disorders. *Best Pract Res CL OB.* 2005;19(6):993-1008.
110. Delorme E, Droupy S, de Tayrac R, Delmas V. Transobturator Tape (Uratape®): A New Minimally-Invasive Procedure to Treat Female Urinary Incontinence. *Eur Urol.* 2004;45(2):203-7.