

RESEARCH COMMUNICATION

Variation in clinical disease and species susceptibility to psittacine beak and feather disease in Zimbabwean lovebirds

N.D. KOCK¹ P.U. HANGARTNER² and V. LUCKE³

ABSTRACT

KOCK, N.D. HANGARTNER, P.U. & LUCKE, V. 1993. Variation in species susceptibility to psittacine beak and feather disease in Zimbabwean lovebirds. *Onderstepoort Journal of Veterinary Research*, 60:159-161 (1993)

While psittacine beak and feather disease has caused 100 % mortality in captive flocks of 2 species of native Zimbabwean lovebirds (*Agapornis nigrigensis* and *A. lilianae*), other lovebird species in close contact with the sick birds have been only transiently affected or not at all. The clinical course of the disease in affected lovebirds may differ from that reported elsewhere, with recovery in some cases. These differences, along with ultrastructural differences may suggest a different virus or different strain of virus underlying disease in Zimbabwe.

INTRODUCTION

Psittacine beak and feather disease (Pbfd), a progressive and ultimately fatal disease, occurs primarily in captive psittacine birds (Graham 1984; Lowenstine 1984; Jacobson 1985), but has also been reported in wild cockatoos (McOrist, Black, Pass, Scott & Marshall 1984). It is well recognized in cockatoos in Australia (Perry 1981; Pass & Perry 1984) and in a variety of psittacine birds in the Uni-

ted States, lovebirds and cockatoos being particularly susceptible (Jacobson 1985; Lowenstine 1984, 1985), and was recently described in lovebirds in Zimbabwe (Kock 1989, 1990). A viral aetiology has been suspected since its initial description, and recently isolation and characterization have been achieved (Ritchie, Niagro, Lukert, Steffens & Latimer 1988, 1989), although no replication was detected in cell cultures.

The disease is progressive and irreversible, with feather, beak and sometimes claw abnormalities. Inclusion-laden cells and degenerative changes are prominent in feather pulp macrophages and epithelium of the feather follicles and rachis, and may also be seen in other tissues, such as the thymus and bursa of Fabricius (Pass & Perry 1984; Jacobson 1985; Kock 1989; Latimer, Rakich, Kir-

¹ Faculty of Veterinary Science, University of Zimbabwe, P.O. Box MP167 Mount Pleasant, Harare, Zimbabwe

² Department of Pathology, School of Veterinary Science, University of Bristol, Langford, Bristol, BS18 7DU ENGLAND

³ International Wildlife Veterinary Services, 1850 No. Main Street Salinas, California, USA

Received 29 March 1993—Editor

cher, Ritchie, Niagro, Steffins & Luckert 1990). Diagnosis of Pbfd is most often based on feather biopsy through light microscopic identification of densely basophilic, botryoid, intracytoplasmic inclusions in macrophages and in pulp and follicular epithelial cells (Lowenstine 1984; Jacobson 1985). These inclusions appear as crystalline arrays of viral nucleocapsid material by electron microscopy, the morphology of which most closely resembles parvoviruses (Jacobson 1985; Gough, Collins & Gresham 1989), although more recent work suggests that the aetiological agent belongs to a new viral family, *Diminuviridae* (Ritchie *et al.* 1989).

MATERIALS AND METHODS

Skin and feathers from Zambezi of black-cheeked (*Agapornis nigrigensis*) and Lillian's or Nyasa (*A. lilliana*) lovebirds diagnosed with Pbfd (Kock 1989, 1990) were placed in 10 % buffered formalin and 4 % glutaraldehyde and routinely processed for light and electron microscopy, respectively.

RESULTS

Formalin-fixed sections disclosed the presence of typical Pbfd disease inclusions in feather pulp macrophages and in follicular and pulp epithelial cells (Kock 1989). These were identified by electron microscopy as paracrystalline arrays of condensed viral capsid material, with estimated subunit diameters of 13 nm (Fig. 1).

DISCUSSION

A recent outbreak of Pbfd in Zimbabwe resulted in 100 % mortality in captive flocks of black-cheeked and Lillian's lovebirds (Kock 1989, 1990), both of which are native to Zimbabwe. In contrast, most peach-faced (*A. roseicollis*) and all Fischer (*Agapornis fischeri*) lovebirds in close contact with the diseased birds showed no signs of disease. A few peach-faced lovebirds and Fischer/peach-faced hybrids developed only transient feather abnormalities, but were diagnosed positively for Pbfd on feather biopsy. Lovebirds in general are thought to be quite susceptible to Pbfd, making the apparent resistance of the peach-face and Fischer lovebirds surprising, although species and individual variation are recognized. The recovery from Pbfd disease in some birds, however, was unanticipated.

Clinically, the disease in black-cheeked and Lillian's lovebirds was similar to previously reported cases of Pbfd, in that progressive feather abnormalities and feather loss occurred. Causes of death, however, could not usually be determined. Secondary fatal infections, the result of impaired immune responses, as described in other cases of the disease (Pass & Perry 1984) were not diagnosed in any of the birds (Kock 1989), and in fact, body condition at

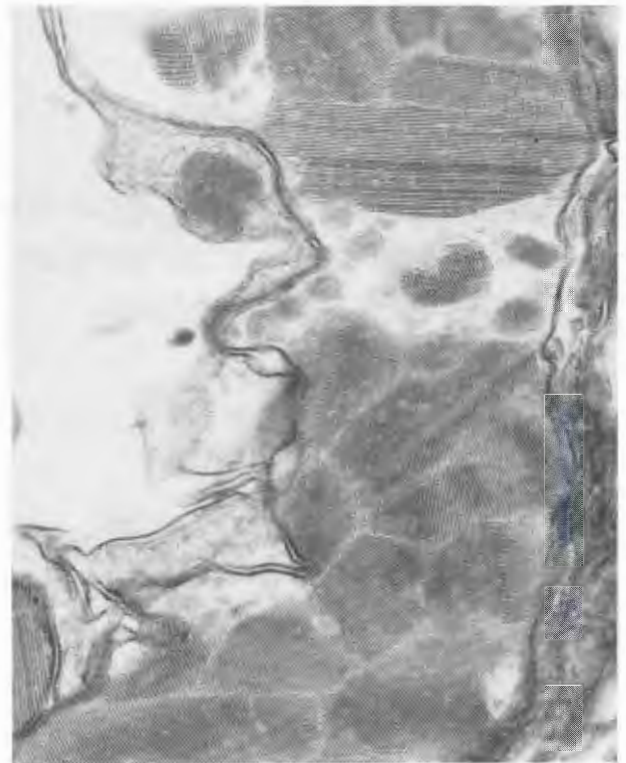


FIG. 1 Electron micrograph showing paracrystalline arrays of condensed viral capsid material, with subunit diameters of 13 nm, within the cytoplasm of a follicular epithelial cell

the time of death tended to be excellent. The only clinical abnormality consistently noted, aside from the feather loss, was elevation in respiratory rate. Degenerative changes in the bursa of Fabricius in 1 of the birds was consistent with previous reports (Pass & Perry 1984).

Intracytoplasmic paracrystalline arrays of viral capsid material were found in macrophages and epithelial cells in the two affected species, which are morphologically similar, although slightly smaller than viral particles characterized in affected psittacine birds in Great Britain, Australia and the United States. The subunit diameters of these arrays is 13 nm, slightly smaller than the 14–17 nm diameter reported for the newly suggested *Diminuviridae*. While it is reasonable to assume that the Zimbabwean virus is the same as has been recently characterized in the US, the differences in species susceptibility and clinical course in some birds make it possible that the Zimbabwean disease is caused by a different virus or perhaps a different strain of virus.

ACKNOWLEDGEMENTS

The authors would like to thank the University of Zimbabwe Research Board for the funding provided for this project and Arthur Dare for providing case

material. International Wildlife Veterinary Services provided additional support.

REFERENCES

- GOUGH, R.E., COLLINS, M.S. & GRESHAM, A.C. 1989. A parvovirus-like agent associated with psittacine beak and feather disease. *Veterinary Record*, 8 July.
- GRAHAM, D.L. 1984. An update on selected pet bird virus infections. *Proceedings of the International Conference on Avian Medicine*: 267–280.
- JACOBSON, E.R. 1985. Cockatoo beak and feather disease syndrome, in *Current veterinary therapy IX*, edited by R. KIRK. London: WB Saunders: 710–713.
- KOCK, N.D. 1989. An outbreak of beak and feather disease in lovebirds (*Agapornis* sp.) in Zimbabwe. *Zimbabwe Veterinary Journal*, 20:97–103.
- KOCK, N.D. 1990. Confirmation of psittacine beak and feather disease in Lillian's lovebirds (*Agapornis lilianae*) in Zimbabwe. *Zimbabwe Veterinary Journal*, 21:73.
- LATIMER, K.S., RAKICH, P.M., KIRCHER, I.M., RITCHIE, B.W., NIAGRO, F.D., STEFFINS, W.L. & LUCKERT, P.D. 1990. Extracutaneous viral inclusions in psittacine beak and feather disease. *Journal of Veterinary Diagnostic Investigations*, 2: 204–207.
- LOWENSTINE, L.J. 1984. Cockatoo feather disease: A summary of preliminary findings. *Proceedings of the 33rd Western Poultry Disease Conference*: 94–96.
- LOWENSTINE, L.J. 1985. Emerging viral diseases of psittacine birds, in *Current veterinary therapy IX*, edited by R. KIRK. London: WB Saunders: 705–710.
- McORIST, S., BLACK, D.G., PASS, D.A., SCOTT, P.C. & MARSHALL, J. 1984. Beak and feather dystrophy in wild sulphur-crested cockatoos (*Cacatua galerita*). *Journal of Wildlife Diseases*, 20:120.
- PASS, D.A. & PERRY, R.A. 1984. The pathology of psittacine beak and feather disease. *Australian Veterinary Journal*, 61: 69–74.
- PERRY, R.A. 1981. A psittacine combined beak and feather disease syndrome, in *Proceedings no. 55 of courses for veterinarians: Cage and aviary birds, Sydney, Australia*: 81–87.
- RITCHIE, B.R., NIAGRO, F.D., LUCKERT, P.D., STEFFINS, W.L. & LATIMER, K.S. 1988. Isolation and characterization of the psittacine beak and feather disease virus. *Proceedings of the Association of Avian Veterinarians*: 1–2.
- RITCHIE, B.R., NIAGRO, F.D., LUCKERT, P.D., LATIMER, K.S. & STEFFINS, W.L. 1989. Characterization of a new virus from cockatoos with psittacine beak and feather disease. *Virology*, 171:83–88.
- RITCHIE, B.R., NIAGRO, F.D., LUCKERT, P.D., STEFFINS, W.L. & LATIMER, K.S. 1989. Characterization of the psittacine beak and feather disease virus. *Proceedings of the Western Poultry Disease Conference*: 161.