

Perinatal mortality in lambs of ewes exposed to cultures of *Diplodia maydis* (= *Stenocarpella maydis*) during gestation. A study of the central-nervous-system lesions

L. PROZESKY, T.S. KELLERMAN¹, D. PETRO SWART, B.P. MAARTENS and R. ANITRA SCHULTZ

Onderstepoort Veterinary Institute, Onderstepoort, 0110 South Africa

ABSTRACT

PROZESKY, L., KELLERMAN, T.S., SWART, D. PETRO, MAARTENS, B.P. & SCHULTZ, R. ANITRA 1994. Perinatal mortality in lambs of ewes exposed to cultures of *Diplodia maydis* (= *Stenocarpella maydis*) during gestation. A study of the central-nervous-system lesions. *Onderstepoort Journal of Veterinary Research*, 61:247–253

Previously published results of dosing trials, involving 82 ewes, revealed that 66% of the offspring of dams exposed to cultures of *Diplodia maydis* in the second trimester of pregnancy and 87% of lambs of ewes exposed in the third trimester, were born dead or died soon afterwards. Spongiform degeneration of myelin of varying degree was present in the brains of all the stillborn and non-viable lambs in these trials. Myelin lamellae were separated at the intraperiod line. The spongiform degeneration occurred throughout the central nervous system in severely affected animals, whereas in mildly affected lambs the lesions had a predilection for the white matter, particularly of the cerebellum and cerebrum. In 28 lambs the spongiform degeneration progressed to lytic necrosis, and hydrocephalus was recorded in two animals.

INTRODUCTION

Diplodiosis is an endemic neuromycotoxicosis of cattle and sheep grazing on harvested maize lands in winter. The causative agent, *Diplodia maydis* (= *Stenocarpella maydis*) (Mitchell 1918; Kellerman, Rabie, Van der Westhuizen, Kriek & Prozesky 1985; Kellerman, Prozesky, Schultz, Rabie, Van Ark, Maartens & Lübben 1991), is a common cob-rot fungus of maize, which forms a coarse, white mycelial mat, frequently at the base of the ear. Towards the end of

the growing season characteristic pinhead-sized, black fruiting bodies or pycnidia are produced and the fungus overwinters in this form on maize residues (Kellerman, Coetzer & Naudé 1988).

The clinical signs of diplodiosis are characterized by ataxia, paresis, and paralysis (Kellerman *et al.* 1985; Kellerman, Coetzer & Naudé 1988). Mortalities may be high in field outbreaks, but if stock are removed from the toxic lands as soon as the signs appear, the prognosis is usually good. Although *D. maydis* is present wherever maize is grown, authenticated outbreaks have apparently not been reported outside southern Africa (Kellerman *et al.* 1988).

Usually, no lesions are seen in animals that succumb to the disease; however, a subcortical laminar status

¹ Honorary Professor, Department of Pharmacology and Toxicology, Faculty of Veterinary Science, University of Pretoria, Private Bag X04, Onderstepoort, 0110 South Africa

Received 21 July 1994—Editor

spongiosus has been observed on histopathological examination of two exceptional experimental cases that displayed persistent nervous signs (Kellerman *et al.* 1985).

D. maydis cultures have recently been found to be extremely foetotoxic to ruminants. Dosing trials at Onderstepoort Veterinary Institute, involving 66 ewes, revealed that 66% of the offspring of dams exposed to cultures of *D. maydis* in the second trimester of pregnancy and 87% of ewes exposed in the third trimester, were either stillborn or died soon after birth. Histopathological examination of the central nervous systems of the affected lambs revealed a status spongiosus in the white matter, similar to that of stillborn lambs and calves in flocks and herds grazing on harvested lands naturally infected by cob rot (Kellerman *et al.* 1991). The lambs of control ewes and those of ewes in the first trimester of pregnancy, on the other hand, showed no ill effects.

There is a dearth of information on the pathogenic effects of mycotoxins on the developing foetus (Abrahamovici 1977). The purpose of this study, therefore, is to report on the lesions in the central nervous system (CNS) of lambs of ewes which were exposed to toxic cultures of *D. maydis* (Kellerman *et al.* 1991) during various stages of gestation.

MATERIALS AND METHODS

Inoculum

The inoculum was prepared from a toxigenic strain of *D. maydis* collected on a maize field where perinatal losses of lambs had occurred. The fungus was cultured on yellow maize for 8 weeks at 26 °C as described by Rabie, Kellerman, Kriek, Van der Westhuizen & De Wet (1985).

Dosing trial

The dosing regimen for both the pilot and main trial (Kellerman *et al.* 1991) is briefly summarized.

Pilot trial

Nineteen ewes in about the third trimester of pregnancy were randomly divided into two groups. One group (nine ewes) was exposed four times, at approximately two-weekly intervals, with a toxic *D. maydis* isolate, while the other group (ten ewes) received autoclaved maize at equivalent rates. Nine ewes, similarly dosed with autoclaved maize seeds, served as controls. An exposure consisted of 10 g/kg of culture material administered on two to four successive days.

Main trial

The oestrus cycle of 63 two-to-four-tooth merino ewes was synchronized prior to artificial insemina-

tion. Rams were kept with the ewes for 4 d after insemination to ensure maximum conception.

During the first trimester of pregnancy group A (nine ewes) was exposed to culture material three times at *c.* two-weekly intervals; group B (nine ewes) was similarly exposed three times during the second trimester; and group C (15 ewes), three times during the third trimester. Group D (ten ewes) was dosed three times at bi-weekly intervals with another isolate of *D. maydis*, during the third trimester. An exposure consisted of 10 g/kg of culture material dosed on each of three successive days. As control animals, 15 pregnant ewes were exposed to maize substrate six times during the second and third trimesters at rates equivalent to those of the cultured material in the treated groups.

Clinical examination

The animals were observed daily, and date of birth, birth mass, and gains in mass were recorded (Kellerman *et al.* 1991).

Pathology

All the stillborn lambs, lambs that had not been able to maintain themselves (non-viable lambs) and ewes that had died, were necropsied. Three lambs born of untreated ewes were slaughtered and necropsied on the day of birth, as controls. The brain and spinal cord of each animal was fixed *in toto*, and specimens from various organs, including the lungs, heart, liver, spleen, gastro-intestinal tract, skeletal muscle, liver, and brachial plexus, were collected in 10% buffered formalin.

From each animal approximately 13–15 coronal brain sections as well as two to three pieces each, of the cervical, thoracic, lumbar and sacral spinal cord and the other specimens, as outlined, were processed routinely and stained with haematoxylin and eosin (HE). Selected sections of brain and spinal cord were stained with luxol-fast-blue Holme's silver nitrate (LFB-H) and luxol-fast-blue periodic-acid-Shiff haematoxylin (LFB-PAS-H) (Margolis & Pickett 1956).

Electron microscopy

Blocks of 0.5–1 mm³ were collected from the white matter of the cerebral hemispheres in the vicinity of the radiation *corporis callosi* and from the cerebellar peduncular area, respectively, of lambs from five ewes within 1 h after death. Specimens were collected from the offspring of two ewes in the control group as outlined for the main trial.

The blocks were fixed in 2.5% glutaraldehyde (pH 7.3–7.4) at room temperature for 24 h and then post-fixed in 2% osmium tetroxide for 1 h. Specimens were dehydrated in a graded ethanol series (50–100%), passed through propylene oxide as the intermediate solvent, and embedded in Taab 812.

Thick (1–2 μm) sections for tissue orientation were cut and stained with toluidine blue. Thin sections from selected tissue blocks were stained for 20 min in a saturated aqueous solution of uranyl acetate and for 3 min in Reynold's lead citrate, with rinsing in between at room temperature.

RESULTS

Perinatal mortality of lambs

Lambing and other relevant data of both the pilot trial and main trial (Kellerman *et al.* 1991) are briefly summarized.

Pilot trial

One normal lamb, six stillborn lambs and three non-viable lambs were born from the sheep exposed to *D. maydis*, as compared with 14 healthy ones in the control group.

Main trial

Five out of 15 lambs of ewes exposed in the second trimester survived, whereas four lambs were stillborn and six were lame (Fig. 1). Five out of 37 lambs born from ewes exposed in the third trimester survived, 24 were stillborn and eight lame. The lambs of ewes in the two control groups and those of ewes that were exposed in the first trimester, were not affected.

Pathological findings

Gross pathology

Except for some dorsoventral flattening of the cerebral hemispheres in two stillborn lambs in group C, no macroscopical lesions could be detected in either the stillborn or non-viable lambs. Coronal sections of these two brains revealed prominent dilatation of both the lateral ventricles (hydrocephalus). Neural tissue bordering the lateral ventricles was affected by pressure atrophy. The cerebral sulci were normal in depth; however, the white matter was very soft and had a gelatinous appearance, and the normal finger-like pattern in the gyri was replaced by a collapsed mass of white matter.

Histopathological lesions

In all the stillborn and lame lambs the most characteristic lesion in the central nervous system was mild to severe spongiform degeneration of the white matter (Fig. 2 and 3). In severely affected lambs, the lesions occurred throughout the brain, while in mildly affected ones the lesions were limited more or less to the white matter of the cerebral and cerebellar hemispheres and central cerebrum and cerebellum.

Spongiform degeneration of the white matter in the spinal cord was usually present only in animals with

pronounced brain lesions. The lesion was either diffusely distributed in the white matter or had a predilection for tracts bordering the grey matter. Spongiform degeneration was also noted in the peripheral nerves of a few lambs.

The spongy appearance of the white matter was attributed to numerous round or oval, membrane-bound, empty spaces of varying size, occurring independently or in rows, particularly evident along the long axis of myelinated fibres. In sections stained by the LFB-PAS-H method, the myelin sheaths appeared to have been replaced by vacuoles, some of which contained small myelin fragments. Morphologically unaltered, naked axons remained. Spongiform degeneration did not evoke a cellular response, with the exception of animals in which the lesions had progressed to lytic necrosis (*vide infra*).

In 28 lambs, multifocal to focally extensive lytic necrosis was noted in HE- and LFB-PAS-H-stained sections (Fig. 4). In group B, 55% (six out of 11) of positive lambs contained necrotic foci in the brain; in group C, 73% (16 out of 22); and in group D, 40% (six out of 15). The latter included three fetuses from ewes that had died of respiratory disorders between days 111 and 115 of gestation, i.e. 8–10 d after having been dosed.

The lytic necrosis varied in severity and extent. These changes were characterized by microcavitation in which dilated blood vessels, glial processes and axons remained intact. Reactive glia and lipid-filled macrophages (Gitter cells) were abundant, and the necrotic areas were surrounded by areas of spongiform degeneration. In animals where it was difficult to assess whether the spongy degeneration had progressed to necrosis, or where autolysis was advanced, the presence of intracytoplasmic PAS-positive material in macrophages was a useful indicator of myelin breakdown.

Transmission-electron-microscopical lesions

The lesions in the myelin sheaths consisted of multiple intralamellar spaces representing separation at the intraperiod lines (Fig. 5 and 6). The extent of the myelin degeneration varied from one myelin sheath to another and from one bundle of fibres to another. The spaces appeared to occur more often at the middle or external third of the myelin sheath, and the vacuoles infrequently contained myelin debris.

Vacuolated myelin membranes frequently formed large cystic spaces (Fig. 7 and 8). Some of the membranes were ruptured, and collapsed. The extracellular space was dilated and occasionally contained a few thin, membrane-bound vacuoles of varying size, identified as probable extensions of the intramyelinic vacuoles.

The axons were unaltered, although some were compressed by the intramyelinic vacuoles, and the

axolemma was occasionally separated from the myelin sheath. Reactive astrocytes were often encountered. Some revealed fragmentation and disintegration of their processes, and cell bodies and mitochondria were swollen. Oligodendroglia appeared unaffected. The glia limitans consisted of swollen astrocytic end feet.

Abundant macrophages, distended with degenerating myelin and neutral fat, occurred in areas of necrosis. Dilated capillaries and venules were frequently present within cavitated areas.

DISCUSSION

Varying degrees of spongiform degeneration of white matter was present in the brains of all the stillborn and non-viable lambs in this study. The spongy changes were attributed mainly to the presence of vacuoles within myelin sheaths, which sometimes developed into large cystic areas, enlargement of the extracellular space (extracellular oedema) and, to a les-

ser degree, to swelling of astrocytes. In lambs with prominent lesions, spongy degeneration occurred throughout the central nervous system, whereas in mildly affected ones, the lesions had a predilection—firstly for the white matter of the cerebellum and then for that of the cerebrum. In the latter cases, lesions were usually absent in the spinal cord.

The term, spongiform degeneration of white matter, also referred to as status spongiosus or intramyelinic oedema, is derived from the characteristic light microscopical sieve-like appearance of the affected white matter. It has various causes, e.g. treatment of sheep with an overdose of rafoxanide (Prozesky & Pienaar 1977), intoxication of domestic ruminants with large quantities of the plant *Helichrysum argyrosphaerum* (Basson, Kellerman, Albl, Von Maltitz, Miller & Welman 1975), *Stypandra imbricata* toxicosis (Huxtable, Dorling & Slatter 1980), hexachlorophene encephalopathy in mice and baboons (Tripier, Bérard, Toga, Martin-Bouyer, Le Breton & Garat 1981), and hyperammonemia in calves (Cho & Leipold 1977). The

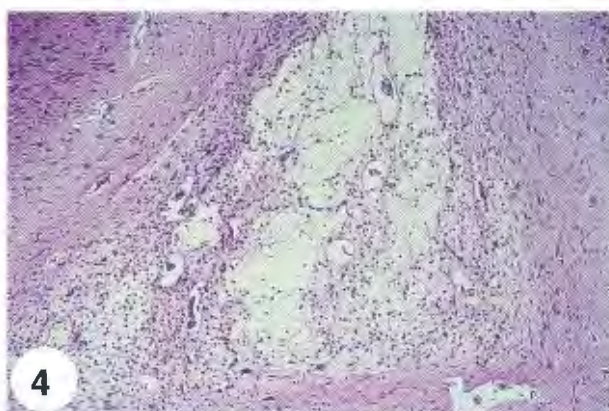
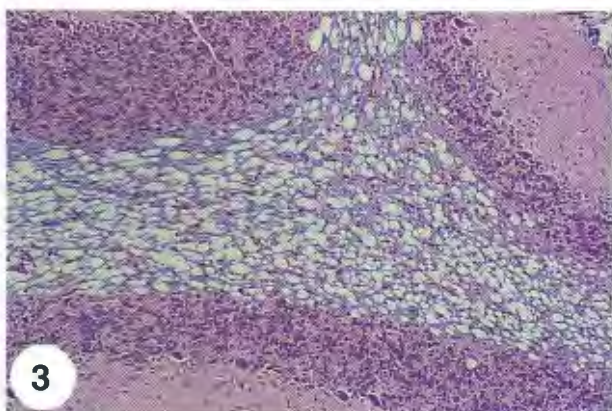
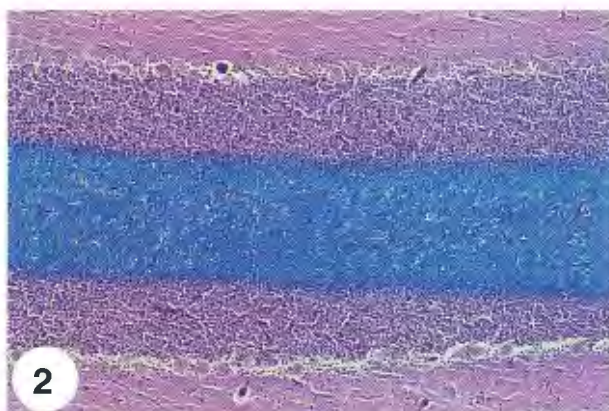


FIG. 1 Two lame lambs born from sheep exposed to *D. maydis*

FIG. 2 Cerebellum of control lamb: Luxol-fast-blue periodic-acid-Shiff haematoxylin

FIG. 3 Spongiform degeneration in the cerebellar white matter of an affected lamb: Luxol-fast-blue periodic-acid-Shiff haematoxylin

FIG. 4 Extensive lytic necrosis in the cerebral white matter of a lamb: haematoxylin and eosin

lesion has also been reported in various spontaneous diseases (Cummings & De Lahunta 1978).

In this study, the myelin lamellae were separated at the intraperiod line. The vacuoles represent a reopening of the extracellular space along the formerly apposed external surfaces of the plasma membranes of oligodendroglia filled with normal extracellular fluid (Davis & Robertson 1991; Huxtable *et al.* 1980). This mechanism can give rise to the formation of vacuoles at multiple levels within the myelin sheath, and multiple loci along an internode.

Under experimental conditions, spongiform degeneration of myelin has been associated with brain oedema, and accounts for the brain swelling which may occur in severe cases (Jubb, Kennedy & Palmer 1993). Depending on the causative agent and the duration of the lesion, spongiform degeneration of myelin may

be associated with structural changes in oligodendroglia (Blakemore 1972). In this study, swelling of astrocytic processes accompanied the myelin vacuolation in the lambs. No morphologic evidence could be found to suggest that the cell bodies of the oligodendroglia were adversely affected.

In the ovine foetus, neuronal multiplication occurs mainly between 40 and 80 d, and glial multiplication between 95 and 130 d of gestation. During these two phases of rapid growth, the foetal brain is apparently particularly vulnerable to toxic or other damage (McIntosh, Baghurst, Potter & Hetzel 1979). Myelination, on the other hand, occurs mainly during the terminal stages of pregnancy and early neonatal period (Patterson, Sweasey & Hebert 1971).

The nature of the CNS lesions in the lambs, and the period of gestation when the foetus is most susceptible to diplodiosis, viz. the second and third trimester

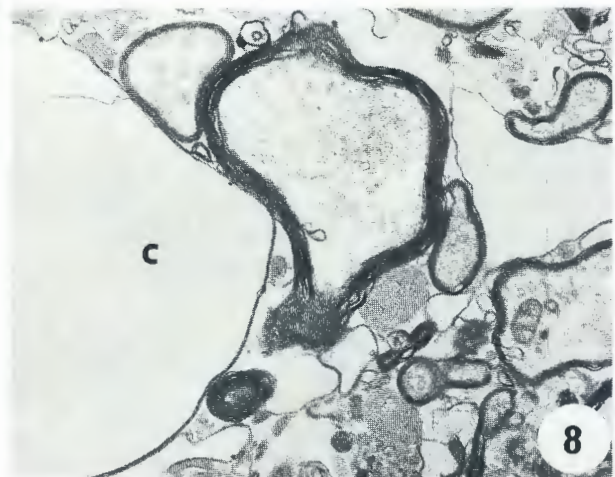
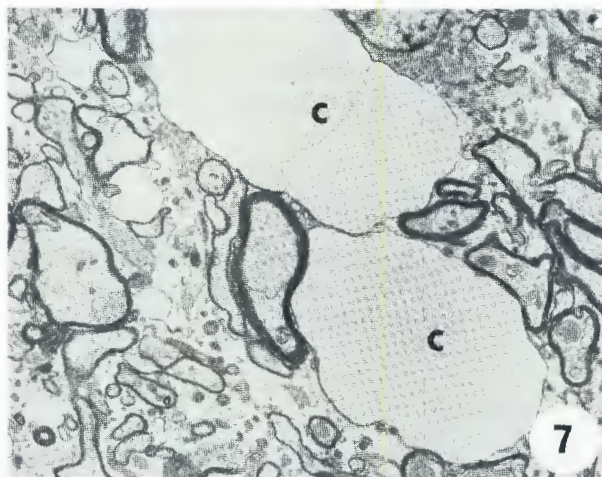
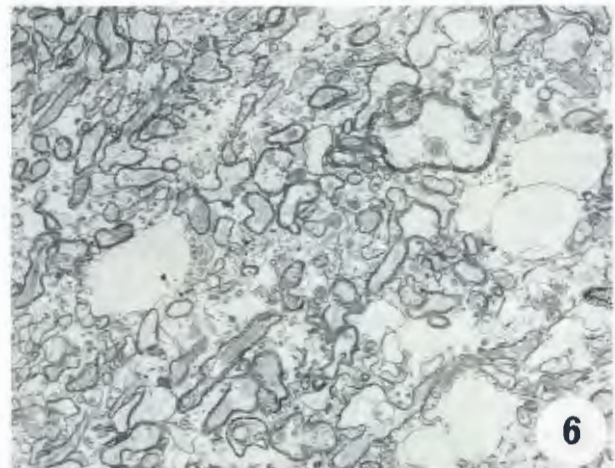


FIG. 5 Myelin lesion represented by a split at the intraperiod line: x 45000

FIG. 6 Low magnification of spongiform degeneration: x 2000

FIG. 7 and 8 Vacuolated myelin membranes frequently formed large cystic spaces (C): x 2000 x 9000

of pregnancy, together with the absence of microscopical detectable lesions in post-natally exposed animals, suggests that the unidentified toxin specifically destabilizes the myelin lamellae of ovine foetuses.

The neurological disorders clinically observed in affected lambs, viz., lameness and ataxia, can possibly be attributed to the severe oedema associated with the myelin lesion. This does not, however, explain the ataxia, paresis, and paralysis in older domestic ruminants which rarely have lesions. Only in exceptional cases, such as adult sheep and cattle that have been paralysed for a protracted period, can mild vacuolation of the white matter be seen (L. Prozesky & T.S. Kellerman 1992, unpublished data) which may be more severe at the cerebral cortico-medullary junction (Kellerman *et al.* 1988).

The cellularity of nerve tissue—particularly of young animals—is extremely variable, and makes it difficult to ascertain whether gliosis accompanied the vacuolar changes in the white matter. Mild to moderate gliosis was, nevertheless, evident in animals in which the spongy changes had progressed to lytic necrosis.

Progression from myelin vacuolation to demyelination has been reported in a number of experimental intoxications, e.g. with isoniazid in dogs (Blakemore, Palmer & Noel 1972), and cuprizone in the mouse (Blakemore 1972), but is infrequently associated with naturally occurring disease.

Depending on the causative agent, spongy degeneration of myelin in the CNS is either reversible or followed by demyelination (Blakemore 1972, Huxtable *et al.* 1980). The highest incidence of lytic necrosis (76% of affected lambs) occurred in group C, where the ewes were exposed to *D. maydis* culture MRC 10400 from day 103 to day 133 of gestation. In two of the latter cases, the lesions were so severe that hydrocephalus ensued. Necrosis was also evident in the cerebrums of foetuses from ewes that had died of respiratory disorders 8–10 d after they had been dosed with culture material. The high incidence of lytic necrosis in lambs of ewes exposed to *D. maydis* in the third trimester of gestation could be related to the high susceptibility of the foetal brain to intoxication at that stage, rather than to the toxicity of a particular strain of the fungus.

Contrary to the situation in lambs, demyelination of peripheral nerves, atrophy, degeneration and necrosis of muscle, and hepatitis were recorded in vervet monkeys exposed to a toxicogenic strain of *D. maydis* (Fincham, Hewlett, De Graaf, Taljaard; Steytler, Rabie, Seier, Venter, Woodroof & Wynchank 1991). No morphologically detectable lesions or nuclear magnetic-resonance-signal alterations of the central white matter, indicative of demyelination, were observed in the monkeys. This further emphasizes the

difference in susceptibility to mycotoxins between species. Spongiform degeneration was observed in the peripheral nerves of some of the lambs; however, this aspect needs to be further investigated.

Fincham *et al.* (1991) suggested that diplodiosis in vervet monkeys was responsible for reduced bio-availability of energy which resulted in a deficiency of structural lipids necessary for the maintenance and production of peripheral myelin.

The classification of diplodiosis in perinatal lambs is not very clear-cut. The predominant pathological feature was vacuolation of myelin, associated in some animals with breakdown of myelin and preservation of axons. According to Jubb *et al.* (1993) the term demyelination should be restricted to lesions in which the myelin sheath is selectively injured, leaving the axons naked but intact. In the light of the extent of the myelin vacuolation in the majority of affected lambs, it is suggested that diplodiosis is classified under spongiform myelinopathies.

Diplodiosis now joins the list of mycotoxicoses associated with abnormal foetal development. Mycotoxins which have a detrimental effect on the developing embryo or foetus, include aflatoxins (Verrett, Marliac & McLaughlin 1964), ochratoxins (Still, MacKlin, Ribelin & Smalley 1971), mycotoxins produced by *Penicillium* spp. (Hood, Innes & Hayes 1973), *Aspergillus* spp. (Abramovici 1977) and *Fusarium* spp. (Hood, Kuczuk & Szczech 1976). With the exception of diplodiosis, however, mycotoxicoses are not considered to be an important cause of reproductive failure of livestock.

The next objective in research on diplodiosis must be the isolation of the neurotoxic principle(s). Identification of this principle is a prerequisite for the chemical diagnosis of diplodiosis and the development of an assay for the toxicity of mouldy maize. Knowledge of this principle will also open the door for the investigation of the pathophysiology of diplodiosis, especially with regard to the effect of the toxin on foetal myelin formation.

ACKNOWLEDGEMENTS

We are indebted to the staff of the Divisions of Pathology, Electron microscopy and Toxicology for competent technical assistance.

REFERENCES

- ABRAMOVICI, A. 1977. Mycotoxins and abnormal fetal development. *Contributions to Microbiology and Immunology*, 3:81–94.
- BASSON, P.A., KELLERMAN, T.S., ALBL, P., VON MALITZ, L.J.F., MILLER, E.S. & WELMAN, WILHELMINA G. 1975. Blindness and encephalopathy caused by *Helichrysum argyrosphaerum* D.C. (Compositae) in sheep and cattle. *Onderstepoort Journal of Veterinary Research*, 42:135–147.

- BLAKEMORE, W.F. 1972. Observations on oligodendrocyte degeneration, the resolution of status spongiosus and remyelination in cuprizone intoxication in mice. *Journal of Neurocytology*, 1:413–426.
- BLAKEMORE, W.F., PALMER, A.C. & NOEL, P.R.W. 1972. Ultrastructural changes in Isoniazid-induced brain oedema in the dog. *Journal of Neurocytology*, 1:263–278.
- CHO, D.Y. & LEIPOLD, H.W. 1977. Experimental spongy degeneration in calves. *Acta Neuropathologica*, 39:115–127.
- CUMMINGS, J.F. & DE LAHUNTA, A. 1978. Hereditary myelopathy of Afghan hounds, a myelinolytic disease. *Acta Neuropathologica*, 42:173–181.
- DAVIS, R.L. & ROBERTSON, D.M. 1991. *Textbook of Neuro-pathology*, 2nd ed. Baltimore: Williams & Wilkins.
- FINCHAM, J.E., HEWLETT, R., DE GRAAF, A.S., TALJAARD, J.J.F., STEYTLER, J.G., RABIE, C.J., SEIER, J.V., VENTER, F.S., WOODROOF, C.W. & WYNCHANK, S. 1991. Mycotoxic peripheral myelinopathy, myopathy, and hepatitis caused by *Diplodia maydis* in vervet monkeys. *Journal Medical Primatology*, 20:240–250.
- HOOD R.D., INNES, J.E. & HAYES, W.A. 1973. Effects of rubratoxin B on prenatal development in mice. *Bulletin Environmental Contamination and Toxicology*, 10:200–207.
- HOOD, R.D., KUCZUK M.H. & SZCZECHE, G.M. 1976. Prenatal effects in mice of mycotoxins in combination: Ochratoxin A and T₂ toxin. *Teratology*, 13:25A.
- HUXTABLE, C.R., DORLING, P.R. & SLATTER, D.H. 1980. Myelin oedema, optic neuropathy and retinopathy in experimental *Stypandra imbricata* toxicosis. *Neuropathology and Applied Neurobiology*, 6:221–232.
- JUBB, K.V.F., KENNEDY, P.C. & PALMER, N. 1993. *Pathology of domestic animals*, 4th ed. London: Academic Press.
- KELLERMAN, T.S., RABIE, C.J., VAN DER WESTHUIZEN, G.C.A., KRIEK, N.P.J. & PROZESKY, L. 1985. Induction of diplodiosis, a neuromycotoxicosis, in domestic ruminants with cultures of indigenous and exotic isolates of *Diplodia maydis*. *Onderstepoort Journal of Veterinary Research*, 52:35–42.
- KELLERMAN, T.S., COETZER, J.A.W. & NAUDÉ, T.W. 1988. *Plant poisonings and mycotoxicoses of livestock in southern Africa*. Cape Town: Oxford University Press.
- KELLERMAN, T.S., PROZESKY, L., SCHULTZ, R. ANITRA, RABIE, C.J., VAN ARK, H., MAARTENS, B.P. & LÜBBEN, AN-
NELIE 1991. Perinatal mortality in lambs of ewes exposed to cultures of *Diplodia maydis* (= *Stenocarpella maydis*) during gestation. *Onderstepoort Journal of Veterinary Research*, 58: 297–308.
- MARGOLIS, G. & PICKETT, J.P. 1956. New applications of the Luxol fast blue myelin stain. *Laboratory Investigations*, 5:459–474.
- MCINTOSH, G.H., BAGHURST, KATRINE I., POTTER, B.J. & HETZEL, B.S. 1979. Foetal brain development in the sheep. *Neuropathology and Applied Neurobiology*, 5:103–114.
- MITCHELL, D.T. 1918. A condition produced in cattle feeding on maize infected with *Diplodia zeae*. *Report on Veterinary Research, Union of South Africa*, 7 & 8:425–437.
- PATTERSON, D.S.P., SWEASEY, D. & HEBERT, C. NANCY 1971. Changes occurring in the chemical composition of the central nervous system during foetal and post-natal development of the sheep. *Journal of Neurochemistry*, 18:2027–2040.
- PROZESKY, L. & PIENAAR, J.G. 1977. Amaurosis in sheep resulting from treatment with rafoxanide. *Onderstepoort Journal of Veterinary Research*, 44:257–260.
- RABIE, C.J., KELLERMAN, T.S., KRIEK, N.P.J., VAN DER WESTHUIZEN, G.C.A. & DE WET, P.J. 1985. Toxicity of *Diplodia maydis* to farm and laboratory animals. *Food and Chemical Toxicology*, 23:349–353.
- STILL, P.E., MACKLIN, A.W., RIBELIN, W.E., & SMALLEY, E.B. 1971. Relationship of ochratoxin A to fetal death in laboratory and domestic animals. *Nature*, 234:563–564.
- TRIPPIER, M.F., BÉRARD, M., TOGA, M., MARTIN-BOUYER, G., LE BRETON, R. & GARAT, J. 1981. Hexachlorophene and the central nervous system. *Acta Neuropathologica*, 53:65–74.
- VERRETT, J.M., MARLIAC, J.P. & MCLAUGHLIN, J. 1964. The use of chicken embryo in the assay of aflatoxin toxicity. *Journal of the Association of Agricultural Chemistry*, 47:1003–1006.