

**LAPAROSCOPIC TESTICULAR ARTERY LIGATION  
AS AN ALTERNATIVE TO CASTRATION  
IN DONKEYS**

**Peter H Briggs**

**Promoter:** Prof. A Olivier-Carstens  
**Co-Promoter:** Prof. RD Gottschalk

Submitted to the Faculty of Veterinary Science, University of Pretoria, in partial fulfilment of the requirements for the degree M Med Vet (Eq. Surg.)



## DEDICATION

To my wife, Shelley and my children Candice and Ryan,  
for their love and support

## TABLE OF CONTENTS

<b>TITLE PAGE</b> .....	<b>i</b>
<b>DEDICATION</b> .....	<b>ii</b>
<b>TABLE OF CONTENTS</b> .....	<b>iii</b>
<b>LIST OF TABLES</b> .....	<b>iv</b>
<b>SUMMARY</b> .....	<b>v</b>
<b>ABSTRACT</b> .....	<b>vii</b>
<b>ACKNOWLEDGEMENTS</b> .....	<b>viii</b>
<b>ABBREVIATIONS</b> .....	<b>x</b>
<b>CHAPTER 1</b> .....	<b>11</b>
<b>INTRODUCTION</b> .....	<b>11</b>
<b>CHAPTER 2</b> .....	<b>14</b>
<b>LITERATURE REVIEW</b> .....	<b>14</b>
2.1 Anatomy .....	14
2.2 Laparoscopy .....	21
2.3 Laparoscopy and its Uses .....	22
2.4 Advantages of Laparoscopy .....	23
2.5 Disadvantages of Laparoscopy .....	23
2.6 Complications of Laparoscopy .....	23
2.7 Aims of this Study .....	24
<b>CHAPTER 3</b> .....	<b>26</b>
<b>MATERIALS AND METHODS</b> .....	<b>26</b>
3.1 Subjects .....	26
3.2 Husbandry Practices .....	26
3.3 Experimental Design .....	27
3.4 Post-Operative Care .....	30
<b>CHAPTER 4</b> .....	<b>32</b>
<b>RESULTS</b> .....	<b>32</b>
<b>CHAPTER 5</b> .....	<b>45</b>
<b>DISCUSSION</b> .....	<b>45</b>
<b>CHAPTER 6</b> .....	<b>47</b>
<b>CONCLUSIONS</b> .....	<b>49</b>
<b>REFERENCES</b> .....	<b>50</b>

## LIST OF TABLES AND FIGURES

<b>TABLE 1: Experimental Donkeys .....</b>	<b>35</b>
<b>TABLE 2: Time Period between Laparoscopy and Testicular Removal .....</b>	<b>36</b>
<b>TABLE 3: Histopathological Findings of the Testes and Epididymes .....</b>	<b>37</b>
<b>TABLE 4: Filshie Clip Removal .....</b>	<b>38</b>
<b>FIGURE 1: Filshie Clips.....</b>	<b>39</b>
<b>FIGURE 2: Filshie Clip Applicator and Filshie Clip .....</b>	<b>40</b>
<b>FIGURE 3: Laparoscopic Portal Sites .....</b>	<b>41</b>
<b>FIGURE 4: Tubular Ligation by Filshie Clip .....</b>	<b>42</b>
<b>FIGURE 5: Diagram demonstrating Filshie Clip position on the testicular artery in the dorsal aspect of the peritoneal cavity .....</b>	<b>43</b>

## SUMMARY

Castration is one of the most frequently performed surgical procedures in equine practice. Although castration is a relatively simple procedure in the hands of an experienced equine practitioner, complications are not uncommon. Some of these complications such as haemorrhage and eventration may be life threatening. The aim of this study was to investigate the viability of laparoscopic testicular artery ligation as an alternative to the more conventional methods of castration and their associated complications.

Twelve intact male donkeys varying in ages from 5 months to 13 years were used in this study. Ten donkeys underwent laparoscopic testicular artery ligation. This was performed with the donkeys standing in stocks and sedated with detomidine and butorphanol tartrate. Both left and right paralumbar fossae were appropriately prepared for surgery. Local anaesthesia was administered in an inverted L pattern at two portal sites. The first site was made midway between the ventral aspect of the tuber coxa and the first rib and the second site was made approximately 50mm ventral to the first. A skin incision was made at each site and a guarded trocar-cannula was inserted through each incision into the abdominal cavity. The laparoscope was inserted via the ventral portal into the abdomen. The testicular artery was then identified within the mesorchium in the dorsal aspect of the body wall. The artery was grasped with atraumatic laparoscopic forceps introduced through the central instrument portal of the laparoscope and clamped with a Filshie clip using a Filshie clip applicator, which was inserted into the abdomen via the dorsal portal. The procedure was then repeated on the opposite side.

The ten donkeys which underwent laparoscopic assisted testicular artery ligation were unilaterally castrated on two separate occasions. These donkeys were castrated using an acceptable open castration technique. The first testes were removed at a specific time period after testicular artery ligation, while the second testes were all removed on the same day 9 months after the first group of donkeys underwent laparoscopic assisted testicular artery ligation. The remaining two donkeys which did not undergo testicular artery ligation were castrated using an acceptable open castration technique. Both testes from each of these donkeys were removed on the same day and were used as controls.

All the testes removed, excluding one testis which was lost to the study, were evaluated histologically.

A total of twenty three testes were examined. Four testes were used as controls. Seven testes showed signs of ischaemic necrosis. Six testes showed seminiferous tubules in varying stages of degeneration and atrophy with no signs of normal tissue. Three testes showed 60-70% of seminiferous tubular atrophy with some active tubules still remaining while three of the testes showed no abnormalities and were histologically normal. One of the testes was accidentally misplaced at *post mortem* due to human error.

The laparoscopic technique used was relatively quick and simple to perform with minimal complications. The Filshie clips were an effective device for ligation of the testicular artery when correctly applied. Avascular necrosis of the testicular tissue was not successful in all the subjects. This method has promise but requires further research in a greater number of subjects.

## ABSTRACT

The aim of this study was to investigate the viability of laparoscopic testicular artery ligation as an alternative to the more conventional castration methods in equids.

Twelve intact male donkeys varying in age from 5 months to 13 years were used in this study. Two of these donkeys were castrated by means of an open technique. The remaining donkeys underwent testicular artery ligation under laparoscopic guidance. Ligation of the testicular artery was achieved by application of Filshie clips under laparoscopic visualisation. This was performed with the donkeys standing in stocks and sedated with a combination of detomidine hydrochloride and butorphanol tartrate.

The ten donkeys which underwent testicular artery ligation were unilaterally castrated using an acceptable open castration technique on two separate occasions. The first testes were removed at a specific time period after testicular artery ligation, while the second testes were all removed on the same day 9 months after the first group of donkeys underwent laparoscopic assisted testicular artery ligation. The remaining two donkeys which acted as controls underwent a standard open bilateral castration procedure both testes being removed on the same day. All the testes removed, excluding one testis lost to the study, were evaluated histologically. Four testes were used as controls. Thirteen testes showed histological signs of ischaemic necrosis, degeneration and/or atrophy. Three testes showed histological tubular degeneration and atrophy as well as the presence of some normal tissue. The remaining three testes were histologically unchanged. One of the testes was accidentally misplaced at *post mortem* due to human error.

Avascular necrosis of the testicular tissue was not successful in all the subjects. This technique shows promise but further research is required.

## ACKNOWLEDGEMENTS

Without the assistance of a large number of people, these studies and this document would not have been possible.

They are as follows:

Dr Lorna Bolton and Dr Emily Lane of the Department of Pathology, University of Pretoria, for processing and interpreting the histopathological results

My wife Shelley, for typing this manuscript

Prof. Ann Carstens, my promoter, for her support, guidance and unfailing enthusiasm

Mr. Cocolus of Triton Enterprises for donating the Filshie clips and supplying the Filshie clip applicator

Family, friends and colleagues for their support and encouragement

Prof. Roy Gottschalk, my co-promoter, for his friendship, unselfish sharing of knowledge and expertise and his continual guidance and support

Johannes and Daniel for assisting with the donkeys

Dr David Gerber for proof reading and all his valuable assistance with this project

Dr Kenneth Joubert for proof reading and assistance with the descriptive statistics

Grant Langley for assisting me with the husbandry of the donkeys



Sister Hildegard Mentz, Sister Lynne McHardy, Sister Bessie Kock and Sister Janet Smith for their nursing assistance

Mrs Denise Marais and Mrs Lettie Oberholzer for secretarial support

Dr Scott Palmer, New Jersey Clinic, New Jersey, PA for agreeing to act as an external examiner for this dissertation

The University of Pretoria, for allowing the time and supplying the experimental animals and the financial backing for this study

Prof. Sybrand van den Berg, for his knowledge, patience and wise words which were always appreciated

## ABBREVIATIONS

ad lib	ad libitum
CO <sub>2</sub>	carbon dioxide
e.g.	for example
<i>et al.</i>	and others
g	grams
i.e.	that is
kg	kilograms
ℓ	litres
L	left
min	minutes
mm	millimeters
mmHg	millimeters of mercury
mℓ	milliliters
no.	number(s)
R	right
<i>vice versa</i>	the other way round

## CHAPTER 1

### INTRODUCTION

Castration is one of the most frequently performed surgical procedures in equine practice.

Horses are usually castrated to eliminate stallion-like behaviour rendering the horse more docile and manageable. Some other indications for castration include tumours, orchitis, scrotal hernia and testicular trauma, to name a few<sup>21,22,52</sup>.

Traditionally, horses are castrated between one and two years of age. The age of castration is optional. Some owners prefer to delay castration until the horse is over two years of age so that masculine traits develop more fully<sup>113</sup>. Others prefer to castrate when the horse is just a few months old to avoid the nuisance of masculine behaviour<sup>3,21,22,52</sup>. Methods of castration described are: open, closed and semi-closed<sup>52,113,116</sup>. The open technique is the most frequently used technique in equine practice and is generally performed in the standing horse with the aid of chemical restraint<sup>113,116</sup>. This method is best suited for field use, but has higher risk of post-operative infection compared with the closed and semi-closed techniques<sup>47</sup>. The closed and semi-closed techniques have the disadvantage of requiring general anaesthetic, a risk in itself, as well as aseptic theatre facilities, advanced expertise and added expense<sup>21,52,113</sup>.

Although castration is a relatively simple procedure in the hands of an experienced equine practitioner, complications are not uncommon. These complications may range from simple swelling and oedema, to life threatening complications such as haemorrhage, eventration and peritonitis<sup>21,52,63,73,76,82,98,99</sup>.

The purpose of this study was to investigate the viability of laparoscopic testicular artery ligation as an alternative to the more conventional methods of castration and their associated complications in the equine.

Laparoscopic procedures in general have decreased mortality and morbidity, and allow a rapid return to exercise which is beneficial to all horses<sup>56,79</sup>. The life threatening complications associated with open castration and the complications associated with general anaesthesia are eliminated with the use of laparoscopic techniques<sup>38,40,46,80</sup>. However, laparoscopy is not without its risks and complications. Haemorrhage at the portal, surgical and biopsy sites has been reported<sup>30,40,46,86,103</sup>. Infection has been reported but is rare<sup>46,103</sup>. Improper insertion of the trocar may cause damage to the viscera, the spleen and left kidney. Mild transient emphysema at the portal sites is not uncommon and is usually self limiting<sup>76,103</sup>.

Ligation of vessels following isolation and transection is a time honoured method of controlling haemorrhage during surgical procedures. Well placed ligatures ensure haemostasis of damaged/or transected vessels. Ligation of vessels in laparoscopy may be achieved by using endoscopic stapling devices, Endoloops and extracorporeal knot tying techniques<sup>9,46,107</sup>. The endoscopic stapling devices although an excellent means of achieving haemostasis especially for larger vessels, are cost prohibitive<sup>46,107</sup>. Endoloops, which are a pretied suture loop with a sliding knot, can be used to ligate blood vessels. They are particularly useful for well isolated pedicles such as cryptorchid testes and ovaries<sup>9,44,46,107</sup>. When it is required to pass a ligature around a vessel that is not free from surrounding tissue, an extracorporeal knot is used<sup>46,107</sup>. This knot is tied outside of the body cavities and advanced to the tissue site with the aid of a knot introducer. Various types of knots are used, for example, the Roeder knot, the modified Roeder knot, the surgeon's knot and the fisherman's knot<sup>46,56,107</sup>. Choice of knot is dependent on the surgeon's preference and the requirement of the knot.

In this study, Filshie clips (Figure 1) were chosen for their ability to lock on to the blood vessels once applied and thus minimising chances of migration<sup>55,108</sup>. Filshie clips are used in human female sterilisation. Female patients are sterilised by tubal application of Filshie clips<sup>4,19,20,36,55,83</sup>. The Filshie clips are made up of titanium with a silicone rubber lining. They are 4mm in width and 12.7mm in length<sup>36,37,83</sup>. Using the special Filshie clip applicator (Figure 2), the clip locks on to the fallopian tubes when occluded. As the tissue atrophies, the silicone expands thus preventing recannulisation and minimises clip migration<sup>36,37,55,83,108</sup>.

From an economic point of view, the technique used in this study is more expensive than the routine standing open castration technique, but compares favourably with the closed and semi-closed techniques which require a general anaesthesia. The Filshie clips used in this study compared favourably with the cost of Endoloops and are less expensive than using stapling devices.

Application of the Filshie clips to incorporate the testicular artery in its entirety was not without difficulty. A modification of the technique by ligation of the entire vascular bundle using an extracorporeal knot could be considered. This technique while more technically difficult may provide more reliable vascular occlusion and prevent potential venous return. This technique may be more time consuming but would be more economical.

## CHAPTER 2

### LITERATURE REVIEW

#### 2.1 Anatomy

##### 2.1.1 Blood Supply of the Testes

The testes are supplied by the testicular artery<sup>3,26,52,66,71,101,106,110,122</sup>. In the horse the testicular artery (*arteria testicularis*) originates from the abdominal aorta at the level of the fourth lumbar vertebrae. The *arteria testicularis* initially runs ventrally over the dorsal body wall and then passes along the lateral abdominal wall in the proximal mesorchium, the *plica vasculosa*, to the internal inguinal ring where it becomes part of the spermatic cord. It joins the testis at its head (*extremitas capita*). Close to the *extremitas capita* the *arteria testicularis* gives off the *ramus epididymales*. The *arteria iliaca interna* gives rise to the *arteria pudenda interna* from which the *arteria umbilica* originates. This gives rise to the *arteria ductus deferentis*. It supplies the *ductus deferens* while following it towards the tail of the epididymis where it anastomoses with the *ramus ductus deferentis* from the epididymal rami of the testicular artery. The *arteria prostatica* arises from the *arteria pudenda interna* from which the *arteria umbilica* originates. This gives rise to the *arteria ductus deferentis*. It supplies the *ductus deferens* while following the *ductus deferens* towards the tail of the epididymis where it anastomoses with the *ramus ductus deferentis* from the epididymal rami of the *arteria testicularis*. The *arteria prostatica* arises from the *arteria pudenda interna* in the region of the greater sciatic notch cranial to the ischiatic spine. It runs laterally along the pelvic peritoneum in the direction of the prostate and gives off the *rami ductus deferentis* which anastomoses with the *arteria ductus deferentis* before the latter anastomoses with the *ramus ductus deferentis* from the epididymal rami of the *arteria testicularis*<sup>46,101,106</sup>.

The *vena testicularis* arises from the caudal vena cava and it runs parallel with the *arteria testicularis* in the *plica vasculosa* to the internal inguinal ring. Surrounding the *arteria testicularis* it forms the *plexus pampiniformis* of the spermatic cord. The *vena testicularis* drains the epididymis by the *rami epididymales* which, together with the *rami ductus deferentis* of the *vena prostatica*, participate in the vascularisation of the ductus deferens.

The *vena prostatica* originates from the *vena pudenda interna* and it gives off the *ramus ductus deferentis*. The origin of the vein of the *ductus deferens* from the external iliac is not at the same level as the one of the artery. Thus the area drained by the vein of the *ductus deferens* is supplied by various arteries<sup>46,101,106</sup>.

No anatomical publications could be found that indicates that the blood supply of donkeys' testes differ from that described in stallions.

### 2.1.2 Complications of Castration

The most common complications of castration in the equine include: excessive haemorrhage; infection; eventration; oedema and fly strike<sup>47,61,62,73,75,82,98,99,103,119</sup>. Less common complications include: unaltered behaviour; hydrocoele; varicocoele; peritonitis; penile trauma; penile paralysis; anaesthetic mortality and morbidity and injuries to personnel during the procedure<sup>21,47,61,62,73,75,82,98,99,103,118,119</sup>.

With the exception of severe haemorrhage, peritonitis and eventration, the majority of castration complications are not considered life threatening<sup>75</sup>.

Some of these complications are discussed further.

#### 2.1.2.1 Haemorrhage

Cases of post castration haemorrhage are primarily a result of failure to achieve haemostasis<sup>75,82</sup>. Haemorrhage may be immediate or delayed up to several days<sup>62,75</sup>. Haemorrhage may be minor or severe enough to be life threatening<sup>62,75,82</sup>. Significant post operative haemorrhage usually originates from the testicular artery<sup>75,82,99</sup>. Other sources of haemorrhage include the scrotal skin, the deferent vessels or large pudendal vessels damaged by over-zealous dissection in the inguinal area<sup>75,99</sup>.

Haemorrhage may occur when emasculators are applied incorrectly or if defective or inferior emasculators are used<sup>63,82</sup>. The most common error with the use of emasculators is reverse application so the distal stump is crushed and the proximal stump is

transected<sup>63,75,82</sup>. Other errors include; the positioning of the emasculator on an angle rather than perpendicular on the cord and cutting the artery tangentially, applying the emasculator to a spermatic cord that is under tension, or failing to apply proper instrument maintenance to ensure adequate function<sup>63,75,82,99</sup>.

A small amount of haemorrhage is to be expected using the traditional open method of castration in which haemostasis is achieved with the emasculator and scrotal incisions are left open for drainage and healing by second intention<sup>75,99</sup>. This minor haemorrhage will usually cease within ten to fifteen minutes if the horse is allowed to stand quietly but if active haemorrhage continues the scrotum and stumps of the spermatic cord should be examined to locate the source<sup>75,82,99</sup>.

Serious life threatening haemorrhage may not be obvious in rare cases in which the spermatic cord retracts proximally in such a way that haemorrhage from the testicular artery may enter the abdomen and go undetected in the initial post operative period. In this situation, horses may lose a substantial amount of blood in the several hours that pass after surgery before blood appears in the open scrotum. The first outward signs exhibited by the horse may be hyperpnoea. Other clinical signs of which the veterinarian should be aware which may indicate severe blood loss includes tachycardia, pale mucous membranes, weakness and/or ataxia, weak thready pulse and poor jugular distention<sup>63</sup>.

#### **2.1.2.2 Eventration**

Eventration; the protrusion of abdominal contents from a castration wound is regarded as the most serious complication of castration and is a life threatening complication and one which demands immediate attention<sup>21,61,62,75,82,119</sup>. Eventration typically occurs within the first twenty four hours after surgery. Some cases however have been reported up to six days post operatively<sup>63,75,82,99</sup>. The offending tissues are usually the small intestine and omentum which may prolapse through the vaginal ring and scrotal incision<sup>61,62,75,82,99</sup>. In one study of visceral prolapse following castration, 33% of the cases involved the omentum and 67% involved the small intestine<sup>62,75</sup>.

In one study, eventration was reported in 3% of 371 horses that were castrated. More



recently an incidence of 0.4 to 0.8% was reported for eventration after castration in larger groups of horses<sup>61,62</sup>. Fortunately eventration occurs infrequently. Initial studies sited 72.6% mortality for equine patients with eventration; however, more recent studies report a substantially lower mortality rate (15%) for horses in which the condition was recognised early and appropriate therapeutic measures were taken<sup>63</sup>.

The causes of eventration remain speculative. Some factors believed to be involved include a pre-existing but undetected inguinal hernia especially of the foal and of horses of pre-disposed breeds (e.g. Standardbred)<sup>99</sup>. Increased intra-abdominal pressure, position of the horse during surgery (i.e. dorsal or lateral recumbency) and size of vaginal ring have also been incriminated in the development of eventration<sup>63</sup>. Eventration has also occurred in some cases where the scrotal wound was closed primarily but the vaginal tunic had not been closed<sup>63,75</sup>.

### **2.1.2.3 Infection**

Infection associated with castration may become clinically evident as early as a few days post-operatively or as late as months or years after surgery. Wound infection of the scrotum usually remains localised<sup>62,102</sup>. Infection of the spermatic cord is an uncommon complication of castration that can occur from extension of scrotal infection or from a contaminated emasculator or ligature<sup>62,75</sup>. Infection of the spermatic cord (septic funiculitis) with streptococcal organisms is commonly referred to as champignon<sup>47,62,75</sup>. Champignon has frequently been associated with ligatures placed on the spermatic cord<sup>75</sup>. These ligatures act as a nidus for persistent infection. Persistent, chronic spermatic cord infection is referred to as scirrhus cord and is usually associated with a low-grade staphylococcal infection<sup>47,62,75</sup>. Clinically it may be difficult to distinguish scirrhus cord from champignon<sup>62</sup>.

Factors such as inadequate drainage, lack of exercise, retained clots, contamination, foreign bodies, excessive swelling and poor surgical technique increase the occurrence of post operative wound infection<sup>75,82</sup>. The most common surgical faults encountered include incorrect incision sites, too small scrotal incisions and over robust tissue handling<sup>75</sup>. More severe infections may become established either because a large number of bacteria were introduced into the wound due to poor technique and/or dirty surroundings<sup>63,75,99</sup>.

#### **2.1.2.4 Peritonitis**

Although peritoneal inflammation occurs commonly following castration, bacterial peritonitis is a rare complication<sup>73,99</sup>. Because the vaginal and peritoneal cavities of the horse communicate, subclinical, non-septic peritonitis occurs in many horses following castration<sup>82,98,99</sup>. Septic peritonitis generally develops secondarily to an infection involving the spermatic cord<sup>98</sup>. Clinical signs of depression, fever, anorexia, colic, weight loss after castration may be strongly suggestive of peritonitis<sup>82,98,99</sup>.

#### **2.1.2.5 Oedema**

The most common complication of castration is oedema, causing swelling of the scrotum and prepuce<sup>62,75,102</sup>. Some degree of post operative swelling is normal and is therefore not considered a complication<sup>62,75,99,102</sup>. In an uncomplicated case, oedema peaks three to six days after surgery and usually recedes nine days after surgery<sup>21,62,75</sup>. Although post operative oedema rarely poses a life threatening crisis, it can lead to considerable discomfort for the horse and concern for the owner<sup>21,62,99</sup>. Extensive swelling of the surgical site is usually the result of inadequate drainage of the wound caused by a lack of post operative exercise, obstruction of drainage by blood clots, too small scrotal incisions, incorrect incision sites and excessive surgical trauma<sup>62,75</sup>. This swelling may lead to secondary problems such as phimosis, impaired urination, paraphimosis and cellulitis or it may indicate infection or even leakage of urine from urethral penetration<sup>21,62</sup>.

#### **2.1.2.6 Hydrocoele**

Hydrocoele is an accumulation of fluid in the vaginal tunic<sup>63,75,99,102</sup>. This condition is believed to result from failure to resect an adequate amount of the vaginal tunic during the open method of castration or by not resecting enough of the vaginal tunic and spermatic cord in the closed or semi-closed techniques of castration<sup>63,75,99</sup>. A hydrocoele usually develops slowly and may not be noticed until a few months after castration<sup>75</sup>. A hydrocoele does not adversely affect the horse but can effect resale value as the horse may appear to still have a testis<sup>75</sup>.

### **2.1.2.7 Penile Paralysis**

Problems associated with the penis are not immediately life threatening but can be difficult and frustrating to manage and can eventually result in death<sup>62</sup>. When penile paralysis occurs as a complication of castration, excessive oedema, iatrogenic trauma, wound infection or use of phenothiazine-derivative tranquilisers are related to its occurrence<sup>62,75,99</sup>. Iatrogenic trauma occurs when lay persons or inexperienced veterinarians attempt to castrate a horse. Prevention therefore lies in education of owners and adequate training of veterinarians<sup>62,75</sup>.

### **2.1.2.8 Penile Trauma**

Penile trauma including incisions into the corpus cavernosum penis or urethra and penile amputation are unlikely complications of castration<sup>75,99</sup>. However, when lay persons or inexperienced veterinarians attempt to perform equine castration, these complications may be encountered<sup>75,99</sup>. Damage to the penile fascia can result in paraphimosis and an incision into the urethra may result in a urethral stricture or fistula<sup>62,99</sup>.

### **2.1.2.9 Unaltered Stallion-like Behaviour**

Castration does not always eliminate objectionable stallion-like behaviour<sup>99</sup>. Geldings that display stallion-like behaviour are sometimes referred to as 'proud cut' or false rigs<sup>21,99</sup>. Alleged causes of false rigs include incomplete removal of epididymal tissue, heterotopic testicular tissue and production of high concentrations of androgens by the adrenal cortex and psychic causes. The epididymis contains no cells capable of producing androgens and therefore a portion left with the horse is probably incapable of causing stallion-like behaviour<sup>99</sup>. The presence of heterotopic testicular tissue in horses has not been demonstrated and the production of androgens by the adrenal cortex has never been shown to be responsible for stallion-like behaviour in geldings<sup>99</sup>. One case however did suggest that remnants of the spermatic cord may contain testosterone-producing cells. Preoperatively, this horse had a history of routine castration, yet he demonstrated stallion-like behaviour and had resting levels of testosterone that were abnormally elevated for a gelding. Administration of HCG resulted in a two fold increase in the levels of baseline serum testosterone. On surgical exploration, no abdominal testicles were found. The

surgeon found considerable length of spermatic cord in both inguinal rings which were subsequently removed. Postoperatively, histological evaluation of the tissue removed found no tissue capable of producing testosterone. However this horse's stallion-like behaviour was eliminated postoperatively and follow-up baseline and HCG response testing indicated normal testosterone levels for a gelding. (Personal communication Dr S Palmer, New Jersey Clinic, New Jersey, PA). Objectionable stallion-like behaviour following castration is possibly psychic in origin and is part of the normal social interaction between horses<sup>99</sup>. Continued stallion-like behaviour can occur following improper castration of a partial abdominal cryptorchid stallion<sup>21,99</sup>. Owners should be forewarned about the incidence of continued stallion-like behaviour following castration so that undeserved blame for performing an improper castration is avoided<sup>99</sup>. The excised testes and epididymes may be shown to the owner to eliminate the possibility of doubt by the owner that the horse was properly castrated in case the horse continues to show stallion-like behaviour<sup>99</sup>.

In this study, blood samples were taken to measure baseline serum testosterone levels before and after laparoscopic assisted testicular artery ligation. These results will be published at a later date in a separate publication.

#### **2.1.2.10 Fly Strike**

Fly strike is a possible complication after performing castration particularly in the warmer summer months. Prevention by regular application of a fly repellent around the wound and diligent wound care is essential<sup>102</sup>.

## 2.2 Laparoscopy

### 2.2.1 Brief History of Laparoscopy

Laparoscopy is the procedure that involves using a telescope to view the abdominopelvic cavity. Laparoscopy is derived from the Greek words, lapara, meaning flank and skopein, meaning to examine<sup>86</sup>. The development of laparoscopic techniques in animals is historically unique. Unlike biomedical techniques, which were first perfected in animal subjects and later applied to humans, laparoscopy had its origins in human application<sup>46,86</sup>. Only in the last decade have these techniques been applied to a wide variety of animal species for research, diagnostic evaluation and surgical procedures. The broad field of endoscopy of which laparoscopy is a specialised component, had its earliest beginnings with the light transmitter developed by Philip Bozzini in 1804. By the mid-1850s Desormeaux had developed an endoscope for examining the urinary bladder<sup>46</sup>. Jacobaeus is credited with the first use of the term laparoscopy to describe the technique of endoscopy in the peritoneal cavity<sup>46,80</sup>. Although Kelling did not use the term to refer to his own work, his earlier use of the techniques in dogs would establish him as the “father of veterinary laparoscopy”<sup>46,80,124</sup>.

With the background of extensive human clinical studies, it has been relatively easy to adapt laparoscopic techniques for use in animals<sup>46,86</sup>. One of the first reports of laparoscopy in animals was conducted in dogs in the early 1900's<sup>46,80,124</sup>. Oindoff (1920) reported on the successful development of endoscopic techniques in animals but did not specify the species used<sup>46</sup>. The increased desire in the 1950s and 1960s for a better understanding of reproductive function in animals stimulated interest in developing a means for directly observing the ovaries. In domestic animals, laparoscopy was first utilised in the cow by Goetzer (1926) and then by Leiss (1936) and Megale *et al* (1956)<sup>46</sup>. Ovulation in mares has been studied using laparoscopes inserted in the flank area. Additional descriptions of laparoscopic techniques for the use in the mare as well as the donkey were reported by Heinze *et al* (1972) and by Heinze and Klug (1973)<sup>46</sup>.



Uses of laparoscopic procedures are increasing in frequency. Refinement of techniques, advancement in instrumentation and increased experience are leading to even more widespread applications in human and veterinary medicine<sup>86</sup>. The number and variety of surgical procedures performed via laparoscopic guidance in horses have steadily increased during the 1990s and into the 21<sup>st</sup> century<sup>46,86</sup>.

### 2.3 Laparoscopy and its Uses

The laparoscopic technique involves the use of a rigid fibre optic telescope, called a laparoscope coupled to a light source and video imaging system for viewing<sup>40,46,56</sup>. Laparoscopic surgical technique is based on the principle of triangulation wherein the laparoscope and specialised laparoscopic instruments converge on the surgical site like the apex of a triangle<sup>38,40,46,56</sup>. Advances in laparoscopy have led to the development of many surgical techniques in humans that in general allow a shorter convalescence than the more conventional open approaches<sup>56</sup>. Examples of laparoscopic surgery in humans include, gall bladder excision, appendectomy; ovariectomy, hernia repair, intestinal surgery, general diagnostic exploration and organ biopsies<sup>56</sup>. Laparoscopy in humans, equines, dogs, cats, birds and certain wildlife species has achieved international recognition as a proven surgical technique<sup>15,46,56,86</sup>.

Laparoscopy in the equine has been used to perform various standing and recumbent procedures. Uses of laparoscopic procedures performed in the equine are many and include the following:-

cryptorchidectomies<sup>1,27,40,41,44,46,54,56,57,58,88,115</sup>, ovariectomies<sup>28,31,40,46,50,53,56,78,80,85,87,94,95,105</sup>, ovariectomy<sup>29,46</sup>, inguinal herniorrhaphy in stallions/colts<sup>42,46,70</sup>; resection of umbilical structures in foals<sup>45,46</sup>; repair of ruptured bladders<sup>32,46,123</sup>; repair of scrotal hernias in foals<sup>46,65</sup>; repair of colonic and rectal tears<sup>14,46</sup>; colopexy<sup>18,46,111</sup>; adhesiolysis of intra-abdominal adhesions<sup>8,11,12,46,67</sup>; nephrectomy<sup>46,64</sup>; mesenteric rent repair<sup>46,109</sup>; closure of the renosplenic space<sup>46,69</sup>; aspiration of intra-abdominal abscesses<sup>46,86</sup>; organ biopsies<sup>46,86</sup>; management of post castration haemorrhage<sup>46,114,122</sup>; diagnosis of ischaemic necrosis of the descending colon<sup>46</sup>; diagnosis of subcapsular splenic haematoma<sup>46,72</sup>; diagnosis and management of uterine tears<sup>46</sup>; removal of uterine leiomyoma<sup>63</sup>; castration by in vivo ligation<sup>7,46,128</sup>; removal of cystic calculi<sup>6,46</sup>; for standing embryo transfer<sup>46</sup>; general abdominal exploration<sup>43,46</sup> and as an aid in student teaching<sup>10,46,48</sup>.

In a recent study a trial was performed on six intact pony stallions<sup>128</sup>. The aim was to evaluate a laparoscopic method to castrate stallions. Under general anaesthetic they were placed in dorsal recumbency. One testis of each stallion was pulled into the abdominal cavity and removed. The *vas deferens* and testicular artery and vein of the testes were clamped, electrocauterised and ligated. These testes were left in place to undergo *in situ* destruction. Histologically, coagulative necrosis of the entire testis occurred<sup>128</sup>.

## 2.4 Advantages of Laparoscopy

The advantages of laparoscopy include a relatively minimally invasive technique that can be done in standing or anaesthetised patients<sup>38,40,46,56,80</sup>. It has decreased morbidity allowing patients a rapid return to exercise<sup>38,40,46,56,79</sup>. Once the necessary skills are mastered, procedures are relatively quick to perform. Standing laparoscopy has the advantage of not requiring general anaesthetic with its associated risks and extra expense<sup>40,46,56</sup>.

## 2.5 Disadvantages of Laparoscopy

The application of laparoscopic techniques in equine surgery has been more gradual<sup>80</sup>. This is in part due to the expense of the required equipment, the skill level required to perform the procedures, limited training opportunities available for veterinary surgeons and physical limitations of equipment designed for use in man<sup>46,56,80</sup>.

## 2.6 Complications of Laparoscopy

Complications of laparoscopy are few, but need to be mentioned. Complications include the same complications in regular surgery as well as those more specific to laparoscopic surgeries<sup>40</sup>.

Haemorrhage may occur at the portal sites, at the sites of biopsies, and at the sites of castration and ovariectomy<sup>30,40,46,86,103</sup>. Infection is rare at the portal sites or intra-abdominally<sup>46,103</sup>. Improper insertion of the trocar may cause damage to the viscera, the spleen and the left kidney<sup>30,40,46,103</sup>. Mild transient emphysema at the portal sites is not

uncommon and is usually self limiting<sup>76,103</sup>. Post operative abdominal discomfort occurs in a low percentage of cases. This discomfort may be as a result of the procedure performed, (e.g. ovariectomy) or the result of the insufflated carbon dioxide gas on the serosal surfaces of the intestines and the peritoneal cavity<sup>76,86,103</sup>. When carbon dioxide is used in the abdominal cavity it is converted to carbonic acid which can irritate the peritoneal surfaces<sup>68,86</sup>. Significant increases in cardiac work, end-tidal CO<sub>2</sub> and calculated physiological shunt along with hypercapnia and acidosis have been reported after CO<sub>2</sub> pneumoperitoneum at 15mm Hg in dorsally recumbent, mechanically ventilated halothane anaesthetised healthy horses undergoing laparoscopy<sup>68</sup>. However pneumoperitoneum with CO<sub>2</sub> during standing laparoscopy in healthy horses does not cause adverse alterations in cardiopulmonary, haematological or plasma chemistry variables, but does induce a mild inflammatory response within the peritoneal cavity<sup>68</sup>. Retroperitoneal placement of insufflated gas is a complication which may force the surgeon to abort the procedure<sup>46,76</sup>. Diathermy injuries to adjacent intra-abdominal structures have been reported<sup>46,80</sup>.

The presence of post operative pain, tachycardia, tachypnoea, anorexia, depression, fever or abdominal distension of horses following laparoscopic surgery, signals the presence of potential complications and must be investigated on an emergency basis<sup>46,80</sup>.

Most of these complications can be avoided with careful attention to preoperative evaluation and intraoperative technique<sup>76,80</sup>. Nonetheless, the advancement of equine laparoscopic surgery continues to develop in order to provide the same benefits of minimally-invasive surgery to horses that are enjoyed by their human counterparts<sup>80</sup>.

## **2.7 Aims of this Study**

Reported conventional techniques of castration in equids have potential life threatening complications and/or require general anaesthetic. The laparoscopic technique used in this study was developed in order to avoid the described complications. To date, no studies have been reported where ligation of the testicular artery alone, has been used to sterilise donkeys. The aim of this technique was to perform laparoscopic assisted intra-abdominal testicular artery ligation in order to cause avascular necrosis of the testes and thus destroying testicular tissue.



## CHAPTER 3

### MATERIALS AND METHODS

#### 3.1 Subjects

Twelve healthy entire male donkeys used in this study were acquired from the Department of Veterinary Tropical Diseases, Faculty of Veterinary Science, University of Pretoria, South Africa. The age of the donkeys ranged from 5 months to 13 years. Identification of the donkeys was by numbers previously branded on the hindquarters. Both the testes of the 12 donkeys could be palpated distal to the superficial inguinal ring. The donkeys were randomly allocated into 6 groups of 2 donkeys as shown in Table 1.

#### 3.2 Husbandry Practices

The donkeys were kept in open grass paddocks of the Department of Veterinary Tropical Diseases, University of Pretoria, South Africa where they were partaking in a helminthology trial. While in these paddocks the donkeys' feeding, watering and general care was the responsibility of the Department of Veterinary Tropical Diseases. Twenty-four hours prior to the surgical procedure being performed the donkeys were stabled in the outdoor open stalls belonging to the Department of Companion Animal Clinical Studies, Faculty of Veterinary Science, University of Pretoria, South Africa. The donkeys were fed with *eragrostis teff* and water was provided *ad lib*. All feed was withdrawn for a 12 hour period prior to surgery. Access to water was allowed *ad lib* up until the time of surgery. After the surgical procedure was completed the donkeys were kept in the outdoor open stalls of the Department of Companion Animal Clinical Studies where they were fed *eragrostis teff* and allowed access to water *ad lib* during the post-operative monitoring period until they were deemed fit to return to the care of the Department of Veterinary Tropical Diseases.

### 3.3 Experimental Design

Twelve healthy entire male donkeys were used in this study. Of the 12 donkeys used in this study, 10 donkeys underwent laparoscopic assisted intra-abdominal testicular artery ligation. Each of these ten donkeys was then unilaterally castrated on two separate occasions. The donkey's were castrated in lateral recumbency using an acceptable open castration technique. The initial unilateral castrations were performed at three week intervals. The second or final unilateral castration was performed on all ten donkeys on the same day 9 months after the first group of donkeys underwent laparoscopic assisted testicular artery ligation.

The testes recovered after each castration procedure was placed in 10% buffered formalin. Histological sections of the testes and epididymes were prepared and evaluated by pathologists of the Department of Pathology, Faculty of Veterinary Science, University of Pretoria, South Africa. The two donkeys (Group 1) which were not subject to testicular artery ligation underwent bilateral castration, by means of an acceptable open castration technique. The testes from these donkeys were stored in 10% buffered formalin and histological sections of the testes and epididymes were prepared and evaluated by the same pathologists of the Department of Pathology, Faculty of Veterinary Science, University of Pretoria, South Africa. These histological sections of the normal testes were used as controls (Group 1).

The Filshie clips (Figure 1) used for ligation of the testicular artery were recovered from all the donkeys that underwent laparoscopic assisted intra-abdominal testicular artery ligation. The Filshie clips were recovered either at *post mortem* or were retrieved laparoscopically (Table 2). The decision as to which donkey would be euthanased was taken by the Department of Veterinary Tropical Diseases, University of Pretoria, South Africa.

### 3.3.1 Pre-operative Procedures

Twelve hours before commencement of surgery, all the donkeys underwent a complete physical examination and complete haematology counts were performed to establish clinical normality. The donkeys were fasted for twelve hours before surgery and *ad lib* water was allowed until the time of surgery. The donkeys were fasted to decrease the volume of the intestinal contents and consequently improve visualisation of the abdominal contents and limit the use of CO<sub>2</sub> insufflation during the laparoscopic procedure.

Premedication consisting of 1m<sup>l</sup> tetanus toxoid (Onderstepoort Biological Products, Pretoria, South Africa) administered intramuscularly, procaine penicillin at 20,000 iu/kg (Depocillin, Intervet, Spartan, South Africa) administered intramuscularly and phenylbutazone at 2.5 mg/kg (Phenylarthrite, Phenix, Logos AGvet, South Africa) was administered intravenously one hour prior to the surgical procedure.

The donkeys were placed in stocks in the special procedures room of the Department of Companion Animal Clinical Studies, Faculty of Veterinary Science, University of Pretoria, South Africa. A sedative analgesic combination of detomidine hydrochloride 0.01 mg/kg bwt iv, (Domosedan, Ciba Geigy Pty Ltd) and butorphanol tartrate 0.025 mg/kg bwt iv, (Fort Dodge Animal Health, Fort Dodge, USA) was administered.

The tail was tied to the stocks to keep it from entering the surgical field. The left and right paralumbar fossae were shaved and thoroughly scrubbed with chlorhexadine gluconate disinfectant soap (chlorhexadine gluconate 4g/100m<sup>l</sup>, ICI Pharmaceuticals, South Africa) and were sprayed with 1% povidone iodine (Betadine, Adcock Ingram Laboratories Ltd., Industria, Johannesburg, South Africa). The povidone iodine was removed by swabbing with sterile surgical swabs. This process was repeated three times with the last application not swabbed off. The surgical site was deemed aseptically prepared for the surgical procedure. The donkey was carefully draped with sterile surgical drapes to allow access to the left flank initially. The stocks on either side of the donkey were then draped with sterile surgical drapes to maintain an aseptic surgical field.

Local anaesthesia Lidocaine 2%, (Centaur Laboratories, Johannesburg, South Africa) was infiltrated subcutaneously and intramuscularly in an inverted L pattern into the sites where the laparoscope and instrument portals were to be inserted. Approximately 10-15m<sup>l</sup> of

local anaesthetic was used per site. A 15mm long skin incision was made in the selected paralumbar fossa at the level of the ventral aspect of the tuber coxa and equidistant between the last rib and cranial border of the tuber coxa. A second 15mm long incision was made 50mm ventral to the first incision (Figure 3). A disposable 11mm laparoscopic trocar-cannula with a 120mm working length and with a safety shield (Ethicon, Ethopath and Endosurgery, Johnson & Johnson Professional Products (Pty) Ltd, Halfway House, Johannesburg) was inserted through each skin incision and flank musculature into the peritoneal cavity. The guarded trocar-cannula was placed through the skin incisions into the peritoneal cavity in a slightly downward and caudal direction. Presence of the cannula in the peritoneal space was confirmed with the sound of air entering the abdomen. The trocar from the ventral portal was removed and replaced by a 10mm laparoscope (Karl Storz, GmbH & Co. KG, Mittelstraße 8, Tuttlingen, Germany) with a 0° viewing angle and central instrument portal. The laparoscope was then connected to a video imaging camera (Karl Storz, GmbH & Co. KG, Mittelstraße 8, Tuttlingen, Germany) and 300 Watt Xenon light source (Richard Wolf, Pforzheimer Straße 32, Knittlingen, Germany) which were stationed in direct line of sight of the surgeon and the surgeon's assistant. If visualisation was inadequate, CO<sub>2</sub> gas was used to insufflate the abdomen (flow rate, 0,5ℓ per minute) to a pressure between 10-15 mm Hg through an insufflator (Wolf 2146 CO<sub>2</sub> pneu-automat) connected by silastic tubing to the stopcock on the laparoscopic cannula.

The testicular artery was identified and visualised running ventrally over the inner lumbar muscles and along the lateral peritoneal wall in the proximal mesorchium to the internal inguinal ring. A laparoscopic atraumatic grasping forceps was inserted into the abdomen via the central instrument port of the laparoscope. The testicular artery was firmly grasped with the atraumatic grasping forceps. A loaded Filshie clip applicator (Femcare, Unit A2, Millennium Way East, Nottingham, United Kingdom) (Figure 2) was inserted through the dorsal instrument portal. The testicular artery was then firmly held by the atraumatic grasping forceps and was then ligated by application of the Filshie clip (Figure 4).

Once the Filshie clip was applied to the testicular artery, the Filshie clip applicator was removed from the dorsal instrument portal. The testicular artery was then visualised to ascertain if the Filshie clip had been correctly placed over the testicular artery. (Figure 5). Once the surgeon was satisfied that the testicular artery was completely ligated the laparoscope and grasping forceps were removed from the ventral portal. If CO<sub>2</sub> gas was

present in the abdomen it was allowed to escape via the two portal cannulas. The portal cannulas were then removed. The wounds were closed in a single layer in a simple interrupted suture pattern with 2/0 synthetic monofilament non-absorbable suture material (Ethicon, Ethopath and Endosurgery, Johnson & Johnson Professional Products (Pty) Ltd, Halfway House, Johannesburg) in the skin. The identical procedure was then repeated on the opposite side.

Unilateral castration of the ten donkeys that underwent laparoscopic testicular artery ligation was performed using an acceptable open technique on two separate occasions (Table 3). The first testes were removed at a specific time period after testicular artery ligation, while the second testes were all removed on the same day 9 months after the first group of donkeys underwent laparoscopic assisted testicular artery ligation. These intervals were chosen to monitor the rate at which the testes would undergo ischaemic necrosis. The testes of the two donkeys (Group 1) which did not undergo testicular artery ligation were removed using a single acceptable bilateral open castration technique. These testes were used as controls. All the testes removed, excluding the one testis lost to the study, were evaluated histologically.

### **3.4 Post-Operative Care**

The donkeys were returned to the outdoor open stalls belonging to the Department of Companion Animal Clinical Studies, Faculty of Veterinary Science, University of Pretoria, South Africa after surgery where they had immediate access to *erogrostis teff* and water *ad lib*. The donkey's vital signs which included general habitus, temperature, heart rate, respiratory rate and capillary refill time were monitored twice daily for a five day period. The donkeys were also observed for any signs of abdominal pain. The surgical wounds were checked for any swelling, subcutaneous emphysema, haemorrhage and infection. If no complications were encountered, the donkeys were returned into the care of the Department of Veterinary Tropical Diseases, Faculty of Veterinary Science, University of Pretoria, South Africa. Suture removal from the wound sites was performed at the Department of Veterinary Tropical Disease fourteen days post-operatively. All procedures performed on the subjects in this trial were approved by the Ethics Committee of the Faculty of Veterinary Science, University of Pretoria, South Africa.



## CHAPTER 4

### RESULTS

Laparoscopic assisted intra-abdominal testicular artery ligation was performed on ten entire healthy male donkeys in this trial. The donkeys' ages ranged from 5 months to 13 years.

The procedure was relatively simple and quick to perform. Surgical time of unilateral laparoscopic testicular artery ligation varied from 12 to 32 minutes with a mean of 22 minutes. The testicular artery was clearly visualised on the dorsal aspect of the peritoneal cavity, whereas in contrast, visualisation of the testicular artery close to the lateral peritoneal wall and inguinal opening was impaired owing to numerous folds in the mesorchium. For this reason it was decided to ligate the testicular artery with the Filshie clip at the more dorsal aspect of the peritoneal cavity where visualisation of the testicular artery was superior.

Abdominal insufflation with CO<sub>2</sub> gas to aid in visualisation and ligation of the testicular artery was only required in donkey 14.

One major complication was encountered during the laparoscopic procedure when the left dorsal colon of donkey 3 was perforated by the trocar. Perforation of the viscera occurred as a result of the incorrect technique used in the placement of the disposable guarded trocar-cannula system. The technique of trocar-cannula placement was reviewed and was subsequently corrected. This donkey was treated in the event of a possible peritonitis developing as a result of the perforation of the viscera. The donkey was treated with procaine penicillin (Depocillin, Intervet, Spartan, South Africa) administered intramuscularly at 20,000 iu/kg twice daily and gentamicin (Genta 50, Phenix, Logos AGvet, South Africa) 6.6 mg/kg intravenously once daily for a period of seven days post-operatively. Donkey 3 remained moderately depressed for four days after which it returned to normal health. Unfortunately this same donkey 3 died five days after being returned to the Department of Veterinary Tropical Diseases, University of Pretoria, South Africa. A diagnosis of acute babesiosis was made at *post mortem*. Signs of a resolving peritonitis were visible at *post mortem*. Both Filshie clips and testes of donkey 3 were recovered at *post mortem* and

were placed in 10% buffered formalin.

In three of the donkeys 9, 11 and 14 signs of subcutaneous emphysema was observed around the wound sites. This was of little consequence and resolved without treatment within four days. All incisions healed by first intention. Cosmetic appearance of the incisions was excellent.

Abdominal discomfort was noted in all the donkeys on application of the Filshie clip to the testicular artery. This discomfort was transient and no additional analgesia was required. Similar discomfort has been reported in women who have undergone laparoscopic tubal ligation with application of Filshie clips<sup>4,34,37</sup>. To avoid this discomfort, human surgeons applied lidocaine gel to the Filshie clips before tubal ligation was performed. These patients were more comfortable one hour post operatively than those patients where no lidocaine gel was applied to the Filshie clips<sup>34</sup>. Due to this time delay and the transient nature of the discomfort, it was decided not to use the lidocaine gel in this study. This discomfort is thought to be the result of the pressure applied to the testicular artery<sup>34,37</sup>.

No abdominal pain or discomfort was observed post operatively in any of the surgical cases including donkey 3 which had experienced the visceral perforation or donkey 14 in which abdominal insufflation with CO<sub>2</sub> gas was required.

A total of 23 testes were recovered from the 12 donkeys. The right testis of donkey 22 was lost to the study. This donkey died of acute heart failure two months after laparoscopic testicular artery ligation. The acute heart failure was diagnosed at *post mortem* and was unrelated to the surgical procedure. Unfortunately the right testis was mislaid at *post mortem*.

At necropsy, the testes of donkeys 2 and 4 (controls Group 1), donkey 9 and the right testis of donkey 8 were firm and resilient on palpation and were macroscopically pinkish in colour. The testes of the remaining donkeys had a doughy consistency with little resilience on palpation. Macroscopically they were yellowish with a pale centre.

The testes of donkeys 2 and 4 in group 1 were used as a control. The 4 testes from these 2 donkeys had histologically normal seminiferous epithelium with spermatids present and the epididymes in these testes were full of spermatozoa (Table 4).

Histological findings of both testes of donkey 1 and 11, the left testis of donkey 22 and the right testis of donkey 20, revealed the seminiferous tubules in varying stages of ischaemic necrosis, degeneration and fibrosis (Table 4).

The left and right testes of donkey 31, the right testis of donkey 14 and the left testis of donkey 25 showed histologically moderate diffuse testicular degeneration and atrophy with areas of intertubular connective tissue (Table 4).

The left testis of donkey 14 and right testis of donkey 25 showed histologically that testicular atrophy was present, with 60% of the tubules undergoing degeneration and the remaining tubules still active. In donkey 8, the left testis showed locally extensive testicular degeneration with 70% of the tubules undergoing degeneration with the remaining tubules still active. Both the testes of donkey 9 and the right testis of donkey 8 were histologically normal.

In summary, seven testes, the left and right testes of donkey 1, the left testis of donkey 3, the left and right testis of donkey 11, the right testis of donkey 20 and the left testis of donkey 22 showed signs that could be attributable to ischaemic necrosis. Six testes, the right testis of donkey 3, the right testis of donkey 14, the left testis of donkey 20, the left testes of donkey 25 and the left and right testes of donkey 31 showed seminiferous tubules in varying stages of degeneration and atrophy with some intertubular fibrous connective tissue. Three testes, the left testis of donkey 8, the left testis of donkey 14 and the right testis of donkey 25 showed 60-70% of seminiferous tubular atrophy with some active tubules remaining. Three testes, the right testis of donkey 8 and the left and right testes of donkey 9 showed no abnormalities and were histologically normal. The contents of the epididymes of the testes varied from being empty to some containing spermatozoa while others contained some proteinaceous debris (Table 4).



To summarise further, 68.4% the testes that underwent testicular artery ligation showed signs of ischaemic necrosis and atrophy, 15.8% showed signs of atrophy and degeneration with some normal testicular tissue still present, while the remaining 15.8% were normal.

Two donkeys, 8 and 14 exhibited signs of unaltered masculine-like behaviour. This behaviour was noted when the female donkeys were re-introduced to the neighbouring paddocks three months after testicular artery ligation had been performed.

All the Filshie clips were recovered from the donkeys that underwent the laparoscopic testicular artery ligation. The Filshie clips were either recovered at *post mortem* or by laparoscopic means. There was no evidence of any Filshie clip migration in any of the donkeys. There were no signs of any adverse reactions in the proximity of any of the Filshie clips. Macroscopically it was evident in the case of donkey 9 that the testicular artery on both the left and right side had not been ligated in their entirety. On close examination of the Filshie clips in donkey 9, a portion of the testicular artery was visibly protruding from the edge of the closed Filshie clip and as a result the testicular artery was not completely occluded. In no other cases was this macroscopically evident. An attempt was made to perform a histological examination of the tissue clamped within the Filshie clips. This however proved unsuccessful and we were unable to ascertain if the testicular artery in all the remaining cases had been completely ligated.

**Table 1: Experimental Donkeys**

<b>Group No.</b>	<b>Donkey No.</b>	<b>Age (years)</b>	<b>Weight (kgs)</b>
1.	2	2.5	125
	4	5	148
2.	9	1.5	136
	20	3	164
3.	8	4	146
	22	13	126
4.	1	0.5	90
	11	1.5	168
5.	3	6	180
	25	3	122
6.	14	13	162
	31	1.5	120
<b>Mean</b>		<b>4.71</b>	<b>140.58</b>
<b>Standard Deviation</b>		<b>4.63</b>	<b>25.59</b>
<b>Median</b>		<b>3.00</b>	<b>141.00</b>

**Table 2: Time and Method of Filshie Clip Removal**

Group No.	Donkey No.	Months post artery ligation removal	Method of Filshie clip removal
1. (Control Group)	2	-	-
	4	-	-
2.	9	19	<i>post mortem</i>
	20	18	<i>post mortem</i>
3.	8	16	laparoscopically
	22	20	<i>post mortem</i>
4.	1	20	laparoscopically
	11	20	laparoscopically
5.	3	0.3	<i>post mortem</i>
	25	19	<i>post mortem</i>
6.	14	18.5	<i>post mortem</i>
	31	20	laparoscopically

**Table 3: Time period between Laparoscopy and Testicular Removal**

Group No.	Donkey No.	Left testis	Right testis
1. (Control Group)	2	-	-
	4	-	-
2.	9	223 days	7 days
	20	7 days	223 days
3.	8	218 days	21 days
	22	21 days	*-
4.	1	42 days	218 days
	11	42 days	218 days
5.	3	10 days	10 days
	25	84 days	194 days
6.	14	194 days	117 days
	31	194 days	117 days
<b>Mean</b>		<b>103.5</b>	<b>125</b>
<b>Standard Deviation</b>		<b>92.242</b>	<b>93.378</b>
<b>Median</b>		<b>63</b>	<b>117</b>


Overall there is no difference between the left and right testes and the time at which the testes were removed

\* = missing testis

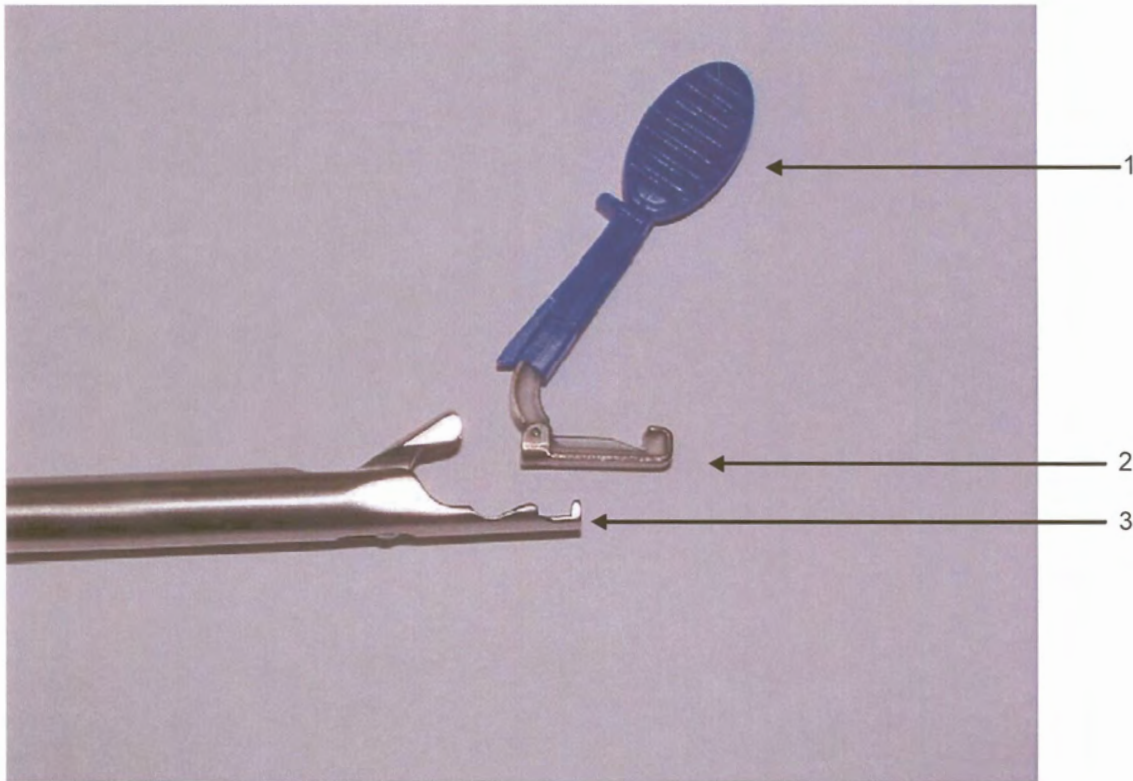
**Note:** The decision as to which testes were removed at the initial castration depended on which side the donkey presented when cast during the open castration procedure i.e. the uppermost testis was removed (e.g. if donkey lay on left side, right testis was removed and *vice versa*).

**Table 4: Histopathological Findings of the Testes and Epididymes**

Group No.	Donkey No.	Left testis findings	Right testis findings
1. (Control Group)	2	<ul style="list-style-type: none"> <li>- Seminiferous epithelium and spermatids were present</li> <li>- Epididymis was full of spermatozoa</li> </ul>	<ul style="list-style-type: none"> <li>- Seminiferous epithelium and spermatids were present</li> <li>- Epididymis was full of spermatozoa</li> </ul>
	4	<ul style="list-style-type: none"> <li>- Seminiferous epithelium and spermatids were present</li> <li>- Epididymis was full of spermatozoa</li> </ul>	<ul style="list-style-type: none"> <li>- Seminiferous epithelium and spermatids were present</li> <li>- Epididymis was full of spermatozoa</li> </ul>
2.	9	<ul style="list-style-type: none"> <li>- Seminiferous epithelium and spermatids were present</li> <li>- Epididymis was full of spermatozoa</li> </ul>	<ul style="list-style-type: none"> <li>- Seminiferous epithelium and spermatids were present</li> <li>- Epididymis was full of spermatozoa</li> </ul>
	20	<ul style="list-style-type: none"> <li>- Diffuse but variable degeneration/atrophy of seminiferous tubules with multinucleate cells in lumen and no spermatids</li> <li>- Epididymis contained spermatozoa</li> </ul>	<ul style="list-style-type: none"> <li>- Seminiferous tubules in varying stages of ischaemic necrosis and degeneration/atrophy</li> <li>- Epididymis contained masses of cellular debris</li> </ul>
3.	8	<ul style="list-style-type: none"> <li>- Locally extensive testicular degeneration present</li> <li>- 70% of tubules underwent degeneration, the remainder were active</li> <li>- Focal lymphoid aggregate present</li> <li>- Epididymis full of spermatozoa</li> </ul>	<ul style="list-style-type: none"> <li>- Seminiferous epithelium and spermatids were present</li> </ul>
	22	<ul style="list-style-type: none"> <li>- Testis was barely identifiable</li> <li>- Seminiferous tubules replaced by fibrous connective tissue</li> <li>- Epididymis contained proteinaceous debris</li> </ul>	<ul style="list-style-type: none"> <li>- Not recovered</li> </ul>
4.	1	<ul style="list-style-type: none"> <li>- Seminiferous tubules were in varying stages of ischaemic necrosis and degeneration/atrophy</li> </ul>	<ul style="list-style-type: none"> <li>- Testicular necrosis, degeneration and fibrosis were present</li> <li>- Areas of fibrosis contained pigment-laden macrophages</li> <li>- Epididymis contained few degenerate spermatozoa</li> </ul>
	11	<ul style="list-style-type: none"> <li>- Diffuse testicular atrophy composed of shrunken inactive seminiferous tubules</li> <li>- Epididymis contained spermatids</li> </ul>	<ul style="list-style-type: none"> <li>- Testicular atrophy with areas of fibrosis and degenerating tubules were present</li> <li>- Epididymis contained occasional spermatozoa</li> </ul>
5.	3	<ul style="list-style-type: none"> <li>- Multifocal segmental to global tubular coagulative necrosis and testicular degeneration were present</li> <li>- Epididymis contained spermatids and necrotic debris</li> </ul>	<ul style="list-style-type: none"> <li>- Diffuse testicular degeneration and fibrosis were present</li> <li>- Occasional tubules contained spermatids however they appeared degenerate</li> </ul>
	25	<ul style="list-style-type: none"> <li>- Scattered degenerated atrophic seminiferous tubules with patchy increase intertubular connective tissue were present</li> <li>- Epididymis contained spermatozoa</li> </ul>	<ul style="list-style-type: none"> <li>- Some testicular degeneration was present</li> <li>- 60% of tubules were undergoing degeneration, the remainder were active</li> <li>- Epididymis contained spermatozoa</li> </ul>
6.	14	<ul style="list-style-type: none"> <li>- Testicular atrophy was present</li> <li>- 60% of tubules were undergoing degeneration, the remaining tubules were active</li> <li>- Focal lymphoid aggregate was present</li> <li>- Epididymis contained spermatozoa</li> </ul>	<ul style="list-style-type: none"> <li>- Testicular atrophy with areas of fibrosis, haemorrhage and degenerating tubules were present</li> <li>- Lymphoid aggregates were present</li> <li>- Epididymis contained a few spermatozoa</li> </ul>
	31	<ul style="list-style-type: none"> <li>- Moderate diffuse testicular degeneration was present</li> <li>- Epididymis contained spermatids and cellular debris</li> </ul>	<ul style="list-style-type: none"> <li>- Diffuse testicular degeneration was present</li> <li>- Epididymis contained spermatids</li> </ul>

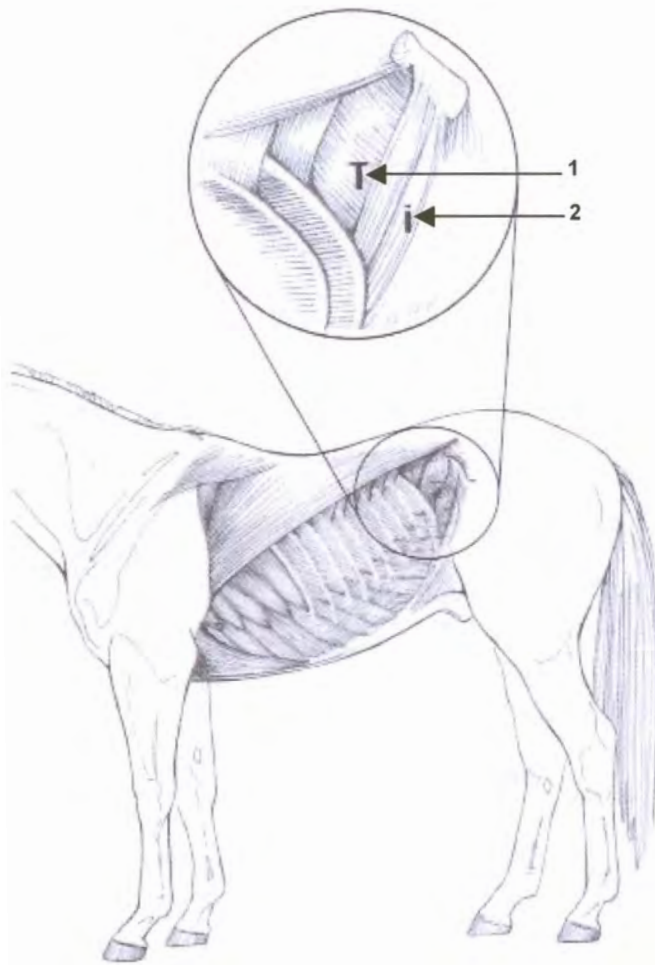


**Figure 1: Filshie Clips 1, Filshie Clip cover; 2, silicone rubber lining; 3, titanium**  
(Courtesy Femcare, Nottingham, UK)



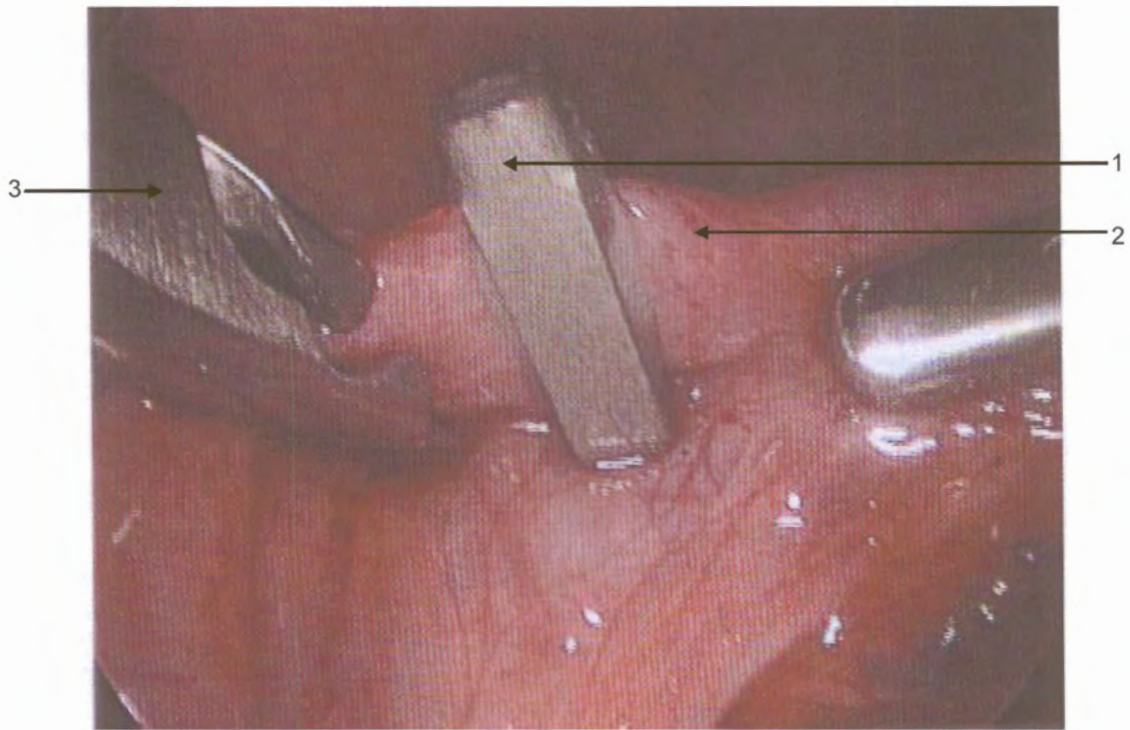
**Figure 2: Filshie Clip Applicator and Filshie Clip 1, Filshie Clip cover;  
2, Filshie Clip; 3, Filshie Clip Applicator**  
(Courtesy Femcare, Nottingham, UK)



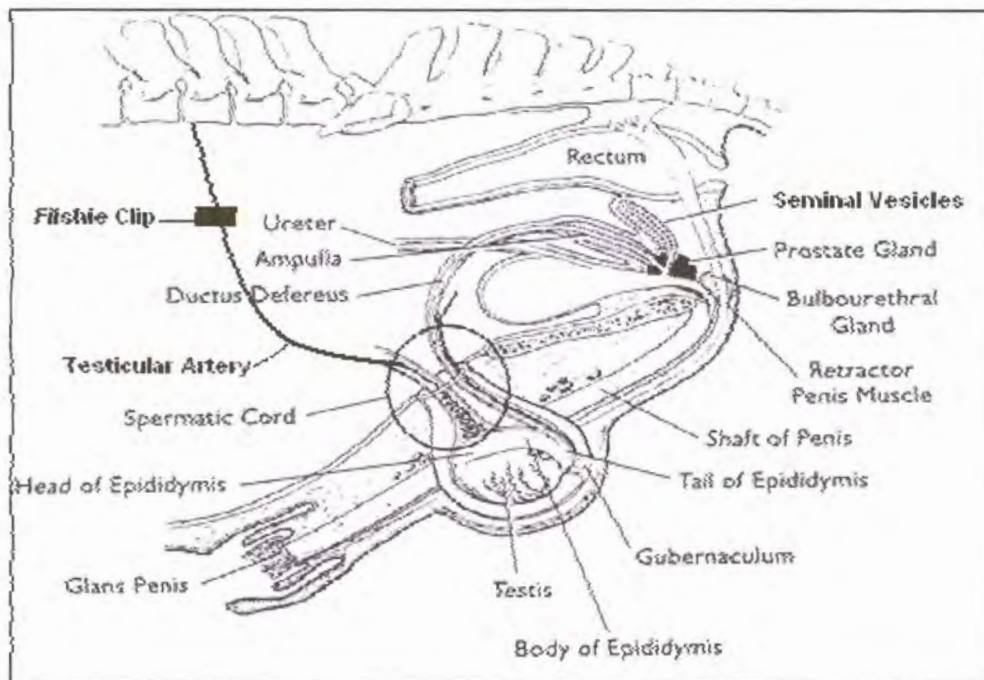


**Figure 3: Laparoscopic Portal Sites<sup>46</sup> 1, Dorsal; 2, Ventral**  
(From Equine diagnostic Surgical Laparoscopy, A.T. Fischer, Jr)





**Figure 4: Tubule ligation by Filshie Clip 1, Filshie Clip; 2, uterine tubule;  
3, Filshie Clip applicator**  
(Courtesy Femcare, Nottingham, UK)



**Figure 5: Diagram demonstrating Filshie Clip position on the testicular artery in the dorsal aspect of the peritoneal cavity**

## CHAPTER 5

### DISCUSSION

The primary aim of this study was to determine if laparoscopically assisted intra-abdominal testicular ligation would result in avascular necrosis of the testicular tissue in donkeys, and if so, could this method be an option to replace the more conventional castration techniques.

To date, no studies have been reported where testicular artery ligation alone has been performed to cause avascular necrosis of the testicular tissue in equids. In two studies the testicular artery and vein and *vas deferens* were electrocauterised and sharply divided and the testes left *in situ* to undergo avascular necrosis<sup>7,128</sup>. In a third study, the spermatic cord was crushed and double ligated and the testes left *in situ* to undergo avascular necrosis<sup>33</sup>. In a fourth study, a double ligation of the mesorchium was performed without transection leaving the testes *in situ* to necrose<sup>124</sup>. The results of the studies were conflicting. In the first study, all the testes left to undergo *in situ* avascular necrosis were examined histologically which confirmed avascular necrosis of the testicular tissues of all the testes. In addition, baseline and stimulated testosterone concentrations were consistent with castration<sup>128</sup>. However, in the second study despite cauterisation and transection of the testicular artery and vein and *vas deferens*, the testis left to undergo avascular necrosis was examined histologically twelve months later and found to have mild degeneration. On gross examination, half the testis appeared normal whereas the other half was of irregular shape<sup>7</sup>. Baseline and stimulated testosterone concentration were in this case consistent with the presence of viable testicular tissue. The survival of testicular tissue in this case was attributed to peritesticular angiogenesis before testicular necrosis was complete resulting in revascularisation of the testicular tissue and subsequent testosterone production<sup>7</sup>. In the third study the testes were not studied histologically but testicular size and testosterone levels were measured. In this study testosterone levels declined rapidly while testes gradually atrophied<sup>33</sup>. In the fourth study, success was measured by baseline and stimulated testosterone concentrations. A small failure rate was seen in clinical cases until the *ductus deferens* was included in the ligature<sup>124</sup>. The difference in the results between the two studies where the testicular artery and testicular vein and the *vas deferens* were

electrocauterised and sharply divided and the testes left *in situ* to undergo avascular necrosis could possibly be attributed to the anatomical position of the testes. In the first study where the surgery was performed on six entire ponies, all the testes were in normal position in the scrotum. However, in the second study, the testis left *in situ* to undergo avascular necrosis was situated proximally in the inguinal canal and was not manually palpable<sup>7</sup>. The inguinal canal area appears more vascular than the scrotal sac, which may have attributed to the peritesticular angiogenesis which occurred in this single testis. The testes in the third study where the spermatic cord was crushed and double ligated were also in the normal anatomical position in the scrotum. The position of the testes in the fourth study was not stipulated. All the testes in the donkeys used in this study were also in the normal anatomical position within the scrotum.

The results in this study support the results found in the first, third and fourth studies (as described above). Seven of the 19 testes in this study showed ischaemic necrosis of the entire testicular tissue upon histological examination. A further six testes showed seminiferous tubules in varying stages of degeneration and atrophy with some intertubular fibrous connective tissue present with no signs of normal testicular tissue present. These histological changes of ischaemic necrosis, degeneration and atrophy of the seminiferous tubules were in our opinion caused by ligation of the testicular artery. However, three of the testes showed only partial (60-70%) degeneration of the seminiferous tubules leaving a percentage of the remaining testicular tissue viable. The presence of viable testicular tissue in these cases could be attributed to one of the following; incorrect Filshie clip application (i.e. technique failure), revascularisation by collateral blood supply, recanalisation of the testicular artery or angiogenesis by peritesticular tissue. Macroscopically these testes were soft and doughy on palpation and yellow and pale in colour. In this study, blood samples were taken to measure baseline serum testosterone levels before and after laparoscopic assisted testicular artery ligation. For the purpose of the Masters Degree, blood results were not required but are the subject of a separate article to be published at a later date.

The left and right testes of donkey 9 and the right testis of donkey 8 were histologically identical to the control donkeys 2 and 4 and were thus considered normal. In donkey 9 it was confirmed on macroscopic examination of the Filshie clips that bilateral testicular artery ligation was unsuccessful. On close examination of the Filshie clips in donkey 9 a portion

of the testicular artery was visibly protruding from the edge of the closed Filshie clip and as a result the testicular artery was not completely occluded. This donkey was one of the first in which the procedure was performed and probably lack of experience in the procedure resulted in this failure. The failure of the right testis in donkey 8 to undergo avascular necrosis degeneration and atrophy was probably also due to technique failure. This however, could not be confirmed on macroscopic examination of the Filshie clip and its contents. Macroscopically these testes were firm and resilient on palpation and pinkish in colour.

The time period that the testes were left *in situ* did not appear to play a significant role in the avascular necrosis or the possible revascularisation for example: in donkeys 1 and 11 the left testis were removed at 42 days post testicular artery ligation and the right testis at 218 days post testicular artery ligation but the histological results of all four testes were identical. In the case of donkey 20, the left testis was removed 7 days post testicular artery ligation and showed diffuse but variable degeneration and atrophy of the seminiferous tubules while the right testis which was removed at 223 days post testicular artery ligation showed varying stages of ischaemic necrosis and degeneration. In the case of donkey 25, the left testis which was removed at 84 days post testicular artery ligation showed scattered degenerated atrophic seminiferous tubules, while the right testis which was removed at 194 days post testicular artery ligation showed only 60% of tubules were undergoing degeneration.

The laparoscopic technique used in this study shows promise as an alternative to the more conventional castration techniques. However, further research is required before the technique can be recommended for use in equine practice. This research should include a larger number of subjects, preferably colts and/or stallions. A modification to the technique using a double ligation method or double ligation and transection should be considered. In addition to histopathology of the testicular tissue, baseline and stimulated testosterone concentrations should be measured. Modification to the technique would however increase the time and expense of the surgery but if successful, these modifications would outweigh the possible complications associated with conventional castration methods.

The use of this technique in the cryptorchid case is a possibility in the future. Further research comparing laparoscopically assisted testicular artery ligation in abdominal and



inguinal cryptorchids would be an interesting study.

A disadvantage of this technique is the visible and palpable dysfunctional testicular remnants retained in the scrotum. These remnants may be mistaken for testicular tissue by uninformed persons.

Two of the donkeys in this study showed unaltered masculine-like behaviour. This has been seen in horses castrated by more conventional techniques and may be attributed to normal psychic behaviour or the presence of viable testicular tissue.

Although greater costs and advanced expertise are required for this technique, these factors outweigh the risks associated with the more conventional castration techniques.

Due to the variability in data and the low numbers of subjects used, this study does not lend itself to statistical analysis. For this reason, only descriptive statistics have been used.

## CHAPTER 5

### DISCUSSION

The primary aim of this study was to determine if laparoscopically assisted intra-abdominal testicular ligation would result in avascular necrosis of the testicular tissue in donkeys, and if so, could this method be an option to replace the more conventional castration techniques.

To date, no studies have been reported where testicular artery ligation alone has been performed to cause avascular necrosis of the testicular tissue in equids. In two studies the testicular artery and vein and *vas deferens* were electrocauterised and sharply divided and the testes left *in situ* to undergo avascular necrosis<sup>7,128</sup>. In a third study, the spermatic cord was crushed and double ligated and the testes left *in situ* to undergo avascular necrosis<sup>33</sup>. In a fourth study, a double ligation of the mesorchium was performed without transection leaving the testes *in situ* to necrose<sup>124</sup>. The results of the studies were conflicting. In the first study, all the testes left to undergo *in situ* avascular necrosis were examined histologically which confirmed avascular necrosis of the testicular tissues of all the testes. In addition, baseline and stimulated testosterone concentrations were consistent with castration<sup>128</sup>. However, in the second study despite cauterisation and transection of the testicular artery and vein and *vas deferens*, the testis left to undergo avascular necrosis was examined histologically twelve months later and found to have mild degeneration. On gross examination, half the testis appeared normal whereas the other half was of irregular shape<sup>7</sup>. Baseline and stimulated testosterone concentration were in this case consistent with the presence of viable testicular tissue. The survival of testicular tissue in this case was attributed to peritesticular angiogenesis before testicular necrosis was complete resulting in revascularisation of the testicular tissue and subsequent testosterone production<sup>7</sup>. In the third study the testes were not studied histologically but testicular size and testosterone levels were measured. In this study testosterone levels declined rapidly while testes gradually atrophied<sup>33</sup>. In the fourth study, success was measured by baseline and stimulated testosterone concentrations. A small failure rate was seen in clinical cases until the *ductus deferens* was included in the ligature<sup>124</sup>. The difference in the results between the two studies where the testicular artery and testicular vein and the *vas deferens* were



electrocauterised and sharply divided and the testes left *in situ* to undergo avascular necrosis could possibly be attributed to the anatomical position of the testes. In the first study where the surgery was performed on six entire ponies, all the testes were in normal position in the scrotum. However, in the second study, the testis left *in situ* to undergo avascular necrosis was situated proximally in the inguinal canal and was not manually palpable<sup>7</sup>. The inguinal canal area appears more vascular than the scrotal sac, which may have attributed to the peritesticular angiogenesis which occurred in this single testis. The testes in the third study where the spermatic cord was crushed and double ligated were also in the normal anatomical position in the scrotum. The position of the testes in the fourth study was not stipulated. All the testes in the donkeys used in this study were also in the normal anatomical position within the scrotum.

The results in this study support the results found in the first, third and fourth studies (as described above). Seven of the 19 testes in this study showed ischaemic necrosis of the entire testicular tissue upon histological examination. A further six testes showed seminiferous tubules in varying stages of degeneration and atrophy with some intertubular fibrous connective tissue present with no signs of normal testicular tissue present. These histological changes of ischaemic necrosis, degeneration and atrophy of the seminiferous tubules were in our opinion caused by ligation of the testicular artery. However, three of the testes showed only partial (60-70%) degeneration of the seminiferous tubules leaving a percentage of the remaining testicular tissue viable. The presence of viable testicular tissue in these cases could be attributed to one of the following; incorrect Filshie clip application (i.e. technique failure), revascularisation by collateral blood supply, recanalisation of the testicular artery or angiogenesis by peritesticular tissue. Macroscopically these testes were soft and doughy on palpation and yellow and pale in colour. In this study, blood samples were taken to measure baseline serum testosterone levels before and after laparoscopic assisted testicular artery ligation. For the purpose of the Masters Degree, blood results were not required but are the subject of a separate article to be published at a later date.

The left and right testes of donkey 9 and the right testis of donkey 8 were histologically identical to the control donkeys 2 and 4 and were thus considered normal. In donkey 9 it was confirmed on macroscopic examination of the Filshie clips that bilateral testicular artery ligation was unsuccessful. On close examination of the Filshie clips in donkey 9 a portion

of the testicular artery was visibly protruding from the edge of the closed Filshie clip and as a result the testicular artery was not completely occluded. This donkey was one of the first in which the procedure was performed and probably lack of experience in the procedure resulted in this failure. The failure of the right testis in donkey 8 to undergo avascular necrosis degeneration and atrophy was probably also due to technique failure. This however, could not be confirmed on macroscopic examination of the Filshie clip and its contents. Macroscopically these testes were firm and resilient on palpation and pinkish in colour.

The time period that the testes were left *in situ* did not appear to play a significant role in the avascular necrosis or the possible revascularisation for example: in donkeys 1 and 11 the left testis were removed at 42 days post testicular artery ligation and the right testis at 218 days post testicular artery ligation but the histological results of all four testes were identical. In the case of donkey 20, the left testis was removed 7 days post testicular artery ligation and showed diffuse but variable degeneration and atrophy of the seminiferous tubules while the right testis which was removed at 223 days post testicular artery ligation showed varying stages of ischaemic necrosis and degeneration. In the case of donkey 25, the left testis which was removed at 84 days post testicular artery ligation showed scattered degenerated atrophic seminiferous tubules, while the right testis which was removed at 194 days post testicular artery ligation showed only 60% of tubules were undergoing degeneration.

The laparoscopic technique used in this study shows promise as an alternative to the more conventional castration techniques. However, further research is required before the technique can be recommended for use in equine practice. This research should include a larger number of subjects, preferably colts and/or stallions. A modification to the technique using a double ligation method or double ligation and transection should be considered. In addition to histopathology of the testicular tissue, baseline and stimulated testosterone concentrations should be measured. Modification to the technique would however increase the time and expense of the surgery but if successful, these modifications would outweigh the possible complications associated with conventional castration methods.

The use of this technique in the cryptorchid case is a possibility in the future. Further research comparing laparoscopically assisted testicular artery ligation in abdominal and

inguinal cryptorchids would be an interesting study.

A disadvantage of this technique is the visible and palpable dysfunctional testicular remnants retained in the scrotum. These remnants may be mistaken for testicular tissue by uninformed persons.

Two of the donkeys in this study showed unaltered masculine-like behaviour. This has been seen in horses castrated by more conventional techniques and may be attributed to normal psychic behaviour or the presence of viable testicular tissue.

Although greater costs and advanced expertise are required for this technique, these factors outweigh the risks associated with the more conventional castration techniques.

Due to the variability in data and the low numbers of subjects used, this study does not lend itself to statistical analysis. For this reason, only descriptive statistics have been used.

## CHAPTER 6

### CONCLUSIONS

The laparoscopic assisted intra-abdominal testicular artery ligation method used in this study was relatively quick (mean 22 minutes) and simple to perform. Minimal intraoperative and post operative complications were encountered. Post operative discomfort was minimal and recovery was rapid and uncomplicated resulting in early return to normal exercise. The cosmetic outcome was excellent.

The Filshie clips used to ligate the testicular artery, when correctly placed resulted in complete occlusion of the artery. No adverse tissue reaction was noted in the proximity of the Filshie clips and no migration of the Filshie clips was noted in any of the donkeys. The Filshie clips were considered an excellent choice for this procedure.

Ligation of the testicular artery alone in order to cause avascular necrosis of the testicular tissue was successful in the majority of the donkeys. However, there is a high rate of failure ( $\pm 32\%$ ) of this laparoscopic technique. For a sterilisation procedure, a 68% success rate is unacceptable. Considering the results in this study it was concluded that this method shows promise as an alternative to the more conventional castration techniques. The method itself should be modified prior to performing another study using the same technique in a larger study group. There is still uncertainty with regard to leaving the testes *in situ* after testicular artery ligation. Further research is needed before this method can be recommended for use in equine practice.

Presently, if a laparoscopic castration method was elected, ligation of the testicular arteries, testicular veins and *vas deferens* and removal of the testes in their entirety would be, in the author's opinion, the method of choice.

## REFERENCES

1. Adams SB 1986 Cryptorchidectomy in stallions. *Modern Veterinary Practice* p: 790-794
2. Alldredge JG, Hendrickson DA 2004 Use of high-power ultrasonic shears for laparoscopic ovariectomy in mares. *Journal American Veterinary Medical Association* 15: 225 (10): 1978-1980
3. Arthur GH, Noakes DE 1987 *Veterinary Reproduction and Obstetrics* 7th edn. W.B. Saunders, Philadelphia
4. Barclay K, Calvert JP, Catling SJ, Edwards ND, Rees A 1994 Analgesia after laparoscopic sterilization. *Anaesthesia* 49: 68-70
5. Barker SM 1985 Castration of horses with primary closure and scrotal ablation. *Veterinary Surgery* 14 (1): 2-6
6. Beard W 2004 Parainguinal laparoscystotomy for urolith removal in geldings. *Veterinary Surgery* 33 (4): 386-390
7. Bergeron JA, Hendrickson DA, McCue PM 1998 Viability of an inguinal testis after laparoscopic cauterization and transection of its blood supply. *Journal American Veterinary Medical Association* 213 (9): 1303-1304
8. Bleyaert HF, Brown MP, Bonenclark G, Bailey JE 1997 Laparoscopic Adhesiolysis in a Horse. *Veterinary Surgery* 26: 492-496
9. Bouré L, Marcoux M, Laverty S 1997 Paralumbar Fossa Laparoscopic Ovariectomy in Horses With Use of Endoloop Ligatures. *Veterinary Surgery* 26: 478-483
10. Bouré L, Marcoux M, Laverty S 1997 Laparoscopic Abdominal Anatomy of Foals Positioned in Dorsal Recumbency. *Veterinary Surgery* 26: 1-6
11. Bouré L, Marcoux M, Lavoie JP, Laverty S 1998 Use of laparoscopic equipment to divide abdominal adhesions in a filly. *Journal American Veterinary Medical Association* 212 (6): 845-847

12. Bouré L, Pearce SG, Kerr CL, Lansdowne JL, Martin CA, Hathway AL, Caswell JL 2002 Evaluation of laparoscopic adhesiolysis for the treatment of experimentally induced adhesions in pony foals. *American Journal Veterinary Research* 63 (2): 289-294
13. Boussouw B, Wilderjans H 1996 Inguinal herniation 12 days after a unilateral castration with primary wound closure. *Equine Veterinary Education* 8 (5): 248-250
14. Brugmans F, Deegen E 2001 Laparoscopic surgical technique for repair of rectal and colonic tears in horses: an experimental study. *Veterinary Surgery* 30 (5): 409-416
15. Burr EW, Huchzermeyer FW, Riley AE 1981 Laparoscopic examination to determine sex in mamomorph avian species. *Journal of South African Veterinary Association* 52 (1): 45-47
16. Butt TD, Wilson DG 2003 Laparoscopic colopexy in a horse. *Canadian Veterinary Journal* 44 (7): 586-588
17. Carson-Dunkerley SA, Hanson RR 1997 Ovariectomy of granulosa cell tumours in mares by use of diagonal paramedian approach: 12 cases (1989-1995). *Journal of American Veterinary Medical Association* 211 (2) 204-206
18. Chan AC, Koehler A, Crisp B, Tam JS, Chung SC 2000 Is it safe to reuse disposable laparoscopic trocars: An in vitro testing. *Surgical Endoscopy*. 14 (11): 1042-1044
19. Chi IC 1994 Use of multiple clips for tubal occlusion in interval laparoscopic sterilization: Circumstances and consequences. *Contraception* 50: 409-413
20. Chi IC, Thapa, S 1994 Mechanical devices for internal laparoscopic tubal sterilisation in previous IUD uses. *Advances in Contraception* 10 (3): 223-234
21. Cox JE 1982 *Surgery of the Reproductive Tract in Large Animals*. Department of Veterinary Clinical Science, University of Liverpool 2nd edn
22. Cox JE 1984 Castration of horses and donkeys with first intention healing. *Veterinary Record* 115: 372-375

23. Cox JE 1989 Testosterone concentration in normal and cryptorchid horses response to human chorionic gonadotrophin. *Animal Reproduction Science* 18: 43-50
24. Crouch GM, Snyder JR, Harmon BG 1983 Adhesion of the ilium to the inguinal ring in a gelding. *Veterinary Clinics of North America: Equine Practice* 5 (9): 32-37
25. Cupps PT 1991 *Reproduction in Domestic Animals* 4th edn. Academic Press, Boston
26. Dadoune JP, Demoulin A 1993. *Structure and Functions of the Testis. Reproduction of Mammals and Man*, Ellipses, Paris
27. Davis EW 1997 Laparoscopic cryptorchidectomy in standing horses. *Veterinary Surgery* 26 (4): 326-331
28. Dechant JE, Hendrickson DA 2000 Standing female equine urogenital endoscopic surgery. *Veterinary Clinics of North America: Equine Practice* 16 (2) 301-315
29. Delling V, Howard RD, Pleasant RS, Jary OI 2004 Hand-assisted laparoscopic ovari hysterectomy in the mare. *Veterinary Surgery* 33(5): 487-494
30. Desmaizieres LM, Martinot S, Lepage OM, Bareiss E, Cadore JL 2003 Complications associated with cannula insertion techniques used for laparoscopy in standing horses. *Veterinary Surgery* 32 (6): 501-506
31. Dusterdieck KF, Pleasant RS, Lanz OI, Saunders G, Howard RD 2003 Evaluation of the harmonic scalpel for laparoscopic bilateral ovariectomy in standing horses. *Veterinary Surgery* 32 (3): 242-250
32. Edwards RB, Ducharme NG, Hackett RP 1995 Laparoscopic Repair of a Bladder Rupture in the Foal. *Veterinary Surgery* 24: 60-63
33. Ensink JM, Klein WR 1998 Castration of horses and ponies by ligation of the spermatic cord. *European College of Veterinary Surgeons Abstracts* 8: 269



34. Ezeh UO, Shoulder VS, Martin JL, Breeson AJ, Lamb MD, Vellacott ID 1995 Local anaesthetic on Filshie clips for pain relief after tubal sterilisation: a randomized double-blind controlled trial. *The Lancet* 346: 82-85
35. Fayrer-Hosken RA, Caudle AB 1991 The laparoscope in follicular oocyte collection and gamete intrafallopian transfer and fertilization (GIFT). *Theriogenology* 36 (5): 709-723
36. Fiddes TM, Williams HW, Henderson GP 1996 An evaluation of the Filshie clip for post-partum sterilisation in Austria. *Contraception* 54 (5): 309-311
37. Fiddes TM, Williams HW, Henderson GP 1996 Evaluation of post-operative analgesia following laparoscopic application of Filshie clips. *British Journal of Obstetrics and Gynaecology*. 103: 1143-1147
38. Fio L 1995 Equine Laparoscopy. *Journal of Equine Veterinary Science* 15 (5): 218-219
39. Fischer AT, Kent-Lloyd KC, Carlson GP, Madigan JE 1989 Diagnostic Laparoscopy in the Horse. *Journal of American Veterinary Medical Association* 3: 289-92
40. Fischer AT 1991 Standing laparoscopic surgery. *Veterinary Clinics North America: Equine Practice* 7 (3): 641-647
41. Fischer AT, Vachon AM 1992 Laparoscopic cyrtorchidectomy in horses. *Journal of American Veterinary Medical Association* 201 (11): 1705-1708
42. Fischer AT, Vachon AM, Klein SR 1995 Laparoscopic inguinal herniorrhaphy in two stallions. *Journal of American Veterinary Medical Association* 207 (12): 1599-1601
43. Fischer AT 1997 Advances in diagnostic techniques for horses with colic. *Veterinary Clinics of North America: Equine Practice* 13 (2): 203-219
44. Fischer AT, Vachon AM 1998 Laparoscopic intra-abdominal ligation and removal of cryptorchid testes in horses. *Equine Veterinary Journal* 30 (2) 105-108

45. Fischer AT 1999 Laparoscopically assisted resection of umbilical structures in foals. *Journal of American Veterinary Medical Association* 214 (12): 1791-1792, 1813-16,
46. Fischer AT 2002 *Equine Diagnostic & Surgical Laparoscopy*. W.B. Saunders, Philadelphia
47. Fitch G, Schumacker J 1996 Infection of the spermatic cord of a pony gelding. *Equine Veterinary Education* 8 (5): 215-252
48. Galuppo LD, Snyder JR, Pascoe JR 1995 Laparoscopic anatomy of the equine abdomen. *American Journal Veterinary Research* 56 (4): 518-531
49. Gooden MD, Hulka JF, Christman, GM 1993 Spontaneous Vaginal Expulsion of Hulka Clips. *Obstetrics and Gynaecology* 81 (5): 884-886
50. Gottschalk RD, van der Berg SS 1997 Standing laparoscopically-aided ovariectomy in mares. *Journal of the South African Veterinary Association* 68 (3) 102-104
51. Gupta SP 1993 Experience in 4500 Cases of Laparoscopic Sterilization. *Journal of Internal Surgery* 78: 76-78
52. Hafez, ESE 1993 *Reproduction in Farm Animals* 6th edn, Lea & Febiger, Philadelphia
53. Hand R, Rakestraw P, Taylor T 2002 Evaluation of a vessel-sealing device for use in laparoscopic ovariectomy in mares. *Veterinary Surgery* 31 (3): 240-244
54. Hanrath M, Rodgerson DH 2002 Laparoscopic cryptorchidectomy using electrosurgical instrumentation in standing horses. *Veterinary Surgery* 31 (2): 117-124
55. Hartfield VJ 1993 Female Sterilization by the Vaginal Route: A Positive Reassessment and Comparison of 4 Tubal Occlusion Methods. *Aust. and N.Z. Journal of Obstetrics and Gynaecology* 33 (4): 408-412

56. Hendrickson DA, Wilson DG 1996 Instrumentation and techniques for laparoscopic and thoracoscopic surgery in the horse. *Veterinary Clinics of North America: Equine Practice* 12 (2): 235-259
57. Hendrickson DA, Wilson DG 1996 Laparoscopic Cryptorchidectomy in Standing Horses. *Proceedings of the Annual Convention of the American Association of Equine Practitioners* 42: 184-185
58. Hendrickson DA, Wilson DG 1997 Laparoscopic Cryptorchid Castration in Standing Horses. *The American College of Veterinary Surgeons* 26: 335-339
59. Hendrickson DA 2000 History and instrumentation of laparoscopic surgery. *Veterinary Clinics of North America: Equine Practice*. 16 (2) 233-250
60. Horattas MC, Rosser JC 1993 A new and simple approach to open laparoscopy. *Surgery, Gynaecology and Obstetrics* 176: 287-289
61. Hunt RJ, Boles CL 1989 Post castration eventration in eight horses (1982-1986). *Canadian Veterinary Journal* 30: 961-963
62. Hunt RJ 1991 Management of Complications Associated with Equine Castration. *Compendium Continuing Education Practice* 13 (12): 1835-1842
63. Javicek JC, Rodgerson DH, Boone BL 2004 Use of a hand-assisted laparoscopic technique for removal of a uterine leiomyoma in a standing mare. *Journal American Veterinary Medical Association* 225 (6): 880, 911-914
64. Keoughan CG, Rodgerson DH, Brown MP 2003 Hand-assisted laparoscopic left nephrectomy in standing horses. *Veterinary Surgery* 32 (3): 206-212
65. Klohnen A, Wilson DG 1996 Laparoscopic Repair of Scrotal Hernia in Two Foals. *Veterinary Surgery* 25: 414-416
66. Knobil E, Neill JD 1988 *The Physiology of Reproduction*. Raven Press, New York
67. Landsdowne JL, Boure LP, Pearce SG, Kerr CL, Caswell JL 2004 Comparison of two laparoscopic treatments for experimentally induced abdominal adhesions in pony foals. *American Journal of Veterinary Research* 65 (5): 681-686

68. Latimer FG, Eades SC, Pettifer G, Tetens J, Hosgood G, Moore RM 2003 Cardiopulmonary, blood and peritoneal fluid alterations associated with abdominal insufflation of carbon dioxide in standing horses. *Equine Veterinary Journal* 35 (3): 283-290
69. Marien T, Adriaenssen A, Hoeck FV, Segers L 2001 Laparoscopic closure of the renosplenic space in standing horses. *Veterinary Surgery* 30 (6) 559-563
70. Marien T 2001 Standing laparoscopic herniorrhaphy in stallions using cylindrical polypropylene mesh prosthesis. *Equine Veterinary Journal* 33 (1): 91-96
71. McKinnon AO, Voss JL 1993 *Equine Reproduction*. Lea and Febiger, Philadelphia
72. Mehl ML, Ragle CA, Mealey RH, Whooten TL 1998 Laparoscopic diagnosis of subcapsular splenic hematoma in a horse. *Journal of American Veterinary Medical Association* 213 (8) 1171-1173
73. Moll HD, Pelzer KD, Pleasant RS, Modransky PD 1995 A Survey of Equine Castration Complications. *Journal of Equine Veterinary Science* 15 (12): 522-526
74. Mueller POE, Parks AH 1999 Cryptorchidism in horses. *Equine Veterinary Education* 11 (2) 77-86
75. Nickels, FA 1988 Complications of Castration and Ovariectomy. *Veterinary Clinics of North America: Equine Practice* 4 (3): 515-523
76. Nord, HJ 1992 Complications of Laparoscopy. *Journal of Endoscopy* 24: 693-700
77. Palmer SE, Passmore JL 1987 Midline scrotal ablation technique for unilateral cryptorchid castration in horses. *Journal of American Veterinary Medical Association* 190 (3): 283-285
78. Palmer SE 1993 Standing laparoscopic laser technique for ovariectomy in five mares. *Journal of American Veterinary Medical Association* 24: 492-497
79. Palmer SE 1993 Fundamentals of Standing Equine Laparoscopy. *Proceedings American Association of Equine Practitioners* 39: 241-242

80. Palmer SE, St John Collier D 1998 Laparoscopy in the horse: Comparative keyhole surgery. *Equine Veterinary Journal* 30 (2): 1991-1992
81. Parks AH, Scott EA, Cox JE, Stick JA 1989 Monorchidism in the horse. *Equine Veterinary Journal* 21 (3) 215-217
82. Perkins NR, Frazer GS 1994 Reproductive Emergencies in the Stallion. *Veterinary Clinics of North America: Equine Practice* 10 (3): 671-683
83. Petersen HB, Hulka JF, Phillips JM, Surrey MW 1993 Laparoscopic Sterilization. *The Journal of Reproductive Medicine* 38 (8): 574-576
84. Petrizzi L, Varasaro V, Noble D, Vallanetti L 2004 Monorchidism in an Appaloosa stallion. *Veterinary Record* 155 (14): 424-425
85. Ragle CA, Schneider RK 1995 Ventral Abdominal Approach for Laparoscopic Ovariectomy in Horses. *Veterinary Surgery* 24: 492-497
86. Ragle CA, Schneider RK, Southwood LL 1996 Abdominal Laparoscopy in Horses. *Continuing Education* 18 (11): 1231-1239
87. Ragle CA, Southwood LL, Hopper S, Buote PL 1996 Laparoscopic ovariectomy in two horses with granulosa cell tumours. *Journal of the American Veterinary Medical Association* 209 (6): 1121-1124
88. Ragle CA, Southwood LL, Howlett MR 1998 Ventral Abdominal Approach for Laparoscopic Cryptorchidectomy in Horses. *Veterinary Surgery* 27: 138-142
89. Ragle CA 2000 Dorsally recumbent female equine urogenital endoscopic surgery. *Veterinary Clinics of North America: Equine Practice* 16 (2): 317-328
90. Roberts SJ 1986 *Veterinary Obstetrics and Genital Disease (Theriogenology)*. Published by the Author, Vermont
91. Robson S, Kerin J 1993 Recurrence of Pelvic Abscess Associated with a Detached Filshie Clip. *Aust and N.Z. Journal of Obstetrics and Gynaecology* 33 (4): 446-448
92. Rodgerson DH, Baird AN, Lin HC, Pugh DG 1998 Ventral Abdominal Approach for Laparoscopic Ovariectomy in llamas. *Veterinary Surgery* 27: 331-336

93. Rodgerson DH, Hanson RR 2000 Ligature slippage during standing laparoscopic ovariectomy in a mare. *Canadian Veterinary Journal* 41 (5): 395-397
94. Rodgerson DH, Belknap JK, Wilson DA 2001 Laparoscopic ovariectomy using sequential electrocoagulation and sharp transection of the equine mesovarium. *Veterinary Surgery* 30 (6): 572-579
95. Rodgerson DH, Brown MP, Watt BC, Keoughan CG, Hanrath M 2002 Hand-assisted laparoscopic technique for removal of ovarian tumors in standing mares. *Journal of American Veterinary Medical Association* 220 (10): 1475, 1503-1507
96. Ross MW 1991 Standing abdominal surgery. *Veterinary Clinics of North America: Equine Practice* 7( 3): 627-639
97. Ross MW 1991 Specific Indications and Preoperative Considerations. *Veterinary Clinics of North America: Equine Practice* 7 (3): 627-639
98. Schumacker J, Scrutchfield WL, Martin MT 1987 Peritonitis following castration in 3 horses. *Equine Veterinary Science* 7 (4): 220-221
99. Schumacker J 1996 Complications of castration. *Equine Veterinary Education* 8 (5): 254-259
100. Schummer A, Nickel R 1979 *The Viscera of the Domestic Mammals*. Paul Parey, Berlin
101. Schummer A, Wilkens H, Vollmerhaus B, Habermehl KH 1981 *The Circulatory System, the Skin and the Cutaneous Organs of the Domestic Mammals*. Paul Parey, Berlin
102. Searle D, Dart AJ, Dart CM, Hodgson DR 1999 Equine Castration: review of anatomy, approaches, techniques and complications in normal, cryptorchid and monorchid horses. *Australian Veterinary Journal* 77 (7) 428-434. Review
103. Shettko DL 2000 Complications in laparoscopic surgery. *Veterinary Clinics of North America: Equine Practice* 16 (2): 377-383



104. Shideler RK, Squires EL, Voss JL 1981 Equine Castration – Disappearance of Spermatozoa. *Equine Practice* 3 (2): 31-36
105. Shoemaker RW, Read EK, Duke T, Wilson DG 2004 In situ coagulation and transection of the ovarian pedicle: an alternative to laparoscopic ovariectomy in juvenile horses. *Canadian Journal of Veterinary Research*. 68 (1): 27-32
106. Sisson S, Grossman JD 1953 *The Anatomy of the Domestic Animals*. W.B. Saunders Co., Philadelphia
107. Soper NJ, Hunter JG 1992 Suturing and knot tying in laparoscopy. *Veterinary Clinics of North America: Equine Practice* 72 (5): 1139-1152
108. Sumiala S, Pirhonen J, Tuominen J, Mäepää J 1995 Increased Uterine and Ovarian Vascular Resistance Following Filshie Clip Sterilization: Preliminary Findings Obtained with Colour Doppler Ultrasonography. 23: 511-516
109. Sutter WW, Hardy J 2004 Laparoscopic repair of a small intestinal mesenteric rent in a broodmare. *Veterinary Surgery* 33 (1): 92-95
110. Thibault C, Levasseur MC, Hunter RHF 1993 *Reproduction in Mammals and Man*. Ellipses, Paris
111. Trostle S, White NA, Donaldson L, Freeman LJ, Hendrickson DA 1998 Laparoscopic Colopexy in Horses. *Veterinary Surgery* 25: 56-63
112. Trostle S 2000 Gastrointestinal endoscopic surgery. *Veterinary Clinics of North America: Equine Practice* 16 (2): 329-341
113. Trotter GW 1988 Normal and cryptorchid castration. *Veterinary Clinics of North America: Equine Practice* 4 (3): 493-513
114. Trumdle TN, Ingle-Fehr J, Hendrickson DA 2000 Laparoscopic intra-abdominal ligation of the testicular artery following castration in a horse. *Journal of American Veterinary Medical Association* 216 (10): 1569, 1596-1598
115. Trumdle TN, Hendrickson DA 2000 Standing male equine urogenital endoscopic surgery. *Veterinary Clinics of North America: Equine Practice* 16 (2) 269-284



116. Turner AS, McIlwraith CW 1989 Castration In: Techniques in Large Animal Surgery. Lea and Febiger, Philadelphia: 177-191
117. Van der Velden MA 1988 Ruptured inguinal hernia in new born colt foals: A review of 14 cases. Equine Veterinary Journal 20 (3): 178-181
118. Van der Velden MA 1988 Surgical treatment of acquired inguinal hernia in the horse: a review of 51 cases. Equine Veterinary Journal 20 (3): 173-177
119. Van der Velden MA, Rutgers LJE 1990 Visceral prolapse after castration in the horse: a review of 18 cases. Equine Veterinary Journal 22 (1): 9-12
120. Van Dijk P, Lankveld DP, Rijkenhuizen AB, Jonker FH 2003 Hormonal, metabolic and physiological effects of laparoscopic surgery using a detomidine-buprenorphine combination in standing horses. Veterinary Anaesthetic Analgesia 30 (2): 72-80
121. Varner DD, Schumacher J, Blanchard TL, Johnson L 1991 Diseases and Management of Breeding Stallions. American Veterinary Publications, Goleta
122. Waguespack R, Belknap J, Williams A 2001 Laparoscopic management of postcastration haemorrhage in a horse. Equine Veterinary Journal 33 (5): 510-513
123. Walesby HA, Ragle CA, Booth LC 2002 Laparoscopic repair of ruptured urinary bladder in a stallion. Journal of American Veterinary Medical Association 221 (12): 1715, 1737-1741
124. Walmsley JP 1999 Review of equine laparoscopy and an analysis of 158 laparoscopies in the horse. Equine Veterinary Journal 31 (6): 456-464
125. Weaver DA 1987 Acquired incarcerated inguinal hernia: a review of 13 horses. Canadian Veterinary Journal 28 (4): 195-199
126. Wilson DG, Reinertson EL 1987 A modified parainguinal approach for cryptorchidectomy in horses: an evaluation in 107 horses. Veterinary Surgery 16 (1): 1-4

127. Wilson DG 1990 Laparoscopy as an Aid in the Surgical Management of the Equine Hemicastrate. Proceedings of the Annual Convention of the American Association of Equine Practitioners 35: 347-353
128. Wilson DG, Dean A, Hendrickson DA, Cooley AJ, Degrave-Madigan E 1996 Laparoscopic methods for castration of equids. Journal of American Veterinary Medical Association 209 (1): 112-114
129. Wilson DG 2000 Dorsally recumbent male equine urogenital endoscopic surgery. Veterinary Clinics of North America: Equine Practice 16 (2): 285-300