

4.4.1.6 Vascular access: Venous cutdown, Great saphenous vein

1. Indications	164
2. Contraindications	164
3. Step by step procedure	164
4. Materials	166
5. Anatomical pitfalls	166
6. Complications (anatomically relevant)	169
7. References	170

1. Indications

- Hypovolemic shock with failed access to peripheral blood veins. (Should be done simultaneously with attempts to find a large-bore antecubital vein³)
- Operator not experienced in central venous catheterization.
- Especially useful in children¹¹ and infants of only a few months old^{4,22}.

2. Contra-indications

- If less invasive alternatives exist.
- When excessive delay would be required for the procedure to be performed.
- Previous coronary bypass surgery where the veins have been harvested
- Where hypertonic solutions need to be given intravenously.
- Local inflammatory process.
- History of severe peripheral vascular disease.

Relative contraindications:

- Abdominal trauma¹⁷.
- Lower extremity trauma.

3. Step by step procedure^{1, 2, 4, 10, 19, 20}

With small variations, this procedure is still performed very close to the original description of the procedure by Kirkham⁴ in 1945.

1. Prepare the skin of the ankle with antiseptic solution and drape the area.
2. Infiltrate the skin if time permits. Be careful not to injure the vein for it will obscure the field with blood. Apply a tourniquet high on the thigh.
3. Distal saphenous vein approach: Perform a full-thickness transverse skin incision of 2.5 cm over the vein, 1.5 cm superior and 1.5 cm anterior from the medial malleolus

if the vein cannot be seen¹⁸. The incision should commence at the anterior border of the tibia and extend to the posterior border of the tibia. (The incision should not commence over the anterior compartment of the leg where various muscle tendons including anterior tibialis muscle are found).

4. Identify the vein with blunt dissection and dissect it free from the accompanying structures as well as underlying periosteum. Take care to separate the saphenous nerve from the vein. Randolph⁵ refers to this step as the key to the procedure. Delivering the vein can be accomplished with a curved mosquito hemostat, twisting it firmly down through the incision to the periosteum and with a sweeping motion passing posteriorly to the vein to deliver it.
5. Elevate and dissect the vein for a distance of approximately 2-cm, to free it from its bed.
6. Ligate the distal, mobilized vein, leaving the suture in place for traction in the case of the distal great saphenous vein. If the proximal great saphenous vein is used, do not ligate the vein.
7. Pass a tie about the vein more proximally.
8. Make a small transverse incision (venotomy) and gently dilate the venotomy with the tip of a closed mosquito hemostat. Use the hemostat as a stage on which to perform the venotomy¹⁵.
9. No ligation, tying or incision of the vein is necessary if a standard intravenous (IV) catheter with a standard large lumen IV catheter is used. The vein is then punctured under direct vision, the cannula is threaded into the vein, and the needle is withdrawn to the skin surface.
10. Introduce a cannula through the venotomy and secure it in place by tying the upper ligature about the vein and cannula. The cannula should be inserted with adequate distance to prevent dislodging.
11. Attach the intravenous line to the cannula.
12. Stitch the catheter in place and close the incision with skin sutures.
13. Secure the catheter to the skin with adhesive tape after applying topical antibiotic ointment over the incision.

Alternative methods:

- Shiu¹⁰ describes a method where the skin is cut but the vein is not dissected, but subcutaneous tissue still covers the vein. The vein is also not ligated, but a catheter over needle device is inserted into the vein like any standard intravenous catheter. After inserting the catheter, the tissue is approximated with a stitch, thus preventing bleeding from around the catheter. The problem with ligating the vein is that it will never be suitable for reuse in the future¹⁶.
- A method where a small venotomy of 1-2 mm and a standard Seldinger wire-guided catheter are used has been described by Shockley *et al*¹⁶ and Klofas *et al*¹⁶. A wire-dilator-catheter assembly is passed into the lumen of the vein. The venotomy is then dilated to fit the catheter. Thereafter the wire and dilator are removed from the catheter. In a randomized, prospective crossover

study¹⁶, it was shown that the performance of the wire-guided technique was 22% faster on average compared to the classic technique.

Alternative veins:

- Great saphenous vein at the groin level.
- Basilic vein proximal and medial to the cubital fossa¹⁸.
- Cephalic vein at the wrist¹⁸.

4. Materials¹⁸

- Tourniquet
- Antiseptic skin preparation
- Sterile gloves and drapes
- Local anesthetic solution
- 3cc syringe with 25-ga needle
- Silk ligatures
- Nonabsorbable skin suture
- Tissue dissection scissors
- Needle holder
- Mosquito hemostat
- No 11 scalpel blade
- IV catheter – large-bore catheters preferred¹⁷. (A large bore catheter by itself does not guarantee high flow rates. The tubing size, fluid type and temperature also play an important role.)
- Forceps
- Intravenous fluid setup
- New Seldinger wire guided catheter if available¹⁵. (The use of this catheter makes tying off the distal vein unnecessary.)

5. Anatomical pitfalls

5.1 Distal saphenous vein

- This vein is the classic pediatric cutdown site⁵.
- The great saphenous vein originates on the dorsum of the foot at the medial marginal vein. It runs anterior to the medial malleolus halfway between the medial malleolus and the tendon of the tibialis anterior muscle, one handbreadth posterior to the patella at the knee joint and terminates in the femoral vein, 3 cm inferior to the inguinal ligament⁶.
- The following anatomical characteristics make the great saphenous vein ideal for

use as described by Randolph⁵:

- i) The vein is anatomically most consistently situated just anterior to the medial malleolus⁴.
 - ii) The vein is the only important structure in the region, with no tendons or arteries situated anterior to the medial malleolus. The saphenous nerve running along the vein should be avoided, but if injured has no great clinical implication. (The tendon of tibialis anterior is found in the anterior compartment of the leg).
 - iii) The vein lies on tough periosteum⁴.
 - iv) The vein can be withdrawn from a relatively small incision without injuring the vein. This is due to the elasticity of the vein.
- The great saphenous vein is located in the superficial fat layer. Therefore, if the incision exposes muscle fascia it is too deep. The vein is pulseless and thin-walled. The vein does not disrupt other emergency actions like taking arterial blood from the femoral artery, chest compressions in CPR etc. The vein has a very constant location: crosses one fingerbreadth anterior to the medial malleolus (or halfway between the medial malleolus and the anterior tibialis muscle) and continues up the anteromedial aspect of the leg.
 - Surface anatomy: one fingerbreadth anterior to the medial malleolus with the incision 1.5 cm anterior and superior to the medial malleolus⁹. Similar descriptions are given by others^{4,5}. In a normal volemic patient the vein can usually be identified by these methods. However, in a severely hypovolemic patient, it is difficult to identify the vein and distinguish the empty vein from the saphenous nerve and underlying periosteum¹⁴. Simon *et al*¹⁴ describes the incision to be made just above the medial malleolus, extending from the anterior tibial shin to the posterior border of the tibia. A curved hemostat is then advanced posterior to all the tissue within the incision. When spreading the tissue apart, all the structures can be identified. The saphenous vein can be easily distinguished from the white periosteum of the tibia. Simon *et al*¹⁴ have compared their anatomically based method to identify the vein, with previously identified methods^{4,5}. They found that the vein was identified in significantly less time. They did not use estimated measurements like fingerbreadths or centimeters because of individual patient variance. Their method also allows for easy memorization, a very important aspect in any emergency situation.
 - A method with a guide wired catheter by Shockley *et al*¹⁶ has been shown to be easier and 22% faster.
 - Klofas¹⁵ described the incision line as two finger breadths proximal to the medial malleolus, with a length of the anteromedial surface of the tibia. The incision should be through the skin, but not significantly into the subcutaneous tissue, for the vein is often just subcutaneous.

5.2 Proximal great saphenous vein

- Venous cut downs can also be performed at the proximal great saphenous vein at the groin level, the basilic vein in the cubital fossa and the cephalic vein²¹ at the wrist.
- The proximal great saphenous vein lies in the subcutaneous fat along the anteromedial aspect of the thigh with an outside diameter of 4-5mm⁶. This outside diameter permits a high rate of infusion.
- Proximal saphenous vein approach¹⁴: Make a horizontal incision of skin only from the point where the scrotal or labial fold meets the medial thigh and extend it laterally to a point past a vertical line coming from the lateral aspect of the pubic tubercle. The vein is found most frequently where an imaginary line running from the lateral aspect of the pubic tubercle crosses a horizontal line on the level where the scrotal or labial fold meet the medial aspect of the thigh. The vein is found in the superficial fat. The proximal saphenous vein is more easily identified by this method, compared to the description of making an incision on the anterolateral thigh parallel to the inguinal ligament and about 5-6 cm distal to it⁶.
- Another method: An incision is made at a point 3 to 4 cm below and lateral to the pubic tubercle¹².
- Schiowitz method¹³: The line of incision to find the proximal saphenous vein is found inferior to the groin skin crease, just medial to a perpendicular line dropped from the midinguinal point. The vein is identified and a venotomy done to pass bladder irrigation tubing. This ensures high flow rates (1330 ml/min) when compared to a 16F Foley (500ml/min) and 14F Foley (237ml/min) catheter. This study illustrates the point that large bore access is essential in severe hypovolemic states. This is consistent with Pouseille's law, which states that flow is proportional to catheter diameter. Cannulation of the great saphenous vein can be a good alternative when skill is lacking in gaining central venous access which is sometimes associated with higher complication rates.

5.3 Periosteum

- The great saphenous vein lies adjacent to the tibial periosteum

5.4 Saphenous nerve

- The nerve runs alongside the great saphenous vein. Injury to the nerve leads to sensory loss over a small area alongside the medial aspect of the foot. A longitudinal incision may prevent injury to the nerve, but does not provide sufficient exposure⁷.

- Injury to the nerve can be prevented by separating the nerve from the vein before ligating the vein.

5.5 Medial malleolus

- The great saphenous vein is found anterior to the medial malleolus and the tendons of tibialis posterior and flexor digitorum longus muscles as well as the posterior tibial artery⁵ and posterior to the tendon of the tibialis anterior muscle.

6. Complications (anatomically relevant)

- There is a minimal risk or complications.

6.1 Infection

- There is a higher risk of phlebitis in veins of the lower extremity.
- Septic complications vary, from local suppuration and phlebitis to systemic infection. These are related to the time the intravenous cannula remains in the vein. The infection rate rises from 50% to 78% when the catheter is left in place for more than 48 hours⁸. Moran *et al*⁸ showed that there is a poor correlation between phlebitis and infection. Non-bacteriologic phlebitis is most likely caused by chemical irritation due to the plastic catheter. Early catheter removal is important. Infection at the entry site can be diminished by applying a combined topical antibiotic ointment (containing neomycin, bacitracin and polymyxin) as was shown in a double-blind trial⁸.

6.2 Hematoma

- To prevent hematoma formation a catheter over needle device (standard large lumen IV cannulation set) should be used. The needle should not be larger in diameter than the catheter inserted due to consequent oozing of blood around the catheter which has been advanced through a bigger hole in the vein.

6.3 Time consuming

- The procedure can be time consuming especially if a venotomy is also performed. However, studies show that the time from skin preparation to bandaging averages less than 5 minutes⁵.

6.4 Trombotic occlusion

- This complication is usually seen when the technique of ligating the vein is followed¹⁰. The reuse of the same vein is usually not possible after vein ligation. This may be important in patients needing repeated venous infusions⁴.

- The complication can be avoided by using a different method for surgical cut-down of the vein. Shiu¹⁰ describes a method where the vein is not circumferentially dissected after the skin incision, but after visualizing the vein, a standard catheter over needle device is inserted. Because the catheter lumen is greater in diameter than the needle oozing from the entry site on the vein is minimal. This is additionally prevented by approximating the subcutaneous tissue over the vein by a thin stitch. In this way venous flow is not compromised. The catheter should be secured firmly to the surrounding skin after the procedure.

6.5 Inability to advance the catheter

- This complication may be encountered due to the valves in the vein and is usually found if the initial skin incision is made too far proximally⁴.

6.6 Incising the vein with the initial skin incision

- This complication can be avoided by grasping the skin with toothed forceps in the neighborhood of the incision and lifting it up. The vein is attached to the periosteum and therefore does not lift up with the skin⁴.
- The initial incision should be through the skin, but not through the subcutaneous tissue because the vein is found directly subcutaneously¹⁵.

6.7 Incorrect placement

- The catheter may advance alongside the vein in the subcutaneous tissue. In an exsanguinated patient it may be impossible to aspirate blood from the vein even when the catheter is correctly placed. Indications that the catheter was placed correctly are¹⁵:
 - i) The fact that the catheter was placed into the vein under direct vision,
 - ii) The ease of passage of the catheter and
 - iii) The unrestricted fluid flow through the vein.

6.8 Injury to the vein

- The great saphenous vein may be transected, perforated or the adventitia dissected during the procedure. This will make the vein unsuitable for use¹⁶. The potential for perforation of the posterior wall of the vein is considerably less with the wire-guided technique, compared to using a large bevelled needle¹⁶.

7. References

¹ American College of Surgeons. Committee on Trauma. Advanced Trauma Life Support Course for Physicians Student Manual. Chicago: American College of Surgeons, 1993: 107-110

² Shami SK, Hassanally DA. Manual of ambulatory general surgery: a step-by-step guide

to minor and intermediate surgery. London: Springer, 2000: 27-28

³ Fowler GC. Venous Cutdown . In Procedures for primary care physicians, Pfenninger JL, Grant CF. St Louis London: Mosby, 1994: 332-339

⁴ Kirkham JG. Infusion into the internal saphenous vein at the ankle. Lancet 1945; 2:815

⁵ Randolph J. Technique for insertion of plastic catheters into the saphenous vein.

Pediatrics 1959; 24:631

⁶ Dronen SC, Yee AS, Tomlanovich MC. Proximal saphenous vein cutdown. Ann Emerg Med 1981; 10:328

⁷ Dronen SC, Lanter P Venous cutdown In: Clinical procedures in emergency medicine by Roberts JR, Hedges JR, 3rd ed, Philadelphia; London: Saunders, 1998: 341

⁸ Moran JM, Atwood RP, Rowe M. A clinical and bacteriologic study of infections associated with venous cutdown. N Eng J Med 1965; 272:554

⁹ VanderSalm TJ, Cutler BS. Atlas of bedside procedures. Boston: Little Brown, 1979: 11-24

¹⁰ Shiu MH: A method for conservation of veins in the surgical cutdown. Surg Gynecol Obstet 1972; 134:315

¹¹ Dunmire SM, Paris PM. Atlas of emergency procedures. Philadelphia; London: Saunders, 1994

¹² Abrahams PH, Webb P. Clinical anatomy of Practical procedures. London: Pitman Medical, 1975: 39

¹³ Schiowitz MF. A Method for rapid intravenous infusion in shock resuscitation. Am J Emerg Med 1998;16:293-295

¹⁴ Simon RR, Hoffman JR. Modified new approaches for rapid intravenous access. Ann Emerg Med 1987;16:44-49

¹⁵ Klofas Ed. A quicker saphenous vein cutdown and a better way to teach it. The J of Trauma: Injury, Infection, and Critical Care 1997; 43(6):985-987

¹⁶ Shockley LW, Butzier DJ. A modified wire guided technique for venous cutdown access. Ann Emerg Med 1990;19:393-395

¹⁷ Dutky PA, Stenens SL, Maull KI. Factors affecting rapid fluid resuscitation with large-bore introducer catheters. J Trauma 1989;29:856-860

¹⁸ Eggertsen SC. Teaching venous cutdown techniques with models. J Fam Pract 1983;16(6):1165-1167

¹⁹ Knopp R. Venous cutdowns in the emergency department. JACEP 1978;7:439-443

²⁰ Wax PM, Talan DA. Advances in cutdown techniques. Emerg Med Clin North Am 1989;7:65-82

²¹ Talan DA, Simon RR, Hoffman JR. Cephalic vein cutdown at the wrist: Comparison to the standard saphenous vein ankle cutdown. Ann Emerg Med 1988;17:79-83.

²² Wright JE. Cutdown technique for intravenous infusion in infants. Med J Australia 1972;37:1203-1206

4.4.2 Office procedures

4.4.2.1 Epistaxis and nasal packing

1. Indications	172
2. Contraindications/ Precautions	172
3. Step by step procedure	172
4. Materials	176
5. Anatomical pitfalls	177
6. Complications (anatomically relevant)	184
7. References	187

1. Indications

- Any continuing episode of epistaxis, despite continuous external pressure of the ala nasi for at least ten minutes.

2. Contraindications

- The use of nasal balloons and catheters should be excluded in massive facial trauma with a suspected skull base fracture as the catheter may travel into the skull cavity.
- Clotting abnormalities. Aggressive nasal packing may cause further bleeding.
- Chronic obstructive airway disease. Posterior nasal packing may result in a significant drop in partial oxygen pressure in these patients
- Known or suspected cerebrospinal fluid leak.

Precaution: Epistaxis may be the presenting symptom of an underlying disease like leukemia, malignancies of the nose, sinuses or nasopharynx, congenital or traumatic arterial-venous malformations and Rendu-Osler-Weber disease³.

3. Step by step procedure

Step 1. Hemodynamic status

- Make sure the patient is hemodynamically stable. Intravenous fluid replacement should be given and the patient be sedated if necessary.

Step 2. History

- Enquire about illnesses like hypertension, angina and chronic obstructive airway disease.
- Many patients with epistaxis are hypertensive as well. However, no direct correlation has been proven between hypertension and epistaxis. Most authors now consider hypertension not to be a cause of epistaxis, but due to anxiety experienced by the patient suffering from the bleeding³. Therefore hypertension does not need treatment until the bleeding is controlled.

Shaheen²⁰ showed that there is an association between epistaxis and cardiovascular disease. Rigid and calcified arteries tend to bleed more persistently.

- Enquire about drug usage.

Step 3. Local compression

- Compression of the ala nasi or soft cartilaginous portion of the nose for at least 10 minutes, with the patient sitting up and leaning forwards to prevent blood from running into the nasopharynx. This will stop most nosebleeds. Pressure is applied directly on Little's area, where most nosebleeds (90%) originate^{2,15,17}. Ice packs across the nose may also help. Compression of the nasal bone has no effect on the nose bleeding at all¹⁵.

Step 4. Position.

- Position the head of the patient horizontally. Tilting of the head only allows inspection of the antero-superior area. Keep the base of the nose parallel to the floor. Let the patient sit upright, in the sniffing position: Head extended on the neck and neck flexed.
- Drape the patient with a gown and let the patient hold an kidney basin to collect bleeding.
- Light sedation can be given if the patient is very anxious.
- Allow the patient to clear his or her nose or use suction.

Step 5. Examination of the nares:

- Insert a nasal speculum in the nose. Good light is essential
- Remove blood clots from the nose and inspect the nose with a good light to find the site of bleeding.
- Identify the source of the bleeding – anterior or posterior by inspection.
- The middle turbinate is a convenient landmark to relate the bleeding to, either above, below, in front or behind.
- If the bleeding is too profuse, administer a topical anesthetic and a vasoconstrictor (lignocaine with epinephrine) on cotton pledgets. Cocaine solution can also be used.
- Most cases of anterior epistaxis occur in Little's area¹⁵. Inspect the area closely for bleeding or ulceration.
- If no anterior source is found and bleeding continues down the nasopharynx, assume a posterior source and pack the nose with an anterior and posterior pack

Step 6. Cautery

- This may be chemical or electrical. Chemical cauterization with silver nitrate is more suitable for use in the Accident and Emergency Department and is ideal in children.

- The bleeding must be visible and accessible.
- In case of an anterior source bleeding, the site can easily be identified and very effectively cauterized. If the site can not be identified, it should be found. A dilated vessel, small crust or heaped-up mucosa may be the source of bleeding³.
- Silver nitrate sticks may cauterize the area, cause sclerosis of the vessels and thickening of the mucosa. Silver nitrate does not cauterize an active bleeding, therefore hemostasis must first be achieved.
 - Cauterize above the bleeding source first.
 - Cauterize around the bleeding source in a circular fashion which will provide hemostasis to cauterize the bleeding source.
 - Wipe away any excess silver nitrate to prevent cauterization of other areas.
 - Cauterization with silver nitrate should be done for at least 20 seconds.
- **Electrocautery** – Electrocautery is done in the same manner as the silver nitrate.
Cauterization is more intense and penetrates more quickly than silver nitrate.
Take care not to perforate the septum due to repeated and aggressive cauterization.
If hemostasis is achieved no nasal packing is necessary. If there is recurrent bleeding the anterior cavity should be packed.

Step 7. Anterior nasal packing

Adequate anesthesia and proper visualization is essential.

- Packing is applied in a layer fashion, Each layer spans the entire length of the nasal cavity. This will prevent the gauze from migrating to the nasopharynx.
- Usually a bismuth iodoform paste pack (BIPP) is used, which is both antiseptic and comforting.
 - Visualize the floor of the nasal cavity.
 - Lay the first layer across the nasal floor.
 - Withdraw the speculum and reintroduce it on top of the first layer.
 - Place a second layer in an identical way.
 - Use a bayonet forceps to push the previously placed packing down onto the floor of the nose.
 - A complete anterior nasal pack, can tamponade a bleeding point anywhere in the nasal cavity.
 - The pack functions by direct pressure on the bleeding site and by causing inflammation and edema of the nasal mucosa³.
 - Remove the pack after 2-3 days, depending on the severity of the bleeding.

- Newly designed tampons can also be used. After insertion, contact with moisture will cause them to swell. An example is the Merocel nasal pack. This pack expands to many times its original size when it is wet. Prophylactic antibiotics should accompany the pack and it should be removed within 48 hours.

Step 8. Posterior nasal packing

- This pack is necessary if no source of bleeding is found anteriorly and the patient continues to bleed down the nasopharynx. Anterior nasal packing will not tamponade this source of bleeding.
- The goal of a posterior pack is to directly compress the sphenopalatine artery or the ethmoidal arteries²⁶.
- Anesthetize the patient's nasal cavity and nasopharynx with a topical anesthetic spray.
- Prepare a roll of gauze, with two no 2 silk ties secured around the middle and extending in opposite directions.
- Place a no 10 rubber Foley's catheter through the bleeding nostril.
- When seen in the oropharynx, grasp it into and out of the oral cavity.
- Attach the Foley's catheter to one of the silk ties secured to the gauze pack. Retract the Foley catheter through the nose, thus carrying the no 2 silk tie through the nasopharynx into and out of the nasal cavity.
- Pull the pack into the nasopharynx
- The tie coming from the nose is to secure the position of the nasal pack
- The tie in the oral cavity will be used to remove the pack and is taped on the cheek, but should not be under any tension for it will cut into the soft palate¹³.
- Pack the anterior nasal cavity as well.
- The pack can be left in for 3 days until oozing has stopped.
- The pack is uncomfortable for patients, and they often need to be sedated.
- Juselius²³ reports on 1724 patients of which 24.8% required posterior nasal packing, 5.6% required some form of surgery and 28.5 percent required blood transfusion.

Alternative 1: Inflatable balloon pack

- Wurman *et al*³ suggests using balloon tamponade for posterior epistaxis, as an emergency measure before referring the patient the next day. It can also be kept in place for two and up to a maximum of three days.
- A Foley's catheter can be very successfully used as a posterior pack^{4, 24}. This is due to direct pressure of the balloon on the bleeding point and by pressure on the turbinates and therefore decreasing the vascularity of the nose⁵. A Foley's catheter is cheap and is usually readily available.
- Insert a no 12F Foley with 30ml balloon through the bleeding nostril into the oropharynx.
- Inflate the balloon half way with half the required volume of saline. Balloon inflation with air deflates over time.

- Slowly pull the catheter into the nasopharynx and secure it against the posterior aspect of the middle turbinate. Then inflate the remainder of the volume.
- This method should minimize discomfort and complications⁵.
- When inflating the balloon before the balloon is in position will require strong anterior pulling which is very uncomfortable and it will be impossible to wedge the balloon into the smaller posterior choana.
- If there is pain or inferior displacement of the soft palate, deflate the balloon until the pain resolves.
- Do not inflate the balloon if it is not in the correct position in the nasopharynx. This will cause ineffective hemostasis⁵.
- A dual balloon pack may also be used. It has a posterior balloon, which is inflated with 10ml of saline, and an anterior balloon, which is inflated with 30 ml of saline. The posterior balloon is located in the posterior aspect of the nasal cavity and proximal nasopharynx, whereas the anterior balloon is in the anterior nasal cavity.
- Wareing describes an improved technique to fixate the Foley's catheter⁴ by using a syringe clamped around the catheter.

Advantages:

- According to Wurman³, the use of a Foley's catheter as a balloon pack is more convenient for the patient compared to a posterior nasal pack.
- If bleeding starts again, more water can be added to the balloon. An amount of 1 cc can be added at a time until bleeding is controlled or maximal balloon volume is reached.
- A balloon pack exerts more pressure directly onto the bleeding site than gauze packing.

Alternative 2: Avitene

Walike *et al*²⁴ reports the use of Avitene. This is an absorbable hemostatic agent made from purified bovine corium collagen. It is applied topically. According to Walike *et al*²⁴ it works effectively.

4. Materials

- Good light, ideally a headlight. An otoscope can also be used.
- Suction.
- Gloves, gown and mask for the physician.
- Topical anesthetic.
- Topical vasoconstrictor.
- Nasal speculum.
- Tongue depressor.
- Scissors.
- Bayonet forceps.
- Kidney basin.

- Gauze.
- Dental rolls or cotton.
- Surgical silk ties.
- Silver nitrate sticks or electrocautery.
- Pediatric Foley catheters and a no 12F Foley's catheter.
- Topical antibiotic ointment.

5. Anatomical pitfalls

5.1 External nose

- The external nose consists of a bony vault, a cartilaginous vault and a lobule. The bony vault consists of the nasal bones, the frontal processes of the maxillae, and the nasal spine of the frontal bone¹.

5.2 Nasal cavity

- The nasal cavity is a pyramidal structure with its base attached to the facial skeleton. The nasal cavity continues posterior with a right angle to the face¹.
- The nasal cavity is divided by the nasal septum into two compartments opening anterior via the nares and posterior via the choanae to the nasopharynx². Each compartment has a roof, floor, medial and lateral wall.
- The mucosal lining of the nose consists of ciliated columnar epithelium, interspersed with mucous-secreting goblet cells.

5.3 Roof of the nose

- The roof of the nasal cavity is formed from anterior to posterior by the nasal and frontal bones, the cribriform plate of the ethmoid bone and posteriorly the downslowing body of the sphenoid bone².

5.4 Nasal septum

- The nasal septum is formed by the perpendicular plate of the ethmoid from superior and the vomer from inferior. Anteriorly attached to these bony structures is the cartilaginous part of the septum. The nasal septum has a free posterior edge¹.
- Deviations of the septum are common (up to 75% of the adult population²) and may be associated with compensatory hypertrophy of the lateral wall which may cause nasal obstruction. Most of the deviated septae are from traumatic origin, probably from minor injuries in childhood causing a minor dislocation of the septal cartilage².

5.5 Nasal lobule

- The nasal lobule consists of the nasal tip, the lower lateral cartilages, the fibro fatty

alae forming the lateral margin of the nostril, the vestibule and columella. The lower lateral cartilages have a medial and lateral crus to form the U-shaped dome of the nasal vestibule to keep the nostril patent¹.

5.6 Lateral wall of the nasal cavity.

- The lateral wall of the nasal cavity is formed by the frontal process of the maxilla anteroinferiorly, the nasal bones anterosuperiorly, the nasal aspect of the ethmoid superiorly and the perpendicular plate of the palatine and medial pterygoid plate behind.
- Three conchae bones forming the three turbinates are found with three meati. The superior and middle concha are part of the ethmoid bone and the inferior concha is a separate bone.
- The paranasal sinuses open to orifices in the lateral nasal wall²:
 - Sphenoid sinus – spheno-ethmoidal recess
 - Posterior ethmoidal cells – superior meatus
 - Middle ethmoidal cells – middle meatus on the bulla ethmoidalis
 - Maxillary sinus – middle meatus in the hiatus semilunaris
 - Anterior ethmoidal cells – middle meatus, anterior to the hiatus semilunaris at the infundibulum
 - Frontal sinus – middle meatus through the frontonasal duct.
 - Nasolacrimal duct – inferior meatus

5.7 Floor of the nasal cavity

- Anteriorly, the floor is formed by the palatine process of the maxilla and posteriorly by the horizontal plate of the palatine bone².

5.8 Conchae

- These horizontal bony ridges project medially from the lateral wall, each overhanging a meatus.

5.9 Meati

- The paranasal sinuses and nasolacrimal duct open into these meati. Of special importance is the nasolacrimal duct opening in the inferior meatus and the maxillary sinus, which opens into the hiatus semilunaris in the middle meatus.

5.10 Blood supply¹

Blood supply to the nose come from the internal and external carotid arteries. The majority comes from the external carotid artery¹³.

There is a free anastomosis between the branches of the external carotid on the same side

and corresponding branches on the other side¹³.

- The **sphenopalatine artery**, a branch from the maxillary artery (branch of the external carotid) enters the nose via the sphenopalatine foramen and supplies the postero-inferior aspect of the lateral wall and the corresponding aspect of the septum. From here it descends to reach the incisive foramen to the surface of the hard palate. The sphenopalatine artery has a medial and lateral branch. The lateral branch supplies the lateral nasal wall and the medial also called the **nasopalatine artery** supplies the septal wall.
The **greater palatine artery**, also a branch of the maxillary artery, supplies the posterior part of the nasal septum. It also supplies the turbinates and meati laterally³. The sphenopalatine artery is considered the primary source of blood supply to the nasal septum.
- **The anterior and posterior ethmoidal arteries** of the internal carotid artery supply the anterosuperior aspect of the lateral wall as well as the corresponding aspect of the nasal septum. They reach the nasal cavity via the ophthalmic artery.
The **anterior ethmoidal artery** enters the nasal cavity next to the crista galli and runs downward over the anterior superior aspect of the nasal cavity¹³. The posterior ethmoidal artery is much smaller than the anterior ethmoidal artery.

Bleeding from these arteries arise from the superior nasal vault and the superior and posterior part of the nasal septum.

Histological sections of the anterior ethmoidal artery and sphenopalatine artery at their entry point into the nose show that the anterior ethmoidal artery is much smaller in diameter. Therefore bleeding from the ethmoid region must be rare.

This bleeding is very occasional¹³ and can only be identified endoscopically³.

- **The superior labial branch** of the facial artery, supplies the anterior part of the septum as well as the anterior lateral nasal mucosa.
- **The vestibule of the nose** receives terminal branches of both the anterior ethmoid and the sphenopalatine artery as well as nasal branches from the superior labial artery
- **Anterior epistaxis**
 - Branches from both the internal and external carotid arteries supply the nasal septum. An anastomotic site is found on the anteroinferior septum, which is known as Little's area, and is the most common site for epistaxis^{2,15}. Little¹⁷ first described bleeding from this lower anterior part of the septum in 1879. Kiesselbach¹⁸ also described the area a few years later in 1884. Little's area and Kiesselbach's area are therefore both used to describe the same area. Both authors did not describe the anatomy of the area. Three of the four cases described by Little¹⁷ were due to arterial bleeding.

- The four main branches anastomosing on the anteroinferior nasal septum (Little's area¹⁷) are:
 - Anterior and posterior ethmoidal arteries of the ophthalmic artery, from the external carotid artery,
 - Sphenopalatine artery from the maxillary artery, from the external carotid artery and the
 - Superior labial artery, from the facial artery, from the external carotid artery.

A prominent blood vessel in this area can often be seen running from inferior to superior. The blood vessels are found within the epithelium, tunica propria and perichondrium of the cartilaginous portion of the nasal septum. The capillary bed of this portion of the nose can easily be traumatized¹⁶.

- Bleeding can also come from the mid portion of the septum, and can usually be easily managed by cautery³.
- Spontaneous bleeding through the nares is almost always septal in origin³.

- **Posterior epistaxis**

- Posterior epistaxis may be either arterial or venous³.
- The bleeding is almost certainly posterior if the patient's first awareness of bleeding is into the nasopharynx³.
- Posterior epistaxis is usually a vigorous bleeding, lasting for minutes or even hours. Significant blood loss is associated with posterior epistaxis, of which the patient is usually unaware.
- The most common source of posterior epistaxis, is the sphenopalatine artery, emerging from the sphenopalatine foramen, which is located at the posterior aspect of the middle turbinate. The artery supplies the turbinates from their posterior aspect and the posterior part of the nasal septum. More elderly patients usually bleed from the posterior nasal passages.
- Woodruff⁸ identified a venous plexus on the posterior section of the lateral wall of the inferior meatus extending posterior to the soft palate, the so-called naso-nasopharyngeal plexus. There is an accompanying inferolateral branch of the sphenopalatine artery¹⁶.
- Wurman *et al*³ uses the eponym 'Woodruff's plexus⁸' to describe blood vessels in the following areas: 1 cm posterior of the nasal floor, inferior meatus, inferior turbinate and middle meatus, the vertical strip of mucosa anterior to the Eustachian tube and the mucosa lateral and superior to the posterior choana.

- Hallberg¹³ reports that in 50.9% of their 106 patients requiring hospitalization, the source of bleeding was from Little's area and in 40% from the posterior part of the nose. Of the posterior bleeders, half seems to be from the sphenopalatine artery and the other half from the venous naso-nasopharyngeal plexus.
- Hallberg¹³ classified the source of nose bleeding of 106 patients requiring hospitalization during a five year period as follows: Little's area¹⁷ (27.3%), sphenopalatine or nasopalatine artery (10.4%), diffuse bleeding (6.6%), turbinates (4.7%), naso-nasopharyngeal plexus (11.3%), anterior septal perforation (5.7%), behind spurs and severe septal deflections (5.7%), anterior ethmoidal artery and vein (5.7%) and undetermined (posterior) (22.6%).
- Woodruff⁸ summarizes the blood supply to the lateral wall of the nose and the nasal septum as follows:

Arteries of the lateral wall of the nose

- External carotid
 - Sphenopalatine from the maxillary artery
 - Greater palatine from the maxillary artery
 - Infraorbital from the maxillary artery
- Internal carotid
 - Anterior and posterior ethmoidal arteries from the ophthalmic artery

Arteries of the nasal septum

- External carotid -
 - Sphenopalatine from the maxillary artery
 - Greater palatine from the maxillary artery
 - Septal branch of the superior labial artery from the facial artery
- Internal carotid -
 - Septal branches of the anterior and posterior ethmoidal arteries from the ophthalmic artery.

- Walike *et al*²⁵ gives a useful conceptual overview of the arteries supplying the nose:

External carotid artery

- Maxillary artery
 - Sphenopalatine artery
 - Posterior nasal septal artery
 - Posterior lateral nasal artery
 - Nasopalatine artery
 - Descending palatine artery
 - Greater palatine artery
 - Lesser palatine arteries
- Facial artery
 - Superior labial artery
 - Septal artery
 - Alar artery

Lateral nasal artery
Angular artery
Ascending palatine artery

Internal carotid artery

Ophthalmic artery Anterior ethmoidal artery
Posterior ethmoidal artery

- Zuckerkandl²¹ divided the arterial distribution in the nose into two regions from the internal and external carotid arteries. Weddell²² describes the middle turbinate on the lateral nasal wall and a corresponding imaginary line on the nasal septum as the division between the internal and external carotid artery's distribution. The region above the line is supplied by the internal carotid artery and below the line by the external carotid artery.
- Zuckerkandl²¹ reports that the middle turbinate is exclusively supplied by the maxillary artery from the external carotid artery. A vessel from the same maxillary artery, supplies the posterior part of the superior turbinate and meatus as well as a corresponding vessel to the septum. The area that is supplied by the internal carotid artery is therefore smaller than Weddell's²² description.
- Shaheen²⁰ reports in a series of 72 patients, that there were very few bleeders originating from the anterior ethmoidal area and no cases from the lateral nasal wall at all.

5.11 Mechanics of the arterio-arterial anastomoses

- The internal and external carotid arteries form an anastomoses in the nose. This explains why there is still persistent bleeding in a number of cases after ligation of the external carotid artery. Previously it was thought that the wrong artery was ligated²⁰. Lowering of the pressure in the external carotid artery, will cause shifting of blood from the upper internal carotid area of the nose to the lower external carotid area across the anastomoses in the nasal mucosa.
- Shaheen²⁰ demonstrated the anastomotic network by injecting dye into the internal carotid artery and studying the spread of dye with and without occlusion of the external carotid artery. In the two cases where there was no occlusion of the external carotid, the dye appeared in the periorbital skin but not in the nose. In six cases where the external carotid artery was occluded, there was a dramatic inflow and displacement of blood (dye) from the cribriform plate towards the upper half of the nasal septum and lateral nasal wall.
- Shaheen²⁰ also demonstrated that bleeding from a point in the territory of the external carotid artery continued after maxillary artery ligation. This is explained by the anastomoses between the sphenopalatine (maxillary artery; external carotid) and ethmoidal arteries (ophthalmic artery; internal carotid).

5.12 Venous drainage¹

- Venous drainage from the nose is via the sphenopalatine, facial and ophthalmic veins, which communicate with the dural sinuses especially the cavernous sinus². Small veins also pass the cribriform plate to the inferior surface of the frontal lobes of the brain. Infection in the nasal cavity and paranasal sinuses can therefore spread intracranially.
- Batson¹⁹ studied the veins of the nose by corrosion preparations. He found that the veins form a mat throughout the nasal mucous membrane, being thickest in the nasopharynx and the turbinates of the nose. There are numerous interconnections with veins in the nasal mucosal network and with veins of the underlying bone. The veins continue at the ostia of the sinuses into the cavities of the sinuses.

This venous network forms the basis for edema and engorgement with blood. The nasal venous network of the septum of the nose has a thickness of 0.5 to 1.0 mm.

The veins form a valveless network.

5.13 Nerve supply¹

- The nasociliary branch of the ophthalmic division as well as the maxillary division of the trigeminal nerve provide sensation to the nasal cavity.
- Most of the septum is supplied by the nasopalatine branch of the sphenopalatine nerve, which comes from the maxillary division via the pterygopalatine ganglion in the pterygopalatine fossa. The anterior part of the septum is supplied by the anterior ethmoidal nerve branch of the ophthalmic division of the trigeminal nerve.
- The posterior aspect of the lateral nasal wall is innervated by the short sphenopalatine nerves. Anteriorly the lateral nasal wall is supplied mostly by the anterior ethmoidal nerve. The inferior turbinate is supplied by the anterior superior alveolar nerve and the greater palatine nerve.
- The floor of the nose is anteriorly supplied by the anterior superior alveolar nerve and posteriorly by the greater palatine nerve.
- The nasopharynx is supplied by the glossopharyngeal nerve (IX) and when provoked by a nasal pack or endoscope, may give rise to the 'gag' reflex, of which the motor function is supplied by the vagus nerve (X).
- The olfactory nerve supplies the olfactory zone of the nose, which is the most superior part of the nasal septum as well as the lateral walls of the nasal cavity².

5.14 Cribriform plate¹

- This forms the roof of the nasal cavity and forms part of the ethmoid bone. The cribriform plate is just inferior to the anterior cranial fossa. Branches from the olfactory bulb enter the nasal cavity through the cribriform plate and thus explains why patients with a skull base fracture may present with anosmia.

5.15 Children^{3 12}

- Epistaxis in children is mostly from Little's area^{2,15}. Nose picking associated with crust formation in the presence of an upper airway infection is often the cause.
- A nasopharyngeal angiofibroma should be considered in the case of a posterior nosebleed.
- Two-finger compression of the soft sides of the nose (ala nasi) usually stops the bleeding effectively.
- In a randomized clinical trial, Ruddy *et al*¹² demonstrated no significant difference in treating epistaxis in children with an antiseptic nasal barrier cream (Naseptin) or with silver nitrate cautery. Both methods work by stopping the bleeding vessels by heat and scar tissue formation.
- Von Willebrand's disease is not uncommon in children presenting with isolated epistaxis.

6. Complications (anatomically relevant)

6.1 Septal perforation

- A septal perforation may cause bleeding, which may result in a chronic anemia³.
- Silver nitrate cautery is less likely to cause a septal perforation than electrocautery. It is however less effective for large bleeders.
- Bilateral cautery should be avoided as cutting off the blood supply to the nasal septum from both sides may result in perforation.
- Always palpate the nasal septum before cauterization, to ensure the integrity of the cartilage³.

6.2 Septal hematoma

- A septal hematoma may be due to trauma to the nasal septum. This hematoma forms between the perichondrium and the cartilage. A septal hematoma should be treated, or it may cause septal perforation, a septal abscess and cartilage destruction with a saddle-nose deformity.
- A septal hematoma is diagnosed by inspecting the nasal septum for swelling and pain.
- Drainage of the hematoma is done by incising the mucosa horizontally over the hematoma. The blood clot should be removed by suction and the septum rinsed with normal saline. A small amount of mucosa should be excised to prevent premature closure of the incision. The nasal cavity should then be packed.

6.3 Persistent bleeding in the elderly

- Shaheen²⁰ has demonstrated in a histological study that the vessels in the elderly are more prone to bleed persistently, due to a collagenous change in the muscular wall of the medium and small arteries supplying the nose. The larger vessels

demonstrated significant calcification and not atheroma formation in his study. Elderly patients usually bleed from the posterior nasal passages.

- Epistaxis is usually more severe in elderly people due to the atherosclerotic changes of the blood vessels which cause them to gape and therefore bleed more persistently¹³.

6.4 Infection: Sinusitis, rhinitis and nasopharyngitis

- Any anterior nasal pack may obstruct drainage of the paranasal sinuses and nasolacrimal duct. Also, due to the foreign body in the nose, mucous production will increase and be a focus for infection. This includes sinusitis and nasopharyngitis. Sinusitis is usually seen if the nasal pack stays in for more than 24 hours. Prophylactic antibiotics are necessary to prevent sinusitis³.
- Rhinitis is associated with anterior packing.

6.5 Toxic shock syndrome

- Toxic shock syndrome has been described by Tag *et al*⁷ related to nasal packing. The syndrome is caused by a toxin released by *Staphylococcus aureus* growing on the nasal pack itself³. The onset is characterized by vomiting and diarrhea with high fever. This may lead to multisystem organ dysfunction. The gauze should therefore be coated with topical broad-spectrum antibiotics. Systemic antibiotics should also be given.

6.6 Tissue necrosis

- Alar necrosis can occur due to too much pressure from a Foley's catheter or posterior nasal pack.
- Nasal mucosa and soft palate necrosis can occur secondary to improper placement of the pack or balloon.
- All packing should be removed within 3 days³.

6.7 Hemotympanum

- A hemotympanum develops when blood is forced up the Eustachian tube into the middle ear. This complication has been reported with the use of postnasal packs¹³.

6.8 Otitis media.

- Otitis media may result from obstruction of the Eustachian tube orifice by a posterior nasal pack²⁴.

6.9 Transient bacteremia

- Approximately 12% of patients with nasal packs develop transient bacteremia²⁴.

Patients with cardiac valve disease should be appropriately treated and other treatment options should possibly be sought.

6.10 Iatrogenic bleeding

- Anterior bleeding from the lateral wall is often due to trauma caused by an inexperienced practitioner looking for an unidentified bleeder³.

6.11 Breakthrough bleeding^{3,6}

- Bleeding may continue despite cautery and nasal packing. It may be necessary for an otolaryngologist to perform one of two advanced procedures. The internal maxillary artery can be ligated. During this procedure the sphenopalatine artery is ligated as well. The second recent procedure is a posterior endoscopic cautery. The latter has no complications associated with posterior nasal packing or balloon tamponade.
- Bleeding from the inferior and middle meatus, or the medial surface of the inferior turbinate, cannot be stopped effectively by nasal packing or balloon tamponade³. Endoscopic cautery is necessary.

6.12 Dislodgement of the nasal pack

- The nasal pack may dislodge and fall into the oropharynx and further down into the laryngopharynx causing asphyxiation, vomiting and aspiration²⁴.

6.13 Hypoventilation

- Patients with posterior nasal packs should be admitted in hospital for sedation and monitoring. Especially those patients with lung disease who are at risk of hypercarbia and hypoxia with a posterior nasal pack. Monitoring of arterial gas levels is necessary in these patients²⁴.

6.14 Complications associated with posterior nasal packs

- Fairbanks⁹ reports on disadvantages like hypoxia and hypoventilation being responsible for the increased rate of myocardial infarction and cerebrovascular accidents in patients with posterior nasal packs. Work on dogs suggests that packing stimulates the vagal reflex, causing bradycardia, hypotension and inhibition of respiratory function¹⁰.
- Wetmore *et al*¹¹ also demonstrated that posterior nasal packing can cause sleep apnea.
- Spar *et al*¹⁴ reports on osteomyelitis of the base of the sphenoid bone with meningitis and cranial nerve lesions due to a nasopharyngeal abscess after posterior nasal packing. Injury to the mucosa in the nasopharynx secondary to nasal packs or instrumentation may give rise to the development of a

nasopharyngeal abscess²⁴.

- Wurman³ suggests that due to these disadvantages this procedure should be rarely used.

6.15 Complications associated with nasal balloon tamponade³

- The pressure is unlikely to be directed at the exact bleeding site posteriorly. Control actually comes from mucosal edema.
- Balloons leak slowly through the valve and the latex.
- Discomfort of the balloon in the nasopharynx may make pain medication and sedation necessary.
- Pressure necrosis of the nostril rim can occur. A gauze pad should be used over the skin. Wareing *et al*⁴ describes an improved technique to fixate the Foley's catheter by using a syringe clamped around the catheter on the external surface of the nose.
- There are no studies showing the risk of balloon tamponade regarding hypoxia, myocardial infarction and sleep apnea.

6.16 Cardiac arrhythmias

- Cardiac arrhythmias can occur due to vagal stimulation¹⁰.

6.17 Aspiration

- Aspiration of blood or packing material is a definite risk²⁴.

7. References

- ¹ Morris IR. Functional anatomy of the upper airway. Review. Emergency Medicine Clinics of North America 1988 Nov;6(4):639-69,
- ² Ellis H, Feldman S. Anatomy for Anaesthetists, 6th Ed. Oxford: Blackwell Scientific Publications, 1993: 6-16
- ³ Wurman LH, Sack JG, Flannery JV. The management of epistaxis (review). Am J Otolaryngol 1992;13:193
- ⁴ Wareing MJ, Gray RF. Foley catheter fixation in posterior epistaxis. J Laryngol Otol 1993;107:1032
- ⁵ Hartley C, Axon PR. The Foley catheter in epistaxis management: A scientific appraisal. J Laryngol Otol 1994;108:399-402
- ⁶ Viducich RA, Blanda MP, Gerson LW. Posterior epistaxis: Clinical features and acute complications. Ann Emerg Med 1995;25:592
- ⁷ Tag AR, Mitchell FB, Harell M, Morrison WV. Toxic shock syndrome: Otolaryngologic presentations. Laryngoscope 1982;92:1070
- ⁸ Woodruff GH Cardiovascular epistaxis and the naso-nasopharyngeal plexus. Laryngoscope 1949;59:1238
- ⁹ Fairbanks DNF Complications of nasal packing. Otolaryngol Head Neck Surg 1986;

94:412

- ¹⁰ Angell James JE, Daly Md. Nasal reflexes. *Proc R Soc Med* 1969; 62(12):1287-93
- ¹¹ Wetmore SJ, Scrima L, Hiller FC Sleep apnea in epistaxis patients treated with nasal packs. *Otolaryngol Head Neck Surg* 1989;98:596
- ¹² Ruddy J, Proops DW, Pearman K, Ruddy H. Management of epistaxis in children. *International J of Pediatr Otorhinolaryngol* 1991;21:139-142
- ¹³ Hallberg OE. Severe nosebleed and its treatment *JAMA* 1952;148:355
- ¹⁴ Spar AA, Williams HL. Osteomyelitis of the basisphenoid and basiocciput with meningitis and cranial nerve palsies as a complication of nasopharyngeal packing for control of epistaxis: Report of a case with recovery. *Arch Otolaryngol* 1947;46:473-477
- ¹⁵ McGarry GW, Moulton C. The first aid management of epistaxis by accident and emergency department staff. *Arch Emerg Med* 1993;10:298-300
- ¹⁶ Hara HJ Severe epistaxis. *Arch Otolaryngol Head Neck Surg* 1962;75:258
- ¹⁷ Little JL. A hitherto undescribed lesion as a cause of epistaxis, with four cases. *The Hospital Gazette* 1879;6:5
- ¹⁸ Kiesselbach W. Ueber spontane Nasenblutungen. *Berliner Klinische Wochenschrift* 1884(June);16:375
- ¹⁹ Batson OV. Venous networks of the nasal mucosa. *Ann Otol* 1954;63:571-580
- ²⁰ Shaheen OH Arterial epistaxis. *J Laryngol Otol* 1975;89:17
- ²¹ Zuckerkandl E. Normale und Pathologische Anatomie der Nasenhöle. W. Braumuller: Wien und Leipzig 1892;1:128
- ²² Weddell G. The surgical treatment of severe epistaxis in relation to the "ethmoidal" artery. *Br J Surg* 1946;33:387
- ²³ Juselius H. Epistaxis – a clinical study of 1724 patients. *J Laryngol Otol* 1974;88: 317-327
- ²⁴ Walike JW, Chinn J. Evaluation and treatment of acute bleeding from the head and neck. *Otolaryngologic Clinics of North America* 1979;12(2):455- 464
- ²⁵ Walike JW. Anatomy of the nasal cavities. *Otol Clin N Am* 1973;6:609-621
- ²⁶ LaForce RF. Treatment of nasal hemorrhage. *Surg Clin N Am* 1969;49:1305-1310

4.4.2.2 Wrist and digital nerve blockade

1. Indications	189
2. Contraindications	190
3. Step by step procedure	190
4. Materials	194
5. Anatomical pitfalls	195
6. Complications (anatomically relevant)	204
7. References	207

1. Indications

1.1 Wrist block:

- Diffuse lesions that are difficult to anesthetize with local infiltration.
- Deep abrasions with embedded debris, often the result of 'road burn', in order to do a proper debridement.
- Multiple and complex lacerations.
- Skin grafting.
- Incision and drainage of hand infection.
- Reduction of metacarpal fractures, especially 'boxer's fracture'.
- Removal of foreign bodies in the palm of the hand.
- Reconstructive hand surgical procedures like tendon grafts, arthrolysis, arthroplasty and tenolysis²².

1.2 Digital nerve block:

- Repair of finger lacerations. Local infiltration of a finger injury has been shown to be less effective and more painful compared to digital nerve block¹⁸. The reason is the limited amount of anesthetic solution that can be accepted by tense surrounding tissue of the distal part of the finger compared to the loose connective tissue at the base of the finger.
- Finger amputations.
- Reduction of metacarpophalangeal, distal interphalangeal and proximal interphalangeal joint dislocations and fractures.
- Drainage of finger infections (relative contraindication).
- Drainage of felons and paronychia.
- Relief of pain from fractures or burn wounds.
- Particularly useful where it is desirable to retain some motor function during surgery².
- Finger nail removal.
- Intrinsic extensor tenolysis²².
- Release of a trigger finger.

2. Contraindications

2.1 Both wrist and digital nerve block

- Sensitivity to 'caine-type' anesthetic solutions.
- Local sepsis in area where the block needs to be administered.

2.2 Wrist block

- Median nerve – the presence of carpal tunnel syndrome is a contraindication.²

2.3 Digital nerve block

- In the case of extensive injuries to the digits, it is better to choose a more proximal site for the block e.g. a wrist block².
- If more than one digit is involved, due to the risk of ischemia, alternatives such as a wrist block should be considered⁷.
- Patients with peripheral vascular disease.⁷

3. Step by Step procedure

Various techniques are described for both the wrist block and digital nerve block. The step by step procedure that is described here, is the author's preferred procedure. Other alternatives are described in the Anatomical pitfalls section.

- Basic principle: If paresthesias are experienced by the patient, the site of the needle point needs to be changed¹⁹.

3.1 Digital nerve block

- **Step 1.** Determine the extent of possible associated nerve injury by two point discrimination before the block.
- **Step 2.** Prepare the skin of the injection site with alcohol or povidone-iodine.
- **Step 3.** Use sterile gloves
- **Step 4. Site of needle entrance:**
 - The following needle entrance sites can be used:
 - The finger,
 - The web space between the fingers (digital nerve block) and
 - Between the metacarpals in the hand (metacarpal block).

- A dorsal or palmar approach to the nerves can be used. The dorsal approach is less painful due to less pain sensitive skin.
- The preferred site is at the base of the finger in the web space. There is more soft tissue space at this site to accommodate the volume of anesthetic solution. The nerve's location is more consistent here than in the hand. Knoop *et al*¹ showed that this approach requires less time to anesthetise the finger when compared to the metacarpal block.
- Leverage *et al*⁹ describe a method where the needle is directed into the dorsal surface of the web space between two fingers to a depth of 1.5 cm and injecting 2-3 ml of anesthetic solution.
- **Step 5** Start at the dorsal positions where the skin is less pain sensitive. Introduce the needle from the dorsal side at the 2:30 and 10:30 positions (with the mid-dorsal point the 12:00 position). No attempt is made to elicit paresthesia. Inject 0.5 to 1 ml of anesthetic solution. Pass the needle on the lateral side of the proximal phalanx and the extensor expansion toward the palmar surface. The needle is aspirated for checking not to be in a vessel and another 0.5 to 1 ml of anesthetic is deposited. Repeat this procedure for the other side of the finger. The result is a circumferential band of anesthesia around the base of the finger.
- **Step 6.** Massage of the area of injection promotes diffusion of the anesthetic.
- **Step 7.** Palmar and dorsal web space approaches can be used for the middle and index finger, to block the palmar digital nerves. This will provide anesthesia for the whole finger.
- **Step 8.** Thumb – A circumferential block can be performed for the thumb. A band of anesthetic solution is delivered in a subcutaneous fashion over the dorsal and ventral sides of the base of the thumb.

Alternative method: Transthecal digital block technique.

- A single injection is given into the flexor tendon sheath, which produces fast and complete finger anesthesia. Cadaver studies suggest that the local anesthetic diffuses out of the tendon sheath and around the phalanx and all 4 digital nerves are anesthetized⁵.

Technique:

- **Step 1.** The flexor tendon sheath is palpated as it glides over the protuberance of the metacarpal head on the palmar surface.
- **Step 2.** A palmar percutaneous injection of 2 ml of lignocaine is delivered into the potential space of the flexor tendon sheath at the level of the palmar flexion crease (approximately 1 cm proximal to the metacarpophalangeal crease). A small

needle (25-30 ga) must be used to minimize damage to the flexor tendon sheath.

- **Step 3.** Direct the needle at an angle of 45° distally.
- **Step 4.** Resistance to injection suggests that the needle is against the flexor tendon.
- **Step 5.** Carefully withdraw the needle until free flow of the anesthetic solution is obtained. This means the fluid is entering the space between the tendon and the sheath.
- **Step 6.** Apply pressure on the palm of the hand to facilitate diffusion of the solution through the sheath.

Advantage: The advantage of this technique is that a single injection and small volume of anesthetic solution is used. Furthermore the block has a quick onset and there is no risk of mechanical trauma to the neurovascular bundle. However, great care must be taken to adhere to sterile techniques, as contamination of the flexor tendon is disastrous.

3.2 Wrist block

3.2.1 Median nerve^{2, 6,7}

- **Step 1. Position:** Abduct the arm with the elbow extended and the forearm supinated on a rest pad. Place a small towel under the wrist of the hand to dorsiflex the hand.
- **Step 2.** Insert a fine needle between the tendons of palmaris longus and flexor carpi radialis, at the level of the proximal wrist crease of the skin. If the flexor palmaris tendon is absent, the point of insertion is approximately 1 cm medial to the ulnar border of the flexor carpi radialis tendon. Insert the needle at right angle with the long axis of the forearm.
- **Step 3.** Advance slowly until a slight 'pop' is felt. This represents penetration of the flexor retinaculum. At this point, inject 3-5 ml of the anesthetic solution⁹.
- **Step 4.** If paresthesias are felt, withdraw 2-3 mm and inject to avoid intraneural injection. If no paresthesias are elicited, deposit the anesthetic solution in the proximity of the nerve, 1cm deep under the tendon of palmaris longus. The solution is actually injected into the ulnar bursa proximal to the carpal tunnel¹⁶.
- **Step 5.** The superficial palmar branch of the median nerve should also be blocked. This nerve is located directly radial to the palmaris longus tendon in the subcutaneous tissue¹⁹.

3.2.2 Ulnar nerve

Ulnar approach

- **Step 1.** First palpate the ulnar artery, pisiform bone and flexor carpi ulnaris tendon. Palpate the flexor carpi ulnaris tendon. Flex the hand against resistance to facilitate palpation of the tendon just proximal to the pisiform bone, with slight ulnar deviation to relax the tendon of flexor carpi ulnaris¹¹. Find the radial border of the tendon of flexor carpi ulnaris by flexing the wrist with reasonable force and pressing the fingers together⁹. The artery can usually be palpated a few millimetres radial to the tendon, especially if the hand is flexed. The ulnar nerve is just deep and to the ulnar side of the ulnar artery.
- **Step 2. Site of needle insertion.** The site of insertion is on the ulnar aspect of the flexor carpi ulnaris tendon at the proximal wrist crease⁷.
- **Step 3.** Direct the needle horizontally under the flexor carpi ulnaris tendon for a distance of 1-1.5 cm. This will bring the tip close to the ulnar nerve, without the risk of injuring the ulnar artery.
- **Step 4.** Deposit 3 to 5 ml of anesthetic solution.
- **Step 5.** The dorsal cutaneous branch of the ulnar nerve runs around the wrist to supply part of the dorsum of the hand. Block this nerve by depositing 5 to 10 ml subcutaneously from the *same* insertion site to the dorsum of the wrist. The advantage with this approach is that the ulnar artery is less often injured¹⁶ and both the superficial and deep branches as well as the dorsal cutaneous branch of the ulnar nerve can be blocked through the same site of insertion⁷.

Alternative: Volar approach

- **Step 1.** First palpate the ulnar artery, pisiform bone and flexor carpi ulnaris tendon. Palpate the flexor carpi ulnaris tendon. Flex the hand against resistance to facilitate palpation of the tendon just proximal to the pisiform bone, with slight ulnar deviation to relax the tendon of flexor carpi ulnaris¹¹. Find the radial border of the tendon of flexor carpi ulnaris by flexing the wrist with reasonable force and pressing the fingers together⁹. The artery can usually be palpated a few millimetres radial to the tendon, especially if the hand is flexed.
- **Step 2.** Insert the needle at a right angle with the skin on the radial side of the tendon of flexor carpi ulnaris and the ulnar side of the ulnar artery. The ulnar nerve lies between the tendon of the flexor carpi ulnaris and ulnar artery at the proximal palmar crease.
- **Step 3.** Insert the needle vertically to a depth of 1.5 to 2 cm and inject 3 to 5 ml of anesthetic solution. If paresthesias are felt, withdraw 2-3 mm and inject to avoid intraneural injection.
- **Step 4.** The dorsal cutaneous branch of the ulnar nerve can be anesthetized by a subcutaneous injection given just distal to the proximal flexor wrist crease. Start

at the ulnar side of the tendon of flexor carpi ulnaris and advance subcutaneously for 2 to 3 cm around the ulnar side to the dorsum of the wrist⁹. A ring of local anesthesia can also be placed subcutaneously around the ulnar aspect of the wrist, just distal to the ulnar styloid¹².

3.2.3 Radial nerve

- **Step 1.** Palpate the radial artery.
- **Step 2 (first injection).** Block the superficial branch of the radial nerve, by infiltrating superficially under the brachioradialis tendon 6-8 cm proximally to the proximal wrist crease. Use a hypodermic needle and inject 0.5-1 ml of anesthetic solution.
- **Step 3.** Position the forearm in pronation.
- **Step 4.** Identify the anatomical snuffbox and mark the bordering tendons. Identify the extensor pollicis longus and brevis muscles and the abductor pollicis longus muscle, bordering the anatomical snuffbox.
- **Step 5.** Take a point over the tendon of the extensor pollicis longus tendon, opposite the base of the first metacarpal. The nerve is often palpable here¹⁶.
- **Step 6 (second injection).** Direct a 25-ga needle proximally along the tendon as far as the dorsal radial tubercle and inject 2 ml subcutaneously.
- **Step 7.** Withdraw the needle almost to the skin and redirect across and superficially to the anatomical snuffbox, to a point just past the extensor pollicis brevis tendon, and inject a further 1 ml anesthetic solution⁷.

Alternative: ⁷

- Inject 2-5 ml, immediately lateral to the radial artery at the level of the proximal palmar crease. Melone *et al*¹² refers to the radial styloid as a landmark to find the terminal branches of the radial nerve, which can be easily blocked here.
- Another 5 to 10 ml is injected subcutaneously away from the initial point of injection to the dorsal midline. Deposit a superficial ring of solution over the anatomical snuffbox created by the tendons of the abductor pollicis longus and extensor pollicis brevis muscles. Withdraw the needle and reposition in an already anesthetised region to minimize pain.

4. Materials

- Sterile gloves.
- Alcohol and povidone-iodine.
- Lignocaine, bupivacaine or mepivacaine without adrenaline for the digital nerve block. With or without adrenaline can be used for the wrist block⁹.
- 25-30-ga hypodermic needle.
- 10 cc syringe
- 18-ga needle to draw up solution.
- Standard resuscitation equipment.

5. Anatomical pitfalls

5.1 Easy access

- The nerves around the wrist (median, radial and ulnar) as well as the digital nerves in the hand or fingers are superficial and can therefore easily be accessed by percutaneous injection⁹.
- Nerves at the wrist joint can more easily be located compared to the elbow and the axilla.

5.2 Digital nerves

- Each finger has two sets of nerves²: palmar and dorsal digital nerves. They run along the finger for the dorsal pair, at the 2 and 10 o'clock positions and for the palmar pairs, at the 4 and 8 o'clock positions.
- The digital nerve to the radial side of the index finger, is the only common digital nerve supplying only one side of a digit.¹¹
- The digital nerves are volar to the lumbrical tendons in the web space⁹.
- A peripheral nerve consists of a number of fascicles embedded in loose connective tissue (epineurium). This tissue is often sheetlike on the outer border. Each fascicle is surrounded by a perineurium. Inside the perineurium the nerves fibres are packed between thin septae of connective tissue, the endoneurium⁴.
- The thumb can be blocked by performing both a median and radial nerve block at the wrist, or with a circumferential block.

5.2.1 Finger or web space injection

- The finger has tight skin and can allow only a limited volume of anesthetic solution with local infiltration¹⁸. This may increase pressure in the restricted space and impair capillary blood flow. Fibrous septae in the fingertip prevent the anesthetic solution from spreading evenly.
- The level of the fingers should be avoided due to the danger of ischemic changes arising from increased pressure caused by solution in a limited digital space¹. The web space between the fingers is ideal due to increased tissue space and constant

anatomical position of the palmar digital nerves. The digital nerves are surrounded by loose fibrous areolar tissue in the web space. This favours the injection of anesthetic solution and does not cause surrounding tissue pressure and obstruction of venous outflow from the digit⁹. When anesthetic solution is injected into this space, opposing surfaces of the fingers will be blocked¹¹.

5.2.2 Palmar digital nerves

- The principal nerves supplying the finger are the palmar digital nerves, branching from the common digital nerves, just proximal to the metacarpal heads¹.
- The palmar digital nerves follow the artery along the volar lateral aspects of every side of the bone. They supply sensation to the volar skin and interphalangeal joints of all 5 digits.
These nerves also supply the dorsal aspects of the index, middle and half of the ring finger distal to the proximal interphalangeal joint¹.
- **Surface anatomy** – The palmar digital nerves run on the edges of the skin creases made by flexing the DIP, PIP and metacarpophalangeal joints. Therefore, if the needle is inserted at the tip of the skin crease, the nerve will be blocked. The digital nerve on the radial side of the second digit and the ulnar side of the fifth digit, lie directly anterior to the metacarpal heads¹⁰. Blocking these nerves requires injecting the solution into the fatty tissue at the metacarpal heads⁹.
- The palmar digital nerves can be blocked at different levels: within the finger, in the web space between the fingers (site of a digital nerve block) and at the level of the metacarpal bones (metacarpal block).
- The palmar digital nerves are accompanied by digital vessels and run on the ventrolateral aspect of the finger immediately lateral to the flexor tendon sheath⁷.

5.2.3 Dorsal digital nerves

- The dorsal digital nerves originate from the radial and ulnar nerves, which run on the dorsomedial and dorsolateral aspects of the fingers. They supply the nail beds of the thumb and little finger and half of the ring finger as well as the dorsal aspects of the index, middle and half of the ring finger up to the proximal/distal interphalangeal joint. All four digital nerves should therefore be blocked in the thumb, little finger and ring finger, especially to obtain anesthesia of the fingertip and nail bed.
- The dorsal digital nerves lie very close to the bone. Therefore as the bone is touched, the needle should be withdrawn 1-2 mm to inject the solution.

5.2.4 Site of injection for digital nerves

- Digital nerves at the base of the finger
 - This is the preferred site for injection to block the digital nerves. It has a quick onset.
 - Introduce the needle from the dorsal side at the 2:30 and 10:30 positions (with the mid-dorsal point the 12:00 position). Inject here 0.5-1 ml for the dorsal sensory branches. Then push the needle to a point next to the flexor tendon sheath and inject 0.5-1 ml for the palmar digital branches.
 - Knoop¹ showed in a randomised prospective study, that a digital nerve block is more efficient and requires less time for anesthesia when compared to a metacarpal block.
- Digital nerves in the hand (Metacarpal block)
 - The injection is made at the distal palmar crease on the palmar side of the hand. This crease overlies the bifurcation of the common digital nerves, which is found just proximal to the metacarpal heads and deep to the palmar aponeurosis. This is a relatively sensitive area. 3 ml of solution can be injected in the intermetacarpal space¹¹ to block the common digital nerve¹². Because the block is performed proximal to the digital artery collaterals, the risk of vascular compromise is minimized¹. This approach has the drawback of causing significant pain when piercing the palmar skin and palmar aponeurosis.
 - The metacarpal space can also be accessed from the dorsal side¹. Advance the needle 90° to the dorsum of the hand, 1 cm proximal to the metacarpal phalangeal joint, until the resistance of the palmar aponeurosis is felt. Inject 3 ml anesthetic solution and another 1 ml as the needle is withdrawn. The advantage of this approach is that the palmar skin need not be pierced and the dorsal sensory branches can be blocked via the same injection site.

5.2.5 Alternative techniques to block the digital nerves. (See preferred technique in Section 3)

- **Bradfield's method⁸:**
 - Inject into the side of the base of the finger (the side is less sensitive than the dorsum)
 - Fill the pulp of the finger with anesthetic solution by passing the point of the needle to the other side superficial to the flexor tendons.
 - It is not necessary to aim for the digital nerves
 - Apply the tourniquet (fine rubber tube) at the base of the finger just

proximal to the injection site.

- Secure the tourniquet with a pair of artery forceps.
- Scrub up for the procedure. This time will allow the finger to be fully anesthetized.

- **Mauldin's method¹⁶**

- Insert a 25-ga needle at a point on the dorsomedial and dorsolateral aspect of the base of the finger.
- Direct the needle anteriorly and slide past the base of the phalanx
- Advance the needle until resistance of the palmar dermis is felt.
- Inject 1ml while withdrawing the needle slightly for the palmar digital nerve
- Inject 0.5-1 ml just under the point of entry for the dorsal digital nerve.
- The palmar digital nerves of the second and fifth digits, may be easier to reach from the sides

- **Ramamurthy's method²³:**

- Insert the needle from the dorsal aspect at the proximal end of the finger to the side of the extensor expansion.
- Inject 1 ml of anesthetic solution into the region of the dorsal digital nerve.
- Advance the needle to the volar aspect of the digit to inject another 1 ml.
- Repeat the procedure on the other side.
- Do not exceed 5 ml solution to each digit.

- **Transthecal(synovial) digital nerve block**

- Hill *et al*¹⁷ showed in a prospective randomised controlled study that transthecal digital nerve blocks are clinically equal to the traditional digital nerve block regarding length of time to achieve anesthesia and pain associated with the procedure.
- The following are advantages of the block¹⁷, although the complications of the traditional method of digital nerve blockade are very low:
 - A single injection is used
 - A smaller amount of anesthetic solution is used
 - The risk of injuring the neurovascular bundle is avoided, reducing direct injury or spasm
- Disadvantages of the block are the following¹⁷:
 - The barrier of the flexor synovial sheath is crossed
 - Tendon trauma and infection is a risk, although minimal with a small needle (25-ga or higher) and sterile technique.

5.3 Median nerve^{2,7}

- **Sensory innervation:** The median nerve supplies the radial aspect of the palm of the hand and the palmar surface of the first (thumb), second and third digits and the radial side of the fourth digit. It also supplies the dorsal surface of the distal

two phalanges of the second and third digits and the radial aspect of the distal two phalanges of the fourth digit⁹.

- **Motor innervation:** The median nerve supplies the two lateral lumbrical muscles in the hand as well as the thenar group of muscles.
- The median nerve is the most superficial structure beneath the flexor retinaculum in the carpal tunnel¹⁶.
- The median nerve lies in the midline and deep to the fascia, invested by the ulnar bursa and accompanied by tendons of flexor pollicis longus, flexor digitorum profundus and superficialis which lie deep to it.
- The median nerve lies just deep to the palmaris longus tendon, or slightly radial to it between palmaris longus and flexor carpi radialis⁹. These tendons can be easily palpated. The palmaris longus tendon is the most superficial tendon and can be easily identified by forced flexion of the wrist while opposing the thumb and the fifth digit. The relation of the nerve to the tendons along the radial part of the wrist is remarkably constant²⁵.
- Palmaris longus is absent in 5 to 10% of people¹⁰. If this is the case the median nerve is more or less 1 cm to the ulnar side of the flexor carpi radialis muscle. The midpoint between the ulnar and radial styloid processes can also be used as a reference point¹⁶.
- The median nerve gives off a palmar branch before entering the carpal tunnel. This branch is located subcutaneously and radial to the palmaris longus tendon¹⁹. This branch should also be blocked by injecting a small amount of anesthetic solution subcutaneously just radial to the palmaris longus tendon.
- **Site of nerve block** - on the radial side of palmaris longus, just proximal to the proximal wrist crease. Insert a 25-ga needle perpendicularly and advance slowly until a slight 'pop' is felt (penetration of the flexor retinaculum) and a paresthesia is produced. If no paresthesia is elicited, deposit 3-5 ml of the anesthetic solution in the proximity of the nerve, 1cm deep under the tendon of palmaris longus. The solution is actually injected into the ulnar bursa proximal to the carpal tunnel¹⁶.
- If only the median nerve is blocked at the wrist level, the extrinsic flexor and extensor function of the hand as well as the intrinsic muscles of the hand supplied by the ulnar nerve, stay intact. This may be valuable in assessing function perioperatively during hand surgery²².

5.4 Ulnar nerve^{2,7}

- There are fewer risks and complications when blocking the ulnar nerve at the

wrist compared to blocking the nerve at the elbow¹⁶. The ulnar nerve may also be locally anesthetized at the elbow joint, where the nerve lies 0.5 cm below the skin but blocking of the nerve at that level is associated with a significant incidence of residual ulnar neuritis⁷.

- **Sensory innervation:** The ulnar nerve supplies the ulnar aspect of the hand on both the dorsal and palmar surface. It supplies the ulnar aspect of the fourth digit and the whole fifth digit. It may also supply parts of the dorsal surface of the proximal third and fourth digits⁹.
- **Motor innervation:** The ulnar nerve supplies all of the intrinsic muscles of the hand, except the thenar muscles and lateral two lumbrical muscles, which are innervated by the median nerve. In the forearm it supplies flexor carpi ulnaris and the ulnar part of flexor digitorum profundus.
- The ulnar nerve follows the ulnar artery to the wrist joint.
- The ulnar artery lies radially and superficial to the ulnar nerve¹⁶. The ulnar nerve lies between the tendon of flexor carpi ulnaris and the artery and *deep* to the artery, making a volar approach to the nerve difficult without injuring the artery. The artery is therefore at risk when using a volar approach to the ulnar nerve.
- Both the ulnar artery and nerve lie covered by the flexor carpi ulnaris muscle, and lie directly beneath the flexor carpi ulnaris tendon at its insertion to the pisiform bone¹¹.
- The artery and nerve lie at the level of the proximal wrist crease just next to the radial border of flexor carpi ulnaris.
- **Branches of the ulnar nerve at the wrist:** In the distal third of the forearm, approximately 5 cm proximal to the wrist, the ulnar nerve gives off the dorsal cutaneous branch of the ulnar nerve⁹. The dorsal cutaneous branch of the ulnar nerve is entirely sensory and proceeds beneath the tendon of flexor carpi ulnaris and reaches the dorsal aspect of the wrist and hand. The ulnar nerve, a mixed nerve, runs along the tendon of flexor carpi ulnaris to divide at the pisiform bone in Guyon's canal into a superficial palmar cutaneous branch and deep motor branch. The superficial palmar cutaneous branch of the ulnar nerve is entirely sensory supplying the ulnar aspect of the palm of the hand and the palmar surfaces of the little finger and ulnar side of the ring finger. The deep motor branch continues through Guyon's canal and supplies the hypothenar muscles, interosseous muscles, the medial two lumbrical muscles and the adductor pollicis muscle.
- During an ulnar nerve block at the wrist, the nerve is blocked before it bifurcates into the deep motor branch and superficial palmar cutaneous branch⁷.

- **Site of needle insertion:**

- **Ulnar approach:** The site of insertion is on the ulnar aspect of the flexor carpi ulnaris tendon at the proximal wrist crease. Direct the needle horizontally under the flexor carpi ulnaris tendon for a distance of 1-1.5 cm. Deposit 3 to 5 ml of anesthetic solution after finding paresthesia. The dorsal cutaneous branch of the ulnar nerve runs around the wrist to supply part of the dorsum of the hand. Block this by depositing 5 to 10 ml subcutaneously from the *same* insertion site to the dorsum of the wrist. The advantage with this approach is that the ulnar artery is less often injured¹⁶ and both the superficial and deep branches of the ulnar nerve as well as the dorsal cutaneous branch can be blocked through the same site of insertion⁷.
- **Alternative: Volar approach:** Insert needle at a right angle with the skin on the radial side of the tendon of flexor carpi ulnaris and the ulnar side of the ulnar artery, about 1 cm proximal to the pisiform bone at the level of the proximal wrist crease¹⁶. The superficial palmar cutaneous branch of the ulnar nerve lies between the tendon of the flexor carpi ulnaris and ulnar artery at the proximal wrist crease. Find the radial border of the tendon of flexor carpi ulnaris by flexing the wrist with reasonable force and pressing the fingers together⁹.

- **Variation of the ulnar nerve**

- Kaplan²⁷ describes an anomalous branch emerging from the dorsal cutaneous branch of the ulnar nerve, 2 cm proximal to the ulnar styloid process. It then coursed on the ulnar side of the pisiform bone to join the superficial palmar cutaneous branch of the ulnar nerve distal to the pisiform bone.
- König *et al*²⁸ reports a case where the ulnar nerve divided into three branches just before entering Guyon's canal.
- Olave *et al*²⁹ reports an ulnar nerve dividing into two branches approximately 6 cm proximal to the distal wrist crease, with the artery between the two branches. The medial branch was prominent and gave off the deep motor branch of the ulnar nerve 6 mm distal to the distal wrist crease. The lateral and medial branches joined again 35 mm distal to the distal wrist crease forming the common palmar digital nerve of the 4th interosseous space.

- **Guyon's canal**

- This fibroosseous tunnel extends for about 4 mm from the palmar carpal ligament at the proximal edge of the pisiform bone to the origin of the

hypothenar muscles at the level of the hamulus²⁰.

- The ulnar nerve bifurcates into the superficial palmar cutaneous branch and the deep motor branch, at a mean distance of 12 mm from the proximal border of the pisiform bone in the middle part of the tunnel²¹. This is a confirmation of an earlier cadaver based study done by Gross *et al*²⁰, where an average distance of 11 mm was found.
- The diameter of the ulnar nerve at the level of the pisiform bone is approximately 3 mm²¹.
- The ulnar artery divides into two branches, 3-7 mm beyond the bifurcation of the ulnar nerve.
- Gross *et al*²⁰ divides the tunnel into three zones. Zone 1 is the part proximal to the bifurcation of the ulnar nerve. Zone 2 represents the deep motor branch of the nerve and zone 3 surrounds the superficial palmar cutaneous branch of the ulnar nerve. Ulnar nerve compression syndromes can occur in any zone with subsequent motor (deep branch) and or sensory (superficial branch) loss.
- Cobb²⁶ proposed that from an anatomical point of view, Guyon's canal should be referred to as the carpal ulnar neurovascular space. The roof is formed by the antebrachial fascia's extension and the palmaris brevis muscle. The floor is formed by the muscles of the hypothenar eminence. The radial border is formed by the junction of the roof and the flexor retinaculum. The ulnar border is formed by the pisiform bone proximally and the fusion of the roof and the hypothenar eminence.

5.5 Radial nerve²

- The radial nerve is entirely superficial to the fascia as seen on a cross section of the wrist, just proximal to the styloid process of the radius¹⁹.
- **Sensory innervation:** The radial nerve supplies the radial aspects of the dorsum of the hand and portions of the dorsal aspects of the first digit. It also supplies portions of the second, third and radial dorsal aspect of the fourth digits. It supplies the dorsal surface up to the proximal or distal interphalangeal joint. It supplies part of the palmar aspect of the first digit as well⁹ and the lateral aspect of the thenar eminence¹⁶.
- **Motor innervation:** The radial nerve has no motor innervation in the hand.
- The superficial branch of the radial nerve follows the radial artery along the

medial side of the brachioradialis muscle. About 6-8 cm proximal to the wrist the nerve passes underneath the tendon of brachioradialis and lies subcutaneously on the extensor surface of the distal forearm⁹. It gives off branches before crossing the wrist. These branches supply the dorsolateral aspect of the hand.

- The superficial radial nerve runs subcutaneously on the roof of the anatomical snuffbox
- The superficial radial nerve can be palpated over the lateral border of the radius, just dorsal to the radial styloid process and proximal to the deepest palpable portion of the anatomical snuffbox¹¹.
- **Site of needle insertion**
 - Block the superficial branch of the radial nerve, by infiltrating under the brachioradialis tendon 6-8 cm proximally from the wrist.
 - Position the forearm in pronation. Identify the anatomical snuffbox and mark the bordering tendons. Identify the extensor pollicis longus and brevis muscles and the abductor pollicis longus muscle, bordering the anatomical snuffbox. Take a point over the tendon of the extensor pollicis longus tendon, opposite the base of the first metacarpal. The nerve is often palpable here¹⁶.
Direct a 25-ga needle proximally along the tendon as far as the dorsal radial tubercle and inject 2 ml subcutaneously. Withdraw the needle almost to the skin and redirect across and superficially to the anatomical snuffbox, to a point just past the extensor pollicis brevis tendon, and inject a further 1 ml anesthetic solution⁷.

5.6 Variation of the nerve supply of the hand

5.6.1 Sensory

- There is occasional crossover of sensory supply to the hand and fingers¹⁹. Exceptions are the distal portion of the second digit, which is as a rule supplied by the median nerve, and the fifth digit, which is as a rule supplied by the ulnar nerve⁹.
- Anatomic variation of the sensory nerve supply to the hand is often the reason for apparent failure of a regional block^{11,16}.
- The radial and ulnar supply to the dorsum of the hand, may enlarge and therefore reduce the area of supply of the other nerve. The ulnar nerve may even be absent in supplying the dorsum of the hand¹⁵.
- On the palmar side, the ulnar nerve may supply the whole of the fourth digit, reaching to the ulnar side of the third digit. It may also be demarcated to the fifth digit only¹⁵.

5.6.2 Motor supply

- The radial nerve never supplies any intrinsic muscles of the hand¹⁵.
- The ulnar nerve may supply part of or even all of the thenar muscles¹⁵.
- The median nerve may supply adductor pollicis and the 1st dorsal interosseous muscle¹⁵.

5.7 Facial compartments of the forearm at the wrist joint

- Both the median and ulnar nerves give off subcutaneous branches before they cross the wrist joint. The radial nerve however is entirely subcutaneous. The median and ulnar nerves are therefore deep to the volar fascia in a relatively large enclosed facial compartment. This makes it possible to inject a small amount of anesthetic solution without the need to elicit paresthesia¹⁹.
- Too large amounts of anesthetic solution injected in these confined facial compartments may lead to compression of vascular and lymphatic structures¹⁹.

5.8 Long flexor and extensor tendons

- An additional advantage of the wrist and digital nerve block is the fact that the long flexor and extensor tendons of the hand are not affected. This enables the patient to move his or her fingers and makes it possible to test for muscle-tendon integrity during the procedure and for example to test for the adequacy of a trigger-finger release¹². Also the patient can appreciate the extent of movement postoperatively and help the surgeon determine the extent of reconstructive surgical hand procedures²².

6. Complications (anatomically relevant)

6.1 Nerve damage

- There were many advocates for the need to elicit paresthesia during regional nerve blocks. This view has changed with studies of Selander *et al*⁴ showing nerve damage due to needle injury. Nerve stimulators have made the need to elicit paresthesia unnecessary. The need for a thorough knowledge of the anatomy, however, has not changed. The insertion site of the needle is still based on sound anatomical knowledge. The relations of the specific nerve are therefore very important.
- Smaller nerves lying over bone and in restricted fascial compartments are more vulnerable to ischemia or traumatic injury¹³. They do not slide away from the advancing needle and are more vulnerable to intraneural injection.
- For all nerve blocks it is best not to directly inject into the nerve, but around it.

- Selander *et al*⁴ showed that the damage caused by a needle depositing the local anesthetic solution may be significant. Neurological sequelae like sensory disturbances such as paresthesia, hyperesthesia, dysesthesia and pain as well as muscular paralysis can occur. Nerve impairment may be due to direct injury to the nerve, intraneural micro vascular injury as well as the toxic effects of the injected agent.
- In a subsequent study, Selander *et al*¹⁴ showed that intraneural injections should be avoided and solutions with epinephrine should also be avoided. It also seems that the sharp pointed needle (14° bevel) causes more axonal damage than a blunt tipped needle (45° bevel)⁴.
- Earle *et al*¹¹ confirms that intraneural injection should be avoided. This is suggested when intense paresthesia is felt on small volume injection⁷. Frederick *et al*²⁴ reports on the nerve damage of both median and ulnar nerves due to intraneural injection during carpal tunnel syndrome treatment.
- When searching for paresthesia, a nerve trunk may be injured, even though nerve fascicles have a tendency to slide and roll away from the advancing needle point.
- Possible pre-existing nerve injuries should be determined by two-point discrimination before the block is performed and should be documented properly. Advise the patient before the block.
- Except for anesthetic causes, wrong positioning of the patient, tight casts and dressings, tourniquet use and surgical trauma may also result in injury to peripheral nerves.

6.2 Vascular insufficiency

- **Vascular insufficiency** may result after digital nerve block as a result of digital arterial occlusion. This may be due to:
 - Epinephrine containing solutions⁷.
 - Excessive amount of local anesthesia injected². The mechanical pressure caused by the volume of anesthetic solution may obstruct the blood supply to the digit and cause ischemia. It may even result in gangrene of the finger⁶. Maximum volumes of 2 ml on each side should not be exceeded⁷.
 - Tourniquets, which are used to create a bloodless field⁷. The tourniquet should not be used for more than 15 minutes⁸.
 - Direct vascular injury, caused by the needle.
 - Inadvertent intravascular injection causing digit ischemia. Blanching of the

finger while injecting the anesthetic solution suggests intravascular injection, after which injection should be discontinued. The ischemia is usually transient. This may be different in patients with underlying vascular disease.

- Peripheral vascular disease. This technique should be avoided in patients with small vessel disease.

- **Gangrene of the finger**
 - Bradfield⁸ analysed the reported cases of gangrene of the finger following a digital nerve block. The following factors are mentioned: whether adrenaline was used, whether a finger tourniquet was used and the time of application, the volume of anesthetic solution injected and the presence of peripheral vascular disease. It seems that a combination of these factors increase the risk of finger gangrene developing. In a series of 267 patients, Bradfield⁸ showed that a finger tourniquet should not be applied for more than 15 minutes.

 - The following precautions should be taken:
 1. Never use adrenaline in the anesthetic solution
 2. Never use a tourniquet when there is a history of Raynaud's phenomenon.
 3. Should a tourniquet be used, do not use more than 2 ml of anesthetic solution on each side⁷.
 4. Do not apply the tourniquet for more than 15 minutes⁸
 5. Do not inject into an infected area.

6.3 Ineffective median nerve block

- This may be the case if the anesthetic solution is injected too superficially. The flexor retinaculum should be penetrated with the needle, because it forms a barrier between the nerve and the superficial tissue. A subcutaneous wheal after injection reveals inadequate depth of the needle¹².

6.4 Ineffective blocking of the palmar digital nerves

- These nerves are more palmar than often appreciated, and are almost adjacent to the flexor tendon. Injecting from the lateral side of the finger may miss the nerve. The palmar digital nerves are found on the edges of the skin creases made by flexing the DIP and PIP joints.

6.5 Ulnar artery injury

- When using a volar approach for blocking the ulnar nerve at the wrist, the artery may be injured due to its position superficial and medial to the ulnar nerve at this point. It is therefore recommended to use the ulnar approach to the nerve.

6.6 Block failure

- This may be due to variational anatomy of the sensory nerve supply to the hand.
- Certain areas of the hand need combined blocks at the wrist. The thumb for instance is innervated by both radial and median nerves and the ring finger by both median, radial and ulnar nerves. For effective anesthesia over the dorsum of the hand, both the superficial radial nerve and dorsal cutaneous branch of the ulnar nerve need to be blocked¹².

6.7 Reactions to the anesthetic solution^{8, 13}

- The dose used in digital nerve blocks is so small, that toxic reactions are very rare. Lignocaine is safe and should be regarded as the anesthetic solution of choice. Toxic signs should however always be kept in mind. These may be sensory disturbances peri-orally, visual disturbances, skin rash or anaphylactic reaction.

7. References

¹ Knoop K, Trott A, Syverud S. Comparison of digital versus metacarpal blocks for repair of finger injuries. *Ann Emerg Med* 1994;23:1296-1300

² Eriksson E. *Illustrated handbook in local anaesthesia*. 2nd ed. London: Lloyd-Luke(Medical Books), 1979: 50

³ Moberg E, Rathke FW. *Dringliche Handchirurgie*. Stuttgart: Georg Thieme Verlag, 1964

⁴ Selander D, Dhuner KG, Lundborg G. Peripheral nerve injury due to injection needles used for regional anesthesia. An experimental study of the acute effects of needle point trauma. *Acta Anaesthesiol Scand* 1977;21:182-188.

⁵ Chiu DTW. Transthecal digital block: Flexor tendon sheath used for anesthetic infusion. *J Hand Surg* 1990;15A:471

⁶ Abadir A. Anesthesia for hand surgery. *Orthop Clin North Am* 1970;1:205

⁷ Brown DL, Bridenbaugh LD. In the upper extremity, somatic block. In: Cousins M, Bridenbaugh PO (eds): *Neural blockade in clinical anesthesia and management of pain*. 2nd ed. Philadelphia: JB Lippincott, 1988: 364-70

⁸ Bradfield WJD Digital block anaesthesia and its complications. *Br J Surg* 1962;50:495-498

⁹ Lerversee JH, Bergman JJ. Wrist and digital nerve blocks. *Journal of Family Practice* 1981;13(3):415-421

¹⁰ Grant JC, Basmajian JV. *Grant's Method of Anatomy*, ed 7. Baltimore: Williams & Wilkins, 1965

¹¹ Earle AC, Blanchard JM. Regional anesthesia in the upper extremity. *Clinics in Plastic Surgery* 1985;12(1):97-114

¹² Melone CP, Isani A. Anesthesia of hand injuries. *Emerg Med Clinics of North Am*. 1985;3(2):235-243

¹³ Swerdlow M. Complications of local anesthetic neural blockade. In: Cousins M,

- Bridenbaugh PO (eds): Neural blockade in clinical anesthesia and management of pain. 2nd ed. Philadelphia: JB Lippincott, 1988: 655-661
- ¹⁴ Selander D, Brattsand R, Lundborg G et al. Local anesthetics: Importance of mode of application, concentration, and adrenaline for the appearance of nerve lesions. *Acta Anaesthesiol Scand* 1979;23:127
- ¹⁵ Ellis H, Feldman S. *Anatomy for anaesthetists*, 7th Ed., Oxford: Blackwell Science, 1997: 188-189
- ¹⁶ Mauldin CC, Brooks DW. Arm, Forearm, and Hand Blocks. In: *Pain Procedures in Clinical Practice*. TA Lennard, 2nd ed Philadelphia: Hanley & Belfus, 2000: 96-107
- ¹⁷ Hill RG, Patterson JW, Parker JC, Bauer J, Wright E, Heller MB. Comparison of transthecal digital block and traditional digital block for anesthesia of the finger. *Ann Emerg Med* 1995;25(5):604-607
- ¹⁸ Robson AK, Bloom PA Suturing of digital lacerations: Digital block or local infiltration? *Ann R Coll Surg Engl* 1990;72:360-361
- ¹⁹ Burnham PJ. Regional block at the wrist of the great nerves of the hand. *JAMA* 1958;167:847
- ²⁰ Gross MS, Gelberman RH. The anatomy of the distal ulnar tunnel. *Clinical Orthopaedics and Related Research* 1985;196:238-247
- ²¹ Zeiss J, Jakab E, Khimji T, Imbriglia J. The ulnar tunnel at the wrist (Guyon's canal): normal MR anatomy and variants. *American Journal of Roentgenology* 1992;158:1081-1085
- ²² Conolly WB, Berry FR. The place of peripheral nerve blocks in reconstructive hand surgery. *Hand* 1977;9:157-160
- ²³ Ramamurthy S. Anesthesia, in Green DP (ed): *Operative Hand Surgery*, 3rd Ed. London and Edinburgh: Churchill Livingstone, 1991: 47-48
- ²⁴ Frederick HA, Carter PR, Littler JW. Injection injuries to the median and the ulnar nerves at the wrist. *J Hand Surg* 1992;17A:645-647
- ²⁵ Robbins H. Anatomical study of the median nerve in the carpal tunnel and etiologies of the carpal tunnel syndrome. *J Bone Joint Surg* 1963;45A:953-66
- ²⁶ Cobb T, Carmichael S, Cooney W. Guyon's canal revisited: an anatomic study of the carpal tunnel neurovascular space. *Journal of Hand Surgery* 1996;21A:861-869
- ²⁷ Kaplan E. Variation of the ulnar nerve at the wrist. *Bulletin of the Hospital of Joint Diseases* 1963;24:85-88
- ²⁸ König P, Hage J, Bloem J, Prosé L Variations of the ulnar nerve and ulnar artery in Guyon's canal: a cadaveric study. *Journal of Hand Surgery* 1994;19A:617-622
- ²⁹ Olave E, Del Sol M, Gabrielli C, Prates JC, Rodrigues CF. The ulnar tunnel: a rare disposition of its contents. *Journal of Anatomy* 1997;191: 615-616

4.4.2.3 Rectal examination, proctoscopy and sigmoidoscopy

1. Indications	209
2. Contraindications	210
3. Step by step procedure	210
4. Materials	216
5. Anatomical pitfalls	216
6. Complications (anatomically relevant)	230
7. References	234

1. Indications

- The following are indications for digital rectal examination. Those that also apply for proctoscopy and/or sigmoidoscopy are marked P (Proctoscopy: Visualization of the anal canal and distal part of the rectum) and S (Sigmoidoscopy: Visualization of the anal canal, rectum and distal part of the sigmoid colon.)
- Anal foreign bodies. (P,S)
- Anal tears and fissures. (P)
- Hemorrhoids. (P,S)
- Bright red blood per rectum. (P,S)
- Recent change in stool character, from diarrhea to constipation. (P,S)
- Pain on defecation. (P)
- Anal pruritis, warts and fistulae. (P)
- Fecal impaction. (P)
- Proctitis/ colitis. (P)
- Rectal prolapse.
- Rectal polyps. (P,S)
- Diarrhea in the elderly. (S,P)
- Backache. (P,S)
- Urinary symptoms – prostatism. Digital prostatic evaluation.

- Anemia. (P,S)
- Chronic inflammatory bowel disease. (P,S)
- Assessing fecal incontinence²¹ – external sphincter dysfunction due to e.g. a spinal cord injury.
- Internal sphincter dysfunction – Autonomic sphincter dysfunction, diabetes mellitus, central nervous system lesions.
- Assessing patients with abdominal symptoms. (S,P)
- Anorectal trauma. (S,P)
- Assessing the presence of fecal matter, its color, amount and consistency. (P)
- To trigger defecation in patients with obstructive constipation.
- Follow-up of patients after radical prostatectomy, combined with PSA screening.
- Abdominal pain in children especially in the presence of constipation, gastroenteritis, appendicitis, abdominal adhesions and abdominal pain of unclear origin¹³.
- Appendicitis – Good technique is necessary, to distinguish anal discomfort from the effect of pressure on the pelvic peritoneum.
- Removal of a foreign body in the rectum. (P,S)

2. Contraindications

- Imperforate anus
- Anal stenosis
- Precautions:
 - Active inflammation of the bowel.
 - Recent radiotherapy in the pelvic region.
 - Rectal surgery.
 - Patients with a history of abuse.
 - Spinal patients with known autonomic dysreflexia.

3. Step by step procedure

- Explain the procedure fully and reassure the patient that the procedure is not unduly painful although inconvenient. It may stimulate a desire to evacuate. Ng¹² did a survey amongst 103 patients who were rectally examined and found that patients

would like to be informed about the procedure. Informed verbal consent should be sufficient. The examiner should ideally be accompanied by a chaperone.

- Check if all the equipment is ready as well as an assistant.
- Appropriate analgesia and sedation is important.
Topical lidocaine jelly can be applied 5-10 minutes prior to the examination.
- **Position:**
 - The patient should be positioned in the lateral decubitus position or the knee-chest position. In the lateral decubitus position the knees and hips are flexed with the knees drawn to the chest and the patient's buttocks placed just over the edge of the bed. The patient's head and shoulders should remain in the center of the table. The back should be kept relatively straight with a pillow under the head.
This position directs the axis of the anal canal and rectum directly toward the examiner.
 - The knee-chest position is difficult in patients who are in severe pain and elderly and sick patients.
- Wash hands and put on gloves.

Digital rectal examination

Step 1. Inspection

- Look for signs of perianal inflammation, which may suggest pruritis or a dermatological condition.
- Gently evert the buttocks to visualize the presence of any anterior and posterior fissures.
- Be diligent especially if there is a sentinel tag in either the posterior midline or anterior midline.
- Anal skin tags, perianal abscesses, pilonidal sinuses, warts, fissures, fistulas, prolapsed rectal mucosa and external thrombosed hemorrhoids can be visible at this stage. Bulging or redness may result from a perianal or ischioanal fossa abscess.
- A bluish discoloration of the perianal region is typical of Crohn's disease⁸.
- Perianal pain is suggestive of a possible perianal abscess, fissure or thrombosed external hemorrhoids.
- Internal and external hemorrhoids are classically located in the right anterior (11 o'clock), right posterior (7 o'clock) and left lateral (3 o'clock) quadrants.

Step 2. Palpation

- Perform the rectal examination with a well lubricated finger, initially pressing with the finger against the anal verge at the 6 o'clock position.
- Ask the patient to strain before digital rectal examination, to evaluate the amount of perineal descent or tissue prolapse¹¹. This may reveal bleeding from internal hemorrhoids
- Sweep the finger over the smooth rectal mucosa in search of any abnormality lying in the bowel lumen, the bowel wall or outside the rectum. The transverse rectal folds (Houston's valves) of the ampulla can also be palpated⁹.
- Determine the presence of fecal impaction, fecal load, prostate size, bleeding, a mass, a foreign body, localized pain or pathology and the axis of the anal canal.
- Internal hemorrhoids and the pectinate line are not palpable. A large hypertrophic anal papilla may be palpable at the level of the pectinate line.
- Digital anal examination in the presence of an anal fissure can be very painful. The finger should be well lubricated and the patient asked to strain down¹.
- The left hand can be used simultaneously to palpate the abdomen. Masses and other possible pathology may now come into reach of the examining finger in the rectum.
- Explore the posterior and posterolateral walls of the rectum with the palmar surface of the finger. This can be done by sitting in a half-crouched position and pronating the wrist. The anterior surface of the rectal mucosa should also be palpated. Normal rectal mucosa is smooth and mobile.
- Male
 - Anterior: palpate the bulb of the penis and the spongy urethra, prostate and seminal vesicles.
 - Normal prostate:
 - A normal prostate gland is smooth on palpation. The palpation of two lateral lobes separated by a median sulcus is indicative of hypertrophy of the prostate gland²⁶. Bowel mucosa should move freely between the examiner's finger and the prostate.
 - A normal prostate is 3.5cm from side to side and protrudes 1cm into the rectum⁸. It has a smooth and rubbery consistency, with a shallow groove separating the left and right lobes.
 - Patients may experience an urge to urinate on palpation. The prostate gland is usually not tender.
 - Size, consistency, nodularity and tenderness are evaluated during

palpation.

- Abnormal prostate
 - Benign prostatic hypertrophy- smooth, rubbery and symmetrical enlargement of the prostate. The median sulcus can become indistinct and bulge more than 1 cm into the rectal lumen.
 - Cancerous prostate – assymetrical, stony hard consistency and discrete nodules may be palpable. The median sulcus is obliterated.
 - Tenderness of the prostate may reflect acute prostatitis, a prostatic abscess or inflammation of the seminal vesicles.
- Female
 - Posterior vaginal wall
 - Cervix,
 - Fundus of a retroverted uterus,
 - The ovaries can occasionally be palpated if situated in the recto-uterine pouch.
 - Tenderness in the right or left iliac fossa with salpingitis and ectopic pregnancy.
- Both sexes
 - Ischioanal fossa and ischial spines laterally.
 - Masses in the iliac fossa (best palpated with bimanual palpation).
 - Tenderness in the right iliac fossa with appendicitis.
 - Posterior – sacrum and the coccyx.
- Assess sphincter tone. For that, the finger is flexed slightly posterior and the patient asked to squeeze down as if to stop a bowel movement. The tightening of the external anal sphincter may be felt at the base of the examining finger.
An easy test to evaluate a possible major incontinence problem: give a 100 ml water enema in the office and observe how long the patient can retain it. If the patient is still continent after 5 minutes, a major incontinence problem is unlikely²¹.

Step 3. Examination of a specimen

- Examine the stool on the glove after the examination. Stools may be blood stained or pale or there may be pus or melenā stool representing gastrointestinal bleeding. Protozoal infection may be diagnosed, which can cause rectal bleeding.
- A prostatic smear can be done for microscopy and culture, by massaging the prostate gland to squeeze prostatic fluid to the urethral meatus.

Children

- Rectal examination should be considered a specialist examination in children to be performed in certain limited situations¹⁴.
- Dickson *et al*¹⁵ classifies the discomfort experienced by children during rectal examination as severe (major crying or screaming) or mild (minor crying or facial grimacing).
- The information obtained often has limited usefulness and a rational decision should be made on when it is indicated¹⁴. Dickson *et al*¹⁵ reports that in only two patients of 103 patients, rectal examination altered management.
- Information obtained from a rectal examination in children can often be obtained from modern imaging techniques like ultrasonography.
- Indications for rectal examination in children are: acute abdomen, trauma, gastrointestinal bleeding, abnormal neurology (e.g. spinal lesions) and congenital anomalies¹⁴.
- Advanced Pediatric Life Support (APLS) recommends a rectal examination should be carried out only when the result will alter management¹⁶.

Proctoscopy

Step 1. Insert the well-lubricated proctoscope with the obturator in place by gently advancing the scope. The scope should initially be directed anteriorly in the direction of the umbilicus and after reaching the rectum in a posterior direction. Once the anal sphincters at the anal orifice are passed, the proctoscope usually passes easily through the recto-anal area.

Keep the thumb on the obturator, for if it slides backwards, reinserting it may pinch the mucosa causing pain. Reinsert the obturator only if the whole proctoscope is removed.

Step 2. Guide the instrument through the anal sphincters to the upper anal canal. Once through the anal sphincters, tilt the tip of the proctoscope posteriorly to avoid pressure on the prostate gland. At this point the instrument can be advanced further.

Step 3. Once inserted, remove the obturator, visualize the anal canal and gradually remove the proctoscope while inspecting the walls of the anal canal. Internal hemorrhoids may be seen prolapsing into the lumen of the instrument.

Step 4. Take a swab if there is any discharge.

Step 5. The proctoscope can be rotated to visualize the whole anal wall.

Look for:

- Internal and external hemorrhoids.
- Anal fistulae.
- Tumors.
- Blood, pus.
- Ulceration and mucosal irregularities.
- Parasites.

Step 6. At the last stage of withdrawal, the reflex spasm of the anal sphincters cause the proctoscope to exit quickly.

Sigmoidoscopy

Step 1. Positioning the patient:

Placing a sandbag under the patient's left hip makes it easier to negotiate the bends in the rectosigmoid region. The patient's buttocks should be positioned close to the edge of the examination couch⁴¹.

Step 2. A digital rectal examination should be done first²⁸.

Step 3. Rigid sigmoidoscopy should be performed under general anesthesia.

Step 4. After passing the anal sphincter, remove the obturator and connect the light source.

Step 5. Direct the sigmoidoscope in the direction of the umbilicus.

Step 6. Advance the scope only when the lumen is visible, and do not use any force.

Step 7. Avoid stool or clear the stool with cotton wool pledgets held in a long biopsy forceps.

Step 8. Having entered the rectum, swing the viewing end of the sigmoidoscope anteriorly to facilitate for the sacral concavity of the rectum and advance into the rectum under direct vision. This is necessary due to the angle of the distal rectum as it joins the anal canal.

Step 9. Some side-to-side movement may be necessary to bypass the rectal inflexions or valves of Houston²².

Step 10. Keep going in this direction for about 15 cm until the recto-sigmoid junction is reached. Here the sigmoid colon bends forward and to the left.

- Step 11.** Therefore the viewing end of the scope should be swung posteriorly and superiorly to the patient's right hip. Advance the scope gently for it can easily perforate the bowel at this point.
- Step 12.** The distal part of the sigmoid colon can now be viewed to the full length of the sigmoidoscope (25-30 cm).
- Step 13.** Having reached the limit of the examination, note the color of the stool. Blood suggests bleeding proximal to this point.
- Step 14.** Withdraw the instrument carefully and look for evidence of mucosal abnormalities, polyps, carcinoma, ulceration, bleeding, exudates, fissures etc.
- Step 15.** Note the location of the lesions: distance from the anus and position on circumference of the sigmoid colon or rectal mucosa. This forms the formal part of the examination.

Caveat:

- Inflating enough air in the bowel for visualization is important however over inflation should be avoided due to patient discomfort. The pressure in the air reservoir bulb is the same as that in the rectum.
- Force should never be used and the scope should only be advanced in the presence of a visible lumen.
- Navigating the sigmoidoscope round the rectosigmoid junction can be difficult and uncomfortable for the patient.
- Avoid the insufflation of large volumes of gas during sigmoidoscopy in the event of anorectal trauma. Stool can be forced through a proximal bowel perforation into the peritoneal cavity¹⁰.
- Visualization of the sigmoid colon is seldom achieved during sigmoidoscopy.

4. Materials

- Sterile gloves.
- Lidocaine jelly.
- Sedation as needed.
- Proctoscope.
- Sigmoidoscope (rigid), with facilities for general anesthesia.

5. Anatomy pitfalls

5.1 Rectosigmoid junction

The rectosigmoid junction is approximately 15 cm from the anal margin. At this point the lumen crosses the sacral promontory.

5.2 Sigmoid colon

At the rectosigmoid junction the sigmoid colon bends forward and to the left. Therefore the viewing end of the scope should be swung posteriorly and superiorly to the patient's right hip. Perforation of the bowel can easily occur at this point.

5.3 Rectum

- The rectum starts where the sigmoid colon loses its mesentery opposite the third sacral vertebra. This is called the rectosigmoid flexure⁹.
- The rectum ends at the tip of the apex of the prostate in men and at the posterior wall of the vagina in women, 2.5-3.1 cm below the tip of the coccyx. Here it changes direction at right angles to become the anal canal⁴. Its total length is approximately 12.5 cm.
- The anorectal junction is called the perineal flexure of the rectum and is pulled anteriorly by the puborectalis muscle⁹.
- The inferior dilated part of the rectum is called the ampulla. The finger enters the ampulla after passing through the resistant external sphincter. The ampulla follows the concavity of the sacrum, which is called the sacral flexure⁹.
- The inferior third of the rectum is free of peritoneum as the peritoneum sweeps forward to form the recto-vesical pouch in the male and the recto-uterine pouch or pouch of Douglas in the female.
- The middle third of rectum is posterior and laterally free from peritoneum and most of the upper third of the rectum is covered by peritoneum anteriorly and laterally.
- Normal rectal mucosa has a smooth glistening and pink appearance. The vascular pattern is visible through the mucosa.
- The following mucosal changes may be experienced: granularity, hyperemia, contact bleeding, pus and blood and active ulceration.
- Rectal wall penetration of rectal carcinoma can be rather accurately determined by digital rectal examination, as Rafaelsen¹⁸ demonstrated. Penetration of the rectal wall was correctly identified in 56 of 61 patients by digital rectal examination compared to 59 of 61 patients with transrectal linear ultrasonography. Cases without penetration of the rectal wall were identified in 26 of 33 patients by transrectal linear ultrasonography and only in 13 of 33 cases by digital rectal examination. Ultrasonography is therefore superior to digital rectal examination in detecting early Dukes A rectal tumors¹⁸.

- Regional lymph node metastasis was not diagnosed in any patient by digital rectal examination. Tumors situated superiorly in the rectum cannot be reached with the finger¹⁸.
- The rectum is straighter in a child and relatively larger⁴.

5.3.1 Endoscopic anatomy of the rectum

5.3.1.1 Rectal curves

- The rectum curves in an antero-posterior or sagittal plane. It has a marked antero-posterior curve following the concavity of the sacrum.
- The rectum also curves in a coronal plane. The upper and lower thirds are straight, but the middle third curves to the left. This causes inflections into the rectum. Usually two lie to the left and one to the right⁴. These inflections can be seen with a sigmoidoscope and are referred to as the valves of Houston who first described them²². See Fig 1.

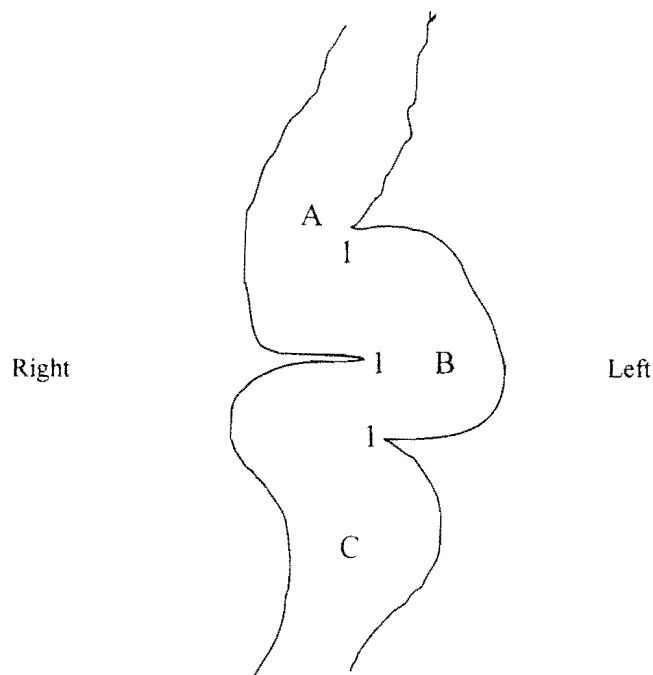


Fig 1. Diagram illustrating the rectum (sagittal section) with the transverse rectal folds (Houston's valves) (1), the upper third (A), the middle third (B) and the lower third (C)

5.3.1.2 Valves of Houston²² (transverse rectal folds)

- Houston²² describes the position of the largest and most regular fold to be three inches from the anus opposite the base of the bladder. Another fold is found near the upper end of the rectum and a third fold somewhere between these two. Houston²²

described an infrequent fourth fold found approximately an inch above the anus.

- The valves contain all the layers of the rectal wall including the outer longitudinal muscular layer. Silver²³ describes their embryological development. First the submucosa becomes thickened followed by the invasion of the circular and longitudinal muscular layers and the perirectal connective tissue. The same findings were reported by Shafik *et al*²⁴ who rarely found that the folds were purely mucosal. The rectal folds thus formed contain mucosa and circular muscle, unlike the mucous membrane only of the valvulae coniventes of the small bowel. This minimizes the risk of perforation during a rectal biopsy.
- The lumen of the rectum therefore has a tortuous path through the valves of Houston²² and is described by Silver²³ as 'horizontal baffle plates' from the lateral wall of the rectum.
- Shafik *et al*²⁴ reports in a cadaver-based study (n=18) that the number of the transverse rectal folds varies. Most had two or three folds, but in a few cases there were more than three folds and even no folds at all. The folds are thick at the base and become thinner towards the midline. Most folds actually extend beyond the midline of the rectal lumen.
He also studied the folds radiologically on barium enemas. In most subjects two or three folds were present. The folds approach the midline of the rectum in two thirds of the subjects.
Of the 54 subjects studied, either radiologically (n=36) or dissection-based (n=18), the folds were absent in 3.7% of cases. The total number of cases with two or three folds was 77.7%, with the threefold pattern being the most frequently observed.
- Shafik *et al*²⁴ proposes that the transverse rectal folds delay the passage of stool due to the fact that they compartmentalize the rectum in a shelving fashion. This prevents a sudden entrance of stool into the rectum and resulting defecation sensation in inopportune circumstances.
- Shafik *et al*²⁴ describes the position of the folds from superior to inferior in most of his cases: Left, right and again left on the inner aspect of the rectal wall. The second fold from superior was in all cases positioned on the right.
- Two folds are found in the rectal ampulla: longitudinal and horizontal. The longitudinal folds are mucosal folds that disappear during distention of the rectum. The horizontal folds are circular muscular layers and are enhanced with distention.
- According to Godlewski *et al*⁹, three prominent folds can be identified: superior, middle and inferior.
 - The superior fold is found below the rectosigmoid flexure. The superior fold forms the upper margin of the ampulla. It also represents the junction between the upper part of the rectum from the hindgut and the middle part from the cloaca.

- The middle fold divides the ampulla in a superior suprapерitoneal part, which can distend laterally in the pelvirectal cavity and therefore serve as a space for storage of feces, and an inferior infraperitoneal part in a confined position in the pelvic cavity and therefore usually empty between defecation. The clinical implication of the middle transverse rectal fold is important. Perforation above the middle fold result in an intraperitoneal perforation whereas perforation below this fold does not lead to an intraperitoneal perforation.
- The inferior fold is found 2-3 cm below the middle fold, is not always present and is situated on the left side of the ampulla.

- **Measurements**²⁴

- **Distances from the anal verge:**
Inferior fold: 7.2 cm (adult); 2.8cm (neonates)
- **Distance between folds:**
Adults: 2.8cm
Neonates: 1.2 cm
- **Mean length of folds:**
Adult: 4.8cm
Neonates: 1.1cm
- **Mean thickness at the base:**
Adults: 0.8cm
Neonates: 0.36cm

5.3.2 Relations of the rectum

Posterior

- The anterior surface of the sacrum (S3,S4 and S5) and coccyx can be felt. Lesions of the bone and presacral space can be palpated.
- Coccydynia may be diagnosed on producing pain during movement of the coccyx.
- The median sacral artery and branches of the superior rectal artery are found posterior to the rectum⁹.

Anterior

Male:

- The seminal vesicles may just be reached with the tip of the finger. It is difficult to palpate normal seminal vesicles, but a pathologic vesicle may be palpated.
- The bladder lies directly anterior to the seminal vesicles and can only be

palpated when it is distended.

- The prostate lies inferior to the bladder. The rectum slides easily over the posterior surface of the prostate due to the rectovesical septum.

Female:

- The cervix can be palpated with superior to it the recto-uterine pouch and inferiorly the posterior vaginal wall.
- Between the rectum and the bladder in a male and rectum and uterus in the female, loops of ileal coils and sigmoid colon may be found.

In both male and female, lesions of the peritoneum may be felt through the anterior wall of the rectum

Lateral

- The superior part of the rectum has the pararectal fossae laterally. During distention of the ampulla, the lateral surface can stretch to the parietal pelvic peritoneum, the superior part of levator ani, the pelvic ureter and the posterior branches of the internal iliac artery and vein.
- In women, the uterine tubes and ovaries are lateral to the superior part of the rectum.
- Below the peritoneal attachment line, the parasympathetic sacral splanchnic nerves (S2,3,4), hypogastric nerves and hypogastric plexus with the sympathetic trunks of left and right are found lateral to the rectum.

5.3.3 Arterial supply

- The rectum is supplied by the superior, middle and inferior rectal arteries and the median sacral artery.
- The superior rectal artery emerges from the inferior mesenteric artery.
- The middle rectal artery arises from the internal iliac artery and is unilateral in 22% of cases
- The inferior rectal artery arises from the internal pudendal artery.
- The median sacral artery emerges from the abdominal aorta and runs posterior to the rectum.

5.3.4 Veins

- Three rectal venous plexuses are found: the external, internal and perimuscular plexus. The external rectal venous plexus is found between the subcutaneous part of the external sphincter and the anal skin. Enlargement of this plexus causes external hemorrhoids⁹. They occur below the pectinate line and can easily be identified on inspection¹.
- The plexuses drain via the superior rectal vein (portal route), middle and inferior rectal veins (systemic route) as well as the median sacral vein

(systemic route).

5.3.5 Lymphatic drainage

- The lymphatic vessels follow the venous drainage of the rectum via the superior, middle and inferior rectal veins.

5.4 Anus

- The anus forms the terminal 3.1 to 3.75 cm of the gastrointestinal tract⁴.
- The anal canal starts from the rectum below the tip of the coccyx in a downward and posterior direction.
- Any instrument that is passed into the anal canal, should therefore initially be directed anteriorly in the direction of the umbilicus and after reaching the rectum in a posterior direction.
- Two parts with distinct differences concerning arterial blood supply, venous drainage, nerve supply, lymphatic drainage, epithelium and embryological origin, can be identified superior and inferior of the pectinate line.

5.4.1 Embryology⁹

- The upper part is derived from the cloaca and the mucous membrane forms sinuses and anal columns. The epithelial lining is stratified columnar epithelium.
- The lower part below the pectinate line is of ectodermal origin and is lined by squamous epithelium.

5.4.2 Endoscopic anatomy of the anal canal⁹

- The lumen is divided into three parts: the columnar zone, the transitional zone or pecten and the cutaneous zone.
- Columnar zone: this is the superior part of the anal canal. It has 5 to 10 longitudinal mucosal folds called the anal columns of Morgagni. Every column has a terminal branch of the superior rectal vessels. Enlargements of these veins are called internal hemorrhoids.
The color of the mucosa is purple due to the rectal venous plexus. At the base of every column, small mucosal folds, called anal valves are found. The alignment of these valves forms the pectineal line⁹.
The anal sinuses are above the anal valves and inbetween the anal columns. These may get infected or form abscesses.
Anal glands empty into the anal crypts in the region of the anal sinuses at the pectinate line.

- The transitional zone extends approximately 1.5cm. It forms a purple ring sometimes called the white line, between the columnar epithelial mucosa and the anal skin. It is located at the intersphincteric groove (between the subcutaneous part of the external anal sphincter and the lower border of the internal anal sphincter).
- The cutaneous zone appears white or brown and the epithelium contains sweat glands and sebaceous glands.

5.4.3 Relations

- Posterior: Coccyx and anococcygeal raphé
- Anterior:
 - Perineal body
 - Bulb of the penis in the male
 - Posterior vaginal wall in the female.
- Lateral: Ischioanal fossa with the inferior rectal nerve and vessels.

5.4.4 Nerve supply⁹

- Proximal to the white line the anal mucosa is supplied by the autonomic nerves plexus and inferior to it by the inferior rectal nerve (somatic nerve). Lesions below the white line are therefore very painful and conditions above the line are usually without pain.
- The sympathetic nerves are inhibitory to the musculature and responsible for the tonus of the internal sphincter. The parasympathetic supply causes movement of the muscles of the rectum and relaxes the internal sphincter for defecation.

5.4.5 Epithelium

- The pectinate line contains glands, which secrete mucus to lubricate the anal canal. It also has anal valves that lie at the distal end of numerous (5 to 10) vertical anal columns.
- Anal crypts are found at the pectinate line and can cause perianal abscess.
- A number of 4 to 8 anal glands open into the anal crypts. They may become infected or be the site for neoplastic change.
- Squamous epithelium is found distal to the white line and columnar epithelium proximal to the white line.
- The squamous epithelium is modified skin devoid of skin appendages.

- Proctoscopically, the epithelial color changes from pink mucosa above, to purplish near the pectinate line and pale below the white line.
- At the anorectal junction, there is mixing of the two epithelial layers, which is called the transition zone.

5.4.6 Arterial blood supply

- Proximal to the pectinate line, the anal canal is supplied by the superior rectal artery from the inferior mesenteric artery and the middle rectal artery from the internal iliac artery, and distal to the line by the inferior rectal artery, which is a branch of the internal pudendal artery.

5.4.7 Venous drainage

- A porto-systemic anastomoses is formed around the pectinate line. Hemorrhoids may theoretically form. Ger⁴ states that it is difficult to prove cause and effect, but strong bleeding after biopsies in patients with schistosomiasis reflect the importance of this anastomosis.

5.4.8 Hemorrhoids

- **Internal hemorrhoids** are just proximal to the pectinate line, and external hemorrhoids just distal to the line. These are considered to be collections of veins and arteries that represent normal anatomy and are not considered varicose veins.
- Internal hemorrhoids are varicosities of the submucous plexus in the wall of the anal canal and lower rectum. They are radicles of the superior rectal vein and contain a branch of the superior rectal artery and mucosal covering.
- Unless thrombosed they are not palpable.
- The branches of the superior rectal vessels are regularly distributed, explaining the common positions of the internal hemorrhoids at 3,7 and 11 o'clock as seen in the lithotomy position.
- Internal hemorrhoids can be better appreciated at proctoscopy¹.
- Hemorrhoids can be classified as: Grade 1 hemorrhoids which bulge and bleed at the time of defecation. Grade 2 which prolapses during defecation but return spontaneously. Grade 3 which prolapses from the anal canal at any time, but especially during bowel movement. They require digital replacement. Grade 4 represents permanently prolapsed hemorrhoids¹.
- The cardinal symptoms of hemorrhoids are pruritis ani (itching), bleeding, protrusion

and pain.

5.5 Anal sphincters

- Voluntary continence is maintained by the external anal sphincter and puborectalis muscle. Involuntary continence is maintained by the internal anal sphincter.
- Modern imaging techniques like endosonography of the anus, gives a 360° view of the sphincters, both internal and external¹¹.

5.5.1 External anal sphincter.

- The external anal sphincter is external to the internal sphincter not only from a medial to lateral aspect, but also from a cephalad to caudad aspect at the anal verge.
- The external sphincter extends from the anal verge to the anorectal ring.
- The sphincter has three parts: subcutaneous, superficial and deep.
 - The deep part is found around the superior part of the anal canal. with its fibers mixing with the puborectalis muscle.
 - The superficial part is found at the level of the anocutaneous or white line.
 - The subcutaneous part is found surrounding the cutaneous zone of the anal canal.
- Cagnard *et al*⁴⁰ described the nerve supply to the external anal sphincter. In a study of 45 dissections, three branches were identified: 1) Inferior rectal branch, 2) the anterior branch from the external perineal nerve and 3) an independent posterior branch. The inferior rectal branch and anterior branch always emerged from the pudendal plexus. The posterior branch emerged either from S4 or from the inferior rectal nerve and was found in 31% of cases. Cagnard *et al*⁴⁰ suggests that suitable names for these nerves would be anterior, middle and posterior anal nerves.

5.5.2 The anorectal ring

- The anorectal ring is located 1 to 2 cm above the pectinate line.
- This palpable anorectal ring represents mainly the puborectalis muscle, but also includes the deep portion of the external anal sphincter and the internal anal sphincter, encircling the very distal rectum from its anterior point of attachment at the pubis.
- The puborectalis comes from the posterior aspect of the pubis and passes postero-inferior to the rectum to form a sling with the other side. Some of the muscles blend with the external anal sphincter⁴. This sling forms the

80-90° angle of the anteriorly and inferiorly directed rectum passing into the posteriorly and inferiorly directed anal canal.

- The puborectalis muscle is palpable along its whole length during rectal examination.

5.5.3 Internal anal sphincter

- The internal anal sphincter consists of a double muscular layer, which is a thickening of the circular muscle coat of the rectum. It is controlled by autonomic nerves.
- The intersphincteric groove is formed between the upper border of the subcutaneous part of the external anal sphincter and the lower border of the internal anal sphincter. This can be palpated during rectal examination.

5.6 Anal sphincter tone

- Resting tone is reflected by function of the internal anal sphincter whereas squeeze pressure is reflected by function of the external anal sphincter. The difficulty to initially insert the digit is due to the tone of the internal anal sphincter³⁶.
- Kaushal *et al*²¹ has demonstrated that the estimation of anal sphincter squeeze pressure by digital examination compares favorably with objective manometric determinations of anal sphincteric pressure. Digital examination is therefore an excellent screening tool for assessing sphincter tone.
- The anal sphincter squeeze pressure can be subjectively estimated by the following scale²¹: 1=absent, +1=markedly reduced, +2=reduced, +3= normal.
- Puborectalis will also contract (in the anorectal ring) during squeezing of the anal sphincter, pulling the tip of the examining finger from posterior to anterior. When sweeping the finger around the circumference of the distal rectum at the level of the anorectal ring, the point of fixation of the puborectalis at the symphysis pubis may be palpated.

5.7 Peritoneum

- Reflections of the peritoneum form the recto-uterine pouch in female and the rectovesical pouch in male.
- The visceral pelvic peritoneum surrounds the rectosigmoid junction.
- The peritoneum is attached to the posterior wall of the vagina in women to form the recto-uterine pouch. This pouch is on a lower level compared to the rectovesical pouch in men. The distance from the pouch to the anus is 5.5 in women cm and 7.5

cm in men. The recto-uterine pouch is bordered laterally in women by the recto-uterine folds.

- The recto-uterine pouch contains ileal coils and sigmoid colon in women.
- The rectum can be divided into a superior part that is located intraperitoneally and an inferior part, which is located subperitoneally. This division is usually at the level of the middle transverse rectal fold (valve of Houston ²²) ⁹.

5.8 Pelvic cavity

- Tenderness high up in the rectum during digital examination may reveal pathology in the pelvic cavity.
- Tenderness in the recto-uterine or rectovesical pouches may suggest injury to an intra-abdominal organ with blood collection in the pouch, or a ruptured ectopic pregnancy or pus from an inflamed organ such as the uterine tube or appendix.
- Deposits from an intra-abdominal malignancy like stomach carcinoma may be palpable in the pouch through the wall of the rectum.

5.9 Right iliac fossa

- Tenderness in the right iliac fossa as experienced by digital rectal examination, is more common in patients with acute appendicitis. However the other symptoms and clinical signs of acute appendicitis such as pain, anorexia, nausea and vomiting, tenderness in the right iliac fossa, rebound tenderness and guarding are more specific. Dixon *et al* ³² studied 1204 patients with pain in the right iliac fossa, 1028 of who had a digital rectal examination. He found that the abdominal signs are better predictors of appendicitis. If rebound tenderness in the right iliac fossa is present, a rectal examination does not provide any further diagnostic information.
- In a study performed by Dickson *et al* ¹⁵ on 103 children, the correct diagnosis was made in 90% of cases by the history and abdominal findings during physical examination. Rectal examination altered management in only two cases. He also found that a rectal examination was a poor indicator for pelvic sepsis postoperatively. Rectal tenderness was present in the absence of acute appendicitis in 12% of children. Dickson concludes that the rectal examination is not necessary in children presenting with a clear history and abdominal signs of appendicitis. It remains important in those with acute abdominal symptoms, but inconclusive abdominal signs. This may be the case in pelvic appendicitis with or without abscess formation.

5.10 Coccyx

- The fifth sacral vertebra and the first coccygeal vertebra are commonly fused⁴.

- A fracture of the coccyx will present with extreme pain when palpating the posterior wall of the rectum.

5.11 Prostate

- The prostate has a firm rubbery consistency and a smooth surface. Nodules or smooth enlargement may be palpated. Tenderness may indicate infection of the gland.
- The following are abnormal findings of the prostate during digital rectal examination³⁴: Nodularity, induration, asymmetry or absence of the median sulcus.
- A normal prostate is 3.5cm from side to side and protrudes 1cm into the rectum⁸. It has a smooth and rubbery consistency, with a shallow groove separating the left and right lobes.
- There is no exterior lobular configuration of the prostate gland. The prostate is divided in zones rather than lobules. McNeal²⁵ described a peripheral zone, a central zone surrounding the ejaculatory duct and a transitional zone lateral to the prostatic urethra. Benign prostatic hypertrophy (BPH) develops in the transitional zone. In BPH, an identifiable lobar architecture develops, which was absent before the hyperplasia²⁶. Above the age of 35, the hyperplastic process starts with the growth of adenomatous acini forming right and left lateral lobes, a middle lobe surrounding the urethra and sometimes a periurethral anterior lobe. These are adenomatous lobes growing from the transitional zone compressing the peripheral zone, by displacing the normal relatively homogenous prostate. Therefore, when performing a rectal examination and palpating a left and right lateral lobe, this will be attributed to BPH. The normal prostate becomes a thin compressed capsule. A lobar architecture of the prostate as palpated during rectal examination is therefore abnormal²⁶.
- Except for digital examination, the prostate can also be imaged by magnetic resonance and transrectal ultrasonography.

5.11.1 Accuracy of rectal examination in detecting prostate carcinoma:

- **Size of the gland**
 - Digital rectal examination underestimates the size of the prostate¹⁷.
 - Bissada *et al*³⁸ found that more than 50% of the estimates for prostate size differed from the actual adenoma weight.
- **Size of nodule or indurated area**
 - Spigelman *et al*³⁷ found that the rectal examination estimates of

tumor size correlated poorly with the actual tumor area as determined histologically. They conclude that the examining finger actually only assesses differences in firmness between regions of the prostate. The digital rectal examination is useful as a screening method, but not for staging or grading prostate carcinoma.

- Phillips *et al*²⁰ concludes that a digital examination is not an accurate examination for prostate carcinoma.

5.11.2 Reliability of rectal examination (Will the conclusions of different observers be the same?)

- In a study done by Phillips *et al*²⁰ to assess the reliability of the digital rectal examination, the interobserver variability was high.
- However with proper teaching, the reliability increased. They correlated the rectal examination with rectal ultrasonography and propose the teaching of digital rectal examination by correlating it to rectal ultrasonography of the prostate gland.

5.11.3 Specificity and sensitivity

- For prostate carcinoma, a digital rectal examination is a specific test. Phillips *et al*²⁰ reports that if a patient has a prostate cancer with a palpable nodule, it is very likely to be adenocarcinoma.
- Digital rectal examination is however not very sensitive. Many patients who are dying from prostate carcinoma, never develop a palpable abnormality of the prostate²⁰. This justifies the use of rectal ultrasonography, which is more sensitive.
- Phillips *et al*²⁰ categorically states that although there are limitations to the value of digital rectal examination regarding the diagnosis of prostate carcinoma, it remains the principal method for the early detection of prostate carcinoma.

5.11.4 Posterior surface of the prostate

- Roehrborn *et al*¹⁷ has demonstrated that the posterior palpable surface of the prostate as examined by digital rectal examination, correlates well with prostate size. The posterior surface area of the prostate should not be more than 7 cm².

6. Complications (anatomically relevant)

6.1 Pain

- Dickson *et al*¹⁵ reports that pain is an important consideration in children undergoing rectal examination. In a study of 103 children over a third experienced severe discomfort.
- External hemorrhoids below the pectinate line cause significant pain¹. Internal hemorrhoids found above the pectinate line present with painless bleeding.
- Crampy abdominal pain can be experienced during sigmoidoscopy due to insufflations of air.

6.2 Digital rectal examination not performed

- Studies show that only half of patients with anorectal symptoms have a rectal examination before being referred. Delay in the diagnosis of colorectal cancers is related to the doctor in a quarter of cases²⁹.
- De Klerk³⁰ reports that 35% of patients with prostate cancer do not have a rectal examination performed before referral.
- Hennigan *et al*³¹ points out that the proper undergraduate and postgraduate training of digital rectal examination, increases the frequency of the performance of rectal examination.
- Yanoshak *et al*³⁹ reports on improved performance of prostate evaluation by digital rectal examinations by general practitioners. He used a three dimensional prostate model to teach the procedure.
- No patient with anorectal symptoms should be reassured by his doctor without performing a rectal examination.

6.3 Cardiac dysrhythmias

- Munter *et al*² reports on a 75-year-old man who developed ventricular fibrillation during a digital rectal examination.
- Syncope and bradydysrhythmias have also been reported. These are all very rare complications and are postulated to be vagally mediated.
- Fletcher *et al*⁶ showed that 70% of patients during routine sigmoidoscopy, demonstrated ECG changes like increased heart rate, ectopic beats and bradycardia in 4% of patients. These changes were not seen during digital rectal examination or

during insertion of the sigmoidoscope. The increased heart rate and ectopic beats were probably due to anxiety and catecholamine release. Fletcher *et al*⁶ demonstrated that there was a significantly greater frequency of an increase in the ectopic beats of those patients with existing heart disease (40%) than those without (17%).

- In a subsequent study Earnest *et al*³⁵ performed digital rectal examinations on 86 patients with acute myocardial infarctions 24 hours after admission to the hospital. They observed no electrocardiographic effects and no angina pectoris was elicited. They found 12 patients with marked prostate enlargement. It is therefore clear that the benefits gained from a digital rectal examination outweigh the small risk of bradycardia and arrhythmias.
- Rectal examination is important in clinical situations like acute gastrointestinal bleeding, trauma patients, patients with neurological deficits, patients with unexplained postural hypotension or anemia, or before starting anticoagulant therapy². Patients need to be individualized and a patient with an acute myocardial infarction with no specific reason to perform a digital rectal examination can wait a week or so for this examination.
- There may be two reasons for ventricular fibrillation during rectal examination. The rectum is innervated by parasympathetic fibers, which are pressure sensitive. They transmit via the parasympathetic sacral splanchnic pathway (S2,3,4) and relay in thalamic and brainstem nuclei resulting in increased vagal tone⁷. This causes a bradycardia and ventricular ectopic beats that can cause ventricular arrhythmias. The second reason may be catecholamine release.

6.4 Elevated Prostatic Specific Antigen (PSA)

- There has been concern that a serum-PSA level done after digital rectal examination may be falsely elevated due to the procedure.
- Crawford *et al*³ however demonstrated in a prospective trial of more than 2000 patients, that digital examination did not significantly elevate levels of serum-PSA.

6.5 Injury to the mucosal wall

- Both a proctoscopic and sigmoidoscopic examination may result in irritation of the mucosal wall, with abrasion and increased bleeding.

6.6 Transmittance of infectious diseases

- Infectious diseases like Hepatitis B, Condilomata accuminata, Genital Herpes simplex virus and Human Immuno deficiency Virus (HIV) can be transmitted with the procedure. Sterilizing instruments is an imperative.

6.7 Perforation

- The most common cause for anorectal trauma is iatrogenic by diagnostic and therapeutic procedures¹⁰.
- Perforation is a surgical emergency and requires prompt operation.
- No force should be applied to advance the proctoscope or sigmoidoscope. This is especially true at the angles of the rectosigmoid junction and recto-anal junction as well as the concave curve of the rectum anterior to the sacrum.
- The risk of perforation during the taking of a biopsy is reduced by performing the biopsy postero-laterally. This area is not intraperitoneally but extraperitoneally.
- A barium enema should not be performed for 5 days after a biopsy was done.
- The scope should not be advanced unless bowel lumen is clearly seen at the tip of the scope.
- Excessive depth of biopsy in the rectal wall should be avoided and great care should be taken with electrocautery.
- Perforation of the rectal wall involving the superior two thirds of the rectum, usually involves the peritoneal cavity whereas perforation of the inferior third does not involve the peritoneal cavity. This is due to the peritoneal coverings of the rectum.
- Foreign bodies in the rectum can be classified in high and low lying objects. High lying objects are above the rectosigmoid junction and low-lying objects below this junction and therefore digitally palpable. Perforation may occur during insertion of the object or during attempts to remove the object⁵.
- The American Association of the Surgery of Trauma has graded rectal injuries according to an anatomical description¹⁰. Grade 1 – Hematoma, contusion without devascularization or a partial-thickness laceration, Grade 2 – laceration of <50% of the mucosal circumference, Grade 3 – laceration of > 50% of the mucosal circumference, Grade 4 – Full thickness laceration with extension into the perineum and Grade 5 – devascularized segment.
- Colon perforation combined with genitourinary injuries, can result in pelvic, suprapubic and subphrenic abscesses as well as fistulae and strictures¹⁰.

6.8 Excessive bleeding

- Excessive bleeding may occur due to a biopsy of a vascular lesion, tear of the bowel wall, a coagulation defect and palpation of an ulcerating tumor in the rectum.

6.9 Underestimating the size of the prostate gland

- Roehrborn *et al*¹⁷ showed in a study correlating prostate size estimated through digital rectal examination with volume measured by transrectal ultrasonography, that prostate size was underestimated in 25-55% of men with a prostate volume of over 40 ml.
However, the posterior surface area of the prostate as measured by digital examination, correlated well with the transrectal ultrasonography measurement. It seems that the posterior surface area of the prostate greater than 7 cm² to determine large prostates is a useful preliminary assessment.
- The ratio of the posterior prostate surface to the prostate volume decreases with age. This explains why a digital rectal examination will underestimate the volume of the prostate as it enlarges. Furthermore, the lateral borders of the posterior surface of the prostate gland are difficult to exactly demarcate during a digital rectal examination with underestimation of the prostatic volume as a result¹⁷.
- Transrectal ultrasonography and MRI can determine prostate volume more accurately.

6.10 Missing pathology

- The sensitivity of digital rectal examination to rectal carcinoma and appendicitis is low. It is difficult to feel abnormalities of the rectal mucosa¹⁹.
It is however higher for prostate carcinoma¹⁹, although patients with prostate cancer may never develop a palpable abnormality²⁰. Hoogendam *et al*³³ did a meta-analysis of several studies to determine the specificity, sensitivity and positive and negative predictive values for digital rectal examination in the screening of prostate carcinoma. The examination has a high specificity and negative predictive value but lower sensitivity and positive predictive value. Therefore a digital rectal examination should be confirmed with other confirming tests, whether it is positive or negative.
- A lower rectal tumor may be missed if only a proctoscopy or sigmoidoscopy is done. A digital rectal examination should always be done first.
- Digital rectal examination and PSA screening remain the standard in early detection tests of prostate carcinoma³⁴.

6.11 Bacteremia

- Due to trauma to mucosal surfaces, transient bacteremia may occur. It has been reported in 0-9.5% of patients after a sigmoidoscopy. Hoffman *et al*²⁷ reports in a study of 74 patients undergoing a digital rectal examination with an initial negative blood culture, an incidence of 4% having positive blood cultures after the procedure. The venous drainage of the anal canal below the pectinate line is systemic via the inferior and middle rectal veins. Blood from above the pectinate line drains into the

portal system. A porto-systemic anastomosis exists. Trauma to the inferior part of the anus (systemic venous drainage) during a sigmoidoscopy, proctoscopy and digital rectal examination, is more likely to cause bacteremia, for the liver serves as an excellent filter for bacteria (portal venous drainage).

- Trauma during digital rectal examination is probably little more than that occurring during defecation.
- Hoffman *et al*²⁷ states that there is no reason to give prophylactic antibiotics to patients with cardiac lesions undergoing rectal examination, for the bacteria isolated are not known to cause endocarditis.

6.12 View obscured by feces

- Cotton wool pledgets may be used during a sigmoidoscopy to clear the view. The procedure may also be repeated after the patient had an enema. This may be necessary due to the fact that patients with chronic constipation may have feces present in the whole rectum⁹.

7. References

- ¹ Mazier WP. Hemorrhoids, fissures and pruritis ani. *Surg Clin North Am* 1994;74:1277
- ² Munter DW, Stoner RS. Ventricular fibrillation during rectal examination. *Am J Emerg Med* 1989;7:57
- ³ Crawford ED, Schultz MJ, Clejan S et al. The effect of digital rectal examination on prostate-specific antigen levels. *JAMA* 1992;267:2227
- ⁴ Ger R. Surgical anatomy of the pelvis. *Surg Clin North Am* 1988;68:1201-1216
- ⁵ Wigle RL. Emergency department management of retained rectal foreign bodies. *Am J Emerg Med* 1988;6(4):385-389
- ⁶ Fletcher GF, Earnest DL, Shuford WF et al. Electrocardiographic changes during routine sigmoidoscopy. *Arch Intern Med* 1968;122:483-486
- ⁷ Adams RD, Victor M. *Principles of Neurology* (ed 2). New York; McGraw-Hill, 1981: 362-383
- ⁸ Epstein O, Perkin GD, De Bono DP, Cookson J. *Clinical Examination*. London: Mosby, 1992: 8.36-8.39
- ⁹ Godlewski G, Prudhomme M. Embryology and anatomy of the anorectum. *Basis of surgery*. *Surg Clin North Am* 2000; 80:319-343
- ¹⁰ Fry RD. Anorectal trauma and foreign bodies. *Surg Clin North Am* 1994; 74(6):1491-1505
- ¹¹ Hull TL, Milsom JW. Pelvic floor disorders. *Surg Clin North Am* 1994; 74(6): 1399-1413
- ¹² Ng DPK, Mayberry JF, McIntyre AS, Long RG. The practice of rectal examination. *Postgrad Med J* 1991;67:904-906
- ¹³ Scholer SJ, Pituch K, Orr DP, Dittus RS. Use of the rectal examination in children with acute abdominal pain. *Clin Pediatr* 1998;37(5):311-6

- ¹⁴ Jesudason EC, Walker J. For debate: Rectal examination in paediatric surgical practice. *Br J Surg* 1999;86:376-8
- ¹⁵ Dickson AP, MacKinlay GA. Rectal examination and acute appendicitis. *Arch Dis Child* 1985;60:666-7
- ¹⁶ Advance Life Support Group. *Advanced Pediatric Life Support: The practical approach*. 2nd Ed London: BMJ Publishing Group, 1997
- ¹⁷ Roehrborn CG, Girman CJ, Rhodes J, Hanson KA et al. Correlation between prostate size estimated by digital rectal examination and measured by transrectal ultrasound. *Urology* 1997;49(4):548-57
- ¹⁸ Rafaelsen SR, Kronborg O, Fenger C. Digital rectal examination and transrectal ultrasonography in staging of rectal cancer. A prospective, blind study. *Acta Radiologica* 1994;35(3):300-4
- ¹⁹ Muris JW, Starmans R, Wolfs GG, Pop P, Knottnerus JA. The diagnostic value of rectal examination. *Family Practice* 1993;10(1):34-7
- ²⁰ Phillips TH, Thompson IM. Digital rectal examination and carcinoma of the prostate. *Urol Clin North Am* 1991;18(3):459-65
- ²¹ Kaushal JN, Goldner F. Validation of the digital rectal examination as an estimate of anal sphincter squeeze pressure. *Am J Gastroenterol* 1991;86(7):886-7
- ²² Houston J. Observations of the mucous membrane of the rectum. *Dublin Hosp. Rep* 1830;5:159-165
- ²³ Silver PHS. Observations on the valves of Houston in the human embryo and foetus. *J of Anatomy* 1955;89:217-224
- ²⁴ Shafik A, Doss S, Ali YA, Shafik AA. Transverse folds of the rectum: Anatomic study and clinical implications. *Clin Anat* 2001;14:196-203
- ²⁵ McNeal JE. Regional morphology and pathology of the prostate. *Am J Clin Pathol* 1968;49:347-357
- ²⁶ Myers RP. Structure of the adult prostate from a clinician's standpoint. *Clin Anat* 2000;13:214-215
- ²⁷ Hoffman BI, Kobasa W, Kaye D. Bacteremia after rectal examination. *Annals of Internal Medicine* 1978;88:658-659
- ²⁸ Balkan E, Kiristioglu A, Gürpınar A, Özel KS, Dogruyol H. Sigmoidoscopy in minor lower gastrointestinal bleeding. *Arch Dis Child* 1998;78:267-268
- ²⁹ Holliday H, Hardcastle J. Delay in diagnosis and treatment of colorectal cancer. *Lancet* 1979; i: 309-311
- ³⁰ De Klerk DP. Rectal examination in the detection of prostate cancer. *S Afr Med J* 1988;73:157-8
- ³¹ Hennigan TW, Franks PJ, Hocken DB, Allen-Mersh TG. Rectal examination in general practice. *BMJ* 1990;301:478-480
- ³² Dixon JM, Elton RA, Rainey JB, Macleod DA. Rectal examination of patients with pain in the right lower quadrant of the abdomen. *BMJ* 1991;302:386-8
- ³³ Hoogendam A, Buntinx F, De Vet HCW. The diagnostic value of digital rectal examination in primary care screening for prostate cancer: a meta-analysis. *Family Practice* 1999;16:621-626
- ³⁴ Brett TD. An analysis of digital rectal examination and serum-prostate-specific antigen in the early detection of prostate cancer in general practice. *Family Practice* 1998;15:529-533

-
- ³⁵ Earnest DL, Fletcher GF. Danger of rectal examination in patients with acute myocardial infarction – fact or fiction? *New Eng Jour Med* 1969;281:238-241
- ³⁶ Addison R. Digital rectal examination-2. *Nursing Times* 1999;95:39-40
- ³⁷ Spigelman SS, McNeal JE, Frieha FS, Stamey TA. Rectal examination in volume determination of carcinoma of the prostate: Clinical and anatomical correlations. *J of Urol* 1986;136:1228-1230
- ³⁸ Bissada NK, Finkbeiner AE, Redman JF. Accuracy of preoperative estimation of resection weight in transurethral prostatectomy. *J Urol* 1976;116:201
- ³⁹ Yanoshak SJ, Roehrborn CG, Girman CJ, Jaffe JS, Ginsberg PC, Harkaway RC. Use of a prostate model to assist in training for digital rectal examination. *Urology* 2000;55:690-693
- ⁴⁰ Cagnard C, Godlewski G, Prat D, Lan O, Cousineau J, Maklouf Y. The nerve branches of the external anal sphincter: the macroscopic supply and microscopic structure. *Surg Radiol Anat* 1986;8:115-119
- ⁴¹ Personal communication, Mr T Welsh, Fellow of Queens College, Cambridge, Sept 2001