

**PANSTEATITIS IN AFRICAN SHARPTOOTH CATFISH, *CLARIAS GARIEPINUS*  
(BURCHELL), IN THE KRUGER NATIONAL PARK, SOUTH AFRICA**

by

KARL DAVID AUGUST HUCHZERMAYER

Submitted in fulfilment of the requirements for the degree of

DOCTOR OF PHILOSOPHY

In the Department of Paraclinical Sciences, Faculty of Veterinary Science

University of Pretoria

Date submitted: October 2012

## **DEDICATION**

This work is dedicated to my family.

My parents, Fritz and Hildegard, who provided the example and set the foundations for a lifelong scientific quest for knowledge.

My wife, Philippa, who gave her unwavering support, love and understanding.

My sons, Carl, Richard and Nicholaus, whose keen interest and help allowed me to set the example for their respective academic achievements as budding scientists.

I thank you for the love, support and encouragement you gave me.



The confluence of the Olifants and lower Letaba rivers at the entrance to the Olifants Gorge in the Kruger National Park. Both rivers in full flood in January 2011.

## ACKNOWLEDGEMENTS

I would like to express my gratitude to Mr D.J. Pienaar and Dr D. Govender of SANParks for organising the fieldwork and project registration with SANParks. The following persons are acknowledged for their contribution to the field data collection: Drs D. Govender, J.G. Myburgh, J.C.A. Steyl, A.R. Deacon, Messrs D.J. Pienaar and J. Müller. The SANParks regional ranger responsible for the Olifants Gorge, Mr L. Olivier is acknowledged for facilitating access to the river and the use of field camping sites. Section rangers Messrs E. Makansi and D. Mobasa are thanked for provision of security. Mss N. Maseko, P. Shikwambana and N. Tyaqana, and Mr K. Deenadayalan of SANParks and Mr D. Booysse of the Faculty of Veterinary Science, University of Pretoria, are thanked for field laboratory technical assistance. The assistance of SANParks rangers and various fishermen with catching and transport of fish is gratefully acknowledged. Mr J. Venter of SANParks and Mr T. Mohlala of the South African Environmental Observation Network are thanked for capture and transportation of fish. Prof H. Bouwman and student helpers, from the University of Northwest, are acknowledged for assistance with sample transport. Colonel R. Dixon and the SAP Forensics Laboratory are thanked for assistance with sample collection and facilitation of analyses.

My sons, students C., R. and N. Huchzermeyer, are thanked for their indispensable help with the logistics of field work, catching and dissecting of fish, and for assisting during the laparotomy procedures. Messrs H. Kgoete and E. Sithole are thanked for assisting with the handling of fish and Mr Sithole for the daily maintenance of the recirculated facility. Acknowledgement is given to my staff at Sterkspruit Veterinary Clinic for logistical support. Dr P.A. Colly is thanked for logistical and financial support and for proof reading of manuscripts. Messrs G., R., and S. van der Merwe of Lunsklip Fisheries are gratefully acknowledged for the supply of positive control fish and for making pancreatitis-affected fish available for the trial.

Mr J. Müller and IDEXX Laboratories are thanked for their generous help with field laboratory services and blood chemistry determinations and Ampath Laboratories for  $\alpha$ -tocopherol determinations. Profs G. Osthoff and A. Hugo from the University of the Free State are thanked for analysis of fatty acid composition and Mr S. Woodborne of the CSIR for stable-isotope mapping of the food web in the Olifants Gorge. Dr R. Du Plessis and Ampath Pathologists Nelspruit are thanked for the initial histological sectioning. My gratitude

is expressed to Prof H. Kaiser of Rhodes University for assistance with statistical analysis of data. Mr M. Lotter is thanked for preparing the map of the sampling sites.

From the Department of Paraclinical Sciences at the Faculty of Veterinary Science, University of Pretoria, Dr J.C.A. Steyl and the staff of the histopathology laboratory are gratefully acknowledged for preparation of histological sections. Prof J.A. Lawrence and Dr Steyl are thanked for comments on histological interpretations. My sincere gratitude is expressed to Prof Lawrence for his editorial and scientific comments, and the proof reading of manuscripts before submission for publication, and in particular for his detailed proof reading of and advice on the final thesis manuscript.

The field study and sediment trial were approved by the respective Research and Animal Use and Care Committees of the Faculty of Veterinary Science, University of Pretoria, Protocol V013/10, and SANParks. The trial on persistence of pansteatitis lesions was approved by the Animal Use and Care Committee of the University of Pretoria under project number V036-11. Funding received from the Water Research Commission (Consultancy Contract K8/948) covered the period 1<sup>st</sup> June 2010 to 31<sup>st</sup> July 2011. The Veterinary Foundation provided funding to cover the preparation of histological sections. IDEXX Laboratories covered the costs of the haematology and blood chemistry. The remainder of the project was funded through the author's private means.

## **DECLARATION**

This thesis is my own original work and has not been submitted in candidature for any other degree.

Candidate: K.D.A. Huchzermeyer

## TABLE OF CONTENTS

Dedication .....	ii
Acknowledgements .....	v
Declaration .....	vi
Summary .....	xi
List of tables.....	xiii
List of figures.....	xv
List of abbreviations.....	xxiii
CHAPTER ONE: INTRODUCTION .....	1
1.1. History and Background of the Study .....	1
1.1.1. The crocodile mortality events .....	1
1.1.2. Organisational response to the crocodile mortality .....	1
1.2. The Olifants River Catchment and Crocodile Mortalities .....	2
1.3. Justification for the study .....	5
1.4. Objective .....	6
CHAPTER TWO: LITERATURE REVIEW .....	7
2.1. Introduction .....	7
2.2. Pansteatitis .....	8
2.2.1. Pathology .....	8
2.2.2. Aetiology .....	10
2.3. Vitamin E .....	14
2.4. Oxidative Stress and <i>in vivo</i> Lipid Peroxidation .....	16
2.4.1. Free radical attack .....	16
2.4.2. Xenobiotics as pro-oxidants .....	17
2.5. Bio-monitoring .....	21
CHAPTER THREE: FIELD STUDY .....	24
3.1. Materials and Method .....	24
3.1.1. Introduction to the fieldwork .....	24
3.1.2. Description of the study area .....	24
3.1.3. Specimen collection .....	25
3.1.4. Sampling and fish dissections .....	26
3.1.5. Gross and histological examinations .....	28
3.1.6. Laboratory work .....	28
3.1.7. Statistical analysis .....	30

3.2.	Results .....	32
3.2.1.	Prevalence of pansteatitis .....	32
3.2.1.1.	Prevalence in free living catfish .....	32
3.2.1.2.	Stomach content relative to prevalence .....	38
3.2.1.3.	Prevalence in a captive farmed population of catfish .....	40
3.2.1.4.	Discussion of prevalence .....	41
3.2.2.	Pathology of pansteatitis in catfish .....	44
3.2.2.1.	Gross pathology of pansteatitis .....	44
3.2.2.2.	Histopathology of pansteatitis .....	56
3.2.2.2.1.	Histopathology of the adipose tissues .....	56
3.2.2.2.2.	Histopathology of other organs .....	63
3.2.2.3.	Statistical analysis .....	70
3.2.2.4.	Discussion of descriptive pathology .....	76
3.2.3.	Haematology and blood chemistry in pansteatitis in catfish .....	81
3.2.3.1.	Blood smear examinations .....	81
3.2.3.2.	Haematocrit .....	82
3.2.3.3.	Blood haemoglobin .....	84
3.2.3.4.	Serum vitamin E .....	85
3.2.3.5.	Blood glutathione peroxidase .....	87
3.2.3.6.	Discussion of haematology and blood chemistry .....	88
3.2.4.	Pathology in other fish species .....	91
<b>CHAPTER FOUR: PERSISTENCE OF PANSTEATITIS AFTER REMOVAL</b>		
<b>OF THE INCITING DIETARY CAUSE .....</b>		
4.1.	Introduction .....	93
4.2.	Hypothesis .....	93
4.3.	Objective .....	93
4.4.	Materials and Method .....	94
4.4.1.	Experimental design .....	94
4.4.2.	Experimental facility .....	94
4.4.3.	Experimental animal procedures .....	95
4.5.	Results .....	98
4.6.	Discussion .....	108
4.7.	Conclusion .....	110

CHAPTER FIVE: EXPOSURE OF FISH TO SEDIMENTS FROM SITES WHERE PANSTEATITIS HAS OCCURRED .....	111
5.1. Introduction .....	111
5.2. Objective .....	112
5.3. Materials and Method .....	112
5.4. Results .....	114
5.5. Discussion .....	117
CHAPTER SIX: GENERAL DISCUSSION .....	119
6.1. Introduction .....	119
6.2. Prevalence of Pansteatitis .....	120
6.3. Pathology .....	123
6.4. Haematology, Blood Chemistry and Bio-monitoring .....	125
6.5. Xenobiotics as Possible Cause of Pansteatitis .....	126
6.6. Dietary Change and Pansteatitis in the KNP .....	130
6.7. Pansteatitis in Catfish and the Crocodile Mortality .....	134
6.8. Conclusion and Recommendations .....	137
REFERENCES .....	140
APPENDIX: Pansteatitis research publications of which the candidate was either the main author or co-author	
Appendix A. Publications	
Appendix A.1.	Huchzermeyer K.D.A., Govender D., Pienaar D.J., Deacon A.R. (2011) Steatitis in wild sharptooth catfish, <i>Clarias gariepinus</i> (Burchell), in the Olifants and Lower Letaba Rivers in the Kruger National Park, South Africa. <i>Journal of Fish Diseases</i> <b>34</b> , 489-498.
Appendix A.2.	Huchzermeyer K.D.A. (2012) Prevalence of pansteatitis in African sharptooth catfish, <i>Clarias gariepinus</i> (Burchell), in the Kruger National Park, South Africa. <i>Journal of the South African Veterinary Association</i> 83(1) Art.#916,9 pages. <a href="http://dx.doi.org/10.4102/jsava.v83i1.916">http://dx.doi.org/10.4102/jsava.v83i1.916</a> .
Appendix A.3.	Woodborne S., Huchzermeyer K.D.A., Govender D., Pienaar D.J., Hall G., Myburgh J.G., Deacon A.R., Venter J., Lübker N. (2012) Ecosystem change and the Olifants River crocodile mass mortality events. <i>Ecosphere</i> <b>3(10)</b> , 1-17.



Appendix A.4. Huchzermeyer K.D.A., Osthoff G., Hugo A., Govender D. (in press)  
Comparison of the lipid properties of healthy and pansteatitis-affected  
African sharptooth catfish, *Clarias gariepinus* (Burchell), and the role  
of diet in pansteatitis outbreaks in the Olifants River in the Kruger  
National Park, South Africa. Accepted for publication 24<sup>th</sup> August  
2012 *Journal of Fish Diseases*.

Appendix B. Reports

Appendix B.1. Huchzermeyer KDA 2012 A preliminary study to identify pathology  
present in fish in the lower Olifants River following a large crocodile  
mortality event. Water Research Commission WRC Report No. KV  
299/12 August 2012

## SUMMARY

### PANSTEATITIS IN AFRICAN SHARPTOOTH CATFISH, *CLARIAS GARIEPINUS* (BURCHELL), IN THE KRUGER NATIONAL PARK, SOUTH AFRICA

by

KARL DAVID AUGUST HUCHZERMAYER

Promoter: Professor J.A. Lawrence

Department: Section of Pathology, Department of Paraclinical Sciences, Faculty of  
Veterinary Science, University of Pretoria

Co-promoter: Doctor J.G. Myburgh

Department: Section of Pharmacology and Toxicology, Department of Paraclinical  
Sciences, Faculty of Veterinary Science, University of Pretoria

Co-promoter: Doctor J.C.A. Steyl

Department: Section of Pathology, Department of Paraclinical Sciences, Faculty of  
Veterinary Science, University of Pretoria

Degree: PhD

In the Kruger National Park (KNP), pansteatitis in sharptooth catfish, *Clarias gariepinus* (Burchell), was shown to be a serious problem in the inlets to large man-made lakes fed by rivers arising in the polluted catchments of the Olifants and Sabie rivers. An increasing prevalence of pansteatitis was recorded in catfish from the Olifants River gorge. A low prevalence was found in catfish upstream of the gorge at two further sites. No pansteatitis was detected in catfish from a rain-filled dam distant from the potential pollution sources affecting the Olifants River and in rivers arising outside of the park that were not dammed. Analysis of stomach content indicated a higher prevalence of fish in the diet of catfish affected by pansteatitis than in those not affected. Significant pathology in catfish was limited to changes associated with a generalised necrosis and inflammation of adipose tissues (pansteatitis), and there was evidence that lesions accumulated over time. Similar pathology was found in a captive population of catfish with known nutritional pansteatitis. Pathology in other organs that might have been attributed to pollution could not be demonstrated. Examination of blood smears and measurement of haematocrit, blood haemoglobin, serum vitamin E and erythrocyte glutathione peroxidase values did not prove useful as monitoring tools, probably because of the episodic exposure to oxidative stress and the chronic nature of the condition. Pansteatitis-affected catfish, kept in an experimental pond for 11 months after

the inciting nutritional cause had been removed, retained steatitis lesions almost unaltered. Whereas lipolysis appeared to be reduced by pansteatitis, adipogenesis appeared to be unaffected. Juvenile catfish confined in experimental tanks with sediments from sites where pansteatitis occurred remained healthy, and no pathology developed after 14 months, suggesting that sediments were not directly toxic.

The results of the study present the first record of pansteatitis in both wild and farmed African sharptooth catfish and emphasize the ecological importance and complexity of nutritional oxidative stress in a disturbed aquatic environment. Nutrient entrapment and the consumption of phytoplankton-feeding fish rich in polyunsaturated fats, particularly silver carp, *Hypophthalmichthys molitrix* (Valenciennes), a species alien to Africa but present in the Olifants River, is proposed as the dietary cause of the pansteatitis.

## LIST OF TABLES

<b>Table 3.1:</b>	Prevalence of macroscopically detectable pansteatitis lesions in the Olifants Gorge and other reference populations of catfish in and around KNP	34
<b>Table 3.2:</b>	Mesenteric adipose tissue mass relative to body mass of catfish sampled from the Olifants Gorge and other sites on various dates. Olifants Gorge (OG), Engelhard Dam (EH), Mamba Weir (M), Reënvoël Dam (RV), van Ryssen Dam (FK), Levuvhu River (LUV) and Crocodile River (CR)	36
<b>Table 3.3:</b>	Prevalence of macroscopically detectable pansteatitis lesions in catfish sampled from a captive population at Lunsklip Fisheries (LK)	41
<b>Table 3.4:</b>	Mesenteric adipose tissue mass relative to body mass of catfish sampled from Lunsklip Fisheries (LK)	41
<b>Table 3.5:</b>	The staining properties of macrophages in various tissues of catfish with pansteatitis sampled from the Olifants Gorge in November 2009 (OG). Perl's Prussian blue. Staining intensity on a scale of 1 to 5 expressed as mean of the sample size n	69
<b>Table 3.6:</b>	Perl's Prussian blue staining properties of hepatocytes and renal tubular epithelial cells in catfish with pansteatitis sampled from the Olifants Gorge in November 2009 (OG). Perl's Prussian blue. Staining intensity on a scale of 1 to 5 expressed as mean of the sample size n	69
<b>Table 3.7:</b>	Comparison of percentage polychromatocytes in blood smears collected from catfish at three sampling sites during November 2009 (*standard deviation)	82
<b>Table 3.8:</b>	Mean haematocrit values (packed cell volume=PCV) of blood collected from catfish from all sites (Olifants Gorge=GL, OGM, OG, OL, LOG, LOC; Lunsklip Fisheries=LK; Reënvoël Dam=RVB; Engelhard Dam=EH; van Ryssen Dam=FK; Mamba Weir=M; Levuvhu River=LUV; Crocodile River=CR) (*standard deviation)	83
<b>Table 3.9:</b>	Mean blood haemoglobin concentrations (g/dl) of blood collected	

	from catfish from all sites (Olifants Gorge=GL, OGM, OG, OL, LOG, LOC; Lunsklip Fisheries=LK; Reënvoël Dam=RV, RVB; Engelhard Dam=EH; van Ryssen Dam=FK; Mamba Weir=M; Levuvhu River=LUV; Crocodile River=CR)(*standard deviation)	84
<b>Table 3.10:</b>	Mean serum vitamin E values of catfish from all sites (Olifants Gorge=OGM, OG, OL; Lunsklip Fisheries=LK; Reënvoël Dam=RV; Engelhard Dam=EH; Mamba Weir=M) (*standard deviation)	86
<b>Table 3.11:</b>	Percentage of catfish from the Olifants Gorge and other sites with serum vitamin E levels below the lower fifth percentile of values of healthy fish sampled from Reënvoël Dam. (Olifants Gorge=OGM, OG, OL; Lunsklip Fisheries=LK; Reënvoël Dam=RV; Engelhard Dam=EH; Mamba Weir=M)	87
<b>Table 4.1:</b>	Measurements of test fish at the start of the trial	99
<b>Table 4.2:</b>	Measurements of surviving test fish at the end of the trial	99
<b>Table 4.3:</b>	Measurements of control fish at the start of the trial	100
<b>Table 4.4:</b>	Measurements of control fish at the end of the trial	100
<b>Table 5.1:</b>	Respective experimental tank and sediment volumes used for the bio-assay trial	113
<b>Table 5.2:</b>	Measurements of surviving catfish at the end of the 14 month trial period (OGST1-OGST4=Olifants Gorge sediment; SST1-SST12= Sabiepoort sediment; BST1-BST7=Bangu sediment)	116

## LIST OF FIGURES

<b>Figure 2.1:</b>	Schematic presentation of the effect of redox cycling of a pro-oxidant on polyunsaturated lipids. Proposed mechanism of paraquat toxicity (from Bus <i>et al.</i> 1976) [GSH=glutathione].	20
<b>Figure 3.1a:</b>	Example of growth rings in the otolith of a 19 year old catfish from the Olifants Gorge.	29
<b>Figure 3.1b:</b>	Example of growth rings in the otolith of a 4 year old catfish from the Olifants Gorge.	29
<b>Figure 3.2:</b>	Macroscopic pansteatitis prevalence as percentage of sampled catfish from various sampling sites in the Kruger National Park during the period 2009-2011.	33
<b>Figure 3.3:</b>	Prevalence of pansteatitis in catfish sampled from various localities along the Olifants and lower Letaba rivers in the Kruger National Park from 2009 to 2011 (Correlation coefficient: $r = 0.87$ , significance: $p = 0.02$ ).	35
<b>Figure 3.4:</b>	Box and whisker plot showing variation in age between catfish with and without pansteatitis sampled from all Olifants Gorge sites (1 denotes fish with pansteatitis incidence, 0 denotes fish without pansteatitis).	37
<b>Figure 3.5:</b>	Box and whisker plot showing variation in body mass between catfish with and without pansteatitis sampled from all Olifants Gorge sites (1 denotes fish with pansteatitis incidence, 0 denotes fish without pansteatitis).	37
<b>Figure 3.6:</b>	Box and whisker plot showing variation in body length between catfish with and without pansteatitis sampled from all Olifants Gorge sites (1 denotes fish with pansteatitis incidence, 0 denotes fish without pansteatitis).	38

- Figure 3.7:** Stomach content analysis of sharptooth catfish showing that the population with pansteatitis (Pan++) at a site where pansteatitis was prevalent had stomach contents with a higher proportion of fish than vegetation, or invertebrates and detritus (mixed) when compared with the population of fish that did not have pansteatitis (Pan+-) from areas that had pansteatitis prevalence, and the population from areas without pansteatitis prevalence (Pan-). (Triplot preparation courtesy of S. Woodborne, Centre for Scientific and Industrial Research, Pretoria). 39
- Figure 3.8a:** Early steatitis lesions in catfish sampled from the Olifants Gorge during July 2010. Note the small sharply circumscribed foci of fat cell necrosis and associated ceroid deposition imparting the characteristic brown colour (arrow). 45
- Figure 3.8b:** Cross-section of mesenteric fat with advanced pansteatitis from a catfish sampled from the Engelhard Dam during July 2010. Note the diffuse brown granular appearance of the fat, the rough surface and virtually total absence of normal appearing fat. 45
- Figure 3.8c:** Cross section of mesenteric adipose tissue from a catfish collected from the Olifants Gorge in November 2009 showing typical severe pansteatitis. Note brown granuloma formation within the adipose tissue. 46
- Figure 3.9:** Pansteatitis of the mesenteric adipose tissues in a catfish sampled from the Olifants Gorge during June 2011. Note that the caudal portion of the mesenteric fat body appears more severely affected. 46
- Figure 3.10a:** Focal steatitis (arrows) in the pectoral fat of a catfish sampled from the Olifants Gorge during July 2010. 47
- Figure 3.10b:** Focal steatitis (arrows) in the intermuscular fat of a catfish sampled from the Olifants Gorge during July 2010. 47
- Figure 3.10c:** Focal areas of steatitis (arrows) in the intermuscular fat of a catfish sampled from Lunsklip Fisheries during November 2009. 48
- Figure 3.10d:** Generalised steatitis in the fat surrounding the brain of a catfish sampled from the Olifants Gorge during July 2010. Note brown discolouration of fat (arrow) adhering to the opened cranium. 48

- Figure 3.11:** Melanin deposition (black arrow) associated with digenean trematode cysts (block arrows) in the caudal mesenteric fat between the male accessory sexual glands of a catfish sampled from Reënvoël Dam in KNP. 50
- Figure 3.12:** Melanin deposition (arrows) in the vicinity of larval nematodes in the mesentery overlying the mesenteric fat in a catfish sampled from van Ryssen Dam. 50
- Figure 3.13:** Gill arch of catfish sampled from the Olifants Gorge during November 2009 showing severe infestation of the cartilage of the primary gill lamellae by encysted digenean trematode metacercariae. 51
- Figure 3.14a:** Swollen fatty liver of a catfish suffering from pansteatitis, sampled from the Olifants Gorge during June 2011. 52
- Figure 3.14b:** Focal fat deposits beneath the liver capsule from a catfish with pansteatitis sampled from Lunsklip Fisheries during November 2009. 52
- Figure 3.14c:** Position of the external lobes of the liver (L) and cranial kidney (K) beneath the pectoral fat cushion caudoventral to the caudal margin of the skull of sharptooth catfish. Note the focal fat deposits visible on the surface of the liver in this catfish sampled from the Olifants Gorge. Arrows point to encysted digenean trematode larvae in the musculature. 53
- Figure 3.14d:** Liver from a catfish sampled from Reënvoël Dam during November 2009. Arrows show damage associated with parasitic cysts in the liver parenchyma. 53
- Figure 3.14e:** Outgrowth of regenerating hepatic tissue (arrow), probably associated with parasitism, in a liver from a catfish sampled from Reënvoël Dam during November 2009. Note the normal brown colour of the liver. 54
- Figure 3.15a:** Enlarged spleen of a catfish from the Olifants Gorge suffering from pansteatitis. 54
- Figure 3.15b:** Spleen of a catfish from Lunsklip Fisheries suffering from severe chronic pansteatitis showing prominent capsular thickening and splenomegaly. Note the rounded appearance of the normally flat spleen. 55



- Figure 3.16a:** Giant cell formation (arrows) in a steatitis lesion in adipose tissue from a catfish sampled from the Olifants Gorge in July 2009. Giant cells (gc), lipopigment (lp), adipocytes (fc) (H&E X100). 56
- Figure 3.16b:** Positive staining ceroid pigment (purple) within the lipopigment remnants (lp) of ruptured adipocytes and macrophages (m) in mesenteric fat of a catfish sampled from the Olifants Gorge during November 2009. Adipocytes (fc) (GAF). 57
- Figure 3.16c:** Advanced stage of fat necrosis and steatitis in mesenteric fat of a catfish sampled from the Olifants Gorge during June 2011. Note the apparently empty lacunae (l) where necrotic remnants of oxidised fat (lp) have been lost during processing, surrounded by a macrophage sheath. Adipocytes (a), foreign body giant cells (arrow) (H&E). 58
- Figure 3.16d:** Atrophied mesenteric adipose tissue showing inflammation typical of steatitis in a catfish sampled from the Olifants Gorge during June 2011. Note small size of adipocytes (fc) and aggregates of macrophages (m) containing ceroid, surrounding areas of fat necrosis containing lipopigment (lp) (H&E). 59
- Figure 3.17a:** Section of pectoral fat from a catfish sampled from the Olifants Gorge in June 2011 showing extensive extracellular ceroid-type lipopigment (lp) surrounded by connective tissue (ct) and macrophages (m). Adipocytes (fc) (H&E). 60
- Figure 3.17b:** Lipopigment-containing macrophages associated with steatitis in the fat surrounding the brain of a catfish sampled from the Olifants Gorge during June 2011. Focus of mixed inflammatory cells (arrow), macrophages (M), adipocytes (FC) (H&E). 60
- Figure 3.18a:** Granuloma caused by migrating larval nematodes (arrow) in the hypodermal fat of a catfish sampled from the Olifants Gorge. Adipocytes (FC) (H&E). 61
- Figure 3.18b:** Granuloma formation in the mesenteric fat of a sharptooth catfish associated with larval nematodes (arrows) sampled from Reënvoël Dam. Note, in this case, the extensive melanomacrophage reaction (MM), but absence of lipopigment (H&E). 62

- Figure 3.18c:** Large encysted nematode larva (arrow) in the mesenteric fat attached to the pancreas (P) of a catfish sampled from van Ryssen Dam (H&E). 62
- Figure 3.19a:** Liver section of a catfish sampled from the Olifants Gorge during November 2009. Note distinct focus of fat vacuoles (f) (H&E, X200). 64
- Figure 3.19b:** Liver section of a catfish sampled from the Olifants Gorge during November 2009. Note distinct focus of fat vacuoles (f) and clustering of haemosiderin (arrows) on the perimeter of this focus (Perl's Prussian blue, X200). 64
- Figure 3.20:** Granuloma in the liver of a catfish sampled from the Levuvhu River containing larval nematodes (arrows). Note amorphous tissue debris within the cyst adjacent to the parasites. Melanomacrophage centre (MM) (H&E). 65
- Figure 3.21:** Pancreatic atrophy in a catfish suffering from pansteatitis, sampled from the Olifants Gorge during June 2011. Note prominence of connective tissue (ct) extending between groups of acinar cells (a). Islet of Langerhans (iL) (H&E). 65
- Figure 3.22a:** Digenean trematode larva encysted within the cartilage of the primary lamellae of a catfish sampled from the Olifants Gorge during June 2011. Note hyperplastic changes in the cartilage (arrows) (H&E). 67
- Figure 3.22b:** Enlarged view of a digenean trematode, probably a metacercaria of *Centrocestus formosanus*, encysted in the gill cartilage (C) of a catfish from the Olifants Gorge. Note the ingested chondrocytes (arrows) (H&E). 68
- Figure 3.23:** Digenean trematodes of the family Diplostomidae (arrows) within the cerebrospinal space adjacent to fat lining the cranium of a catfish sampled from Engelhard Dam during July 2010. Note the cellular reaction associated with presence of these parasites (H&E). 68

- Figure 3.24:** Comparison of steatitis severity in mesenteric fat of catfish sampled from LK (positive reference site), Test (all OG sites) and Ref (RV and RVB negative reference sites). Fmst=steatitis severity in mesenteric fat on a scale of 1 to 5 with 1 representing severe steatitis and 5 representing absence of steatitis. 70
- Figure 3.25:** Comparison of hepatic lipidosis incidence between LK (positive reference site), Test (all OG sites) and Ref (RV & RVB negative reference site). Lipid=hepatic lipidosis on a scale of 1 to 5 with 1 representing severe lipidosis and 5 representing absence of lipidosis. 71
- Figure 3.26:** Comparison of level of pigment (haemosiderin and ceroid) stored by hepatocytes between LK (positive reference site), Test (all OG sites) and Ref (RV and RVB negative reference site). Haemos=hepatocyte pigment on a scale of 1 to 5 with 1 representing severe accumulation and 5 representing absence of pigment. 72
- Figure 3.27:** Comparison of metabolic activity of hepatocytes of catfish between LK (positive reference site), Test (all OG sites) and Ref (RV and RVB negative reference site). Met act=metabolic activity on a scale of 1 to 5 with 1 representing compact inactive hepatocytes and 5 representing distended vacuolated hepatocytes. 73
- Figure 3.28:** Comparison of structural disorder in the liver of catfish between LK (positive reference site), Test (all OG sites) and Ref (RV and RVB negative reference site). Arch=structural disorder on a scale of 1 to 5 with 1 representing a severe degree of disorder and 5 representing normal hepatic structure. 74
- Figure 3.29:** Comparison of vacuolated foci in the liver of catfish between LK (positive reference site), Test (all OG sites) and Ref (RV and RVB negative reference site). Vacf=presence of vacuolated foci on a scale of 1 to 5 with 1 representing numerous foci and 5 representing absence of foci. 75

- Figure 3.30:** Comparison of melanomacrophage centre intensity in the liver of catfish between LK (positive reference site), Test (all OG sites) and Ref (RV and RVB negative reference sites).  
Lmm=melanomacrophage intensity on a scale of 1 to 5 with 1 representing numerous melanomacrophage centres and 5 representing absence of melanomacrophage centres. 76
- Figure 3.31:** Comparison of mean haematocrit (PCV%) from catfish sampled from Lunsklip Fisheries (n 21) and the Olifants Gorge (n 20) during November 2009 (p=0.016, vertical bars denote +/- standard errors). 83
- Figure 3.32:** Comparison of mean blood haemoglobin concentrations (g/dl) of catfish sampled during November 2009. LK=Lunsklip Fisheries (n 21), OG=Olifants Gorge (n 20) and RV= Reënvoël Dam (n 14). (p=0.021, vertical bars denote +/- standard errors). 85
- Figure 3.33:** Comparison of mean serum vitamin E values (mg/l) of catfish sampled during November 2009. LK=Lunsklip Fisheries (n 20), OG=Olifants Gorge (n 15), and RV= Reënvoël Dam (n 15). (p<0.001, vertical bars denote +/- standard errors). 86
- Figure 3.34:** Mean glutathione peroxidase (GSH-Px) values ( $\mu$ U/mgHb) of catfish with and without pansteatitis sampled from all sampling sites. 88
- Figure 4.1:** Laparotomy incision along the ventral midline of the abdomen of a test fish with mesenteric fat protruding from the incision. 96
- Figure 4.2:** Incision through skin, linea alba and parietal peritoneum of a catfish to access the underlying mesenteric fat (MF). Note severe steatitis of the mesenteric fat evidenced by the grey-brown colour and presence of granulomata visible beneath the surface of the fat. 96
- Figure 4.3:** Removal of a fat biopsy through a ventral midline abdominal incision in a test fish. Note the obvious signs of steatitis in the fat biopsy. 97
- Figure 4.4a:** Male test fish showing the scar of the laparotomy incision in the ventral abdominal skin, at the end of the 11 month trial period. This fish had rejected all of the original nylon sutures. 102

- Figure 4.4b:** Laparotomy scar in the abdominal skin of a test fish after the 11 month trial period showing good healing despite retention of 2 nylon sutures. 103
- Figure 4.5:** Surface of mesenteric fat body of a test fish after the 11 month trial period showing minimal scar formation where the biopsy had been taken (arrow). 104
- Figure 4.6a:** Cross section from the edge of mesenteric fat of a test fish at the end of the 11 month trial period showing distinct yellow and brown granulomata and smaller brown spots dispersed throughout the fat. 104
- Figure 4.6b:** Cross section of mesenteric fat body retained after the 11 month trial period. Note more recently deposited white fat on the surface of the fat body, whereas the bulk of the fat body shows intense granulomata formation imparting the brown colour. 105
- Figure 4.7:** Mesenteric fat of a test fish that died 23 days after the start of the trial. Note the severely affected older fat (OF) deposited in the mesentery closest to the kidney (K) that has taken on a diffuse brown colour due to the intensity of small granulomata in the fat, and the white more recently deposited fat (NF). 106
- Figure 4.8:** Ventro-dorsal view of the abdominal cavity of a dissected test fish at the end of the 11 month trial. Note the large amount of mesenteric fat (MF). Recently deposited white fat (arrow) can be observed in the mesentery caudal to the liver (L). Also note the large rounded spleen (S). Stomach (ST). 106
- Figure 4.9:** Steatitis of the intermuscular fat in the region of the pterygiophores of a test fish at the end of the 11 month trial period. Note focally disseminated small brown spots in the adipose tissue (arrow). 107
- Figure 5.1:** Silt deposits in the Olifants Gorge at the inlet to Lake Massingir on the South African-Mozambique border in KNP. 112

## LIST OF ABBREVIATIONS

CR	Crocodile River
CROC	Consortium for the Restoration of the Olifants Catchment
DHA	docosahexaenoic acid C22:6n-3
ECC	extracellular ceroid
EH	Engelhard Dam sampling site, July 2010
EPA	eicosapentaenoic acid C20:5n-3
FK	van Ryssen Dam
GAF	Gomoris aldehyde fuchsin
GL	Olifants Gorge*
GPx	glutathione peroxidase
GSH	glutathione
H&E	haematoxylin and eosin
LK	Lunsklip Fisheries
KNP	Kruger National Park
LUV	Levuvhu River
M	Mamba Weir
MDA	malondialdehyde
MFO	mixed function oxygenases
OG	Olifants Gorge*
OGM	Olifants Gorge Mozambique border
OL	Olifants Gorge*
LOC	Olifants Gorge*
LOG	Olifants Gorge*
PAS	Periodic acid Schiff's
PCV	packed cell volume
SAP	South African Police



SOD	Superoxide dismutase
SP	Sabiepoort sampling site
ROS	reactive oxygen species
RV	Reënvoël Dam*
RVB	Reënvoël Dam*
SANParks	South African National Parks
TBARS	thiobarbituric acid reactive substances

(\*denotes codes used relating to the same sampling sites at different times)

## CHAPTER ONE: INTRODUCTION

### 1.1. History and Background of the Study

#### 1.1.1 The crocodile mortality events

The Olifants River Gorge and Lower Letaba River, at the confluence with the Olifants River, in the Kruger National Park (KNP), are home to one of the densest populations of large Nile crocodile, *Crocodylus niloticus* Laurenti, in South Africa. During 2007, the rising level of Lake Massingir, in Mozambique, flooded many of the rapids and pools in the Olifants Gorge. Altered hydrodynamics have resulted in the deposition of clay-rich sediments within the aquatic habitat of the area. During the autumn and winter of 2008 and 2009, large numbers of adult crocodiles were found dead in this area. Some 180 specimens out of a known population of at least 600 were found dead in 2008 alone. Autopsies performed by KNP veterinarians revealed exceptionally fat carcasses with an abnormal hardening of the fat. Histological examination of tissue specimens by Drs E. Lane (National Zoological Gardens, Pretoria, South Africa), J. Steyl and F.W. Huchzermeyer (Faculty of Veterinary Science, University of Pretoria, Onderstepoort, South Africa) confirmed an inflammation of the fat typical of pansteatitis.

#### 1.1.2 Organisational response to the crocodile mortality

In response to the crocodile deaths in 2008, the Consortium for the Restoration of the Olifants Catchment (CROC) was founded as a multidisciplinary initiative. CROC provides the following preamble: "*Crocodile catastrophe – implications for mankind*

- *It is increasingly clear that the crocodile deaths in the Olifants Basin are symptomatic of a serious and growing environmental problem in which a tipping point has been reached /crossed with dramatic unexpected effects.*
- *Such a top predator collapse indicates prolonged and cumulative ecosystem stress caused by human activities in which the implementation of our legislated environmental controls and monitoring response proved inadequate.*
- *There are serious implications for human health and well-being if the situation continues and river health is not restored."*

A collaborative team effort was initiated, including KNP researchers, various universities, government departments and private sector consultants, to investigate various



aspects, including fish pathology, that may have played a role leading to the development of pansteatitis in the crocodiles.

A fish survey in the Olifants Gorge conducted by the author during August 2008, at the request of South African National Parks (SANParks), indicated that some sharptooth catfish, *Clarias gariepinus* (Burchell), carried large stores of fat that appeared to be affected by steatitis. Other fish species appeared to be healthy. The author subsequently confirmed pansteatitis in these catfish by histological examination of affected adipose tissues. This finding by the author formed the basis for the research that led to this PhD study. As catfish are known to form part of the diet of large crocodiles, the investigation was focussed on a study of the pathology in catfish inhabiting the Olifants Gorge. On 8 July 2009, for the first time, a large fish mortality event was observed within the Olifants Gorge. Affected fish were almost exclusively large sharptooth catfish and were found in the area overlying the clay-rich deposits at the point where the gorge widens into the dam. Fish carcasses were observed to be very fat. The fish kill remained localized in space and time, and no mortalities were observed in either the Olifants or Letaba rivers up-stream of the gorge, and fish in Lake Massingir appeared unaffected. Pansteatitis was confirmed by the author in live catfish sampled from the Olifants Gorge around this time by SANParks scientists.

It was assumed that pansteatitis in catfish and crocodiles in the Olifants Gorge was linked and associated with pollution. This study was based on the assumption that pollution-associated pathology in fish in the Olifants River in the KNP preceded the pansteatitis syndrome that caused the deaths of crocodiles during the winter of 2008 and that certain pathological indicators may be used to monitor the incidence of pansteatitis in catfish along the river. This information may indirectly reflect the risk that pansteatitis poses to crocodiles in the same section of the river.

## **1.2. The Olifants River Catchment and Crocodile Mortalities**

The Olifants River originates on the Highveld plateau of Mpumalanga Province in South Africa, then flows eastwards down the escarpment and traverses the KNP where it is joined by the Letaba River at the entrance to the Olifants Gorge. The gorge extends through the Lebombo mountains for approximately 9 km, exiting into Lake Massingir in Mozambique. From here the Olifants River continues through Mozambique before discharging into the Indian Ocean. The Olifants River is regarded as one of the most threatened aquatic

ecosystems in Mpumalanga Province of South Africa (Ashton 2010; de Villiers & Mkwelo 2009; Heath, Coleman & Engelbrecht 2010). Since large numbers of Nile crocodiles died from pansteatitis in the Olifants Gorge during 2008 (Ferreira & Pienaar 2011), a link has been sought to the consequences of human activity in the catchment of the Olifants and Letaba Rivers. The Olifants catchment has been heavily impacted by human activity including mining, coal-fired electricity generation, industrial and urban wastewater discharges, agricultural practices and water impoundments (Heath *et al.* 2010), whereas the Letaba catchment has been impacted by agriculture and human settlements. Lake Massingir sustains a considerable freshwater fishery.

Within the upper Olifants catchment lies Lake Loskop. Nile crocodile mortalities in this lake have coincided with periodic mass die-offs of fish since 2003 (Botha, van Hoven & Guillette 2011; Driescher 2007). During 2007, acid mine seepage was held responsible for a large scale fish mortality, and consumption of dead and rotting fish was found to be the most likely cause of the deaths of significant numbers of crocodiles and terrapins as a result of pansteatitis (J. Myburgh and co-workers, Faculty of Veterinary Science, University of Pretoria, pers. comm. 2009). Yellow discolouration of fat in Mozambique tilapia *Oreochromis mossambicus* (Peters) has been observed in Lake Loskop, and this change has been attributed to bioaccumulation of aluminium and iron via various species of phytoplankton on which these fish feed (Oberholster, Myburgh, Ashton, Coetzee & Botha 2011).

Between Lake Loskop and the KNP, the Olifants River has been dammed to form Lake Flag Boshielo. This lake maintains a healthy population of crocodiles, and fish mortalities are uncommon (A. Hoffman, Mpumalanga Parks Board, Marble Hall, pers. comm. 2012), indicating that mine pollution is not affecting this section of river. It has been proposed that the phytoplankton composition of this lake has been depleted by presence of silver carp, *Hypophthalmichthys molitrix* (Valenciennes) (Lübcker 2011), and is likely to differ from that of Lake Loskop.

The Massingir dam in Mozambique was constructed between 1972 and 1977 but the lake was never allowed to fill to capacity due to seepage from the dam wall. Rehabilitation of the dam and installation of the sluices was completed in late 2006. As a result the head-waters of Lake Massingir extended into and flooded parts of the Olifants Gorge in the KNP during the subsequent summer. This has brought about a drastic alteration of the aquatic habitat in the

Gorge. The sediment-rich burden of the Olifants River is now deposited annually in the Olifants Gorge where the flow of the river has been slowed by Lake Massingir. In the KNP, the deaths of crocodiles during the winter of 2008 (Ferreira & Pienaar 2011; Huchzermeyer, Govender, Pienaar & Deacon 2011), was thought to be linked to the altered habitat of the gorge in some way. However, no coincidental fish die-off was observed. The number of crocodile deaths has declined during the subsequent winters. Crocodile deaths in the Olifants Gorge continue to be restricted to the winter months, and, as with the 2008 crocodile mortalities, SANParks veterinarians established the cause of death as pansteatitis. Autopsies performed on some of the crocodiles revealed exceptionally fat carcasses with an abnormal hardening and yellow discolouration of the fat. Histological examination confirmed an inflammation of the fat typical of pansteatitis (E. Lane and co-workers, National Zoological Gardens, Pretoria & Faculty of Veterinary Science, University of Pretoria, pers. comm. 2008). Impaired movement, an inability to swim and eventual emaciation have been observed in surviving crocodiles in the Olifants Gorge. Apparently healthy crocodiles as well as those obviously affected were observed in the same area. Bioaccumulation of a pollutant was not confirmed in the crocodiles with pansteatitis, and the cause, though probably linked to pollution and hydrodynamic change, is unknown.

During periods of flooding the Olifants River carries large loads of silt. From time to time this is exacerbated when the Phalaborwa Barrage, on the Olifants River just west of the KNP, releases water to prevent debris build-up from damaging the sluice gates and to create space to accommodate the increased flow. Downstream, occasional fish kills have resulted from the oxygen depletion in the Olifants River caused by the high silt burden in the released water. During such episodes, in February 1999 and January 2004, a large number of silver carp were identified amongst the dead fish in the Olifants River within KNP, confirming the presence of this species during these months (J. Venter, SANParks, Skukuza, pers. comm. 2012).

Mamba Weir, on the Olifants River, lies just inside the western boundary of the KNP and this section of river differs from the Olifants Gorge in that the regular scouring, when the Phalaborwa barrage is opened, removes sediment build-up from the weir. Riparian vegetation along this section of the Olifants River includes sycamore fig trees, *Ficus sycomorus* L., which are absent on the steep banks of the Olifants Gorge. sycamore figs are a favoured food source for catfish.

A large phosphate mine is situated near the town of Phalaborwa (Ba-Phalaborwa Municipality) near the western entry point of the Olifants River into the KNP. For a number of years prior to 2004, and once in 2008, abnormally high phosphate levels were recorded in the Olifants River within the KNP (J. Venter, SANParks, Skukuza, pers. comm. 2012). These were ascribed to the discharge of tailings from the phosphate mine in Phalaborwa into the Selati River, a tributary of the Olifants River, and to municipal sewerage discharges from the town of Phalaborwa. This discharge was apparently discontinued after 2004 and, except during the winter of 2008, the measurement of phosphate levels in the Olifants River downstream in the KNP has shown acceptable limits (J. Venter, SANParks, Skukuza, pers. comm. 2012). Dissolved phosphate is often the limiting nutrient governing phytoplankton growth in fresh water. The high levels of phosphate reaching Lake Massingir may have been a significant stimulus for phytoplankton growth resulting in the blooms observed in 2008 (J. Myburgh, Faculty of Veterinary Science, University of Pretoria, pers. comm. 2008).

Implication of pollutants in the development of pansteatitis has potentially serious consequences. In the KNP the disease directly threatens biodiversity and the conservation of the Nile crocodile. The Olifants River serves as a source of drinking water and edible fish for communities living along its length, and both commercial and subsistence farmers rely on the river to irrigate crops and to supply water to livestock. Communities around Lake Massingir are dependent on the substantial inland fishery that has developed in this water body, and the impact of pollution from the industrial heartland of South Africa extending into Mozambique has international implications.

### **1.3. Justification for the study**

A study of pansteatitis in sharptooth catfish will provide information on this nutritional disease in the KNP which is important for the conservation of keystone aquatic species such as the Nile crocodile. Pansteatitis is seldom encountered in free ranging wild animals, and as fish form part of the natural crocodilian diet an association between pathology in fish, changes in the aquatic environment and development of pansteatitis in crocodiles may be shown to exist. Pansteatitis has not been described previously in African sharptooth catfish. The species is ubiquitous and widespread, occurring throughout the African continent. Significant inland fisheries depend on this species in Mozambique and in countries to the north of South Africa. In South Africa the aquaculture potential of this species has not been fully exploited, but in many African countries as well as in Europe it is an important

aquaculture species that is farmed both intensively and extensively. This study will add valuable information on the nutrition of farmed catfish.

Discovery of the relationship of mortality in catfish and crocodiles and the impact of pollution will enable authorities to take steps to better conserve aquatic ecosystems and to prevent pollution entering conservation areas. The demise of crocodiles in the KNP has raised serious concerns about biodiversity conservation downstream of heavily polluted areas in the catchments of rivers traversing the park. The close spatial proximity of the Olifants Gorge, where pansteatitis occurs in crocodiles and catfish, to the freshwater fishery in Lake Massingir raises potential health concerns for people consuming fish from this lake.

#### **1.4. Objective**

The objective of this project was to study pansteatitis in African sharptooth catfish in the Olifants Gorge, to compare this to pathology in catfish from other sites within and outside of the KNP, to try to establish the probable causes of the pansteatitis in the catfish, to establish the relationship to the crocodile mortality and to identify improved procedures for monitoring fish health in KNP.

## CHAPTER TWO: LITERATURE REVIEW

### 2.1. Introduction

A review of pertinent literature providing insight on the current knowledge of pancreatitis in various species of animal is provided in the first section of the review. From this review it is evident that pancreatitis, a nutritional disease, is the consequence of an oxidative stress process. The underlying biochemical and molecular process leading to the clinical picture of pancreatitis is the peroxidation of lipids within the adipose tissues of the animal. In situations of oxidative stress the antioxidant defences of an animal are overwhelmed by the release of reactive oxygen species, and the subsequent chain reactions causing damage to lipids, proteins and nucleic acids can result in a variety of pathologies. Polyunsaturated fat, consumed in large amounts by animals poorly adapted to such a diet, causes considerable oxidative stress, and this can lead to the development of pancreatitis. Lipid peroxidation may also be initiated by pro-oxidants other than polyunsaturated fats and may be the common pathogenic mechanism of numerous diseases, including certain neoplasias.

The second section of the review deals with the non-enzymatic metabolic role of vitamin E as an antioxidant and its protective role in biological membranes. Vitamin E is the major chain reaction-breaking antioxidant that protects tissues from the harmful effects of lipid peroxidation and the actions of other free radicals. High polyunsaturated fat intake can lead to higher vitamin E consumption in the liver and adipose tissues, and the ensuing hypovitaminosis E leaves these and other tissues vulnerable to oxidative attack. In many species pancreatitis is inextricably linked to vitamin E deficiency, either as a manifestation of the symptomatology of primary hypovitaminosis E or secondary to oxidative stress associated with lipid peroxidation.

In the third section of the review, the biochemical processes underlying oxidative stress and lipid peroxidation are explored. The roles of xenobiotics and particularly the effect of redox-cycling as an initiator of oxidative stress are discussed in the second part of this section. In the final section of the review the use of biomarkers in monitoring exposure to oxidative stress is examined, and applications and limitations of their use in field studies is discussed.

## 2.2. Pansteatitis

### 2.2.1. Pathology

The terms steatitis, necrotising steatitis, fat cell necrosis, generalised fat necrosis, pansteatitis and yellow fat disease have been used in the literature to describe a disease in animals resulting from necrosis of fat cells in one or more tissues. The term pansteatitis defines a generalised disorder of adipose tissues characterised by degeneration and necrosis of fat cells, inflammation and fibrosis, and accumulation of ceroid and lipopigment (Danse & Verschuren 1978a; de Bruijn, Veldhuis Kroeze & Sloet van Oldenruiterborgh-Oosterbaan 2006). The term steatosis is used to describe the underlying degeneration and necrosis of fat cells, whereas the term steatitis refers to the secondary inflammation and fibrosis that follow on fat cell breakdown (Danse & Verschuren 1978a). The characteristic yellow colour of steatitis-affected adipose tissues has led to the name yellow fat disease being used to describe the condition. In cats the disease has also been described as a sterile pigmentary panniculitis (Fytianou, Koutinas, Saridomichelakis, & Koutinas 2006). For consistency, where reference is made to the work of other authors the term pansteatitis will be used where the author describes the generalised disorder and the term steatitis will be used where non-generalised lesions of fat cell necrosis are described.

The necrosis and inflammation in the adipose tissues results in a hardening of the affected tissue that, depending on whether in a subcutaneous or visceral location, may be palpable in some species (de Bruijn *et al.* 2006; Niza, Vilela & Ferreira 2003). In young horses the lesions may be extensive and consist of multinodular, focally haemorrhagic hard swellings of the adipose tissues with yellow-brown discolouration and an opaque appearance (de Bruijn *et al.* 2006). The pathology of steatitis has been reported in the literature for various species of fish (Begg, Bruno & McVicar 2000; Goodwin 2006; Helder 1979; Herman & Kircheis 1985; Roberts & Agius 2008; Roberts, Richards & Bullock 1979) and in these species is similar to that of warm blooded animals. In rainbow trout, *Oncorhynchus mykiss* (Walbaum), myopathy and anaemia have been described with both pansteatitis (Roberts *et al.* 1979) and vitamin E deficiency (Cowey, Degener, Tacon, Youngson & Bell 1984). Histological lesions of steatitis include severe degeneration and necrosis of fat cells. Macrophages and syncytial giant cells surround the necrotic fat cells and are often laden with pale brown lipopigment globules (Begget *al.* 2000; de Bruijn *et al.* 2006). Affected tissues may be variably infiltrated by other leucocytes, including neutrophils, and in advanced stages in the horse, dystrophic calcification may occur (de Bruijn *et al.* 2006). In fish, the lesions of steatitis are



characterised by an inflammatory reaction dominated by macrophages progressing to epithelioid granulation tissue with fibrous connective tissue infiltration resulting in granuloma formation (Begg *et al.* 2000; Herman & Kircheis 1985).

Lipid peroxidation induces inflammation in the following way. Oxidative deterioration of polyunsaturated lipids, through the release of free radicals, initiates a sequence of events that lead to molecular damage of subcellular membranes and eventually to cell membrane damage and necrosis (Tappel 1973). Fish fats are more susceptible to autoxidation than other polyunsaturated fats due to their high content of long-chain polyunsaturated fatty acids, particularly eicosapentaenoic acid [C20:5(n-3)] (EPA) and docosahexaenoic acid [C22:6(n-3)] (DHA) (Gonzalez, Schemmel, Dugan & Welsch 1992). The extracellular lipopigment (ceroid) released during fat cell necrosis accumulates and persists in areas of fat affected by steatitis and acts as an irritant evoking a foreign body-type inflammatory reaction. This is typified histologically by presence of Langhans giant cells, macrophages and other leukocytes (Ginn, Mansell & Rakich 2007). Danse and Verschuren (1978b) found that in steatitis-affected adipose tissues of rats, the associated damage to fat cell membranes resulted in reduced activation of lipase. The reduction in lipolysis in severely affected fat tissues renders these fat stores unavailable as a source of energy to the animal. This may explain the body weight loss and cachexia in the absence of fat atrophy associated with poor appetite seen in some species suffering from yellow fat disease.

In warm blooded animals, the disease is often painful and may lead to fever and malaise (de Bruijn *et al.* 2006; Ginn *et al.* 2007; Niza, *et al.* 2003). In cats, symptoms of fever and malaise arise after several weeks of feeding unsuitable fish-based diets (Ginn *et al.* 2007; Niza *et al.* 2003). Early cases can be treated by correcting the diet, giving oral vitamin E supplementation at 25 to 75 IU twice daily and reducing the inflammation in the adipose tissues by administering corticosteroids (White 2000). A delay in therapeutic intervention reduces the chances of success, and advanced cases may be refractory to treatment (Niza *et al.* 2003; White 2000). The prognosis in horses, where the disease mostly occurs in foals, is considered to be poor (de Bruijn *et al.* 2006). In fish, steatitis lesions have been reported as incidental finding from apparently healthy slaughter fish (Goodwin 2006). Similar findings of subclinical pansteatitis found at slaughter have been reported from American alligators, *Alligator mississippiensis* (Daudin) (Larsen, Buergelt, Cardeilhac & Jacobson 1983).



### 2.2.2. Aetiology

The pathogenesis of pancreatitis is closely linked to vitamin E intake and consumption of diets rich in polyunsaturated fats. The aetiological cause is a deficiency in the non-enzymatic role of vitamin E as an antioxidant (Danse & Verschuren 1978a; White 2000). This may be caused either by a diet containing insufficient vitamin E or by a relative deficiency of vitamin E brought about by consumption of polyunsaturated fats that destroy the vitamin E (White 2000). The high degree of polyunsaturation of lipids in fish make these particularly prone to oxidative deterioration (Baker & Davies 1996a), and feeding certain fish diets rich in polyunsaturated fatty acids, or rancid fish oils with low vitamin E content, has been implicated in many cases of pancreatitis in both warm and cold blooded animals (Davis & Gorham 1954; Roberts & Rodger 2001; Wallach & Hoessle 1968, White 2000). The concentration of endogenous vitamin E in stored fish oil, known to be rich in polyunsaturated fatty acids, was found to be inversely proportional to the degree of oxidation of the oil (Hung, Cho & Slinger 1980). Polyunsaturated fatty acids are particularly prone to oxidation and consume high levels of vitamin E to contain the harmful effects of lipid peroxidation, accounting for significant depletion of plasma vitamin E associated with consumption of rancid fish diets (Baker & Davies 1996b).

Pancreatitis has been associated with anaemia and myopathy, symptoms typical of vitamin E deficiency. In fish, the anaemia and myopathy appear to be linked to the concurrent hypovitaminosis E that often manifests with pancreatitis. As vitamin E protects against lipid peroxidation, tissue vitamin E levels tend to, within limits, increase with heightened unsaturated fat intake (Raynard, McVicar, Bell, Youngson, Knox & Fraser 1991). In fish feeding on high levels of polyunsaturated fat, however, the tissue vitamin E levels become exhausted within a relatively short period. Vitamin E levels in rainbow trout liver were found to be inversely proportional to dietary level of lipid unsaturation, showing a higher consumption of vitamin E associated with unsaturated lipid intake, and feeding of such diets may induce apparent vitamin E deficiency symptoms (Watanabe, Takeuchi, Wada & Uehara 1981). Under conditions of dietary oxidant overload, depletion of hepatic vitamin E has also been shown to occur in sharpshooth catfish (Baker & Davies 1997a). Furthermore, consumption of rancid oils in the diet may hinder intestinal absorption of vitamin E, and oxidation of vitamin E in the diet prior to ingestion can contribute to suppressed vitamin E intake (Baker & Davies 1996b). Where vitamin E intake is insufficient to provide adequate

protection against the peroxidation of dietary unsaturated or rancid fats, necrosis and inflammation of the fatty tissues ensues giving rise to the clinical picture of pansteatitis.

The close relationship between the oxidation of polyunsaturated lipids and vitamin E deficiency explains the overlap in the symptomatology of pansteatitis and hypovitaminosis E seen in some species (Ginn *et al.* 2007; Post 1993; van Vleet&Valentine 2007). Reduced growth, anaemia, exudative diathesis (ascites, exophthalmos), myopathy, dermal depigmentation, fatty livers with yellow to orange colouration and pancreatic atrophy (Murai & Andrews 1974; Post 1993; Poston, Combs & Leibovitz 1976; Stewart 1993) are typical of vitamin E deficiency in fish, and myopathy and exudative diathesis have also been described with selenium deficiency (Gallagher 1993). Similar changes have been described in some cases of pansteatitis in fish (Roberts *et al.* 1979). However, these changes have not been described in all cases of pansteatitis reported in the literature, and difference in degree of hypovitaminosis E and selenium uptake may explain some of the variation in symptoms and pathology in affected tissues. Other poorly elucidated factors may play a role in the initiation of lesions, and species and tissue dependent sensitivity may be important for the pathogenesis (Danse & Verschuren 1978a). Also, difference in fatty acid composition between various fat depots may account for differences in distribution of lesions in various species (Danse & Verschuren 1978a, de Bruijn *et al.* 2006). Pansteatitis has been extensively studied in rats fed a vitamin E deficient diet supplemented with fish oil by Danse & Verschuren (1978a & b), and these authors suggest that the adipogenic and metabolic characteristics of fat depots may be important determinants for the progression of degenerative changes seen with the disease and may explain species differences in the locations of steatitis within the body. In horses and swine, linolenic acid [18:3(n-3)] is the most important polyunsaturated fatty acid in the fat depots, whereas in other species EPA [20:5(n-3)] and DHA [22:6(n-3)] may be important too, and differences in deposition and metabolic rates of various fat depots may influence the development of steatitis at different sites (Danse & Verschuren 1978a).

Goodwin (2006) described steatitis at the fin bases of channel catfish, *Ictalurus punctatus* (Rafinesque), leading to ulceration and fin loss with few changes elsewhere. In a similar case described in Atlantic halibut, *Hippoglossus hippoglossus* L., Bricknell, Bruno, Bowden and Smith (1996) found fat cell necrosis restricted to the sub-dermal fat deposits around the fin bases of the fish. As the incidence of lesions was restricted to the dorsal surface of the fish the authors postulated an imbalance of dietary oxidants resulting in membrane damage that

may have been aggravated by exposure to sunlight. The fin bases or pterygiophoral regions were similarly implicated in a case of steatitis described in wild common dab, *Limanda limanda* (L.), by Begg *et al.* (2000); however, in this case only the ventral regions of the fish were affected. The authors describe similar lesions in another free-living fish, the long rough dab, *Hippoglossoides platessoides* (Fabricius). The authors point out that there is little overlap in diet between these two species, and this suggests a non-dietary, possibly pollution related cause.

Fish diets have been widely implicated as a cause of pansteatitis in many species of animal. The disorder is known to occur in mink and swine when fed large amounts of fish meal or fish waste that result in a relative vitamin E deficiency, with symptoms appearing approximately one month after commencement of such a diet (Smith *et al.* 1972). In birds the disease has been described in captive fledgling boat billed herons, *Cochlearius cochlearius* (Linnaeus), as a consequence of hypovitaminosis E associated with a frozen fish diet (Pollock, Sleeman, Houle & Ramsay 1999). Vitamin E supplementation applied to the outside of the food fish was suspected to have been washed off the fish by the parent birds before they fed the fish to their young. The disease has frequently been described in the domestic cat, when fed unsuitable fish-based home-made diets (Fytianou *et al.* 2006; Nizaet *al.* 2003). Marine fish are rich in polyunsaturated lipids. In herring the lipids are approximately 80% unsaturated compared with only 50% in beef fat (Geraci & St. Aubin 1980). The rate of lipid peroxidation in fish flesh is increased by light, heat, heavy metals and by the iron-rich haematin compounds that are abundant in dark-fleshed fishes (Geraci & St. Aubin 1980). In cats the disease is particularly associated with feeding of red fish, such as tuna, and diets containing cod liver oil (White 2000; van den Broek & Thoday 1994).

Pansteatitis has also been reported in various species of cultured fish fed diets containing relatively high levels of polyunsaturated fats. Fats of fish origin, particularly in the absence of sufficient vitamin E, have most commonly been implicated (Goodwin 2006; Herman & Kircheis 1985; Roberts & Agius 2008; Robertset *al.* 1979). Under culture conditions, pansteatitis has been described in channel catfish (Goodwin 2006); guppy, *Poecilia reticulata* Peters (Helder 1979); rainbow trout (Roberts *et al.* 1979); Sunapee trout, *Salvelinus alpinusoquassa* Girard (Herman & Kircheis 1985); striped jack, *Caranx vinctus* Jordan & Gilbert (Wada, Hatai & Kubota 1991); Atlantic halibut (Bricknell *et al.* 1996); white sturgeon,

*Acipenser transmontanus* Richardson (Guarda, Bertoja, Zoccarato, Tartari & Biolatti 1997) and northern bluefin tuna, *Thunnus thynnus* L. (Roberts & Agius 2008).

Captive reptiles fed fish diets are known to develop pansteatitis, and the disease has been described in snakes (Langham, Zydeck & Bennett 1971). In crocodylians, pansteatitis has been associated with consumption of large numbers of dead and rancid fish following large scale fish mortality (Huchzermeyer 2003; Ladds, Mangunwirjo, Sebayang & Daniels 1995) and with a change in type of fish fed (Wallach and Hoessle 1968). Pansteatitis was found as an incidental finding at slaughter in captive American alligators fed over a period of 14 years on predominantly freshwater fish in the form of whole fish, fish heads, skins and entrails (Larsenet *al.* 1983), whereas a captive South American caiman, *Caiman crocodilus* (L.), died acutely from pansteatitis following a 3 week period of anorexia after being fed a similar diet (Frye & Schelling 1973).

Reports of pansteatitis in free-ranging wild animals are rare. Pansteatitis has been reported in a wild juvenile red-tailed hawk, *Buteo jamaicensis* (Gmelin), normally a non-piscivorous bird (Wong, Mikaelian, Desnoyers & Fitzgerald 1999), in great blue herons, *Ardea herodias* (Mitchell) (Nichols, Campbell & Montali 1986), and in wild egrets and herons from a reservoir in Japan (Neagari, Arie, Udagawa, Onuma, Odaya, Kawasaki, Tenpaku, Hayama, Harada, Mizukami & Murata 2011), where the cause of the disease was unclear. In wild rabbits, pansteatitis has been described where these animals lived in close association with sea birds and are suspected to have eaten regurgitated fish at times when grazing was sparse (Jones, Howard & Gresham 1969). In wild fish, steatitis has been described from common dab and long rough dab (Begg *et al.* 2000). In Lake Loskop, acid mine seepage was found to be the most likely cause of a mass fish mortality that in 2007 led to the deaths of significant numbers of crocodiles and terrapins as a result of pansteatitis (J. Myburgh and co-workers, Faculty of Veterinary Science, University of Pretoria, pers. comm. 2009). The 2008 episode of crocodile pansteatitis in the KNP differed in that no mass mortality of fish was observed in the affected region. Circumstantial evidence pointed to illegal fishing activity with gill nets as a possible source of dead, rancid fish.

An infectious cause of pansteatitis has seldom been implicated, although steatitis may develop secondary to other disease processes. An unidentified coccidian-like protozoon has been associated with steatitis in a red kangaroo, *Macropus rufus* Desmarest (Dubey & Hartley

1992). In captive marmosets (*Callithrix* spp.), pansteatitis, anaemia and myopathy were thought to be associated with vitamin E deficiency that may have been compounded by presence of chronic colitis (Juan-Salles, Prats, Resendes, Domingo, Hilton, Ruiz, Garner, Valls & Marco 2003). The lipotropic property of certain coxsackie viruses has been demonstrated in mice, and the resulting steatitis was comparable to certain forms of panniculitis in man (Goodman, Bunting & Melnick 1951). In man, the expression of coxsackie virus B-induced myocarditis has been associated with selenium deficiency and other nutritional factors, including polyunsaturated fat and vitamin E intake (Levander & Beck 1997). Steatitis in association with *Streptococcus iniae* infection has been reported in the Amazon River dolphin, *Inia geoffrensis*(Blainville), (Bonar & Wagner 2003) and under mariculture conditions in silver perch, *Bidyanus bidyanus*(Mitchell), (Deng, Peng, Chen, Chen & Chang 2012). In the latter case steatitis was accompanied by severe lipidosis in the affected fish, and a dietary cause was suggested. A congenital cause has been proposed to explain the occurrence of some cases of pansteatitis in foals. Seasonal influences may account for low vitamin E transfer from dam to foal, and oxidation of adipose tissues in the foal might be initiated by infectious agents (de Bruijn *et al.* 2006).

### 2.3. Vitamin E

Under normal metabolic conditions oxyradical production is balanced by cellular antioxidant capacities (Burton 1994). The non-enzymatic role of the fat-soluble vitamin E, and its molecular function as an antioxidant, is well documented, and it is known that Vitamin E plays an important role in nature as an *in vivo* antioxidant preventing the oxidative conversion of polyunsaturated fats into lipid hydroperoxides (Burton 1994; Bus, Aust & Gibson 1976; Hove 1955; Stewart 1993). Lipid peroxides are held responsible for the multiple changes observed in animals deprived of vitamin E (Hove 1955). Several exogenous substances have been reported in the literature to promote the peroxidation of fats, including consumption of unsaturated fat (Burton 1994; Demopoulos 1973). These reactions can be mitigated by the presence of adequate dietary vitamin E (Baker *et al.* 1997; Bell, Cowey, Adron & Shanks 1985; Cowey *et al.* 1984; Fytianou *et al.* 2006; Moccia, Hung, Slinger & Ferguson 1984; Murai & Andrews 1974; Post 1993; Smith 1979; Watanabe *et al.* 1981).

Vitamin E is the generic name used to describe the four tocopherols and four tocotrienols that make up this group of lipid soluble substances (Burton 1994; Kumar, Cotran & Robbins 1997). Of these,  $\alpha$ -tocopherol is the most biologically active (Burton 1994; Puertollano,

Puertollano, Álvarez de Cienfuegos & de Pablo 2011; Stewart 1993). For reasons of consistency the term vitamin E will be used to refer to  $\alpha$ -tocopherol in this thesis. Vitamin E is absorbed from the diet via the small intestine and is taken up by the lymph in chylomicrons derived from the intestine (Burton 1994). As with other fat soluble vitamins this requires normal biliary and pancreatic function (Kumar *et al.* 1997). In the circulation, lipoprotein lipase bound to the vascular endothelium rapidly catabolises chylomicrons to free fatty acids and monoacylglycerols allowing the transfer of fatty acids and vitamin E to tissues (Burton 1994). At the same time chylomicron components and vitamin E are transferred to plasma, where vitamin E rapidly equilibrates with low density lipoprotein in the plasma (Burton 1994; Kumar *et al.* 1997). From the liver vitamin E is secreted into plasma in triacylglycerol-rich, very low density lipoproteins. The hydrolysis of these lipoproteins by lipoprotein lipase delivers fatty acids and vitamin E to tissues (Burton 1994). In contrast to vitamin A, which is primarily stored in the liver, vitamin E is stored throughout the body, mainly in adipose tissue and to a lesser extent in liver and muscle (Baker & Davies 1997a; Kumar *et al.* 1997).

Vitamin E is the main chain-breaking lipid soluble antioxidant that reduces damage to lipid membranes caused by reactive oxygen species (ROS) (Puertollano *et al.* 2011). In rats fed a vitamin E deficient diet, lipid peroxidation in tissues was enhanced by concurrent selenium deficiency (Awad, Morrow, Hill, Roberts & Burk 1994). In fish, as in mammals, glutathione peroxidase, an enzyme that recycles glutathione and removes further ROS to balance the redox state of the cell, is selenium dependant (Bell *et al.* 1985). Apart from its antioxidant role, vitamin E is involved in a number of other metabolic functions, including cell membrane integrity, enzyme and heme synthesis, and steroidogenesis (Geraci & St. Aubin 1980).

Dependency on lipoprotein polyunsaturated fats for normal metabolic function is more pronounced in poikilothermic (cold blooded) animals than in homothermic (warm blooded) animals (Agius & Agbede 1984; Hazel 1979; Hulbert 2003). The elongated and desaturated derivatives of linoleic acid (n-6) and  $\alpha$ -linolenic acid (n-3) are essential fatty acids that affect the fluidity, flexibility and permeability of membranes (Steffens 1997). Poikilothermic animals such as fish and crocodiles depend on dietary polyunsaturated fats to maintain this membrane fluidity and normal metabolic function, especially at colder ambient temperatures, and are thus particularly sensitive to the effects of lipid autoxidation (Hazel 1979; Hulbert 2003). In trout this is expressed by a greater susceptibility to vitamin E deficiency at low



water temperatures (Cowey *et al.* 1984). Stabilising lipids is an important *in vivo* function of vitamin E that extends beyond the life of the animal and is important in the storage stability of meat products. The risk of post-mortal oxidative lipid breakdown (rancidity) is magnified in fish as a result of the high polyunsaturated fatty acid content of fish flesh. In many parts of Africa, lack of cooling facilities and poor sanitary conditions lead to rapid deterioration of harvested fish. In freshwater fisheries, such as Lake Massingir, smoked fish are a popular product and are often kept for several weeks and shipped long distances before being consumed. Where vitamin E levels in the tissues are already low as a result of *in vivo* radical-mediated damage, there is a potentially increased risk of radical attack on human tissues after consumption of such fish products (Baker & Davies 1996a).

## **2.4. Oxidative Stress and *in vivo* Lipid Peroxidation**

### **2.4.1. Free radical attack**

Free radical reactions are common in normal cellular functions, but uncontrolled free radical reactions may be the initial molecular events resulting in various pathological processes (Demopoulos 1973). Lipid peroxidation is common to oxidative stress reactions, whether dietary or xenobiotic in nature. Although polyunsaturated fats are the most abundant and vulnerable target of free radical attack, structural and functional damage also occurs to carbohydrate, protein and DNA containing structures leading to various pathologies including neoplasia (Burton 1994; Porter 1989). Autoxidation, the spontaneous reaction of molecular oxygen with radicals, is held responsible for numerous deteriorative processes, including rancidity, that develop in foodstuffs (Porter 1989). The propensity of autoxidation to initiate chain reactions can greatly amplify damage to lipids. This can lead to the sometimes far reaching consequences of free radical exposure (Burton 1994; Porter 1989).

Free radicals are chemical species that have a lone, unpaired electron in an outer orbit, a state that can exist in diverse compounds and that initiates relatively nonspecific hydrogen abstraction and chemical addition reactions (Demopoulos 1973; Tappel 1973). In unsaturated fatty acids, the presence of a double bond weakens the carbon-hydrogen bond of the carbon atom adjacent to a carbon with an unsaturated bond, making these particularly prone to peroxidation (Demopoulos 1973). With increasing number of double bonds in a fatty acid, the susceptibility to radical reactions is increased. Polyunsaturated fats are the most vulnerable and most abundant target of free radical reactions, the damage being caused either by free radicals themselves or by lipid peroxidation products such as aldehydes (Burton, 1994).

Peroxidation of polyunsaturated lipids results directly from the oxidative effects of oxygen, but the reaction needs to be initiated in some way to overcome the dissociation energy of an allylic bond in the polyunsaturated fatty acid (Burton 1994; Minotti & Aust 1992).

Lipid peroxidation can be initiated by redox cycling of various transition metals. Iron, an abundant metal in the body and needed for oxygen transportation, has been shown to be a potent initiator of lipid peroxidation (Demopoulos 1973; Kibanova, Nieto-Camacho & Cervini-Silva 2009; Minotti & Aust 1992). Unsaturated fatty acids make up an integral part of the plasma membranes of cells and of the membranes of organelles. The unsaturated bonds of fatty acids are situated in the nonpolar hydrophobic mid-zone of cell membranes where they are protected from oxidative damage (Bus *et al.* 1976; Demopoulos 1973; Minotti & Aust 1992). The rancidity of fats exposed to air follows a radical reaction initiated and catalysed by metals such as iron and copper, particularly if in complexes, such as heme, as these are more soluble in the nonpolar environment of the mid-zone of membranes (Demopoulos 1973). As the allylic carbon bonds of unsaturated fatty acids are partially activated, small amounts of pro-oxidants will initiate complete activation, resulting in abstraction of an allylic hydrogen. This sets in motion the series of structurally significant chain reactions termed lipid peroxidation and exerts a profound effect on membrane structure and function (Demopoulos 1973; Kelly, Havrilla, Brady, Abramo & Levin 1998; Minotti & Aust 1992). Lipid free radicals released from decomposition of lipid hydroperoxides initiate the subsequent lipid peroxidation of cell membranes with far reaching consequences (Bus *et al.* 1976).

Pro-oxidant or oxyradical production in aquatic organisms has been linked to anthropogenic activity resulting in pollution of the aquatic environment (Bainy, Saito, Carvalho & Janqueira 1996; Winston 1991; Winston & Di Giulio 1991). A link between pollution-induced *in vivo* lipid autoxidation in fish and the subsequent development of pansteatitis in crocodiles and fish has not previously been elucidated.

#### **2.4.2. Xenobiotics as pro-oxidants**

Oxidative stress is an important component of toxicology, and increasing evidence suggests that it is also of ecological significance, particularly where pollutants are carried in the aquatic environment (Kelly *et al.* 1998). The *in vivo* reduction in tissue vitamin E brought about by the inherent instability of polyunsaturated fatty acids may increase expression of



other xenobiotic oxidants where dietary polyunsaturated fat intake is high. Oberholster *et al.* (2011) working in Lake Loskop, a polluted water body in the upper Olifants River catchment, have documented the bioaccumulation of iron and aluminium by phytoplankton species in this lake. Raised levels of both aluminium and iron in the fat of Mozambique tilapia from some sites in Lake Loskop were thought to derive from ingestion of phytoplankton species, and may have been responsible for the yellow discolouration of the fat of these fish. Redox cycling of iron is known to be an initiator of lipid peroxidation (Baker *et al.* 1997; Demopoulos 1973; Di Giulio, Washburn, Wenning, Winston & Jewell 1989; Kibanova *et al.* 2009; Minotti & Aust 1992; Tappel 1973) and depletion of tissue vitamin E levels by high dietary iron intake may render polyunsaturated fats in the tissues of the fish vulnerable to peroxidation (Baker *et al.* 1997).

The acquisition of iron by teleost fishes has been reviewed by Bury and Grosell (2003). Although iron is one of the most abundant metals on earth, biologically unavailable colloidal hydrous iron oxides predominate in naturally oxygenated freshwater environments with near neutral pH. When these complex with organic matter in freshwater environments they settle out, and in the anoxic zone of sediments the ferric iron ( $\text{Fe}^{3+}$ ) reduces to ferrous iron ( $\text{Fe}^{2+}$ ), which may leach back into the water. In freshwater fish, iron is readily taken up by the gill and intestinal epithelia in the ferrous state, and, although iron may be assimilated from both the water and the diet, uptake from the aquatic environment forms a considerable part of the iron homeostasis of freshwater fish. To regulate cellular iron concentrations the intracellular protein ferritin takes up ferrous iron and oxidises this to ferric iron which is incorporated into the ferritin molecule (Bury & Grosell 2003). The lipid peroxidation potential of iron is countered by the strong iron-binding properties of lactoferrin and transferrin at physiological degrees of iron saturation (Gutteridge, Paterson, Segal & Halliwell 1981). There is no known regulatory excretory pathway for excretion of iron. Homeostasis is regulated by absorption from the diet, although some iron may be lost through breakdown of haemoglobin and excretion through bile and by sloughing of intestinal epithelium (Bury & Grosell 2003). Baker and Davies (1997b) have proposed that transient lipid damage instigated by elevated dietary intake of iron in sharptooth catfish may be responsible for lowering hepatic vitamin E levels.

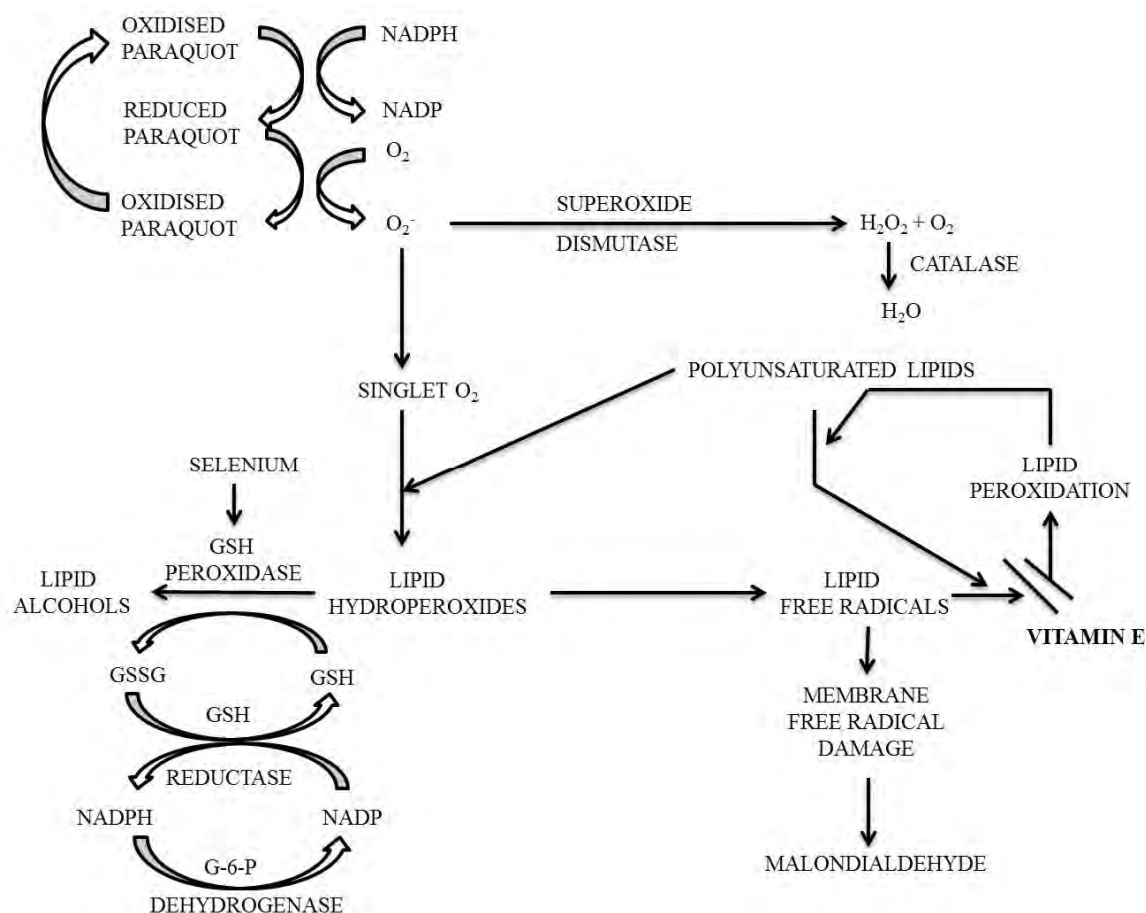
A number of other vitamin E antagonists involved in catalytic peroxidation of unsaturated fats are known for their pro-oxidant effect. Hove (1955) described the vitamin E antagonistic

effects of cod liver oil; tri-o-cresyl phosphate (TOCP), a plasticizer, solvent and gasoline additive; carbon tetrachloride ( $\text{CCL}_4$ ); pyridine; some sulphonamides; and sodium sulphite, although the biochemical action of these poisons may be more complex. Tri-o-cresyl phosphate in the diet of lambs was shown by Draper, James and Johnson (1952) to induce a disease identical to “stiff lamb disease”; the symptoms could be prevented by administration of vitamin E. In silver poisoning, Diplock, Green, Bunyan, Mchale and Muthy (1967) showed that, in the rat, the dietary stress of silver on vitamin E function was independent of peroxidation of unsaturated fat and that the anti-vitamin E effect of silver was not a pro-oxidant effect. On the other hand iron, was demonstrated by Baker *et al.* (1997) to increase fatty acid peroxidation in hepatic and cardiac tissue in sharptooth catfish consuming sub-lethal levels of dietary iron sulphate (ferrous iron).

Xenobiotics capable of redox cycling are particularly relevant to toxicology (Kelly *et al.*, 1998). Those capable of redox cycling include: quinones (menadione, pyrene quinone, adriamycin and mitomycin C), bipyridyl herbicides (paraquat, diquat and 1,10-phenanthroline), aromatic nitro compounds (nitrofurantoin, nitropyrene and misonidazole), aromatic hydroxylamines, some dyes, some transition metals, and metal chelates (Fe-EDTA and Cu-bleomycin) (Di Giulio *et al.* 1989; Kelly *et al.* 1998). Other chemicals that are either free radicals or hydrophobic may induce free radical reactions in the presence of unsaturated fatty acids and include the alkyl polyhalides ( $\text{CCL}_4$ , DDT, halothane), alcohols, and the chemical carcinogens 4-amino biphenyl and dimethyl 4-amino biphenyl (Demopoulos 1973). It has been proposed that the oxidative tissue damage, reflected in hepatic lipid peroxidation and DNA damage resulting from exposure to the polyhalogenated hydrocarbons, lindane, DDT, chlordane and endrin may contribute to the toxic manifestations of these xenobiotics (Hassoun, Bagchi, Bagchi & Stohs 1993). In mice and rats exposed to dietary dieldrin, a reduction in hepatic and serum vitamin E level was observed, suggesting oxidative challenge (Bachowski, Xu, Stevenson, Walborg & Klaunig 1998). Pansteatitis has, however, not been reported with exposure to these xenobiotics.

The herbicide, paraquat, has been used as an oxidant model causing lipid peroxidation of cell membranes in both humans and animals (Åkerman, Amcoff, Tjärnlund, Fogelberg, Torrissen & Balk 2002; Bus *et al.* 1976; Parvez and Raisuddin 2005). The cyclical reduction-oxidation of paraquat results in generation of superoxide radicals which dismutate to singlet oxygen, a free radical species that has a lone, unpaired electron. Singlet oxygen reacts with unsaturated

lipids in cell membranes to form lipid hydroperoxides. The chain reaction leading to the membrane destructive process of lipid peroxidation results from the spontaneous decomposition of lipid hydroperoxides to lipid free radicals (Buset *al.*1976) (Figure 2.1). Imbalances in generation and removal of radical species result in oxidative stress that has the potential to cause biological injury (Kelly *et al.* 1998). Basic biological processes such as cellular respiration and the action of certain enzymes lead to production of reactive oxygen species within the body. Certain xenobiotics have the ability to enhance the cellular production of such oxyradicals within cells (Kelly *et al.* 1998).



**Figure 2.1:** Schematic presentation of the effect of redox cycling of a pro-oxidant on polyunsaturated lipids. Proposed mechanism of paraquat toxicity (from Bus *et al.* 1976) [GSH=glutathione].

Mammalian organisms use three defence mechanisms to counter the destructive process caused by oxidative stress. Superoxide dismutase scavenges toxic superoxide radicals, endogenous antioxidants such as vitamin E terminate the free radical chain reaction of lipid

peroxidation and glutathione peroxidase enzymatically reduces the unstable lipid hydroperoxides to stable lipid alcohols, thus preventing further formation of free radicals (Bus *et al.* 1976). Vitamin E acts as hydrogen atom donor thereby preventing the reactive lipid peroxy radicals from abstracting hydrogen atoms from *in vivo* sources such as DNA and proteins (Kelly *et al.* 1998). With deficiency of the antioxidants selenium, vitamin E and glutathione the toxicity of xenobiotics such as paraquat is significantly increased (Bus *et al.* 1976).

## 2.5. Bio-monitoring

Histopathological tissue changes in fish have been proposed as a sensitive tool for assessing exposure to pollution (Adams, Brown & Goede 1993; Bernet, Schmidt, Meier, Burkhardt-Holm & Wahli 1999; Heath, du Preez, Genthe & Avenant-Oldewage 2004; Roberts & Agius 2003), and the role of fish in sediment toxicity assessments has been reviewed by Halare, Seiler and Hollert (2011). These authors stress the importance of benthic rather than pelagic fish species in such studies. Histology has been used to monitor the health status of tigerfish, *Hydrocynus vittatus* Castelnau, lowveld large scale yellowfish, *Labeobarbus marequensis* (Smith), rednose labeo, *Labeo rosae* Steindachner and redeye labeo, *L. cylindricus* Peters, fish representing different trophic levels in the Olifants River in the KNP, and showed that these species were in a healthy state (Wagenaar, Smith & Smit 2012a; Wagenaar, Smith & Smit 2012b).

The cellular responses to oxidative stress in fish are similar to those of mammals. These include activation of low molecular weight radical scavengers such as glutathione (GSH), vitamin E and ascorbic acid as well as the antioxidant enzymes, superoxide dismutase (SOD), catalase and glutathione peroxidase (GPx) (Kelly *et al.* 1998, Winston 1991). Increased activity of these enzymes has been associated with exposure to redox-cycling compounds (Di Giulio *et al.* 1989). As in mammals, glutathione peroxidase activity in salmonids has been shown to be dependent on selenium (Bell *et al.* 1985; Poston *et al.* 1976). These endogenous antioxidant defence mechanisms and related biomarkers have been used in mammalian and fish tissues to measure the effects of pro-oxidant exposure (Awad *et al.* 1994; Parvez & Raisuddin 2006). Amongst mammals, cats are known to be particularly sensitive to the pro-oxidant effect of ingested polyunsaturated fats. Measurable changes in the levels of vitamin E and glutathione peroxidase have been demonstrated in the blood of kittens exposed to experimental diets rich in polyunsaturated fats (Fytianou *et al.* 2006).

A prerequisite for use of biomarkers is that the response should be a selective, primary response detectable in the living organism before the onset of more serious pathological consequences, but not all biochemical responses meet these criteria (Di Giulio *et al.* 1989). Interpretation of such changes in *in vivo* field studies may not be straightforward. The influence of variables that are difficult to control such as age, physiological and reproductive state, season and water quality, affecting both the organism and toxicant bio-availability, can influence the quantifiable endpoint of bio-monitoring (Di Giulio *et al.* 1989). Depending on the type of oxidative stressor, the responses of antioxidant enzyme activity may be variable; they may be elevated as a result of induction or suppressed as a toxic reaction to a stressor, or with exposure to multiple stressors both responses may occur simultaneously resulting in no net difference (Di Giulio *et al.* 1989). Oxidative stress has been shown, particularly in cases of toxicant-induced inflammation, to lead to up-regulation of antioxidant enzymes (Kelly *et al.* 1998). In experimental situations the harmful influences of pro-oxidants have been demonstrated by negating these effects by antioxidant supplementation, particularly with vitamin E (Awad *et al.* 1994; Baker & Davies 1996a; Baker & Davies 1996b; Bell *et al.* 1985; Cowey *et al.* 1984).

The thiobarbituric acid reactive substances (TBARS) test is a commonly used assay to measure malondialdehyde (MDA), one of the end products of lipid peroxidation, in plasma (Kelly *et al.* 1998, Hinchcliff & Piercy 2000). However, as thiobarbituric acid reacts with a number of other oxidation products, the test is non-specific (Kelly *et al.* 1998). Malondialdehyde is also rapidly metabolised and may not always be a reliable indicator of lipid peroxidation *in vivo* (Bus *et al.* 1976), and significant levels above the basal level must be present for accurate assessment of *in vivo* lipid peroxidation (Di Giulio *et al.* 1989). It has been suggested that ethane and pentane, measurable  $\beta$ -scission products of n-3 and n-6 fatty acids in the breath of small laboratory animals, might also be adapted to aquatic animals as a sensitive test of *in vivo* lipid peroxidation (Di Giulio *et al.* 1989).

Free radicals may also play a role in chemical carcinogenesis and induction of the mixed-function oxygenases (MFO), and MFO responses have been used as biomarkers for chemical exposure, particularly to hydrocarbon pollutants (Di Giulio *et al.* 1989). The effect of oxyradical damage on DNA from environmental genotoxicants such as polycyclic aromatic hydrocarbons, pesticides and metals has led to the development of several methods for

detecting DNA damage. Lee and Steinert (2003) have reviewed the use of single cell electrophoresis or the comet analysis for detecting DNA damage in marine and freshwater aquatic animals and suggest that this test has several advantages over other methods of determining DNA damage.

## **CHAPTER THREE: FIELD STUDY**

### **3.1. Materials and Method**

#### **3.1.1. Introduction to the fieldwork**

The focus of the fieldwork was on the sharptooth catfish, as this species was thought to be a major food source for crocodiles along the Olifants River gorge and lower Letaba River. Being an omnivorous benthic scavenger it is likely that this species would be preying on other weakened fish species in the system. Samples were collected and processed over a 2 year period between November 2009 and November 2011. Fish surveys were done by the author as early as August 2008 and, where relevant, data from fish sampled between August 2008 and November 2009, although not part of the structured study, have been included in the results. Collection of fish samples from the Olifants Gorge took place every six months. Winter samplings were done between June and September when river flow had subsided, most of the rainfall-related sediment load had been dropped and water temperatures had reached their winter minimum. Summer sampling was done between November and March when river flow and sediment load were high. Up to 25 fish were collected during each sampling episode in the Olifants Gorge. It was not always possible to catch as many fish as this from the reference sites. Fish were caught by baited hook and line and by netting. A range of fish species, including Mozambique tilapia, were included in samplings prior to November 2009. In September 2008 and June 2011, tigerfish were also sampled in the Olifants Gorge from the confluence of the Olifants and Letaba rivers.

### **3.1.2. Description of the study area**

Samplings took place from the confluence of the Olifants and Letaba rivers (23°59'21.8"S 31°49'35.6"E), where the Olifants River enters a 9 km long gorge through the Lebombo Mountains, to where it enters Lake Massingir on the Mozambique border (23°57'48"S 31°52'97"E) (Figure 3.2). Catfish specimens were also collected from various other localities within and outside the KNP. These included a negative reference population in Reënvoël Dam (23°58'37.2"S 31°19'38.4"E) that has its entire catchment within the KNP, and a wild population in van Ryssen Dam (24°00'13.6"S 31°05'36.9"E) at the FOSKOR phosphate mine near the town of Phalaborwa (Ba-Phalaborwa Municipality) just west of the KNP. Upstream of the gorge fish were sampled at Mamba Weir (24°03'32"S 31°14'14"E), where the Olifants River enters the western boundary of the KNP. On the Letaba River fish were sampled from Engelhard Dam (23°50'19"S 31°28'28"E). Further south in the KNP samplings took place from the Sabiepoort (25°10'25.41"S 32°02'23.42"E), where the Sabie River enters Lake Corumana on the Mozambique border and from the Crocodile River (25°23'57.1"S 31°57'29.9"E) on the southern boundary of the Park. In the north of the KNP, fish were sampled from the Levuvhu River (22°25'51.0"S 31°18'04.4"E). Catfish were also sampled



from a farmed population at Lunsklip Fisheries (25°23'08.9"S 30°15'35"E) near Lydenburg (Thaba Chweu Municipality), Mpumalanga. These fish were fed almost exclusively an excess of trout slaughterhouse waste, rich in polyunsaturated fat. Slaughterhouse waste, consisting largely of fat rich innards, was dumped into the catfish pond where it was left to be consumed by the fish. Trout farmed at Lunsklip fisheries were fed a commercial trout ration which was top-dressed with additional marine fish oil.

### **3.1.3. Specimen collection**

To minimise the influence of autolytic change on the gross and microscopic appearance of the organs and tissues of the sampled fish, all sampled fish were transported live to the relevant examination facilities and were kept alive until they could be examined. Setting up a field laboratory near the site of sampling was not always possible due to the logistical and safety considerations of working in the field in the KNP. Sharptooth catfish are air-breathing fish and can be transported live over relatively long distances without adverse effects. A portable holding tank (Minurphy Tarpaulins, Pietermaritzburg) was filled with river water at each field laboratory site. To minimise stress, the fish were released into the holding tank as soon as was practical after being caught and were kept there until they could be examined. A maximum of 20 fish could be examined in one day, but the number was dependent on the catch success of the fishermen. Up to 28 fish were collected on each sampling occasion. Two 250 L fish transport tanks belonging to SANParks were used to transport the fish. The catfish were either processed at the sampling site or transported live in fish transport tanks to various laboratory facilities.

All fish sampled prior to November 2009 were examined and dissected in field laboratories set up near the sampling sites along the river. Catfish caught in the Olifants Gorge and in Reënvoël Dam in November 2009 were transported live to Lydenburg and examined and dissected in the author's facility. In July 2010 the post-mortem facility, belonging to SANParks Scientific Services, in Skukuza was used and fish from the Olifants Gorge, Mamba Weir, Engelhard Dam and the Sabiepoort were transported live to Skukuza. In January 2011, a field laboratory was set up first near the confluence of the Olifants and Letaba Rivers and then at Reënvoël Dam, and fish were examined and dissected on site. Fish from van Ryssen Dam were brought live to the field laboratory at Reënvoël Dam. For the June 2011 samplings, a field laboratory was again set up near the confluence of the Olifants and Letaba rivers and fish from the Levuvhu River were transported live to this site. Tigerfish



sampled from the Olifants Gorge at the confluence of the Olifants and Letaba rivers were caught within a short walking distance from a field laboratory set up at the confluence. Tigerfish are sensitive to water quality and handling stress, and these fish were examined and dissected without delay as they were caught. For examination of catfish from the Crocodile River in June 2011 the post-mortem facility in Skukuza was used. The fish were transported live from the Crocodile River to Skukuza. Catfish from Lunsklip Fisheries were examined and processed on site at Lunsklip Fisheries.

#### **3.1.4. Sampling and fish dissections**

For examination fish were placed into a water bath containing benzocaine hydrochloride (Kyron Laboratories, Johannesburg) as anaesthetic at approximately 30 ppm. Once anaesthetised, the fish were removed from the anaesthetic bath, weighed and subjected to length measurements, body condition scoring and blood collection. For ease of handling the fish were placed into a PVC cradle made from a one meter section of PVC pipe, cut lengthwise through the middle, with rectangular plastic ends attached to prevent the cradle from rolling. Detailed data sheets were completed for all gross observations and measurements. Blood was collected through a 20 gauge hypodermic needle into a 5 ml syringe from the large vessels just ventral to the vertebral canal in the tail area caudal to the abdominal cavity or from the large blood vessels running through the kidney. Collected blood was directly transferred to both EDTA and serum tubes. EDTA tubes were gently shaken to avoid clotting and were wrapped immediately in aluminium foil to prevent exposure to sunlight. Fresh blood smears were made from each fish and air dried before being fixed and stained. Samples for serum were centrifuged to separate the blood from the serum after clotting had occurred.

The catfish were then euthanized by being kept in the benzocaine hydrochloride anaesthetic bath until all life signs had ceased. Gross examination and post-mortem dissection were performed. The following adipose tissues were carefully examined for gross signs of pancreatitis: mesenteric fat, pectoral fat, coronary fat, intermuscular and hypodermal fat, and fat surrounding the brain. The mesenteric fat was removed from each fish and weighed. Tissue specimens from all organs were collected and immediately fixed in 10% buffered formalin.

The major part of the visceral fat of sharptooth catfish is stored within the mesenteries, forming a discrete body towards the caudal portion of the abdominal cavity. A further discrete body of fat originating from the hypodermal fat layer is situated behind the pectoral fin. This fat cushion overlies an extension of the anterior kidney and liver into the hypodermal space, a feature unique to this species. For the purposes of this manuscript these two discrete fat depots will be referred to as mesenteric and pectoral fat respectively. Samples of liver, mesenteric fat, pectoral fat and eyes were collected on ice for toxicological examination by co-workers. Pectoral and mesenteric fat were collected for determination of fatty acid composition. The bony structures surrounding the swim bladders of the catfish were opened to allow inspection of the swim bladders. Otoliths were collected from all specimens for age determinations.

As each organ system was examined the relevant observations were recorded. The following small tissue samples were collected in 10% buffered formalin from each fish. Tissue blocks, approximately 15 mm long, 10 mm wide and at least 5 mm thick, were cut from the mesenteric fat, pectoral fat, brain fat, liver, pancreas, spleen, cranial and caudal kidney, heart and gonad. A cross-sectional wedge of muscle and skin, including intermuscular fat, approximately 5 mm thick, was cut from the body of each fish. The wedge was cut from the tail region, just caudal to the cloaca, and extended from the pterygiophores on the ventral midline into the lateral musculature. One gill arch was removed from one side of the fish, and the soft tissue of the arch with a number of attached primary gill filaments was dissected free of the bony arch. The entire brain was removed from the cranium and also fixed in 10% buffered formalin. Intestine was included only on some occasions. Sagittal otoliths were removed from each sampled fish and placed into small paper envelopes and left to dry. The number code allocated to each fish was recorded on the respective specimen bottle and otolith envelope.

Sampling from the Sabiepoort and from van Ryssen Dam had not been included in the original protocol. As a result of time constraints and limited facilities at these two sampling sites, no blood samples or weights of fat tissues were collected from these fish.


### **3.1.5. Gross and histological examinations**

All information gleaned from the gross and histological examinations was recorded in table form and later transcribed to Excel spread sheets. Each fish was given a sampling number and


code relevant to the sampling site and date. The fish identification number was written onto a square of paper and placed onto the relevant fish for photographic documentation. Each fish was photographed before the start of the dissection. A second photograph was taken of each fish after the abdominal wall had been removed exposing the abdominal organs. All interesting pathology was photographed. The originally assigned code and number of each fish was used to identify all samples collected from the fish. Laboratory results, including the histological examination of the tissues, were linked to each individual fish via this number. During the initial data collection from the gross examination, written descriptions were recorded and numerical scores were ascribed to each observation. Apart from sample collection for further laboratory evaluation, the length and weight of each fish was measured, and the condition score was recorded. A scoring system on a scale of one to five was systematically applied to all organs and tissues, with one showing the greatest degree of abnormality and five showing no abnormality.

### **3.1.6. Laboratory Work**

Preparation of histological sections was done by the histopathology laboratory of the Pathology Section, Department of Paraclinical Sciences, Faculty of Veterinary Science, University of Pretoria. Tissue specimens, fixed in 10% formalin, were processed using standard histological technique, and paraffin wax sections were cut at 5µm. All specimens were mounted on glass slides and stained with haematoxylin and eosin (H&E). A selected number of sections from fish with severe pansteatitis, sampled from Lunsklip Fisheries and from the Olifants Gorge in November 2009, were in addition stained with Periodic acid Schiff's (PAS), Gomoris aldehyde fuchsin (GAF) and Perl's Prussian blue stain. Sections were prepared from the following organs and tissues of all sampled fish: mesenteric fat, pectoral fat, hypodermal and intermuscular fat, brain fat, liver, spleen, kidney, pancreas, heart, gonad, muscle, skin, gills and brain. Sections of the intestines were prepared from a selected number of fish. Blood smears were fixed and stained with a CAM's quick stain (Kyro-Quick stain, Kyron Laboratories) in the author's veterinary clinic. Otoliths were embedded in resin and sectioned transversely at 0.4 mm thickness by microtome according to the method of Weyl and Booth (2008) at the Department of Ichthyology and Fisheries Science, Rhodes University, Grahamstown. Mounted sections were examined under the light microscope by the author. Growth zones were counted to determine the ages of the fish (Figure 3.1a & 3.1b).



**Figure 3.1a:** Example of growth rings in the otolith of a 19 year old catfish from the Olifants Gorge.



**Figure 3.1b:** Example of growth rings in the otolith of a 4 year old catfish from the Olifants Gorge.

Histological sections were examined by the author by standard light microscopy for presence of pathology. Relevant pathology was photographed by the author at the Pathology Section, Department of Paraclinical Sciences, Faculty of Veterinary Science, University of Pretoria. Stained blood smears made from all fish collected from the Olifants Gorge, Lunsklip Fisheries and Reënvoël Dam during November 2009 were examined under a standard light

microscope. One hundred erythrocytes were counted, and the proportion of polychromatocytes determined and recorded. This was repeated over two further areas of the same blood smear. The average of the three counts was taken to be representative of a specific blood smear. The amount of crenation of the erythrocytes was noted.

To determine the haematocrit of the fish, microhaematocrit tubes were filled and sealed before centrifugation on a field micro-centrifuge. Packed cell volume (PCV) was expressed as percentage of the height of the red cell column compared to the total column height. All changes were recorded in detail and the relevant information added to the fish data sheets.

Blood glutathione peroxidase and vitamin E measurements have been used in studies of the acute effects of steatitis in kittens (Fytianou *et al.* 2006) and dietary vitamin E and selenium deficiency in rainbow trout (Bell *et al.* 1985). The measurement of these blood parameters was included in this study in an attempt to identify tests suitable for non-lethal monitoring of pansteatitis in catfish of the KNP. Serum samples and blood samples collected in EDTA were immediately put on ice or refrigerated and submitted to IDEXX Laboratories (Johannesburg) for determination of haemoglobin and erythrocyte glutathione peroxidase values. Serum vitamin E determinations were done by the laboratory of Ampath Pathologists on behalf of IDEXX laboratories.

### **3.1.7. Statistical analysis**

Presence of grossly visible signs of pansteatitis was used to determine pansteatitis prevalence. For further statistical evaluation, data were grouped into two categories: those collected from fish with pansteatitis (category 1) and those collected from fish where pansteatitis could not be demonstrated either macroscopically or histologically (category 2). Where an observation could be categorised into presence or absence of the observation, the frequency distribution was analysed using the chi-squared test or contingency analysis (Agresti & Franklin 2007). To test the effect of age on pansteatitis in catfish from the Olifants Gorge, the frequency of pansteatitis in catfish below and above 3 years of age was examined. A further test was done to compare the mean ages of catfish with and without pansteatitis. To test the effect of mass and length on pansteatitis incidence, the means for body mass and length of catfish with and without pansteatitis were compared. To allow the effect of condition factor on pansteatitis incidence to be tested, mass and length data were converted to express condition factor [ $C=(\text{mass}/\text{length}^3)10^5$ ].



Apart from the descriptive recordings of gross pathology and histopathology observations, all observations were assigned a numerical score on a scale of one to five, where five denoted no observable abnormality and one denoted severe abnormality. As these scores represented frequencies of less than  $n=5$ , the non-parametric Kruskal-Wallis and Mann-Whitney U tests (Agresti & Franklin 2007) were used to test for differences in the frequency of histopathology observations of various parameters between fish with and without pansteatitis from the Olifants Gorge sites. The same tests were used to analyse whether significant variances also existed for the frequency of a specific observation between sampling sites. The tests were performed on the following data sets: data from all Olifants Gorge samplings (Test data=sites where pansteatitis was found), data from Reënvoël Dam (RV and RVB) samplings (Ref data=sites where no pansteatitis was found), data from the Lunsklip Fisheries sampling (LK=positive reference site with high prevalence of pansteatitis).

T-tests were used to compare mean blood chemistry and haematological values between steatitis positive and steatitis negative fish sampled from the Olifants Gorge and from Lunsklip Fisheries. Type 1 error levels below 0.05 (5%) were accepted as significant. A second set of data was arranged to compare means of all data for a particular variable between sampling sites without differentiating whether the samples were obtained from fish with or without steatitis. The data were statistically analysed using analysis of variance followed by the post-hoc Tukey HSD Test (Agresti & Franklin 2007). Where necessary, the non-parametric Kruskal-Wallis test was used (Agresti & Franklin 2007). For comparison of the percentage of fish with suppressed serum vitamin E values between sites, the chi-squared test was used.

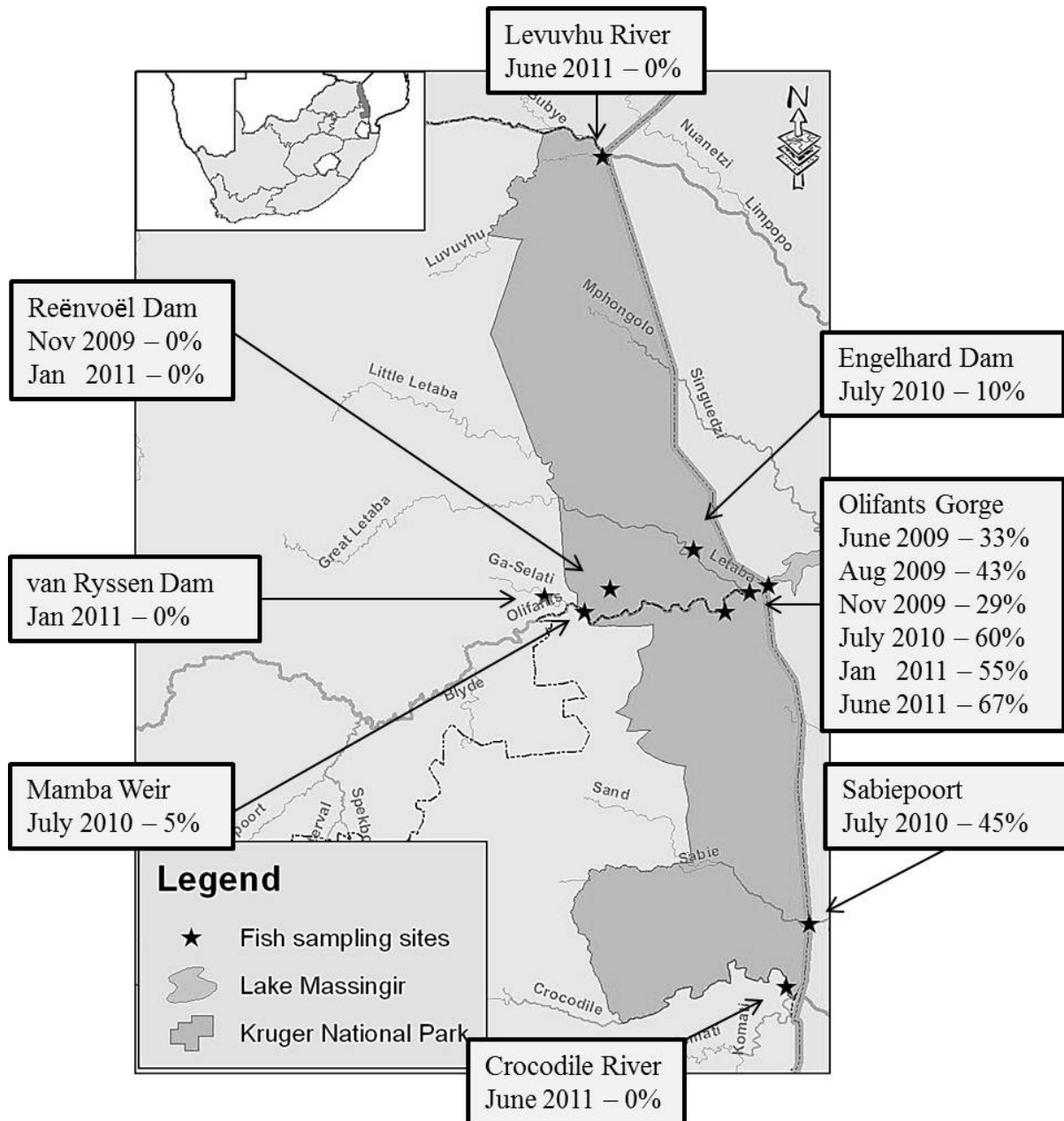
All statistical analyses were done using Statistica 10 (Statsoft).

- 3.2. Results**
- 3.2.1. Prevalence of pansteatitis**
- 3.2.1.1. Prevalence in free living catfish**

The observations on prevalence of pansteatitis in catfish in rivers and dams in the KNP have been published and the manuscript is attached to the thesis (Huchzermeyer 2012) [see Appendix A.2].

The most distinctive pathology observed in catfish from the Olifants Gorge was centred in the adipose tissues of the fish. At localities where pansteatitis was observed in the sampled catfish, the mesenteric fat was most frequently and most severely affected by pansteatitis. Pansteatitis was only occasionally observed in the pectoral, intermuscular and hypodermal fat and in the fat surrounding the brain simultaneously with pansteatitis in the mesenteric fat. Pansteatitis was never observed in the coronary fat. Presence of macroscopic lesions of fat necrosis and associated inflammation of the adipose tissues was used to determine pansteatitis prevalence in the KNP rivers (Figure 3.2).

A high prevalence of pansteatitis was repeatedly identified in catfish sampled from the Olifants Gorge between August 2009 and July 2011. Pansteatitis prevalence similar to that found in fish from the Olifants Gorge was detected in catfish sampled from the Sabiepoort during a single sampling in July 2010. Lesions in the adipose tissues were identical to those observed in fish from the Olifants Gorge, and splenomegaly and pancreatic atrophy was similarly observed. Lower pansteatitis prevalence was observed in fish sampled from Engelhard Dam. However, the severity of pansteatitis lesions in one fish from this site was comparable to that of severely affected fish from the Olifants Gorge and Lunsklip Fisheries (see section 3.2.1.3). In catfish sampled from Mamba Weir a low prevalence of pansteatitis was noted. Macroscopically no pansteatitis could be identified in fish sampled from Reënvoël Dam during November 2009 and again during a repeat sampling in January 2011. Similarly, pansteatitis could not be detected in fish sampled from van Ryssen Dam (Figure 3.2). Pansteatitis could also not be demonstrated in catfish sampled from the Levuvhu and Crocodile rivers (Table 3.1).

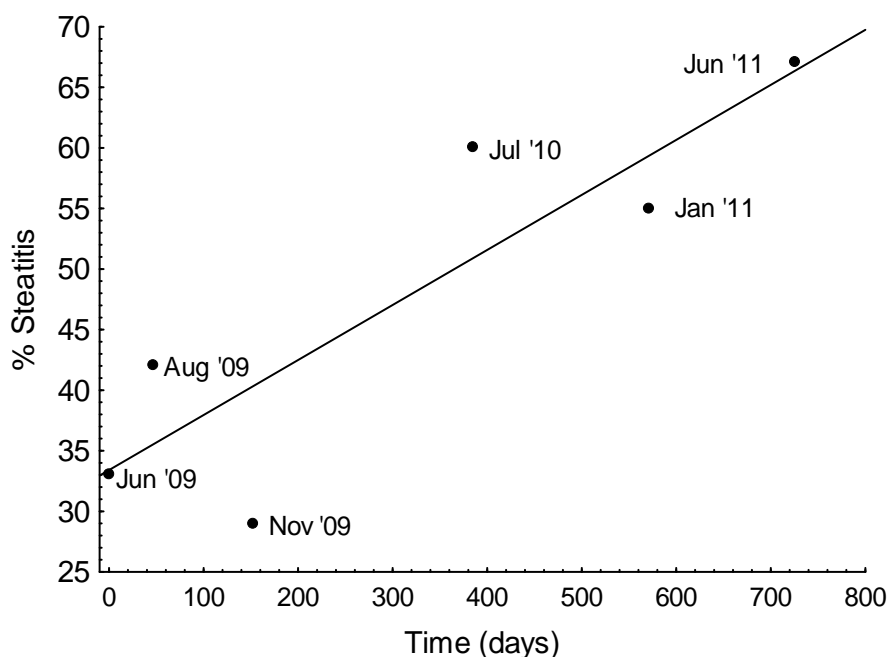


**Figure 3.2:** Macroscopic pansteatitis prevalence as percentage of sampled catfish from various sampling sites in the Kruger National Park during the period 2009-2011.



**Table 3.1:** Prevalence of macroscopically detectable pansteatitis lesions in the Olifants Gorge and other reference populations of catfish in and around KNP

Date	Sampling site	% fish with pansteatitis	Total fish sampled
June 2009	Olifants Gorge	33	9
August 2009	Olifants Gorge	43	14
November 2009	Olifants Gorge	29	21
November 2009	Reënvoël Dam	0	28
July 2010	Olifants Gorge	60	25
July 2010	Mamba Weir	5	20
July 2010	Engelhard Dam	10	21
July 2010	Sabiepoort	45	11
January 2011	Olifants Gorge	55	22
January 2011	Reënvoël Dam	0	13
January 2011	van Ryssen Dam	0	10
June 2011	Olifants Gorge	67	21
June 2011	Levuvhu River	0	14
June 2011	Crocodile River	0	20



**Figure 3.3:** Prevalence of pansteatitis in catfish sampled from various localities along the Olifants and lower Letaba rivers in the Kruger National Park from 2009 to 2011 (Correlation coefficient:  $r = 0.87$ , significance:  $p = 0.02$ ).

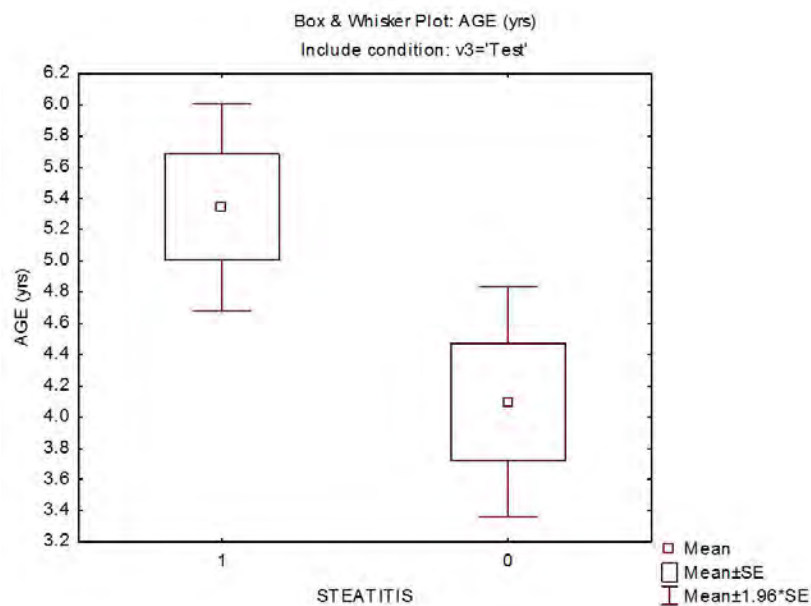
Most catfish from the Olifants Gorge, as well as from the Sabiepoort, stored relatively larger amounts of fat compared to catfish sampled from other localities in KNP. However the amount of fat carried was considerably less than that carried by the fish from Lunsklip Fisheries. A decline over time in amount of stored fat in catfish sampled from the Olifants Gorge was noted during repeat samplings between November 2009 and June 2011. Mesenteric fat made up 4.6% of body mass in the most obese specimen from the Olifants Gorge sampled during November 2009, whereas it only constituted 0.9% of body mass in the most obese specimen sampled during June 2011. By contrast, the most obese fish sampled from Lunsklip Fisheries carried more than 12% of body mass as mesenteric fat (see section 3.2.1.3). Fish sampled from the Olifants Gorge during June 2011 were distinctly leaner than fish sampled during July 2010 and several wasted fish were caught from the Olifants Gorge during the 2011 samplings. One of these fish was extremely emaciated but nevertheless had a reasonable amount of fat stored in the mesenteric adipose tissue. Pansteatitis was evident in the adipose tissue of this fish. Most catfish sampled from Engelhard Dam, Mamba Weir, Reënvoël Dam and van Ryssen Dam were lean (Table 3.2). Fish from the Levuvhu River carried more fat in their adipose tissues than fish sampled from the Olifants Gorge during the

same period, whilst fish from the Crocodile River were notably leaner than fish from the Olifants Gorge (Table 3.2).

**Table 3.2:** Mesenteric adipose tissue mass relative to body mass of catfish sampled from the Olifants Gorge and other sites on various dates. Olifants Gorge (OG), Engelhard Dam (EH), Mamba Weir (M), Reënvoël Dam (RV), van Ryssen Dam (FK), Levuvhu River (LUV) and Crocodile River (CR)

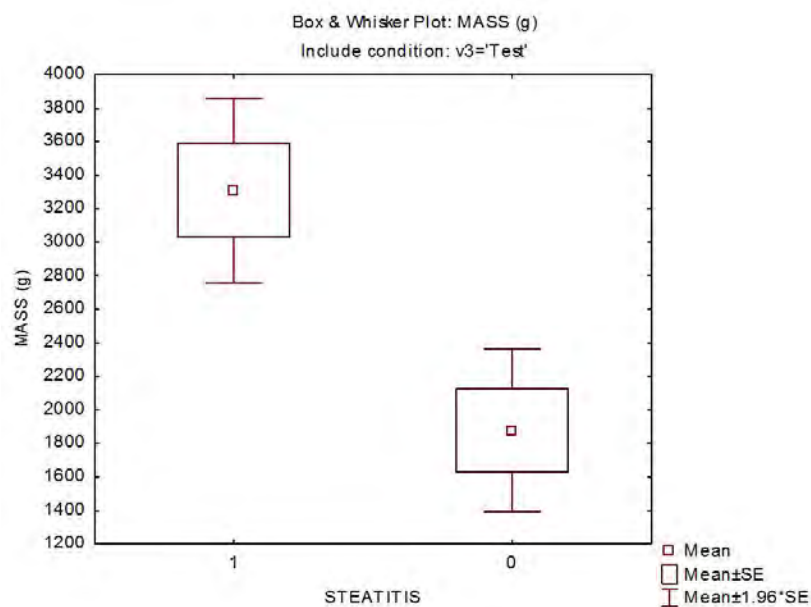
Sampling site	Date	Fat % of body mass				
		Mean	Standard Deviation	Sample variance	Range	n
OG	Nov-09	1.17	1.36	1.86	0.08-4.59	20
OG	Jul-10	1.12	1.02	1.05	0.00-3.68	25
OG	Jan-11	0.40	0.80	0.64	0.02-3.80	22
OG	Jun-11	0.18	0.20	0.04	0.02-0.88	21
EH	Jul-10	0.19	0.40	0.16	0.00-1.57	21
M	Jul-10	0.16	0.24	0.06	0.00-0.74	20
RV	Jul-10	0.32	0.29	0.08	0.00-0.88	13
FK	Jul-10	0.05	0.08	0.01	0.00-0.26	10
LUV	Jun-11	0.96	0.78	0.61	0.03-2.20	14
CR	Jun-11	0.14	0.16	0.03	0.00-0.53	20

Repeated samplings have taken place in the Olifants Gorge since 2009, and an increase in prevalence of pansteatitis was detected (Figure 3.3). The ages of catfish sampled from the Olifants Gorge ranged from 1 to 19 years, and pansteatitis was observed in catfish from 3 to 19 years old. Comparison of the number of fish with pansteatitis under 3 years of age with the number above 3 years indicated a significant effect of age on pansteatitis incidence in the Olifants Gorge (Chi-squared Test,  $p < 0.002$ ). A comparison between the mean ages of fish with and without pansteatitis in the Olifants Gorge indicated a higher frequency of pansteatitis in older fish ( $p = 0.021$ ) (Figure 3.4). Severity of pansteatitis, however, did not vary with age. There was also no variation in pansteatitis incidence between male and female catfish. Ages of catfish sampled from Reënvoël Dam, where no pansteatitis was found, similarly ranged from 1 to 19 years with both male and female fish represented.

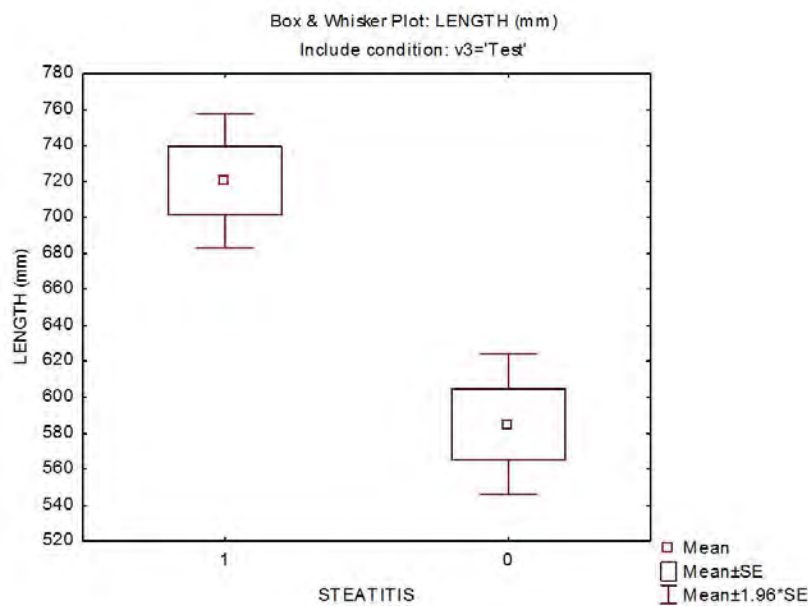


**Figure 3.4:** Box and whisker plot showing variation in age between catfish with and without pansteatitis sampled from all Olifants Gorge sites (1 denotes fish with pansteatitis incidence, 0 denotes fish without pansteatitis).

Pansteatitis also varied with mass and length in the Olifants Gorge catfish (Figures 3.5 & 3.6), and significant differences in prevalence of pansteatitis were noted between mass and length classes (Chi-squared Test,  $P < 0.001$ ). There was, however, no variation between condition factor and pansteatitis incidence (T Test,  $p = 0.59$ ).



**Figure 3.5:** Box and whisker plot showing variation in body mass between catfish with and without pansteatitis sampled from all Olifants Gorge sites (1 denotes fish with pansteatitis incidence, 0 denotes fish without pansteatitis).



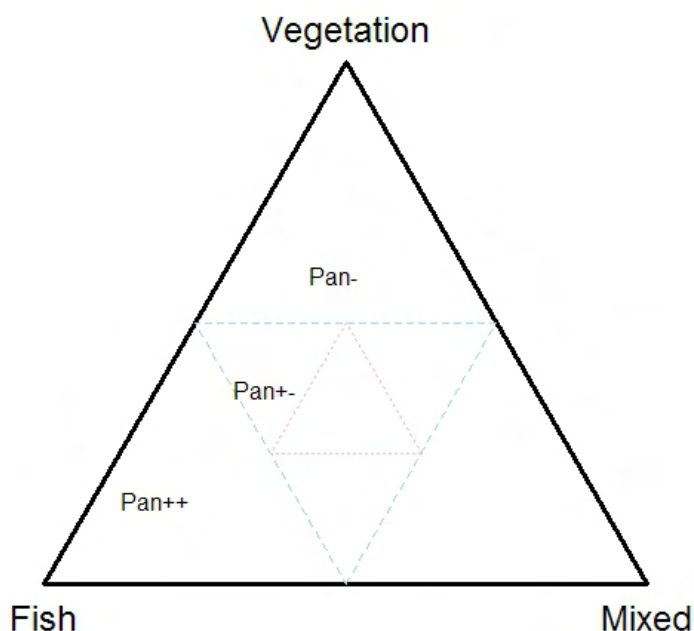
**Figure 3.6:** Box and whisker plot showing variation in body length between catfish with and without pansteatitis sampled from all Olifants Gorge sites (1 denotes fish with pansteatitis incidence, 0 denotes fish without pansteatitis).

### 3.2.1.2. Stomach content relative to prevalence

The observations on stomach content relative to pansteatitis prevalence in catfish in rivers and dams in the KNP have been accepted for publication in a manuscript that addresses the food-web of the respective aquatic ecosystems in the KNP using stable isotopes (Woodborne, Huchzermeyer, Govender, Pienaar, Hall, Myburgh, Deacon, Venter & Lückner 2012) [see Appendix A.3]. A further manuscript dealing with a comparison of lipid properties of healthy and pansteatitis-affected catfish relative to diet has been accepted for publication and is in press (Huchzermeyer, Osthoff, Hugo & Govender in press) [see Appendix A.4]. Both manuscripts have been attached to the thesis.

The sharptooth catfish is an omnivorous benthic scavenger and an active hunter. In the Olifants Gorge, catfish stomach contents consisted predominantly of fish. On the Mozambique border where the Olifants River flows into Lake Massingir and where the sand bottomed pools and rapids have been covered with clay deposits, stomach and intestinal content of sampled catfish consisted of algal detritus and clay. At those sampling sites where pansteatitis was prevalent in catfish, this was repeatedly linked to presence of fish remnants in the stomach contents. Although stomach content only revealed what had been ingested

prior to sampling, a relative relationship between fish in the diet and presence of pansteatitis existed as illustrated in the triplot in Figure 3.7.



**Figure 3.7:** Stomach content analysis of sharptooth catfish showing that the population with pansteatitis (Pan++) at a site where pansteatitis was prevalent had stomach contents with a higher proportion of fish than vegetation, or invertebrates and detritus (mixed) when compared with the population of fish that did not have pansteatitis (Pan+-) from areas that had pansteatitis prevalence, and the population from areas without pansteatitis prevalence (Pan-). (Triplot preparation courtesy of S. Woodborne, Centre for Scientific and Industrial Research, Pretoria).

Fish remnants in stomach content were often in an advanced stage of digestion and consisted of bones and scales from noticeably large fish as well as occasional pectoral spines of *Synodontis* spp. fish. In a few cases these spines had migrated through the stomach wall and were found lying in the mesenteric cavity with only a mild associated inflammatory reaction. Intestinal content was often considerable and appeared whitish grey and pasty in catfish where bones and scales were present in the stomach. This was distinct from the black brown intestinal content associated with invertebrate and plant stomach content. Almost all catfish sampled in the Olifants Gorge during the peak flow of January 2011 had full stomachs, the ingesta consisting of fish as well as insects and small reptiles that had been washed into the

river during the flood conditions. Despite the murky turbulent water, catfish appeared to feed with ease under these conditions. During the winter samplings when the water in the Olifants River is relatively clear far fewer sampled catfish had significant amounts of ingesta in the stomach.

Stomach content of catfish sampled from the Sabiepoort consisted mainly of fish remnants, although stomachs of several of these fish contained recently ingested crocodile fat with visible signs of steatitis still present. The stomachs of catfish sampled from Mamba Weir contained predominantly the fruit of sycamore fig trees, which overhang the embankment of this stretch of the river. Although more than half of sampled catfish from Reënvoël Dam had empty stomachs, invertebrate and mixed detritus, vegetation and fish were represented in the ingesta of the remaining fish. Recognizable remnants of Mozambique tilapia were found in the stomach content of most catfish sampled from van Ryssen Dam. The majority of catfish sampled from the Crocodile River during June 2011 had stomachs distended with filamentous algae. Microscopic examination of fluid expressed from the stomach contents revealed that large numbers of diatoms had been ingested with the filamentous algae. Stomach content of catfish sampled from the Levuvhu River, during June 2011, consisted of algae and sycamore figs.

### **3.2.1.3. Prevalence in a captive farmed population of catfish**

Lesions identical to those found in the adipose tissues of catfish from the Olifants Gorge, the Sabiepoort and Engelhard Dam were discovered by the author in a captive population of catfish at Lunsklip Fisheries. The majority of these fish had severe visible changes in the fat associated with pansteatitis (Table 3.3). This provided the study with an identified positive control for evaluation of gross pathology and histology observed in catfish in the KNP. Although pansteatitis was observed macroscopically in 66% of fish sampled from Lunsklip Fisheries, 95% of these fish showed steatitis on histological examination. Many of these fish had very large mesenteric fat reserves (Table 3.4).

**Table 3.3:** Prevalence of macroscopically detectable pansteatitis lesions in catfish sampled from a captive population at Lunsklip Fisheries (LK)

Date	Sampling site	% fish with pansteatitis	Total fish sampled
Nov-09	LK	66	21

**Table 3.4:** Mesenteric adipose tissue mass relative to body mass of catfish sampled from Lunsklip Fisheries (LK)

Date	Sampling site	Fat % of body mass				
		Mean	Standard deviation	Sample variance	Range	n
Nov-09	LK	4.61	3.45	11.89	1.01-12.07	21

These fish were from the remnants of a previously farmed population of catfish that had been retained in an earth pond. They were fed the untreated fish-waste from a trout slaughterhouse on the farm. The fat-rich innards of the trout were fed to an excess that left an oily scum, visible on the water surface along the edges of the dam. The stomach contents of these fish consisted largely of oily fish remnants. The fish carried considerably more mesenteric fat than the fish from the Olifants Gorge and other sampling sites (Tables 3.2 & 3.4). In many cases the fat was severely affected by pansteatitis. The sampled catfish were large, weighing from 2.82 to 11.5 kg and ranged in age from 5 to 13 years. On observing the dam in broad daylight, numerous large catfish could be seen swimming sluggishly near the surface with either the dorsal and tail fin or one pectoral fin protruding above the surface of the water. These fish appeared to have lost the negative buoyancy that is usual for this species. As these catfish were caught by scoop net, the sampling bias was towards weaker fish.

#### 3.2.1.4. Discussion of prevalence

Pansteatitis was identified in catfish sampled from the Olifants River at the confluence with the Letaba River where the Olifants River enters the 9 km long gorge that opens into Lake Massingir in Mozambique. This same area has been the epicentre of the recent crocodile mortalities. During repeat samplings, an increasing prevalence of pansteatitis affecting up to 67% of catfish in this section of river was identified. A lower prevalence of pansteatitis was found in catfish sampled from Engelhard Dam on the Letaba River a few kilometres upstream of the confluence with the Olifants River and in catfish sampled from Mamba Weir where the



Olifants River enters the western boundary of the KNP. In the Sabiepoort of the KNP, the Sabie River flows through a gorge before entering Lake Corumana in Mozambique. Here pansteatitis prevalence was similar to that in fish from the Olifants Gorge. Crocodile deaths from pansteatitis have also been observed in the Sabiepoort (D Govender, SANParks, Skukuza, pers. comm. 2010). It is well documented that the Olifants River, draining the eastern side of the Mpumalanga Highveld, has been extensively affected by anthropogenic activity (Ashton 2010; de Villiers & Mkwelo 2009; Heath *et al.* 2010). There is, however, little similarity in pollution impacts between the respective catchments of the Sabie, Letaba and Olifants rivers. Pansteatitis could not be detected in fish from the Levuvhu and Crocodile rivers, both of which drain catchment areas subject to divergent anthropogenic impact and neither of which are dammed in or near the KNP. Neither could pansteatitis be demonstrated in fish from Reënvoël Dam, which is an entirely rain-fed water body within KNP and distant from potential pollution sources affecting the Olifants River. It is possible that pansteatitis in catfish in Engelhard Dam was associated with upstream movement of fish from the Olifants Letaba confluence.

Catfish are known to prey on a wide variety of organisms including invertebrates and fish, and their feeding preferences change with size, fish being the preferred prey of large catfish (Bruton 1979). They are also known to switch their feeding activity to prey on the most abundant and vulnerable fish species available (Bruton 1979). In the Olifants Gorge, pansteatitis was positively correlated to age, weight and length of catfish and no pansteatitis was found in fish less than 3 years of age. As length and weight were correlated to age, it is likely that larger catfish were able to catch and kill larger prey. This may imply a change in preference of food source when catfish reach a certain size in the Olifants Gorge and in the Sabiepoort. This was reflected in the stomach content analysis, which indicated a greater prevalence of fish in the diet of catfish with pansteatitis when compared to catfish without pansteatitis. Stable isotope analysis of muscle tissue of catfish from sites with pansteatitis indicated a dietary shift by catfish to a higher trophic level, and a change in feeding behaviour to a limited range of species (Woodborne *et al.* 2012) [see Appendix A.3]. In most cases, the fish remnants in the stomachs were in an advanced stage of digestion and it was not possible to identify prey species.

The debilitating effects of advanced pansteatitis were evident in the captive catfish from Lunsklip Fisheries. The large amounts of fat trapped in the adipose tissues and impaired

muscular activity of these fish appeared to interfere with the sounding abilities of the fish. Healthy catfish prefer to remain close to the bottom of pools and rivers and are seldom seen near the surface of water bodies during the daytime, other than to gulp air into the suprabranchial air-breathing organ. Sluggish behaviour and positive buoyancy in pansteatitis-affected fish make them easy prey in a habitat where crocodiles occur.

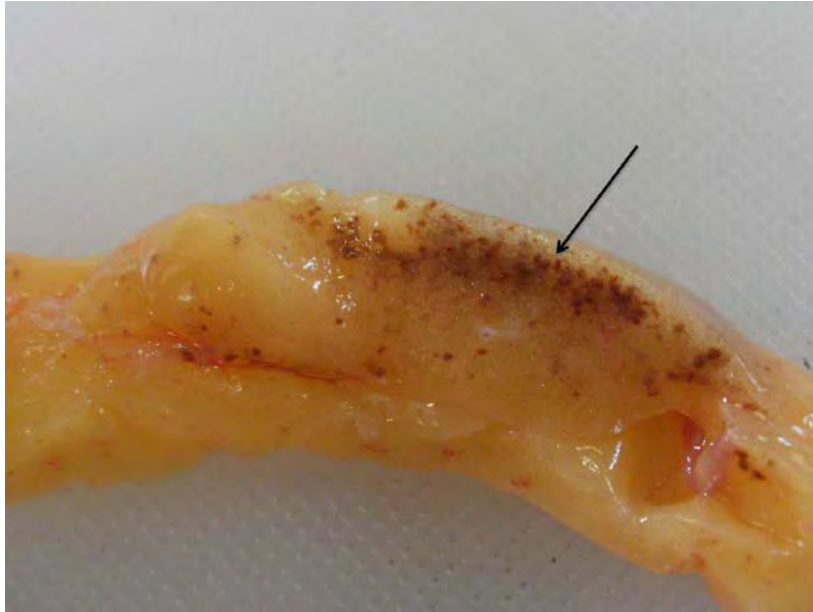### **3.2.2. Pathology of pansteatitis in catfish**

#### **3.2.2.1. Gross pathology of pansteatitis**

The detailed pathology and histopathology of the organs and the specific lesions associated with fat necrosis in catfish from the Olifants Gorge have been published (Huchzermeyer *et al.* 2011) and the manuscript is attached to the thesis (see Appendix A.1). A report on the findings of a preliminary study to identify pathology present in fish in the lower Olifants River has been prepared for the Water Research Commission and is also attached to the thesis (see Appendix B.1).

Necrosis and associated steatitis was observed repeatedly in the adipose tissues and, other than severity, there was no distinction between the lesions observed in catfish sampled from the Olifants Gorge, Engelhard Dam, Sabiepoort and the positive reference population at Lunsklip Fisheries. Steatitis lesions presented as distinct white and brown spots (Figure 3.8a) consisting of small focally disseminated to coalescing granulomata up to 5 mm in diameter. In more advanced cases lesions were characterized by a brown colour, sometimes with an orange coloured centre. Affected mesenteric fat, in severe cases, had a rubbery consistency, and brown granulomata were confluent throughout the fat (Figures 3.8b & 3.8c).

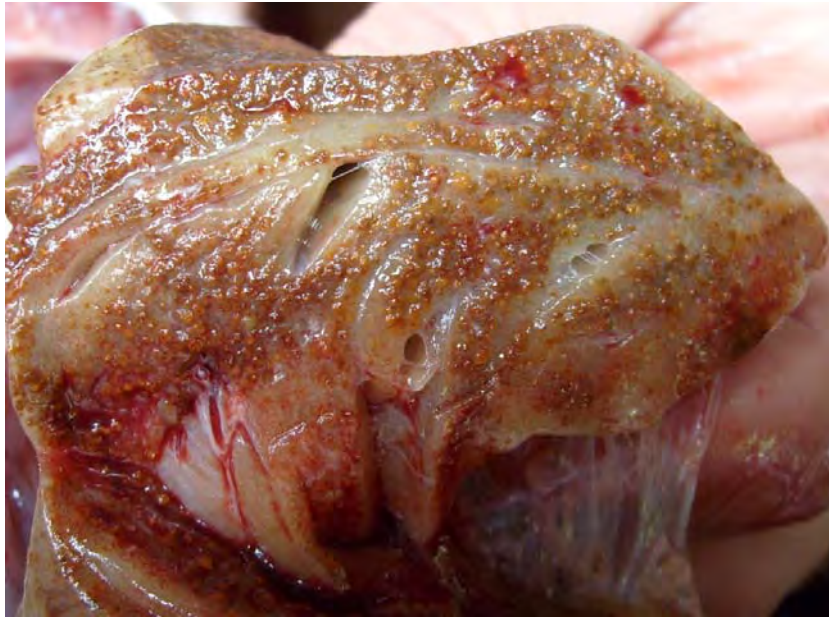In catfish with pansteatitis from both the Olifants Gorge and Lunsklip Fisheries, lesions were mostly restricted to the mesenteric fat tissue. In severely affected fish the caudal section of the mesenteric fat body was often adherent to the hind gut and the caudal section of the gonads (Figure 3.9). In milder cases granulomata were more densely concentrated on the parietal aspect of the fat body closest to the mesenteric insertion (Figure 3.8a). Layers of fat with differing severity of steatitis were observed in some fish. Presence of both coalescing granulomata and scarring of the adipose tissues together with more recent lesions characterized by focal brown spots in the fat appeared to indicate an on-going incitement of fat necrosis in catfish of the Olifants Gorge. Occasional fish showed steatitis in the pectoral fat cushion (Figure 3.10a) and the intermuscular fat (Figure 3.10b & 3.10c). Steatitis could not be demonstrated in the epicardial fat. In fish with generalised pansteatitis, lesions could however be demonstrated in the intracranial fat surrounding the brain (Figure 3.10d).



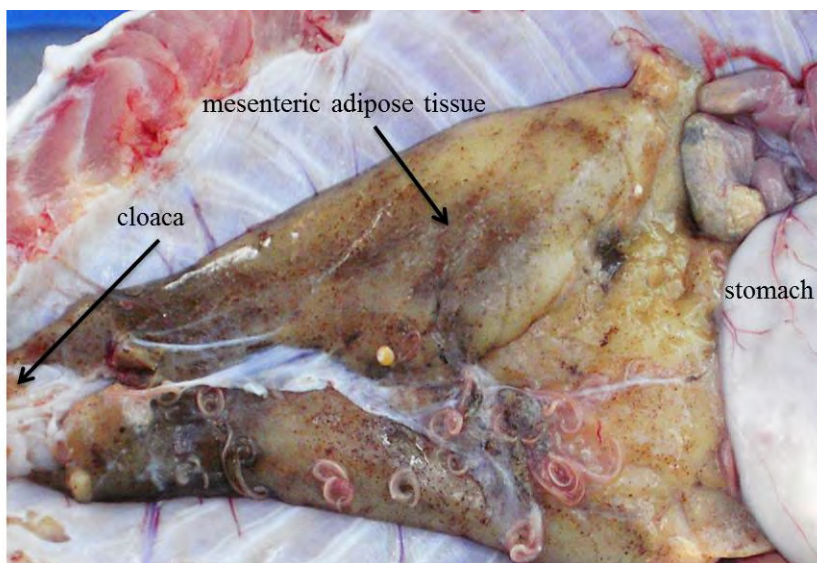
**Figure 3.8a:** Early steatitis lesions in catfish sampled from the Olifants Gorge during July 2010. Note the small sharply circumscribed foci of fat cell necrosis and associated ceroid deposition imparting the characteristic brown colour (arrow).



**Figure 3.8b:** Cross-section of mesenteric fat with advanced pansteatitis from a catfish sampled from the Engelhard Dam during July 2010. Note the diffuse brown granular appearance of the fat, the rough surface and virtually total absence of normal appearing fat.

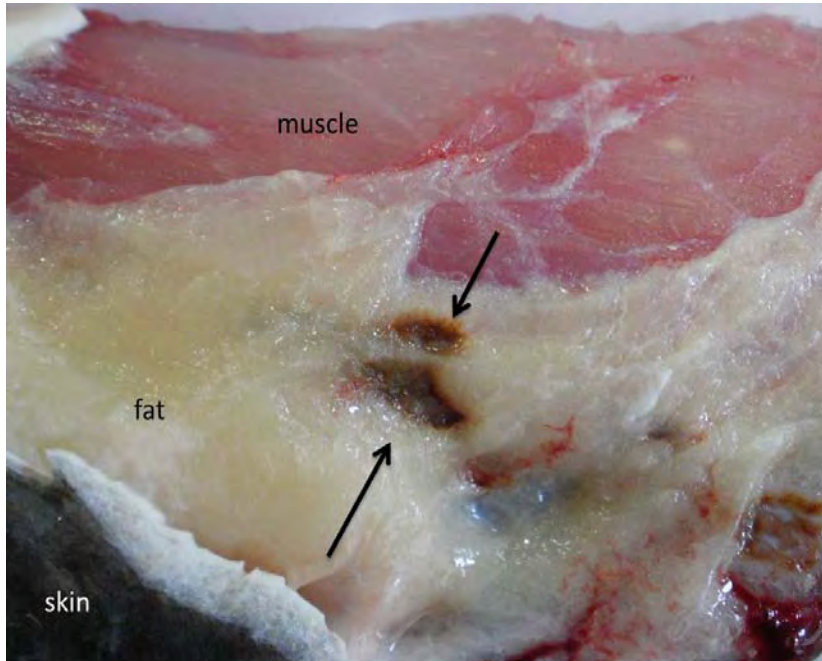


**Figure 3.8c:** Cross section of mesenteric adipose tissue from a catfish collected from the Olifants Gorge in November 2009 showing typical severe pansteatitis. Note brown granuloma formation within the adipose tissue.

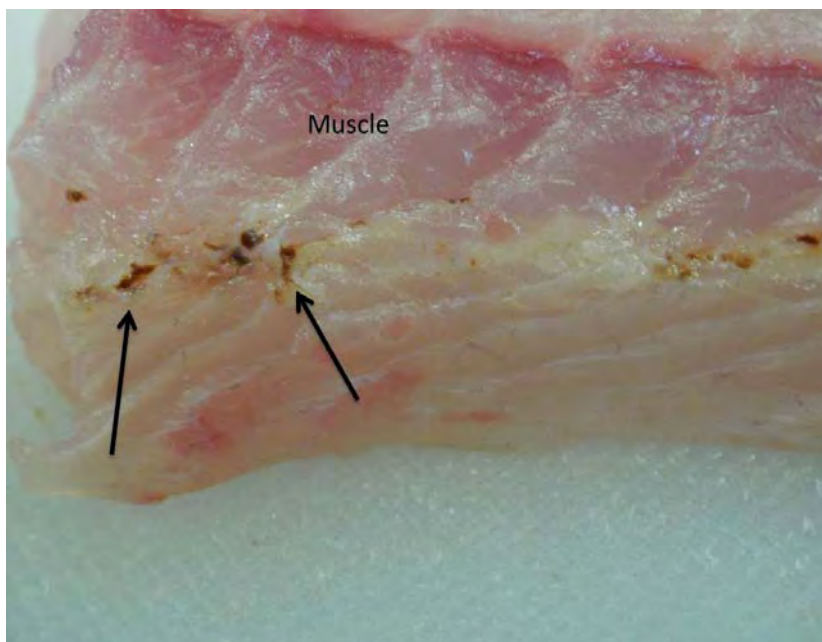


**Figure 3.9:** Pansteatitis of the mesenteric adipose tissues in a catfish sampled from the Olifants Gorge during June 2011. Note that the caudal portion of the mesenteric fat body appears more severely affected.

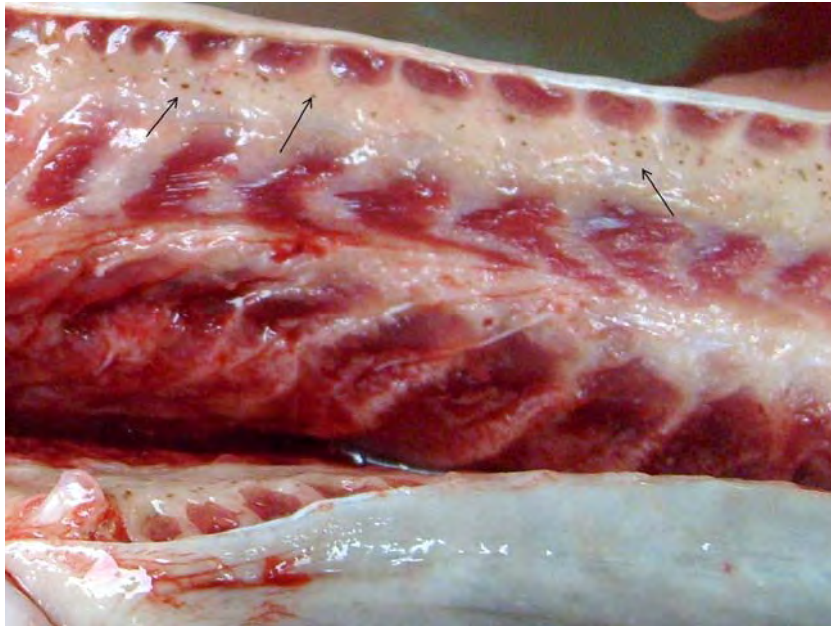



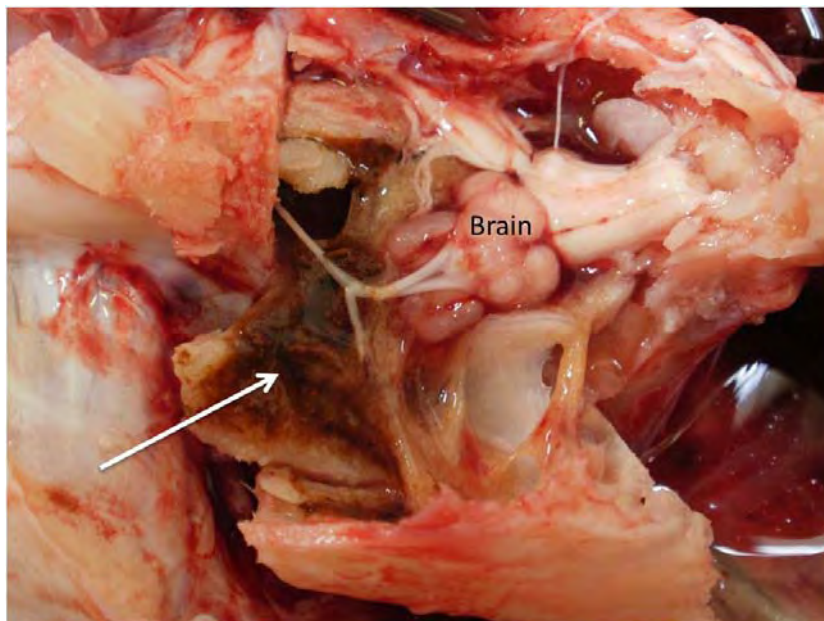
**Figure 3.10a:** Focal steatitis (arrows) in the pectoral fat of a catfish sampled from the Olifants Gorge during July 2010.



**Figure 3.10b:** Focal steatitis (arrows) in the intermuscular fat of a catfish sampled from the Olifants Gorge during July 2010.



**Figure 3.10c:** Focal areas of steatitis (arrows) in the intermuscular fat of a catfish sampled from Lunsklip Fisheries during November 2009.

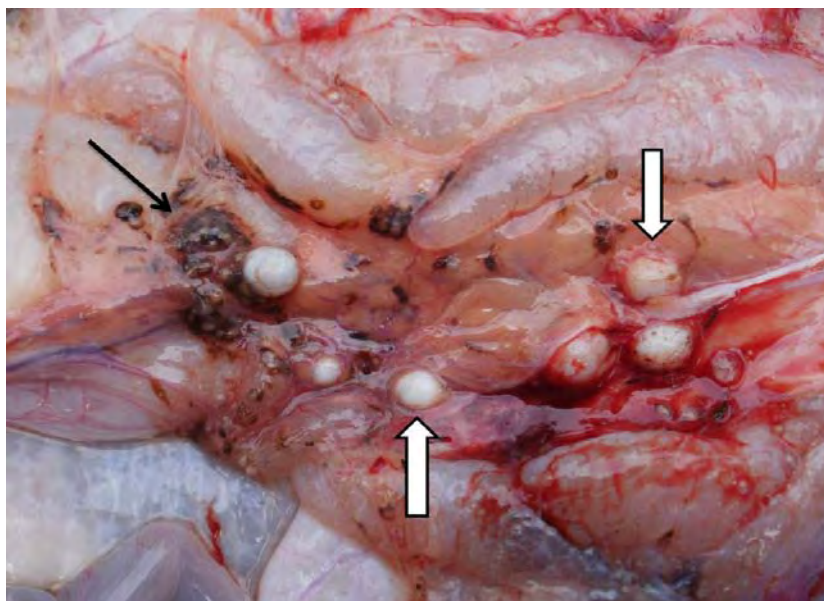


**Figure 3.10d:** Generalised steatitis in the fat surrounding the brain of a catfish sampled from the Olifants Gorge during July 2010. Note brown discolouration of fat (arrow) adhering to the opened cranium.

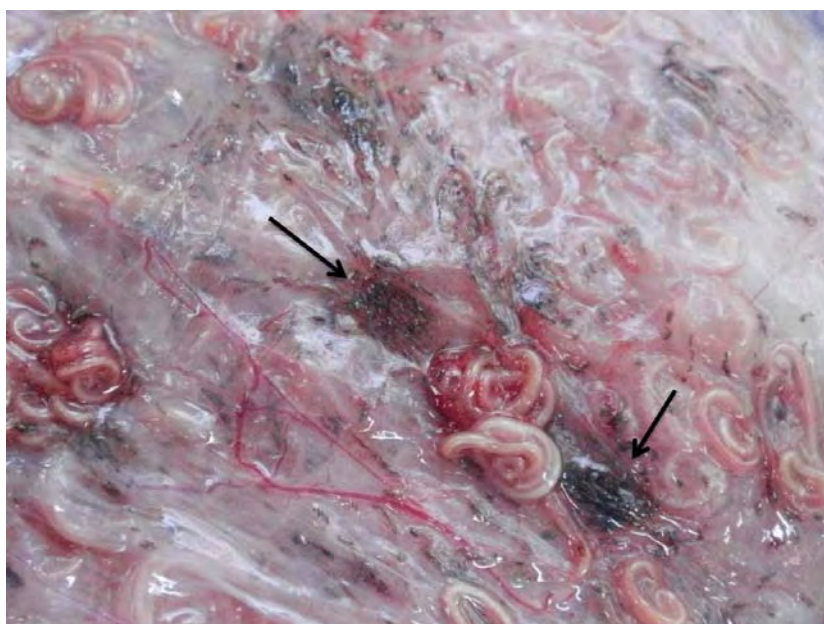Catfish collected from the Olifants Gorge and lower Letaba River during the samplings prior to November 2009 presented with large amounts of variably coloured fat in the body cavity and between the muscles of the tail. The variation in colour, from a cream white to dark yellow, continued to characterize the mesenteric fat of catfish from all samplings in the Olifants Gorge, despite the reduction in quantity of mesenteric fat noted during subsequent samplings (Table 3.2). There was no correlation between fat colour and pansteatitis. Microscopic examination of histological sections of fat from sampled fish confirmed the macroscopic diagnosis of pansteatitis (Figures 3.16a and 3.16b).

Incidental pathology in adipose tissue associated with presence of parasites was noted in many fish and could be differentiated from changes associated with pansteatitis. Cysts of digenean parasites, varying in size from 2 to 15 mm in diameter, were occasionally noted in the mesenteric adipose tissues of fish sampled from the Olifants Gorge. Cysts mostly appeared as well circumscribed, hard, white nodules, sometimes focally disseminated throughout the mesenteric fat (Figure 3.11). On incision they consisted of a dense connective tissue capsule surrounding a central parasitic larva. In some cases an irregular brown discolouration as a result of melanin deposition was noted in the adjoining tissue. Such granulomata were distinguishable from those caused by fat necrosis. *Contracaecum* spp. larval nematodes were present in variable numbers within the peritoneal cavity of most fish sampled from the Olifants Gorge. Brown discolouration from melanin deposition in focal areas of the mesenteries overlying the mesenteric fat was occasionally noted in the presence of severe infestation with *Contracaecum* spp. larvae. This was particularly evident in catfish sampled from van Ryssen Dam (Figure 3.12). The dark colour associated with melanin deposition around larval nematodes and digenean trematodes differed distinctly from the discolouration associated with pansteatitis. Both lipopigment and ceroid were absent from such lesions.





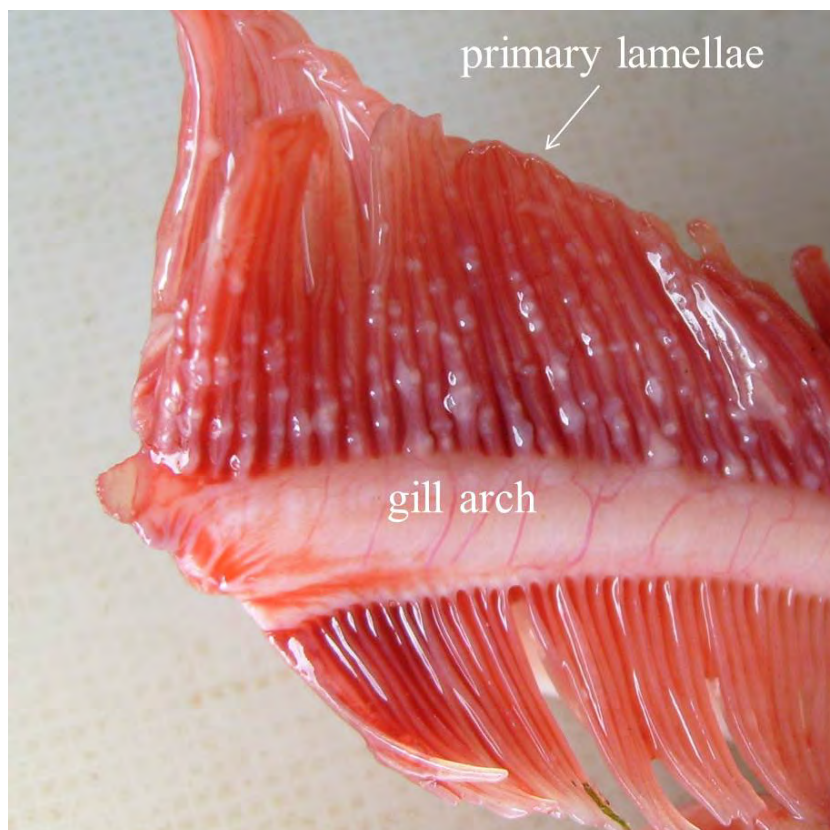**Figure 3.11:** Melanin deposition (black arrow) associated with digenean trematode cysts (block arrows) in the caudal mesenteric fat between the male accessory sexual glands of a catfish sampled from Reënvoël Dam in KNP.



**Figure 3.12:** Melanin deposition (arrows) in the vicinity of larval nematodes in the mesentery overlying the mesenteric fat in a catfish sampled from van Ryssen Dam.

Gills of catfish sampled from the Olifants Gorge generally appeared to be in a good condition. During the early samplings in the Olifants Gorge during 2008 and 2009, gills of

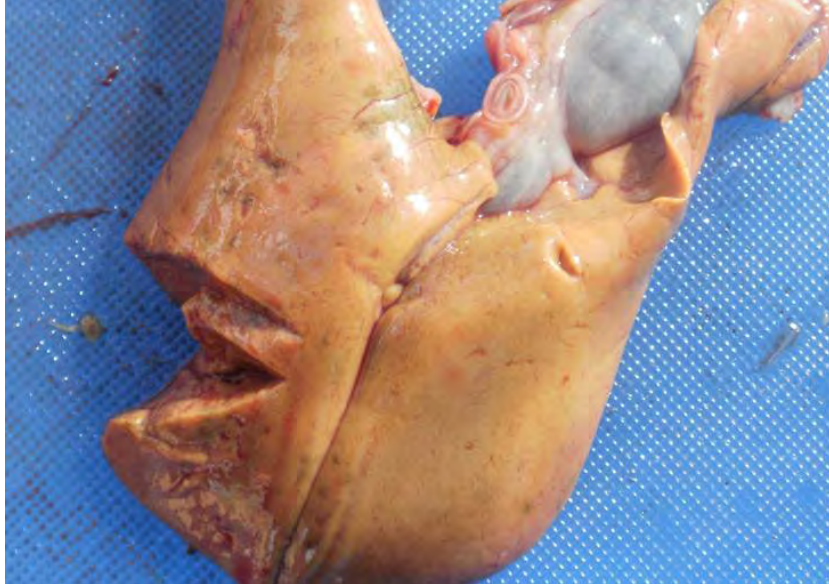many catfish appeared paler than normal and mildly hyperplastic. During later samplings this was no longer evident. Furthermore gill pallor appeared to be affected by temperature of the holding water and length of time that fish were kept in the holding tanks. With warmer water and longer holding periods gills appeared paler. Deformities of the gill cartilage associated with intense infestation by digenean trematode metacercariae were evident in some fish sampled from the Olifants Gorge, Mamba Weir, Engelhard Dam and Reënvoël Dam (Figure 3.13).



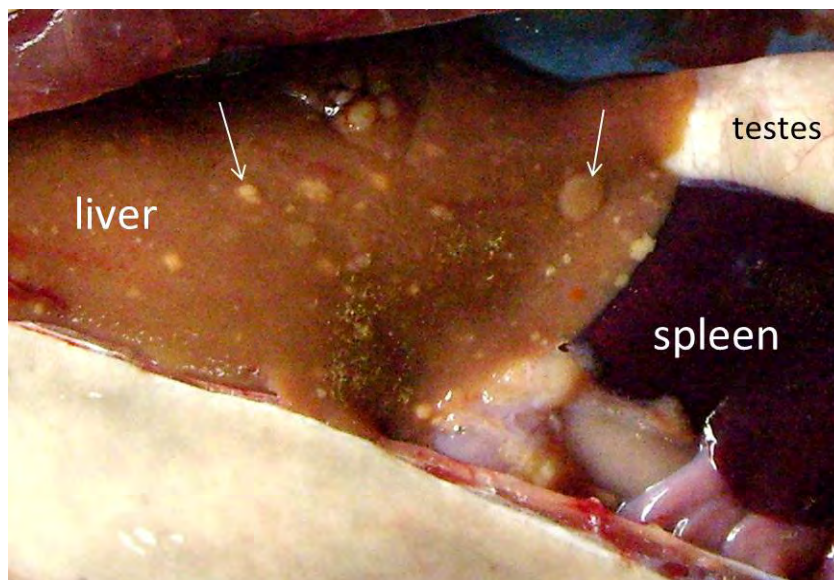
**Figure 3.13:** Gill arch of catfish sampled from the Olifants Gorge during November 2009 showing severe infestation of the cartilage of the primary gill lamellae by encysted digenean trematode metacercariae.

Livers of fish from the Olifants Gorge varied in colour but appeared more orange, fatty and swollen than in fish sampled elsewhere (Figure 3.14a). Livers of fish with good fat reserves often showed small focal deposits of fat on the surface (Figure 3.14b). Pale zones, sometimes observed in parts of the liver, occasionally extended into the hypodermal lobe (Figure 3.14c). Most of the pansteatitis-affected fish from the Olifants Gorge and Lunsklip Fisheries

had enlarged and rounded spleens with a rough surface (Figure 3.15a & 3.15b); the healthy spleen of catfish is an oval flat structure with sharp edges and a smooth surface. Atrophy of the pancreas was evident macroscopically in fish suffering from pansteatitis.

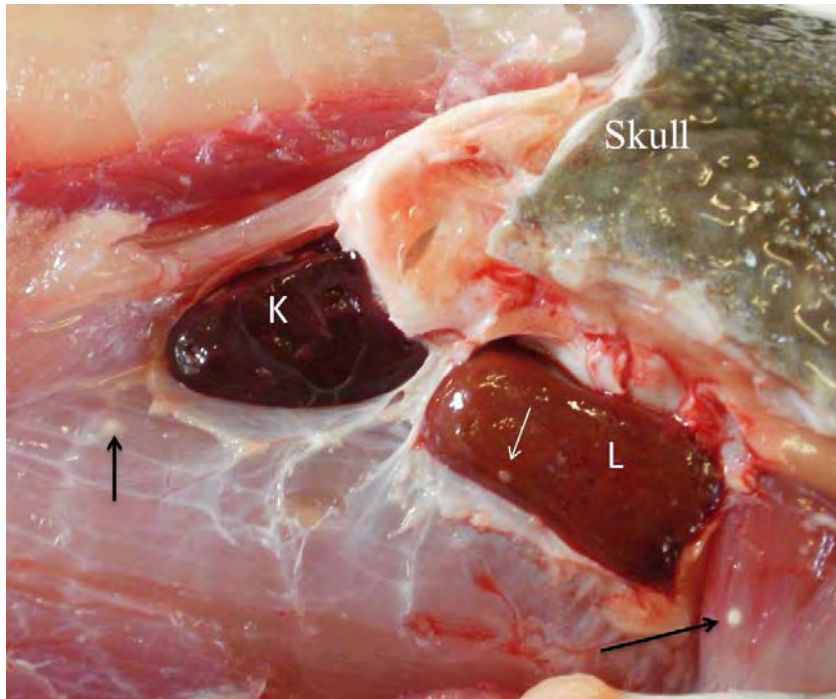


**Figure 3.14a:** Swollen fatty liver of a catfish suffering from pansteatitis, sampled from the Olifants Gorge during June 2011.

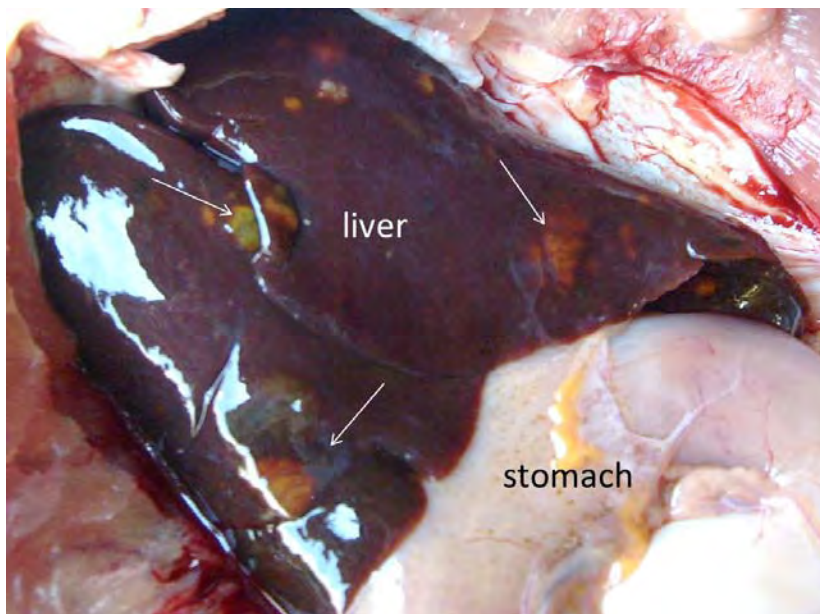


**Figure 3.14b:** Focal fat deposits beneath the liver capsule from a catfish with pansteatitis sampled from Lunsklip Fisheries during November 2009.

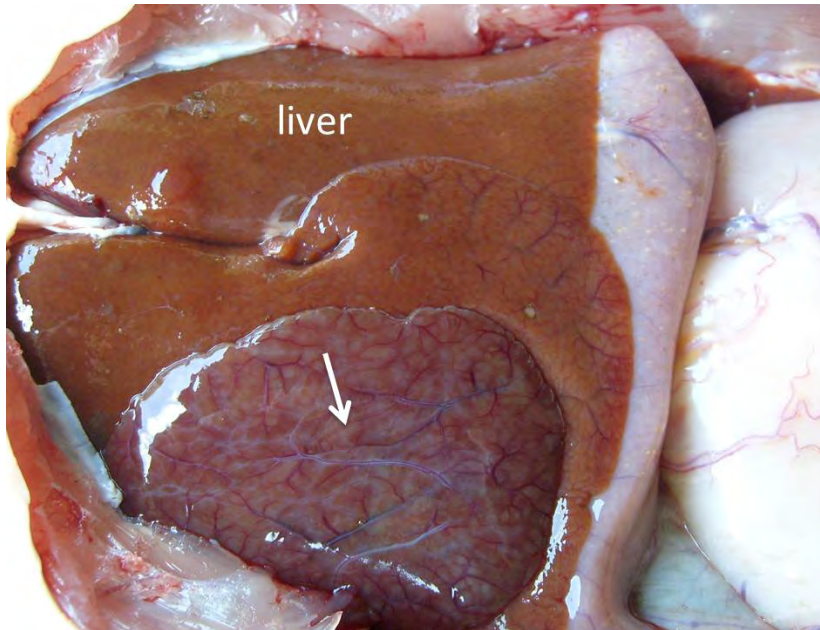




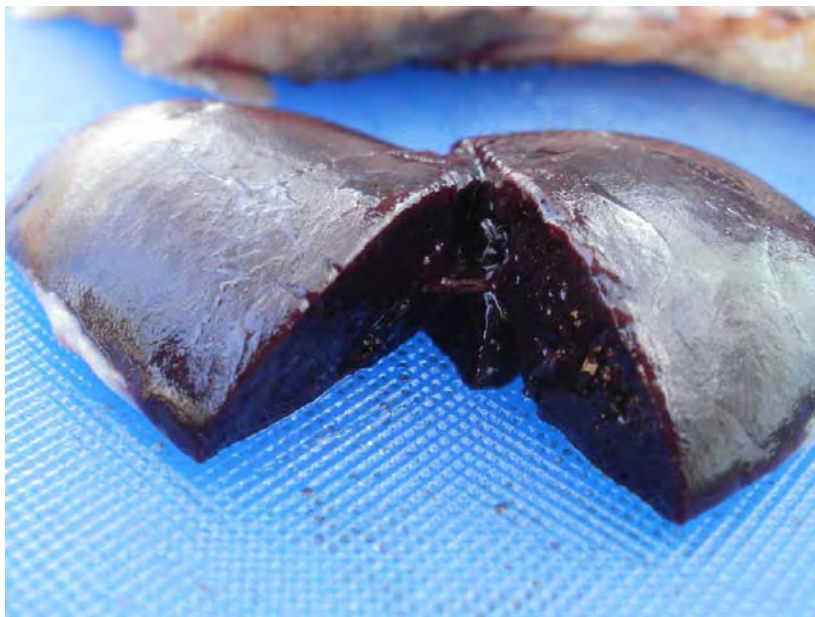
**Figure 3.14c:** Position of the external lobes of the liver (L) and cranial kidney (K) beneath the pectoral fat cushion caudoventral to the caudal margin of the skull of sharptooth catfish. Note the focal fat deposits visible on the surface of the liver in this catfish sampled from the Olifants Gorge. Arrows point to encysted digenean trematode larvae in the musculature.



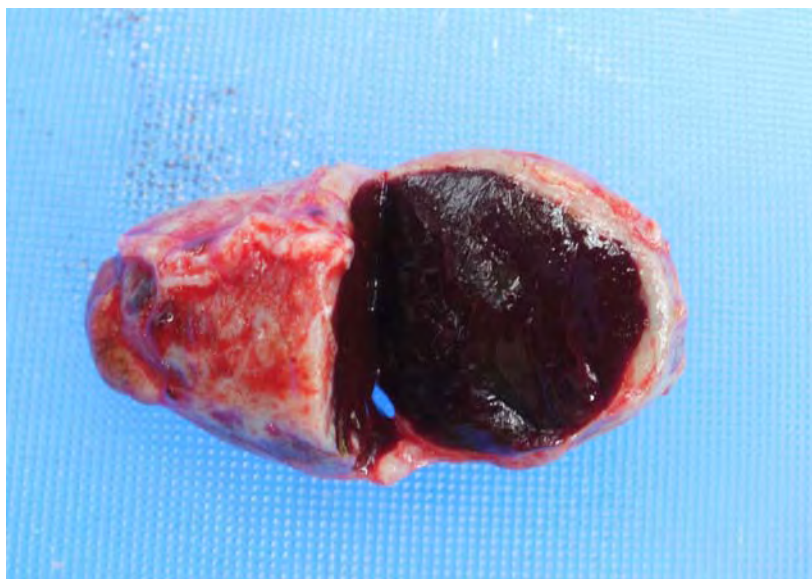
**Figure 3.14d:** Liver from a catfish sampled from Reënvoël Dam during November 2009. Arrows show damage associated with parasitic cysts in the liver parenchyma.



**Figure 3.14e:** Outgrowth of regenerating hepatic tissue (arrow), probably associated with parasitism, in a liver from a catfish sampled from Reënvoël Dam during November 2009. Note the normal brown colour of the liver.



**Figure 3.15a:** Enlarged spleen of a catfish from the Olifants Gorge suffering from pansteatitis.



**Figure 3.15b:** Spleen of a catfish from Lunsklip Fisheries suffering from severe chronic pansteatitis showing prominent capsular thickening and splenomegaly. Note the rounded appearance of the normally flat spleen.

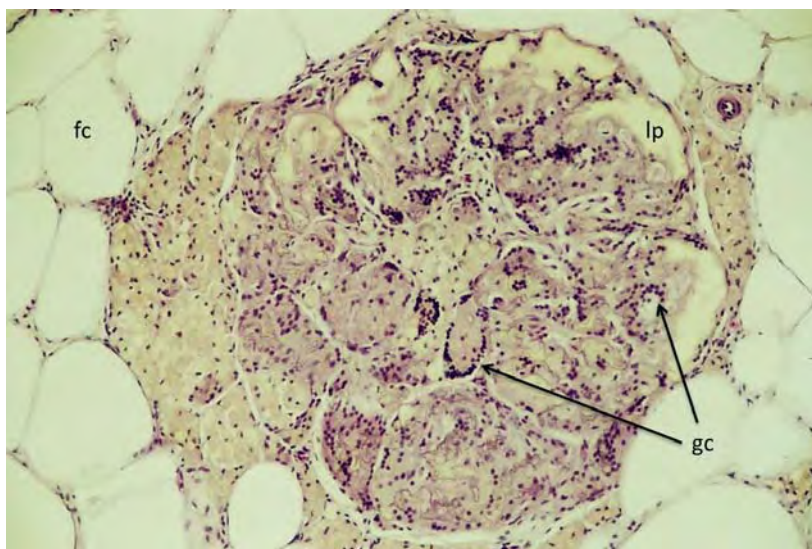
Catfish sampled from Reënvoël Dam showed no pansteatitis and were used as a negative control population (Table 3.1). The gills of catfish sampled from Reënvoël Dam during November 2009 appeared normal and in good condition despite heavy parasite burdens. Livers showed no fatty change, but varying pathology was observed associated with high levels of parasitosis, including outgrowths of regenerating liver tissue on the dorsal and ventral surface of some livers (Figures 3.14d & 3.14e). *Contracaecum* spp. larval nematodes were present in variable numbers within the peritoneal cavity of most catfish sampled from Reënvoël Dam, and parasitic granulomata were frequently present in large numbers in the mesenteric adipose tissue. Brown melanisation of focal areas of the mesenteries overlying the mesenteric fat in the presence of *Contracaecum* spp. larvae and in the vicinity of larval digenean trematode cysts was occasionally noted (Figure 3.11). Compared to other sampling sites, fish from Reënvoël Dam carried the heaviest burdens of digenean trematode cysts in the organs and musculature. Similar deposits of melanin were observed in association with heavy *Contracaecum* spp. larval burdens in catfish from van Ryssen Dam (Figure 3.12).

### 3.2.2.2. Histopathology of pansteatitis



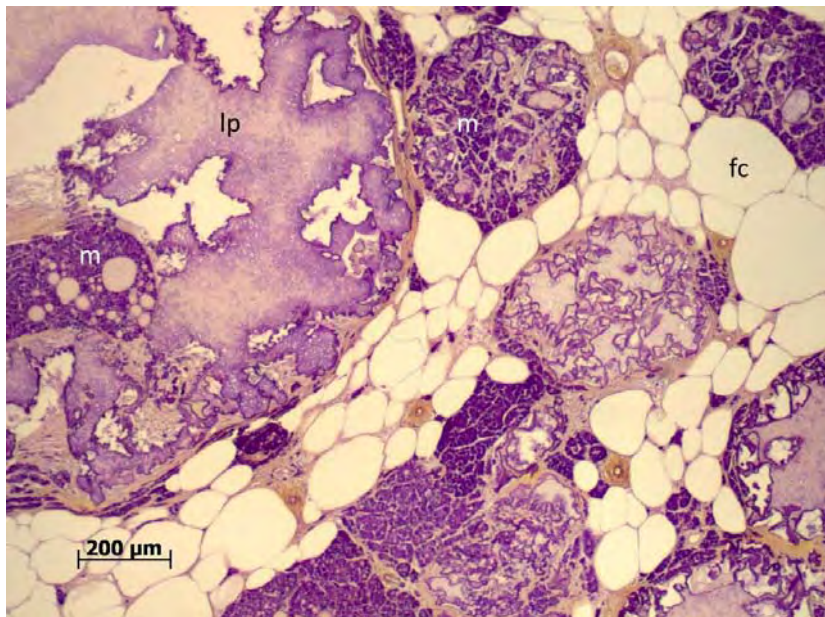
### 3.2.2.2.1. Histopathology of the adipose tissues

Various granulomatous reactions were observed in the fat tissues of catfish. Parasitic granulomata were distinguishable from foci of inflammation and granuloma formation associated with non-parasitic causes. The histological appearance of non-parasitic granulomata in the adipose tissues was typical of lesions expected with steatitis (Figures 3.16a & 3.16b). These lesions were similar in appearance in all fish sampled with macroscopic pansteatitis, including the fish suffering from nutritional pansteatitis at Lunsklip Fisheries.



**Figure 3.16a:** Giant cell formation (arrows) in a steatitis lesion in adipose tissue from a catfish sampled from the Olifants Gorge in July 2009. Giant cells (gc), lipopigment (lp), adipocytes (fc) (H&E X100).



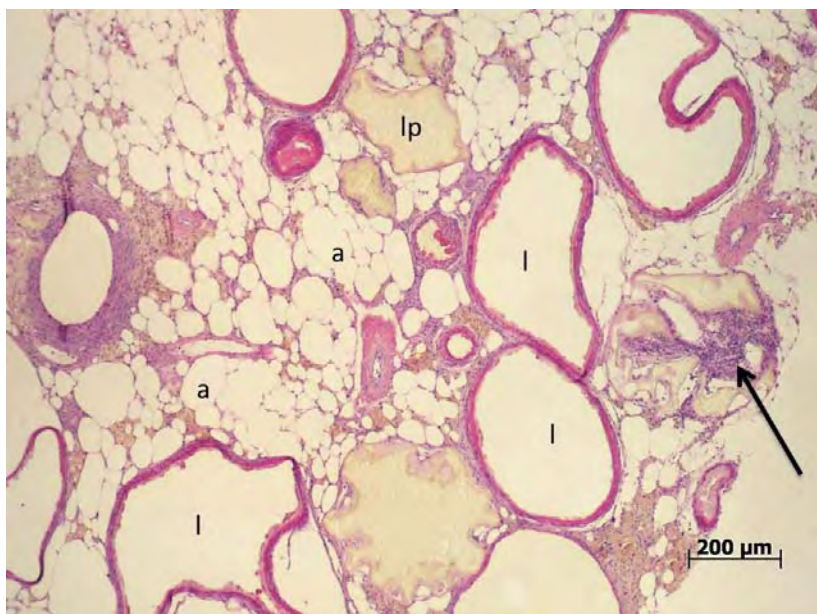

**Figure 3.16b:** Positive staining ceroid pigment (purple) within the lipopigment remnants (lp) of ruptured adipocytes and macrophages (m) in mesenteric fat of a catfish sampled from the Olifants Gorge during November 2009. Adipocytes (fc) (GAF).

In haematoxylin and eosin stained sections of affected fat, varying sized foci consisting of ruptured adipocytes contained a characteristic pigment identified as extracellular ceroid-type (ECC) lipopigment (Elleder 1991), also called preceroid (Jolly & Dalefield 1990). This pigment, typical of oxidative damage to fat cells, appeared as yellow, granular and refractive inclusions of varying size. ECC lipopigment was also observed to be phagocytised by the macrophages surrounding steatitis lesions. Necrotic adipocytes and associated cell breakdown debris were surrounded by a dense mass of macrophages containing intracellular ceroid (Figure 3.16b). The lesions were associated with the presence of variable numbers of fibroblasts and connective tissue deposition. However, macrophage aggregations associated with fat cell necrosis in the adipose tissues did not contain haemosiderin (Table 3.5). Lesions were focally disseminated throughout the affected mesenteric adipose tissue and represented the brown granulomata noted macroscopically. Lipopigment- and ceroid-containing macrophage aggregations within the interstitium of the fat tissues in the absence of adipocyte necrosis were noted in a few fish, and were considered to be indicative of mild or early oxidative damage to the fat. Presence of ceroid in the macrophages was confirmed by staining with GAF (Figure 3.16b) and PAS stains. Multinucleate Langhans giant cells were

invariably associated with the inflammatory response surrounding necrotic areas of fat (Figure 3.16a).

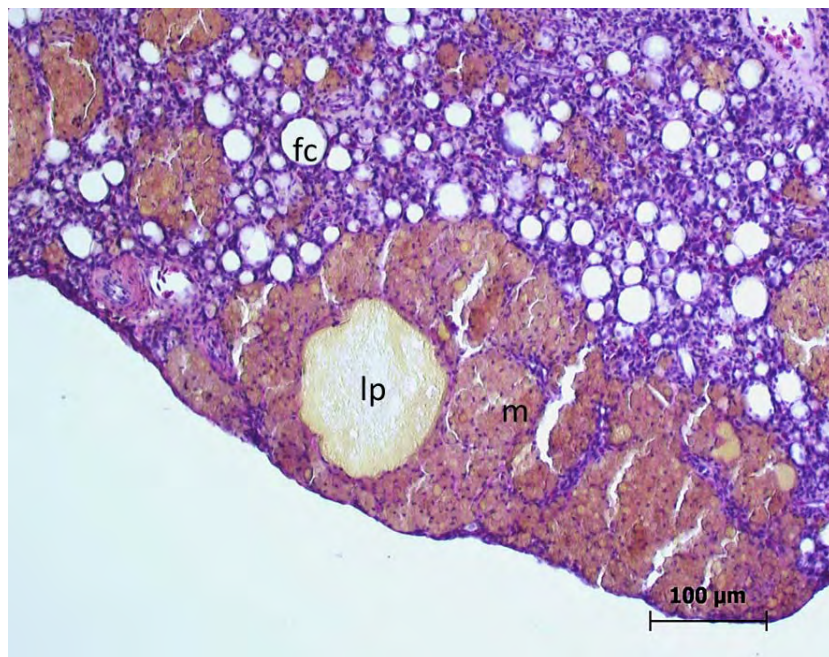
In some lesions, smaller macrophages were arranged in the form of a sheath surrounding the ruptured fat cells. Advanced cases presented with a clear or lipopigment containing central lacuna surrounded by organised layers of epithelioid cells that in places coalesced and became embedded in fibrous connective tissue (Figure 3.16c). Clear lacunae were an artefact of sectioning where the central pigmented area of fat breakdown products had been lost during sectioning.



**Figure 3.16c:** Advanced stage of fat necrosis and steatitis in mesenteric fat of a catfish sampled from the Olifants Gorge during June 2011. Note the apparently empty lacunae (l) where necrotic remnants of oxidised fat (lp) have been lost during processing, surrounded by a macrophage sheath. Adipocytes (a), foreign body giant cells (arrow) (H&E).

Lesions in the adipose tissues were focal and often roughly circular in shape in mild cases, and disseminated and coalescing throughout the adipose tissue in severe cases. Surrounding adipocytes often appeared normal, although in severe cases they were reduced in number and displaced by the associated inflammatory reaction.

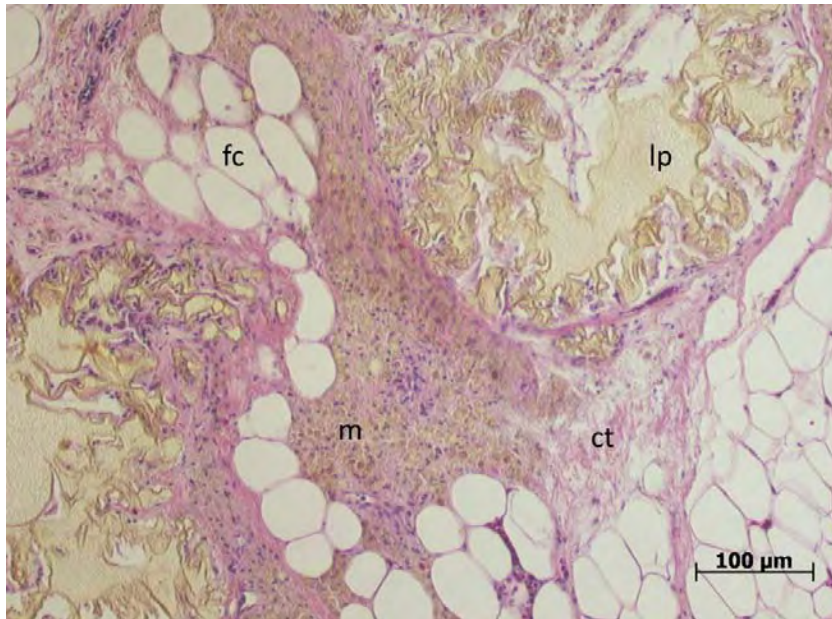
Steatitis was observed in both atrophied adipose tissue (Figure 3.16d) and in adipose tissue where adipocytes were replete with fat. The focal distribution of granulomata in mildly affected fish resulted in lesions sometimes being missed during the sectioning process. Such cases, although positive for pansteatitis on macroscopic evaluation, could not be identified on histological evaluation alone.



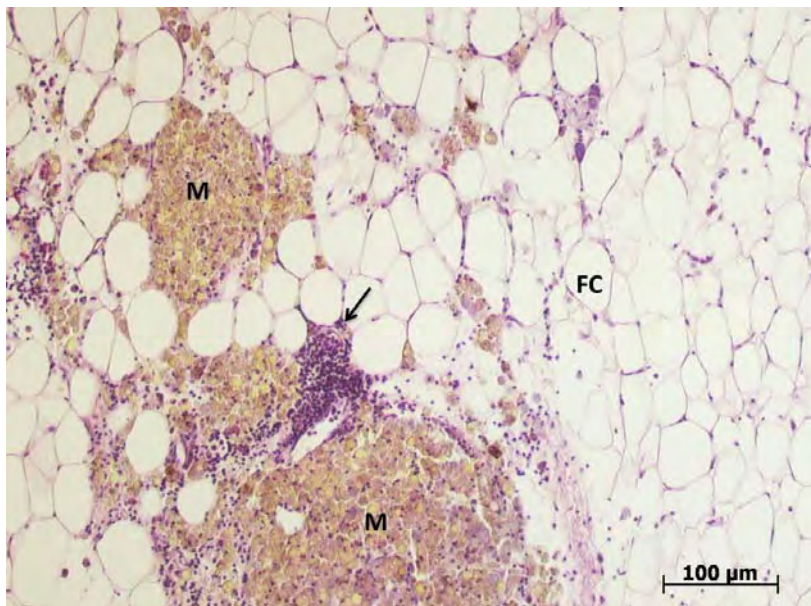
**Figure 3.16d:** Atrophied mesenteric adipose tissue showing inflammation typical of steatitis in a catfish sampled from the Olifants Gorge during June 2011. Note small size of adipocytes (fc) and aggregates of macrophages (m) containing ceroid, surrounding areas of fat necrosis containing lipopigment (lp) (H&E).

In many catfish with pansteatitis, only the mesenteric adipose tissues were affected. Where other fat tissues were affected, lesions in these were less severe than in the mesenteric fat. In a small number of catfish with pansteatitis the fat surrounding the brain and the pectoral adipose tissue was affected. Lesions in the pectoral fat appeared similar to those in the mesenteric fat (Figure 3.17a). In the intracranial fat the large areas of extracellular ceroid-type lipopigment, noted in association with steatitis in other adipose tissues, were absent, and the lesions consisted of dense aggregations of ceroid- and lipopigment-containing macrophages and a mild, sometimes focal, mixed inflammatory cell infiltration (Figure 3.17b). A fibroblast and connective tissue reaction was absent from lesions in this fat.



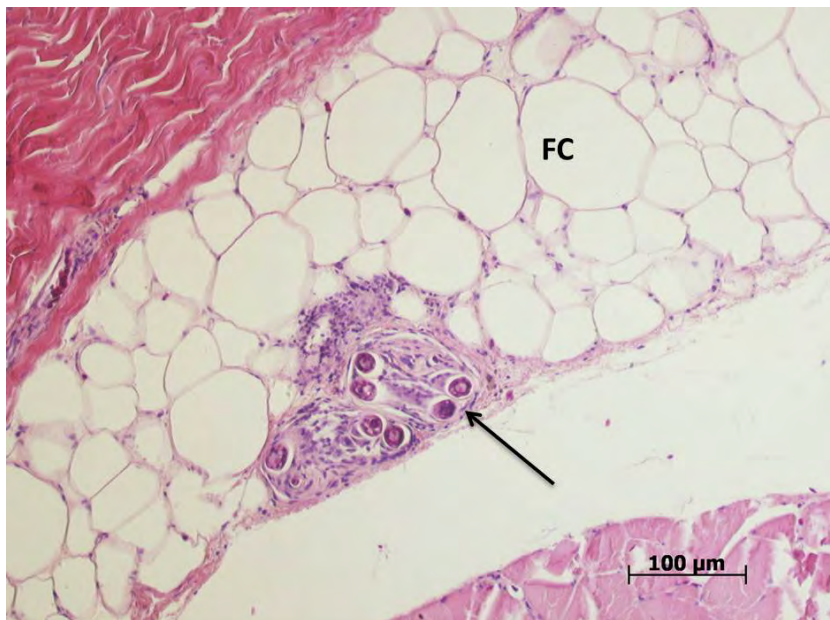


**Figure 3.17a:** Section of pectoral fat from a catfish sampled from the Olifants Gorge in June 2011 showing extensive extracellular ceroid-type lipopigment (lp) surrounded by connective tissue (ct) and macrophages (m). Adipocytes (fc) (H&E).



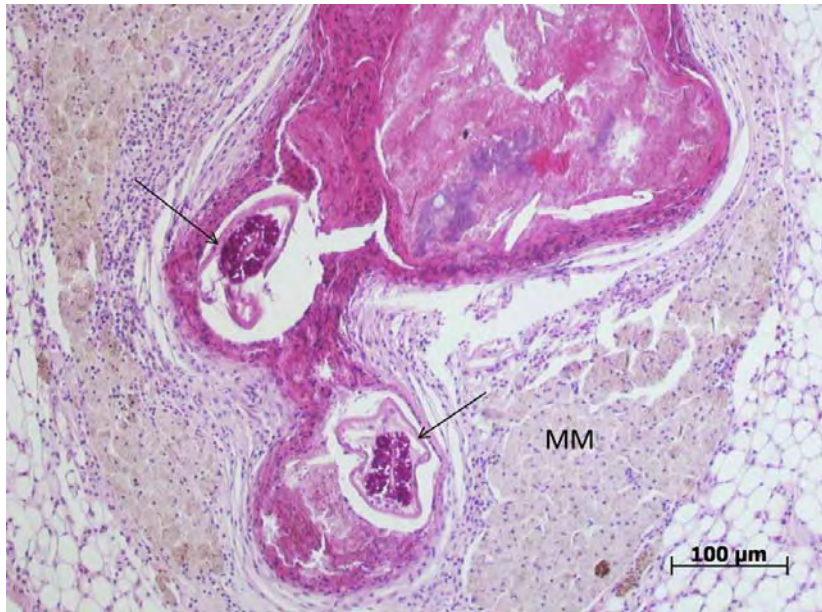
**Figure 3.17b:** Lipopigment-containing macrophages associated with steatitis in the fat surrounding the brain of a catfish sampled from the Olifants Gorge during June 2011. Focus of mixed inflammatory cells (arrow), macrophages (M), adipocytes (FC) (H&E).

Parasitic granulomata of varying sizes were common in the mesenteric, hypodermal and intermuscular fat but were not observed in the pectoral fat (Figures 3.18a, 3.18b & 3.18c). These granulomata were distinct from granulomata caused by steatitis. Parasitic granulomata showed a greater infiltration of fibroblasts and greater collagen deposition in the capsule than observed with granulomata associated with steatitis. Macrophage clusters on the periphery of parasitic granulomata were less intense and usually in the form of melanomacrophage centres. In haematoxylin and eosin stained sections, these appeared mildly basophilic in colour with variable amounts of brown melanin pigment. Ceroid- and lipopigment-containing macrophages were not generally associated with parasitic granulomata, and were infrequent in the vicinity of parasites in the mesenteric adipose tissues.

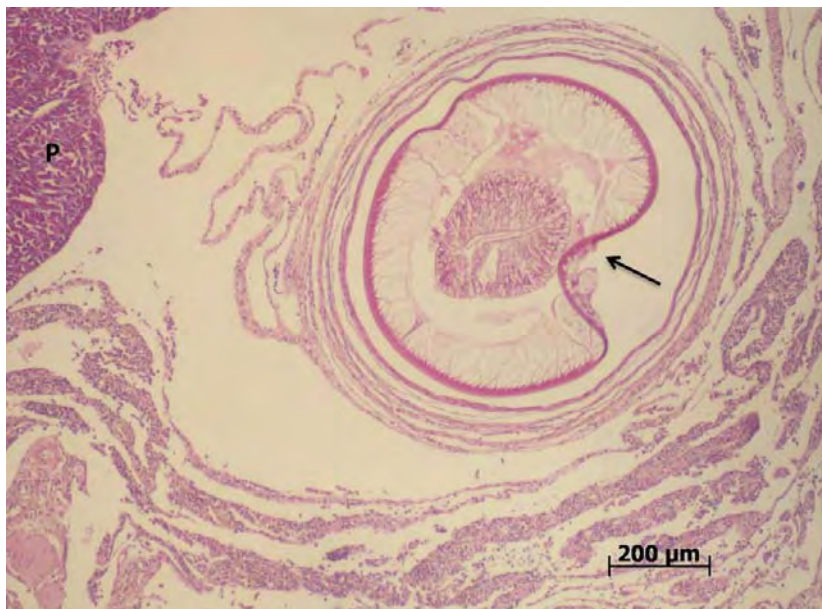

**Figure 3.18a:** Granuloma caused by migrating larval nematodes (arrow) in the hypodermal fat of a catfish sampled from the Olifants Gorge. Adipocytes (FC) (H&E).





**Figure 3.18b:** Granuloma formation in the mesenteric fat of a sharptooth catfish associated with larval nematodes (arrows) sampled from Reënvoël Dam. Note, in this case, the extensive melanomacrophage reaction (MM), but absence of lipopigment (H&E).



**Figure 3.18c:** Large encysted nematode larva (arrow) in the mesenteric fat attached to the pancreas (P) of a catfish sampled from van Ryssen Dam (H&E).

#### 3.2.2.2.2. Histopathology of other organs

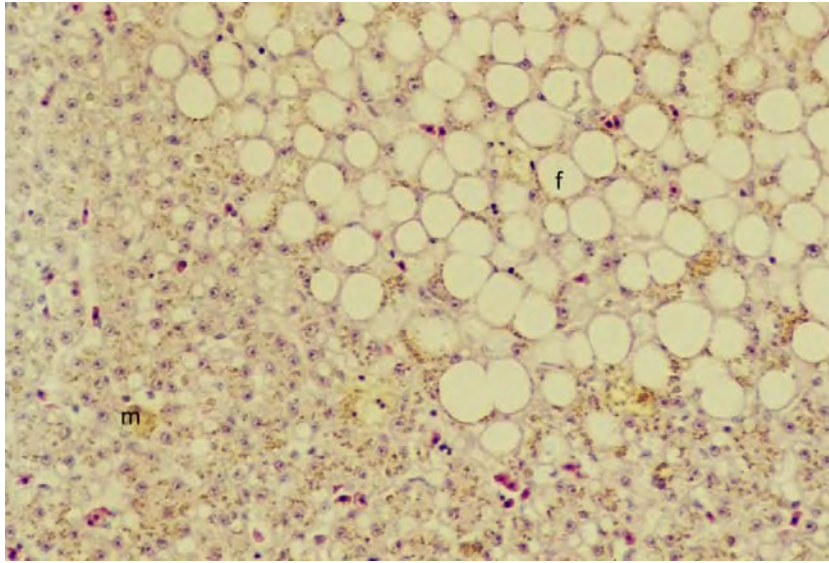
Varying degrees of hepatic lipidosis, often within distinct foci, were observed in the livers of fish suffering from pansteatitis. Special stains established the presence of ceroid, a golden brown breakdown product of oxidised unsaturated fat, in the hepatocytes of these fish, as well as large amounts of haemosiderin (Figures 3.19a and 3.19b). Presence of haemosiderin was confirmed by use of Perl's Prussian blue stain (Table 3.6). In places, well-demarcated foci of fat vacuolation contained distinctly less iron than in surrounding hepatocytes. In other areas the haemosiderin appeared clumped within the zone of fat vacuolation (Figure 3.19b). Such areas of fat vacuolation were also observed in livers of some catfish from Reënvoël Dam in the absence of pansteatitis.

A large focus of hepatocellular disorganization was observed in the liver of one fish from Lunsklip Fisheries suffering from severe pansteatitis. The affected area showed eosinophilia of hepatocytes and tracts of fibroblasts and associated inflammatory round cells infiltrating the liver parenchyma. The periphery of the focus was demarcated by a zone of melanomacrophage aggregations. The central area of the lesion appeared partitioned by fibrous tracts with islands of hepatocytes undergoing degeneration and necrosis. A clearly demarcated zone of disorganization with enlarged hepatocytes, devoid of pigment, arranged in loose whorls with mild fibroplasia, surrounding dilated vascular spaces was observed occasionally in catfish from Reënvoël Dam and from the Olifants Gorge. Adventitious macrophages were numerous in the livers of fish with pansteatitis, containing large deposits of both ceroid and haemosiderin, imparting a pronounced golden brown colour in the haematoxylin and eosin stained sections, with the macrophages staining strongly for iron with Perl's Prussian blue stain (Table 3.5). Melanomacrophages in all organs of older fish were replete with melanin. Variable numbers of inflammatory cells associated with ducts and blood vessels were observed in the livers of older fish particularly.

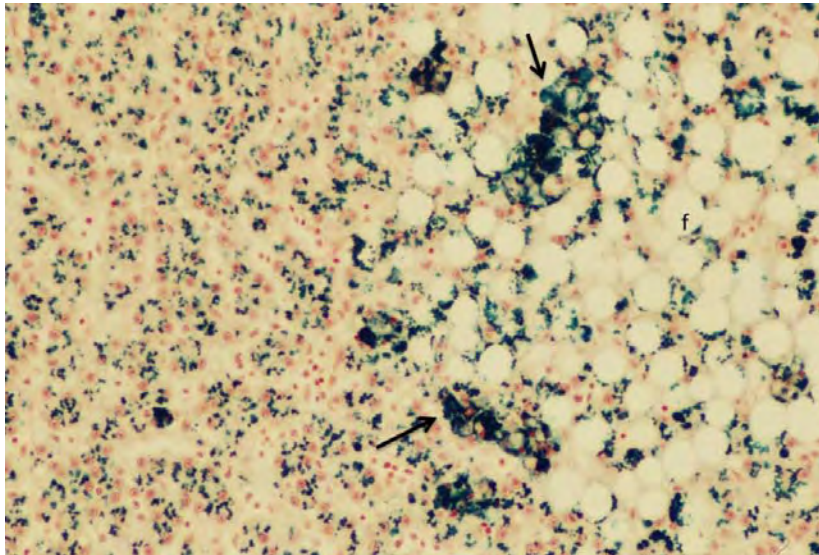
Granulomata associated with well-encapsulated larval nematodes of varying sizes were a common histological finding in many liver sections of fish from both the Olifants Gorge and Reënvoël Dam and other sampling sites in KNP, but were not observed in livers of catfish from Lunsklip Fisheries. These granulomata were characterised by a central cavity, filled with amorphous tissue debris, surrounded by a fibrous capsule of varying thickness. The nematode larvae could either be observed on the perimeter of the cavity or within the connective tissue capsule. Although some cysts were surrounded by a variable mixed



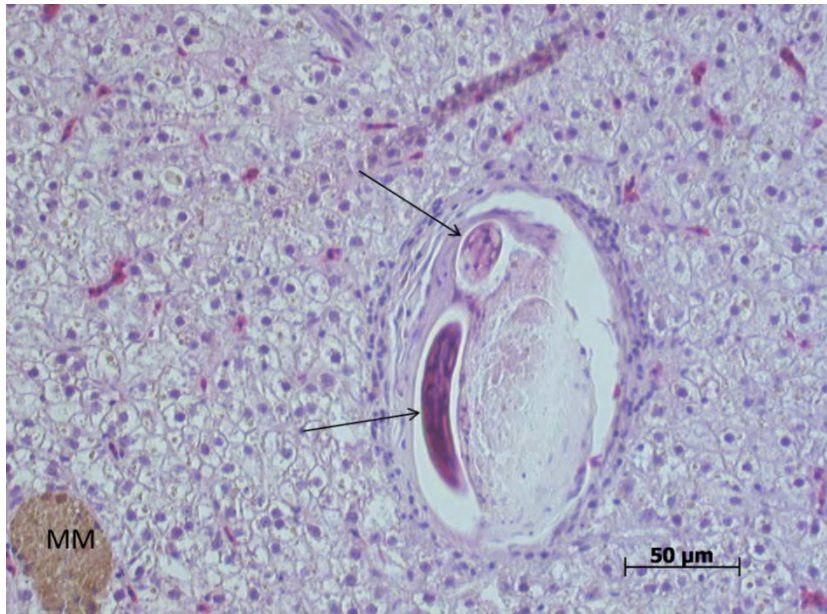inflammatory cell reaction, melanomacrophages were usually absent from these reactions (Figure 3.20).



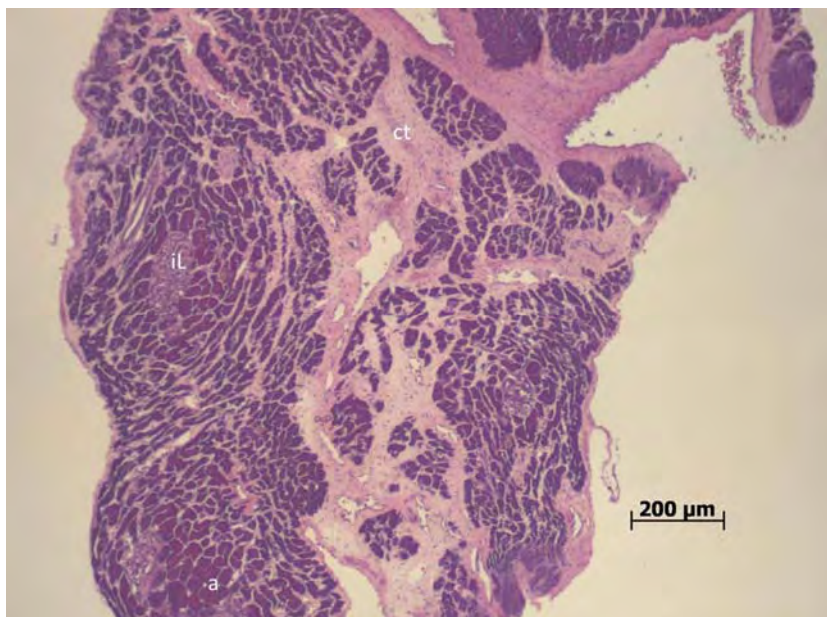
**Figure 3.19a:** Liver section of a catfish sampled from the Olifants Gorge during November 2009. Note distinct focus of fat vacuoles (f) (H&E, X200).



**Figure 3.19b:** Liver section of a catfish sampled from the Olifants Gorge during November 2009. Note distinct focus of fat vacuoles (f) and clustering of haemosiderin (arrows) on the perimeter of this focus (Perl's Prussian blue, X200).



**Figure 3.20:** Granuloma in the liver of a catfish sampled from the Levuvhu River containing larval nematodes (arrows). Note amorphous tissue debris within the cyst adjacent to the parasites. Melanomacrophage centre (MM) (H&E).



**Figure 3.21:** Pancreatic atrophy in a catfish suffering from pansteatitis, sampled from the Olifants Gorge during June 2011. Note prominence of connective tissue (ct) extending between groups of acinar cells (a). Islet of Langerhans (iL) (H&E).

Pancreatic acinar and islet of Langerhans cells appeared normal in all of the fish. The variable prominence of pancreatic tissues noted macroscopically was explained by atrophy of the organ, which was most prominent in fish affected by pansteatitis (Figure 3.21). Macrophages associated with the pancreas of fish suffering from pansteatitis did not contain haemosiderin. No specific pathology was observed in the intestines of the sampled fish.

In fish from all sites, variable numbers of focally disseminated clusters of dense basophilic lymphocytes were noted in the cranial and caudal kidney representing variation in the normal lymphocytic tissue within this organ. Melanomacrophages in the kidneys of fish with pansteatitis were replete with ceroid. Haemosiderin was also observed in the macrophages of the kidney in fish with pansteatitis but to a lesser extent than in the spleen and liver (Table 3.5). Positive Perl's staining material was observed in some of the renal tubular epithelial cells of such fish (Table 3.6).

The spleens of fish from various sites were variable in appearance depending on the numbers of erythrocytes held in the splenic sinusoids. Melanomacrophages in the spleen of fish with pansteatitis were replete with ceroid, and the splenic macrophages also carried large amounts of haemosiderin (Table 3.5). Encapsulated necrotic foci from degenerating parasites within the spleen were observed in two fish from the Olifants Gorge. Multiple cyst-like mineralized foci were observed in the spleen of one fish that was not suffering from pansteatitis. Small unidentified coccidian-type intracellular parasites were observed in macrophages within melanomacrophage centres of both the spleen and kidney of fish from the Olifants River and from Reënvoël Dam. These parasites were not observed in fish from Lunsklip Fisheries. No pathology was associated with the presence of this parasite.

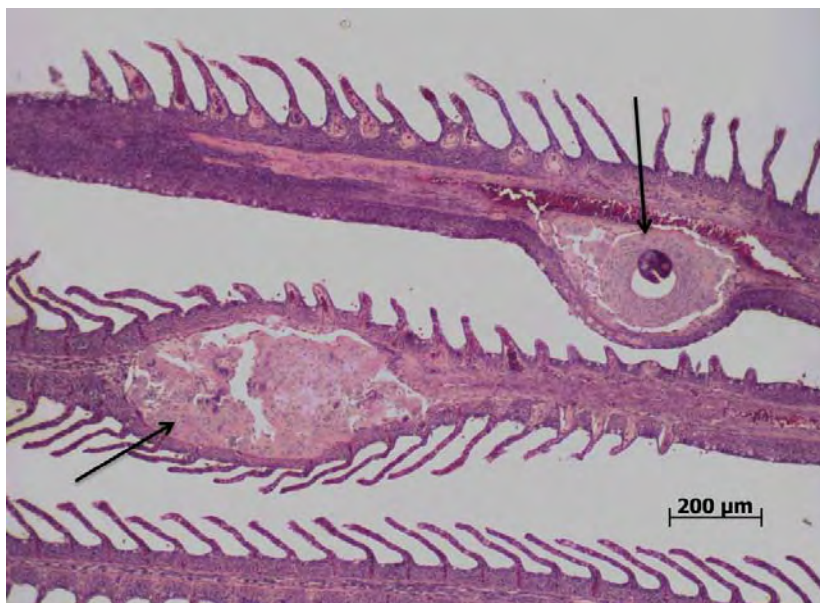Multiple focal cyst-like structures that appeared to be of thyroid origin were observed in the hearts of two fish with pansteatitis from Lunsklip Fisheries. The structures appeared to be lined by an epithelium and were filled with homogenous eosinophilic material. Myocardial lesions were not observed in fish from other sampling sites. No signs of fat necrosis could be detected in epicardial fat cells, where these were present on the hearts of sampled fish.

Gills in the catfish specimens collected in the Olifants Gorge during January 2009 presented with a two to three-fold increase in the thickness of the epithelium of the secondary lamellae. In many of these specimens the epithelial hyperplasia increased towards the base of the

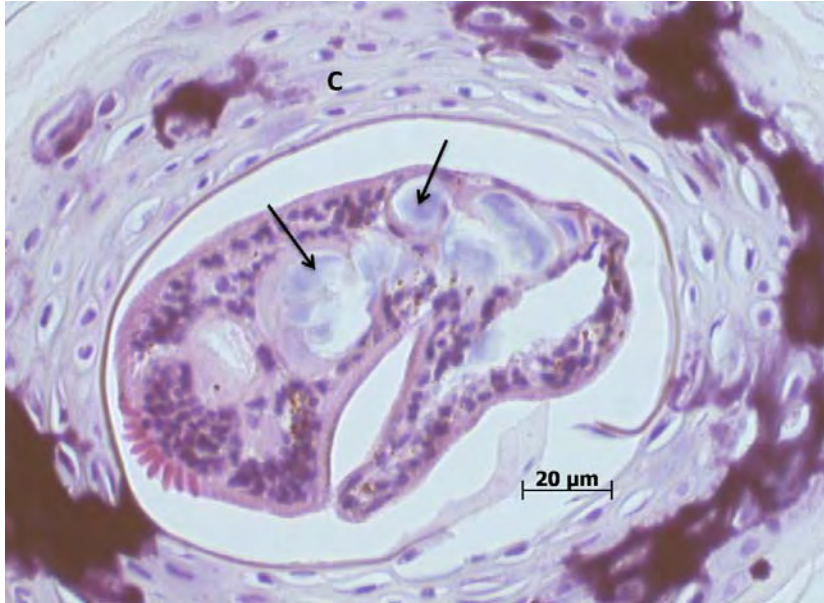

secondary lamellae, imparting a wedge-shaped appearance. Such changes were less evident in fish sampled from the Olifants Gorge in November 2009, and during later samplings gills showed minimal signs of hyperplasia. Monogenean trematodes were occasionally visible between the secondary lamellae of the gills. Some fish showed deformity and hyperplasia of the cartilage of the primary gill lamellae as a result of infection with a digenean trematode, possibly *Centrocestus formosanus* (Nishigori) (Figures 3.22a & 3.22b). These parasites could be observed lying within cysts in the gill cartilage, where they appeared to feed off chondrocytes, causing considerable damage to the gill cartilage. Infection with this parasite and resultant gill cartilage deformity was also common in fish sampled from Reënvoël Dam. Only mild hyperplasia of the gill epithelium was evident in some fish from Lunsklip Fisheries; however the absence of digenean gill parasites from these fish was notable.

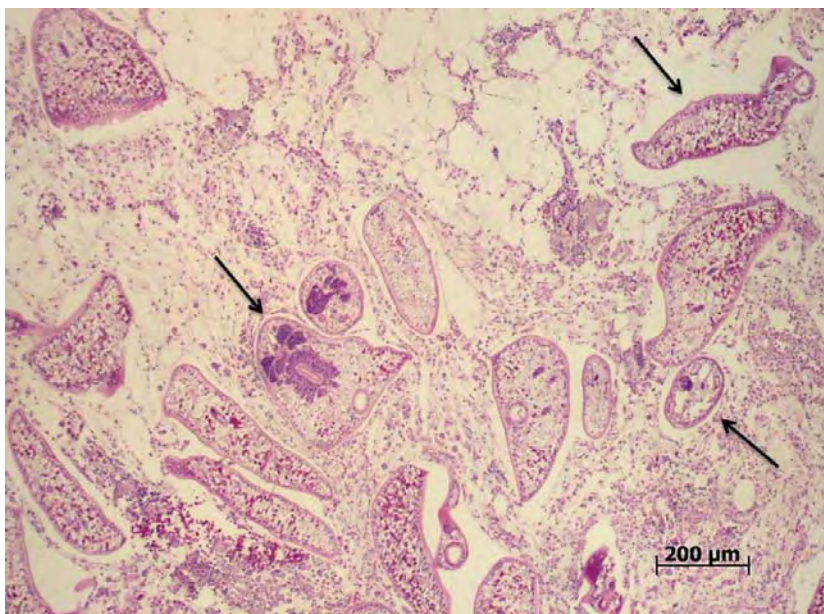
No lesions were observed in the brains of fish from any of the sampling sites. At some sampling sites large numbers of digenean trematodes (Fam. Diplostomidae) were observed surrounding the brain and within the brain fat (Figure 3.23). An inflammatory reaction with presence of macrophages was observed in association with these parasites, but they were never observed penetrating the brain tissues. There was no correlation between parasite presence and pansteatitis in the brain fat.



**Figure 3.22a:** Digenean trematode larva encysted within the cartilage of the primary lamellae of a catfish sampled from the Olifants Gorge during June 2011. Note hyperplastic changes in the cartilage (arrows) (H&E).



**Figure 3.22b:** Enlarged view of a digenean trematode, probably a metacercaria of *Centrocestus formosanus*, encysted in the gill cartilage (C) of a catfish from the Olifants Gorge. Note the ingested chondrocytes (arrows) (H&E).



**Figure 3.23:** Digenean trematodes of the family Diplostomidae (arrows) within the cerebrospinal space adjacent to fat lining the cranium of a catfish sampled from Engelhard Dam during July 2010. Note the cellular reaction associated with presence of these parasites (H&E).

Maturity of gonads observed in sampled fish depended on age and sampling season. Older female fish showed large numbers of melanomacrophages within the ovaries. Sections of the ovaries of fish with pansteatitis showed numerous adventitious macrophage aggregates containing large amounts of haemosiderin (Table 3.5). In testicular tissue, melanomacrophages were seldom noted, and if present were devoid of haemosiderin. Gonadal development in all cases appeared to be normal, and no pathology was noted within the gonads. Development of intersex was not observed in sampled fish.

Muscle atrophy was observed in some fish suffering from pansteatitis. Other than the presence of parasitic cysts, no other pathology was observed in muscle tissue. The fibrous and round cell inflammatory reaction associated with parasites depended on type and stage of parasite but was not correlated with presence of steatitis in the intermuscular fat. Macrophages in the hypodermis did not contain haemosiderin in pansteatitis-affected fish. No specific pathology was observed in the skin of sampled fish.

**Table 3.5:** The staining properties of macrophages in various tissues of catfish with pansteatitis sampled from the Olifants Gorge in November 2009 (OG). Perl's Prussian blue. Staining intensity on a scale of 1 to 5 expressed as mean of the sample size n

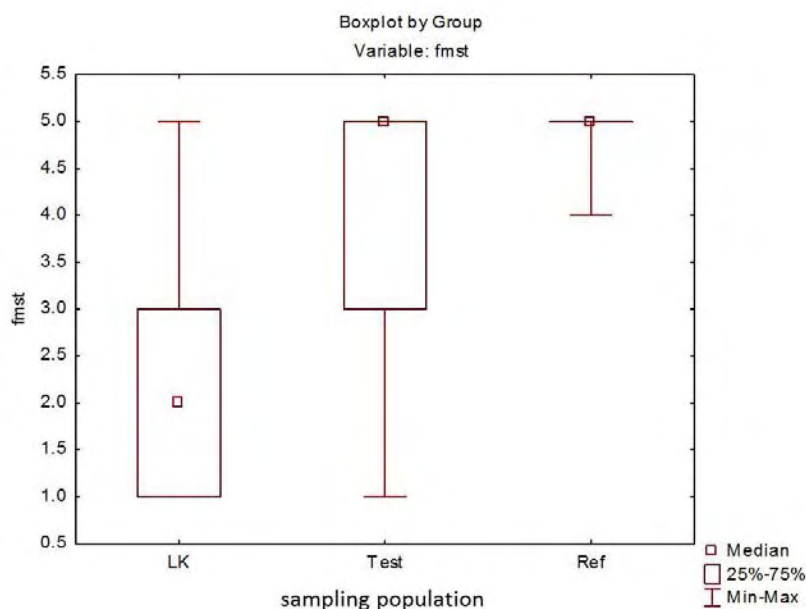
Sampling site	Liver (n11)	Spleen (n9)	Cranial kidney (n3)	Caudal kidney (n9)	Ovary (n3)	Testes (n4)	Pancreas (n3)	Hypo- dermis (n6)	Fat (n11)	Brain (n2)
OG	3.90	3.86	1.50	1.79	4.00	0.00	0.00	0.00	0.00	0.00

**Table 3.6:** Perl's Prussian blue staining properties of hepatocytes and renal tubular epithelial cells in catfish with pansteatitis sampled from the Olifants Gorge in November 2009 (OG). Perl's Prussian blue. Staining intensity on a scale of 1 to 5 expressed as mean of the sample size n

Sampling site	Hepatocytes (n11)	Tubular epithelial cells (n9)
OG	3.73	1.17

### 3.2.2.3. Statistical analysis

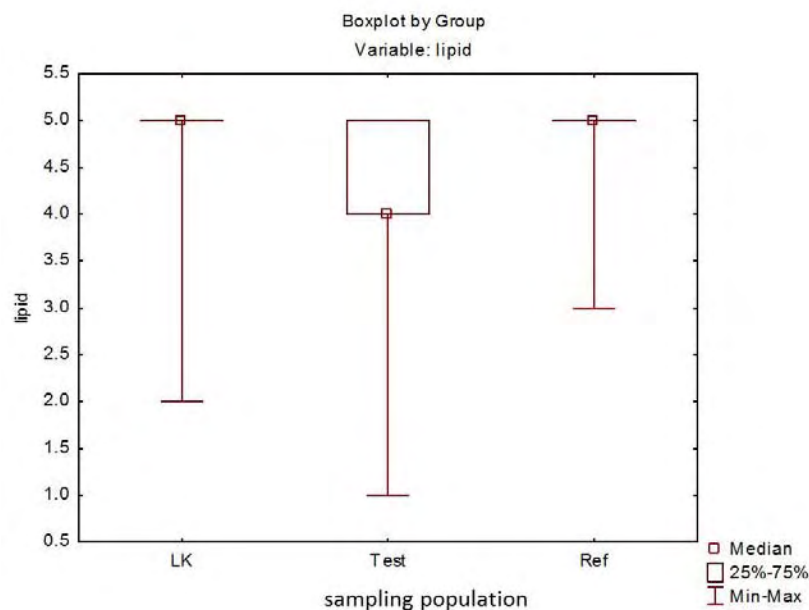
The numerical scores assigned to descriptive observations were used to detect differences between various pathology parameters and presence or absence of pansteatitis. Splenomegaly was observed frequently in catfish suffering from pansteatitis, and a significant effect of pansteatitis on spleen size was noted (Chi-squared Test,  $p=0.015$ ). Pancreatic atrophy was often noted in fish suffering from pansteatitis but there was no significant difference in catfish with and without pansteatitis. There was no effect of parasitosis on incidence or severity of pansteatitis. A comparison of the severity of steatitis lesions in the mesenteric fat of catfish showed significant differences between the Olifants Gorge test sites and the reference sites (Kruskal-Wallis ANOVA by ranks,  $p<0.001$ ), with the degree of severity greatest in catfish from Lunsklip Fisheries (Figure 3.24).



**Figure 3.24:** Comparison of steatitis severity in mesenteric fat of catfish sampled from LK (positive reference site), Test (all OG sites) and Ref (RV and RVB negative reference sites). Fmst=steatitis severity in mesenteric fat on a scale of 1 to 5 with 1 representing severe steatitis and 5 representing absence of steatitis.

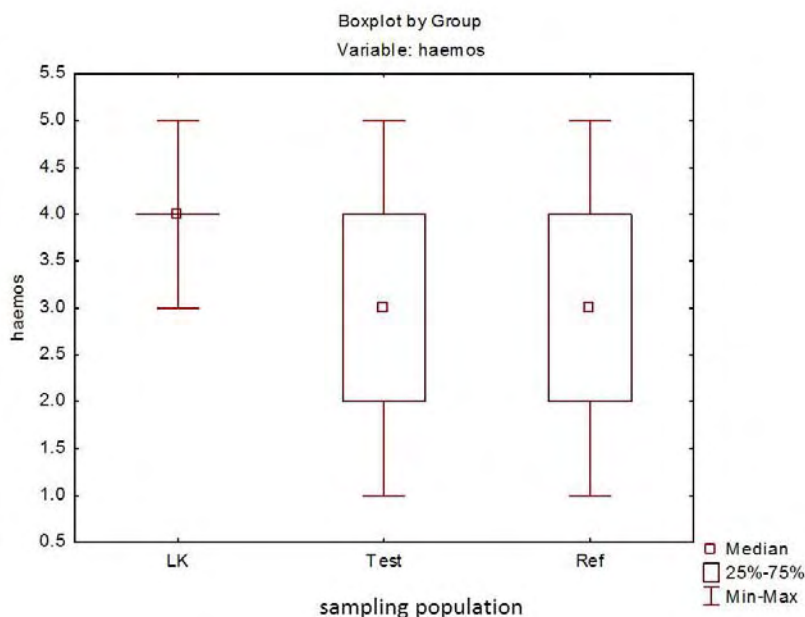
There was no significant difference in degree of hepatic lipidosis between catfish with and without pansteatitis within the Olifants Gorge population of catfish. But when comparing all catfish sampled from Olifants Gorge to the catfish from Reënvoël Dam, a significantly higher proportion of the Olifants Gorge fish showed hepatic lipidosis (Kruskal Wallis Test,  $p<0.001$ ), whereas there was no significant difference in hepatic lipidosis between fish from Lunsklip Fisheries and Reënvoël Dam. (Figure 3.25).





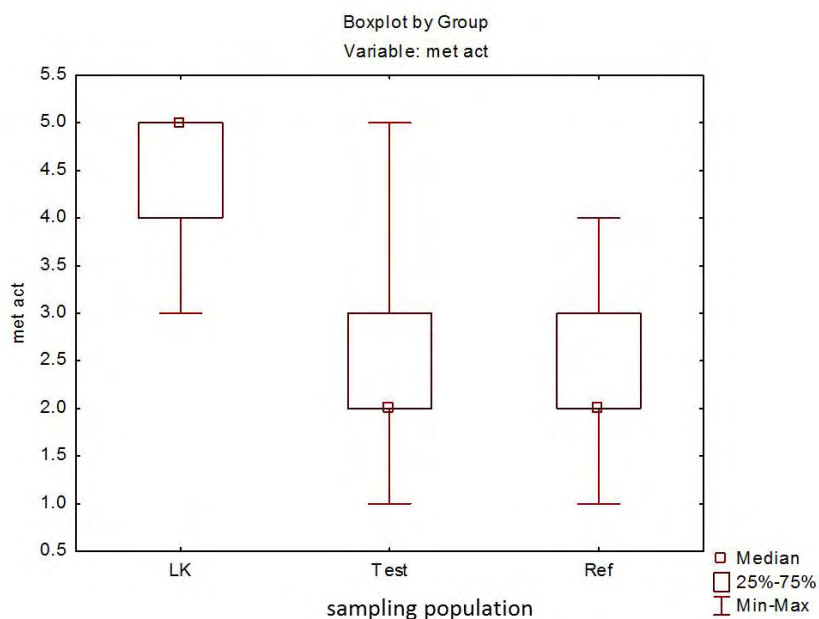
**Figure 3.25:** Comparison of hepatic lipidosis incidence between LK (positive reference site), Test (all OG sites) and Ref (RV & RVB negative reference site). Lipid=hepatic lipidosis on a scale of 1 to 5 with 1 representing severe lipidosis and 5 representing absence of lipidosis.

Within the Olifants Gorge population there was no significant difference in the amount of pigment (haemosiderin and ceroid) stored by hepatocytes between catfish with and without pancreatitis. In the livers of fish with pancreatitis, no association could be shown between pigment accumulation and age (Mann Whitney-U test,  $p=0.89$ ), whereas in catfish from Reënvoël Dam, pigment accumulation in hepatocytes increased significantly with age (Mann Whitney-U test,  $p<0.001$ ). Pigment accumulation in hepatocytes also increased significantly with age when healthy fish, from all sites sampled, were included in the analysis (Mann Whitney-U test  $p<0.001$ ). A comparison of hepatocyte pigment accumulation in catfish between sites indicated a significantly lower pigment accumulation in catfish from Lunsklip Fisheries (Kruskal Wallis ANOVA by ranks,  $p=0.006$ ) when compared with fish from the Olifants Gorge and Reënvoël Dam sites, whereas there was no overall difference between fish from the Olifants Gorge and Reënvoël Dam sites (Figure 3.26).



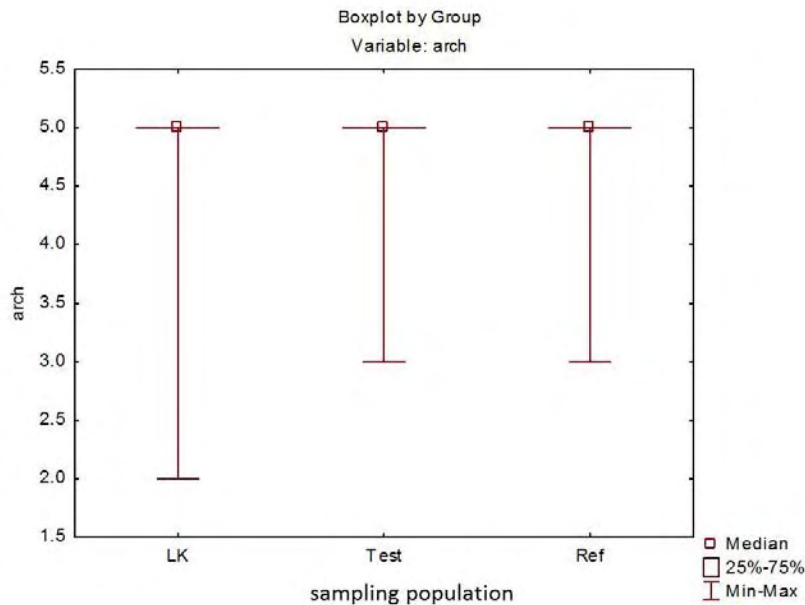
**Figure 3.26:** Comparison of level of pigment (haemosiderin and ceroid) stored by hepatocytes between LK (positive reference site), Test (all OG sites) and Ref (RV and RVB negative reference site). Haemos=hepatocyte pigment on a scale of 1 to 5 with 1 representing severe accumulation and 5 representing absence of pigment.

The degree of basophilia and compactness of hepatocytes as well as the presence of vacuoles and vesicles causing distension of hepatocytes was used to gauge the level of metabolic activity in the liver. There was no significant difference in the metabolic activity of hepatocytes between catfish with and without pancreatitis in the Olifants Gorge. A comparison between sites indicated significantly greater metabolic activity in the catfish from Lunsklip Fisheries (Kruskal-Wallis ANOVA by ranks,  $p < 0.001$ ). Some of the Olifants Gorge fish showed an equivalent degree of metabolic activity, although there were no significant differences between metabolic activity in the livers of fish from the Olifants Gorge and Reënvoël Dam (Figure 3.27).



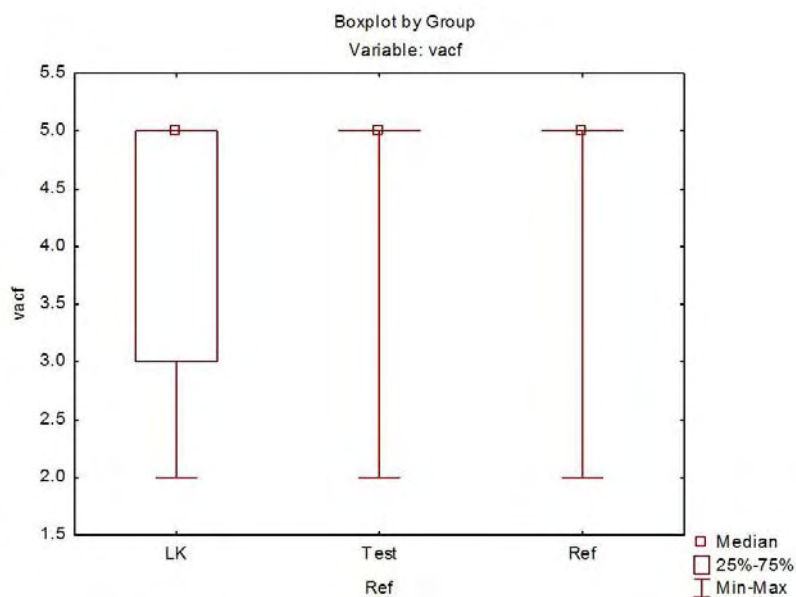
**Figure 3.27:** Comparison of metabolic activity of hepatocytes of catfish between LK (positive reference site), Test (all OG sites) and Ref (RV and RVB negative reference site). Met act=metabolic activity on a scale of 1 to 5 with 1 representing compact inactive hepatocytes and 5 representing distended vacuolated hepatocytes.

There were no significant differences in the median intensity of structural disorder of the livers when catfish from the Olifants Gorge were compared to catfish from Lunsklip Fisheries and Reënvoël Dam. Although not statistically significant, the worst degree of structural disorder of the liver was observed in a small number of catfish from Lunsklip Fisheries (Figure 3.28). There was no variation in bile duct fibroplasia between fish with and without pansteatitis or between sites.



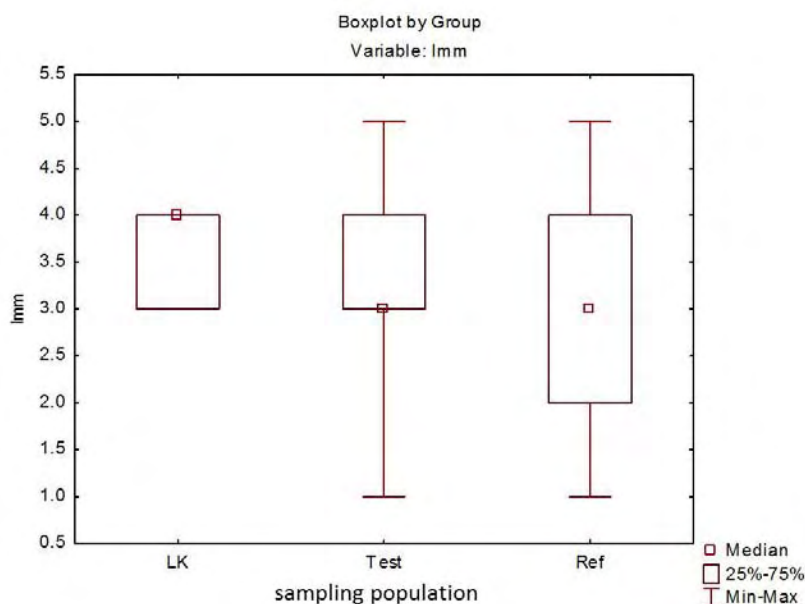
**Figure 3.28:** Comparison of structural disorder in the liver of catfish between LK (positive reference site), Test (all OG sites) and Ref (RV and RVB negative reference site). Arch=structural disorder on a scale of 1 to 5 with 1 representing a severe degree of disorder and 5 representing normal hepatic structure.

Livers from catfish from Lunsklip Fisheries showed the greatest number of vacuolated foci. A significant difference in intensity of vacuolated foci in the livers of fish from the Olifants Gorge with and without pansteatitis could not be detected. Although there was no significant difference in the means between the Olifants Gorge and Reënvoël Dam sites, there was a significant difference between the Olifants Gorge and Lunsklip Fisheries sites (Kruskal-Wallis ANOVA by ranks,  $p < 0.001$ ) (Figure 3.29).



**Figure 3.29:** Comparison of vacuolated foci in the liver of catfish between LK (positive reference site), Test (all OG sites) and Ref (RV and RVB negative reference site). Vacf=presence of vacuolated foci on a scale of 1 to 5 with 1 representing numerous foci and 5 representing absence of foci.

There was no significant difference in intensity of melanomacrophage centres in the livers of catfish between the Olifants Gorge, Lunsklip Fisheries and Reënvoël Dam sites (Figure 3.30). Using the Mann-Whitney U test, there was also no significant variation in the intensity of melanomacrophages in the liver, spleen and gonad when catfish with and without pansteatitis were compared, although catfish with pansteatitis showed a negative correlation ( $p=0.003$ ) between intensity of melanomacrophages in the kidney and presence of pansteatitis.



**Figure 3.30:** Comparison of melanomacrophage centre intensity in the liver of catfish between LK (positive reference site), Test (all OG sites) and Ref (RV and RVB negative reference sites). Lmm=melanomacrophage intensity on a scale of 1 to 5 with 1 representing numerous melanomacrophage centres and 5 representing absence of melanomacrophage centres.

Regression analysis showed a significant increase in the intensity of liver melanomacrophage centres with age ( $p < 0.001$ ) in the Reënvoël Dam reference catfish but not in the Olifants Gorge or Lunsklip Fisheries catfish, both populations with pansteatitis prevalence.

#### 3.2.2.4. Discussion of descriptive pathology

In catfish from the Olifants Gorge, significant pathology was restricted to the adipose tissues, with the most intense and frequent lesions being in the mesenteric fat. Further changes observed in the liver and spleen appeared to be secondary to fat necrosis. Necrosis of the adipose tissue resulting in steatitis was repeatedly observed and was a consistent indicator of oxidative stress.

For many species the term “yellow fat disease” is used to describe pansteatitis. The fat of sharptooth catfish is distinct from that of other fish species in that a variation in colour of the mesenteric adipose tissues appears to be normal. Fat colour can thus not be used as an indication of lipid peroxidation as in other species. Pearson, Chinabut, Karnchanakharn and Somsiri (1994) have, however, described jaundice in sharptooth catfish hybrids associated



with lipid liver degeneration, following on feeding of rancid chicken viscera, and this resulted in pale yellow discoloration of the body fat and gills. During the study, specific pathology relating to lipid autoxidation and pansteatitis was also observed in a captive population of sharptooth catfish suffering from known nutritionally-induced pansteatitis. In these fish severely affected fat took on a grey-brown colour rather than the yellow colour observed in wild catfish, and jaundice was not present.

Where pansteatitis was present in catfish, the mesenteric adipose tissues were most severely affected. Steatitis was only occasionally observed in other fat depots and this may relate to specific adipogenic and lipolytic factors associated with the differing functions of these fat tissues. The pectoral adipose tissue is embedded in a mesenchyme connective tissue matrix and appears to protect the lobes of the cranial kidney and liver where they lie outside of the abdominal cavity in a hypodermal position. The intracranial fat, also occasionally affected by steatitis, is a fluid filled loose tissue surrounding the brain. Large numbers of digenean trematode metacercariae were often in close proximity to this fat but appeared to have little effect on the tissue. The intermuscular fat was affected with steatitis in only a few fish in both the captive fish from Lunsklip Fisheries and the fish from the Olifants Gorge. The variable size of the mesenteric fat tissue suggests that this is the most labile and metabolically active fat depot in the body. It is not clear why this tissue is more prone to developing steatitis in catfish.

Catch methods imposed by the environment in the Olifants Gorge (presence of hippos and crocodiles) have limited most samplings to catching by baited hook and line. The most severely affected fish may not have taken bait and would have been easy prey for crocodiles. This favoured sampling of relatively healthy fish whereas the worst affected fish remained under-represented. Despite this, significant numbers of fish with pansteatitis were caught repeatedly in the Olifants Gorge and on the single occasion in the Sabiepoort.

Teleost hepatocytes can carry considerably more glycogen and lipid without showing nuclear degeneration than can mammalian hepatocytes (Stoskopf 1993), and fish have the capacity to store large amounts of lipid without ill effect. Hepatic lipid accumulation has been associated with exposure to toxicants and particularly with lipid peroxidation following on feeding of diets high in polyunsaturated lipids and/or with suppression of vitamin E (Wolf & Wolfe 2005). Various degrees of hepatic lipidosis and ceroidosis were observed in catfish with

severe pansteatitis; however, no correlation could be demonstrated between hepatic lipidosis and pansteatitis.

The degree of vacuolation in hepatocytes reflects imbalances in energy intake and expenditure, providing an indication of the metabolic state of the fish. During periods of starvation in fish, this may reflect preservation of hepatic glycogen (Wolf & Wolfe 2005). Exposure to organic toxicants resulting in sub-lethal injury to hepatocytes can also cause vacuolation of hepatocytes as a result of lipid-filled vacuoles (Hayes 2004). Presence of vacuolated foci in hepatic tissues of fish may indicate chronic hepatic injury in polluted waters, particularly in benthic fish (Gingerich 1982). The greater number of vacuolated foci observed in the livers of catfish from Lunsklip Fisheries may have been related to the severe degree of pansteatitis, and the obesity observed in the majority of these fish, caused by the excessive feeding of rancid, oil-rich fish waste.

Relative to cardiac output, the perfusion of the teleost liver is low, limiting exposure of the basal membrane of the hepatocyte to toxicants (Wolf & Wolfe 2005). Contributing to the stasis of chemicals and metabolites in the hepatobiliary system of fishes is the slow bile flow, which in rainbow trout is about 50 times slower than in mammals (Gingerich 1982). This stasis of chemical compounds and their metabolites in the liver and the propensity of chemicals excreted in the bile to become incorporated into enterohepatic cycling can cause prolonged hepatotoxic effects in fish (Gingerich 1982). Furthermore it is thought that the close association of the biliary system with hepatocytes in fish is responsible for the high incidence of peribiliary damage to hepatocytes and biliary epithelial cells with exposure to toxicants (Hinton & Laurén 1990). It is a well-established fact that many xenobiotics exert their harmful effects through oxidative damage to phospholipid structures in various organs and tissues. Exposure to such pollutants would be expected to result in detectable pathology particularly in the liver. There was, however, no significant correlation between pansteatitis incidence and hepatic lipidosis or peribiliary fibrosis within the Olifants Gorge population of catfish. When fish from the Olifants Gorge were compared to fish from Reënvoël Dam, a significantly higher proportion of the Olifants Gorge fish showed hepatic lipidosis ( $p < 0.001$ ), whereas there was no significant difference in hepatic lipidosis between fish from Lunsklip Fisheries and Reënvoël Dam. This may have reflected different feeding activity in the respective fish.

Melanomacrophage centres are groups of distinct pigment-containing cells that are a unique feature of the lymphomyeloid tissue of fish (Kennedy-Stoskopf 1993) and are generally found in the reticulo-endothelial supporting matrix of haemopoietic tissues (Agius & Roberts 2003). In teleosts they occur in both hepatic and extra-hepatic tissues and represent possible forerunners of the germinal centres in the spleen and lymph nodes of higher animals (Agius 1979). Melanomacrophage centres are known to increase in size and frequency with exposure to environmental stress and may increase with exposure to organic chemicals (Agius & Roberts 2003; Metcalfe 1999; Wolf & Wolfe 2005). Interpretation of such increases in melanomacrophages must be done with care as these increases also occur physiologically with age and during periods of starvation (Agius & Roberts 2003; Hinton & Laurén 1990; Wolf & Wolfe 2005). Melanomacrophages are thought to sequester and detoxify endogenous and exogenous substances. Apart from melanin and haemosiderin, they are known to carry lipogenic pigments (lipofuscin and ceroid) representing effete cellular components. These, as in the case of haemosiderin, may also increase during catabolic states such as starvation and with follicular atresia (Agius & Roberts 2003; Kennedy-Stoskopf 1993). In a comparison of catfish from the Olifants Gorge, Reënvoël Dam and Lunsklip Fisheries, no significant correlations were found between mean liver melanomacrophage intensity and site. The wide ranging standard deviation in the results from both the Olifants Gorge and Reënvoël Dam reflected a high degree of variation in intensity of melanomacrophages. Regression analysis showed significant correlation between age and intensity of liver melanomacrophage centres ( $P < 0.001$ ) in the Reënvoël Dam reference catfish but not in the Olifants Gorge or Lunsklip Fisheries catfish, both populations with pansteatitis prevalence.

Perl's Prussian blue stain demonstrates presence of ferric iron. Agius (1979) investigated the pattern of iron storage in the melanomacrophage centres in various organs of 14 different species of healthy and diseased fish. The spleen was the main organ of iron storage by melanomacrophages, whereas melanomacrophage centres in the liver and kidney were found to store insignificant amounts of iron. Whilst certain diseases including pansteatitis resulted in accumulation of iron in splenic macrophage centres, the same did not happen in hepatic and renal macrophage centres (Agius 1979). In contrast to the findings of Agius (1979), melanomacrophages from both the spleen and liver of fish suffering from pansteatitis in the Olifants Gorge appeared to be storing large amounts of iron, and even renal melanomacrophages contained obvious amounts of iron, albeit less than in the liver. Such ferric iron compounds may be derived predominantly from haemoglobin catabolism (Moccia

*et al.* 1984), in which case, bound to transferrin or sequestered as haemosiderin, the iron is well tolerated by the liver (Hayes 2004). In the Olifants Gorge catfish, statistical analysis showed no correlation between pigment accumulation by hepatocytes and incidence of pansteatitis. While adventitious macrophage aggregations in the ovaries contained large amounts of iron, macrophage aggregations associated with fat cell necrosis in the adipose tissues, and macrophage centres in the pancreas, testes and hypodermis did not contain iron. It is not clear whether the iron deposits represent increased iron storage as haemosiderin due to excessive haemolysis or whether they are indicative of abnormal uptake of iron from the environment. However, Baker, Martin and Davies (1997) have demonstrated heightened oxidative stress in *C. gariepinus* ingesting abnormally high levels of iron under experimental conditions. The clustering of haemosiderin around the perimeter of fat accumulation in livers of fish with pansteatitis is interesting in that redox cycling of iron has been implicated as a cause of iron-catalysed lipid peroxidation (Minotti & Aust 1992).

Splenomegaly was a consistent finding in fish with pansteatitis and was significantly correlated with presence of steatitis ( $p=0.015$ ), and splenic haemosiderosis may have been indicative of increased haemoglobin catabolism. There was no correlation between pancreatic atrophy and pansteatitis incidence. Pancreatic atrophy may simply have reflected episodes of reduced feeding.

Myopathy, as described in association with pansteatitis and vitamin E deficiency in other species (Ginn *et al.* 2007; Murai & Andrews 1974; Roberts *et al.* 1979; van Vleet & Valentine 2007), was not observed in catfish with pansteatitis from either the Olifants Gorge or Lunsklip Fisheries. This may reflect adequate dietary intake of vitamin E, but may also have been influenced by the selenium status of the fish. Many fish with pansteatitis were in remarkably good condition. A few fish with pansteatitis did show muscle wasting, but on histological examination myopathy was not present.

Compared to control fish, catfish from most sampling sites carried heavy burdens of parasites. Frequent and varied pathology associated with parasites was observed in most of the wild caught fish and varied between sampling sites depending on parasite burdens and prevalence of specific parasites. Despite the associated pathology, presence of parasites appeared to be well tolerated by the fish. Fish from Reënvoël Dam, a population where pansteatitis could not be demonstrated, showed the heaviest parasite burdens. Focal steatitis

with minimal lipopigment formation was observed only infrequently in association with parasites and no correlation could be demonstrated between parasite burden and pansteatitis. The steatitis described in association with lipidosis and streptococcosis in cultured silver perch (Deng *et al.* 2012), was similarly characterised by an absence of ceroid within the necrotic lesions in fat deposits observed in various organs. It is interesting to note the presence of metacercariae of *Centrocestus formosanus* in gills of catfish from KNP, as spread of this zoonotic parasite has been associated with introduction of carp from Asia elsewhere (Vélez-Hernández, Constantino-Casas, García-Márquez, & Osorio-Sarabia 1998) and as far as the author is aware this is the first preliminary recording of the occurrence of this parasite in South Africa.

### **3.2.3. Haematology and blood chemistry in pansteatitis in catfish**

#### **3.2.3.1. Blood smear examinations**

Examination of blood smears taken from catfish collected from the Olifants Gorge soon after the mass crocodile mortality in the winter of 2008 revealed an increase in numbers of immature erythrocytes and erythrocytes with irregular cell shapes and crenated cell membranes in many of the fish. Nuclear shapes were similarly irregular with a high prevalence of chromatin clumping visible within the nuclei in some blood smears. As the changes were not restricted to immature erythrocytes, these may have been an artefact of smear preparation. An increase in polychromatocytes was, however, still evident in blood smears taken during the November 2009 sampling (Table 3.7). Sharptooth catfish normally have round nucleated erythrocytes which are distinct from the oval erythrocytes of many other fish species. Compared to mature erythrocytes, polychromatocytes were characterised by a more basophilic cytoplasm and a larger, granular appearing nucleus. Crenation of erythrocyte cell membranes was also present in some blood smears of fish sampled from the Olifants Gorge during November 2009.

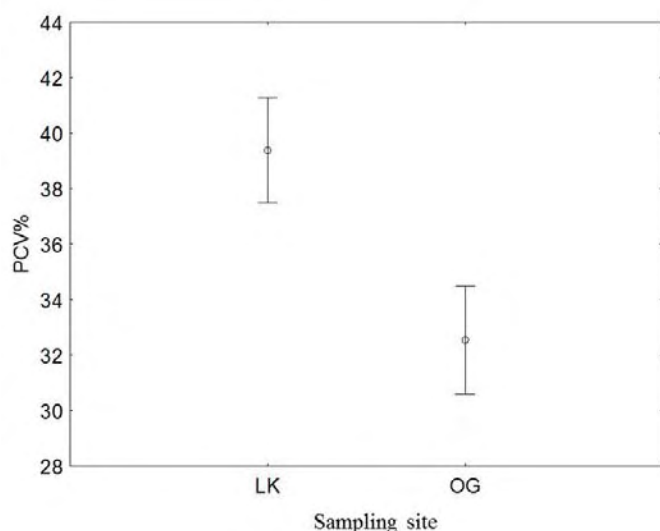
**Table 3.7:** Comparison of percentage polychromatocytes in blood smears collected from catfish at three sampling sites during November 2009 (\*standard deviation)

Sampling site	% polychromatocytes		
	mean $\pm$ SD*	range	number
Lunsklip Fisheries	0.75 $\pm$ 0.60	0.00- 2.33	21
Olifants Gorge	3.26 $\pm$ 2.73	0.67-12.33	19
Reënvoël Dam	1.95 $\pm$ 1.65	0.33- 5.33	20

### 3.2.3.2. Haematocrit

Mean haematocrit values are presented in Table 3.8. There were no significant differences in haematocrit values between fish with and without pansteatitis at various sampling sites where pansteatitis was found to occur. In the Olifants Gorge, mean PCV values of fish ranged between 25% and 41% in apparently healthy fish and between 24% and 37% in fish with pansteatitis. The mean PCV value for fish sampled from Reënvoël Dam was 32.3% (n=13, standard deviation=6.1). Comparison of mean PCV values of fish sampled from the Olifants Gorge (32.6%) with Lunsklip Fisheries (39.4%) during November 2009 (Figure 3.31) indicated significantly lower haematocrit values in the Olifants Gorge fish (p<0.05). Haematocrit values were only available from fish sampled from Reënvoël Dam during January 2011; during the November 2009 sampling of catfish from Reënvoël Dam a field micro-centrifuge was not available. Analysis of variance (p<0.001) followed by post-hoc Tukey's HSD test showed significant differences between mean PCV values (39.4%) for fish from Lunsklip Fisheries (positive reference population, n=21) when compared to mean PCV values (30.3%) for all fish sampled from the Olifants Gorge (n=111), and to mean PCV values (32.3%) for fish from Reënvoël Dam (negative reference population, n=13).





**Figure 3.31:** Comparison of mean haematocrit (PCV%) from catfish sampled from Lunsklip Fisheries (n 21) and the Olifants Gorge (n 20) during November 2009 (p=0.016, vertical bars denote +/- standard errors).

**Table 3.8:** Mean haematocrit values (packed cell volume=PCV) of blood collected from catfish from all sites (Olifants Gorge=GL, OGM, OG, OL, LOG, LOC; Lunsklip Fisheries=LK; Reënvoël Dam=RVB; Engelhard Dam=EH; van Ryssen Dam=FK; Mamba Weir=M; Levuvhu River=LUV; Crocodile River=CR) (\*standard deviation)

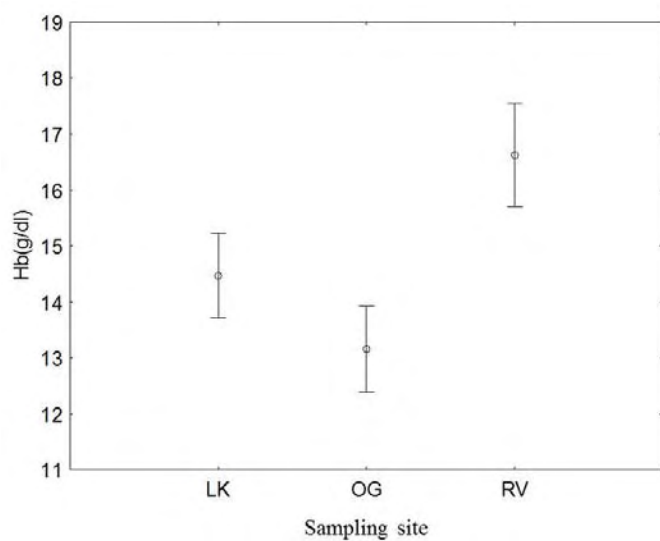
Sample site	Date	Packed cell volume (%)		
		mean $\pm$ SD*	range	number
GL	Jun-09	26.33 $\pm$ 4.97	15-31	9
OGM	Aug-09	39.07 $\pm$ 6.75	30-50	14
LK	Nov-09	39.38 $\pm$ 7.60	22-50	21
OG	Nov-09	32.55 $\pm$ 9.71	10-50	20
EH	Jul-10	29.95 $\pm$ 5.96	19-40	19
OL	Jul-10	28.56 $\pm$ 6.92	15-38	25
M	Jul-10	27.75 $\pm$ 8.34	12-45	20
LOG	Jan-11	30.59 $\pm$ 6.04	14-39	22
RVB	Jan-11	32.31 $\pm$ 6.06	20-44	13
FK	Jan-11	32.20 $\pm$ 4.69	22-38	10
LUV	Jun-11	30.79 $\pm$ 5.82	21-40	14
LOC	Jun-11	25.67 $\pm$ 7.43	11-40	21

### 3.2.3.3. Blood haemoglobin

Mean blood haemoglobin concentrations for fish sampled from all sites are shown in Table 3.9 and were noticeably variable. Haemoglobin values (g/dl) did not differ significantly between fish with and without pansteatitis from the Olifants Gorge, with mean values of 10.1 and 9.7 respectively. Analysis of variance showed significant difference ( $p < 0.05$ ) in mean haemoglobin values of fish sampled during November 2009 from the Olifants Gorge, Lunsklip Fisheries and Reënvoël Dam (post-hoc Tukey's test) (Figure 3.32). The mean haemoglobin value of fish sampled from Reënvoël Dam during January 2011 was however, much lower than that of fish sampled from the same site during November 2009, with mean values being similar to those of catfish sampled from the Levuvhu and Crocodile rivers. The significance of the differences observed in the November results thus remains uncertain.

**Table 3.9:** Mean blood haemoglobin concentrations (g/dl) of blood collected from catfish from all sites (Olifants Gorge=GL, OGM, OG, OL, LOG, LOC; Lunsklip Fisheries=LK; Reënvoël Dam=RV, RVB; Engelhard Dam=EH; van Ryssen Dam=FK; Mamba Weir=M; Levuvhu River=LUV; Crocodile River=CR)(\*standard deviation)

Sample site	Date	Haemoglobin		
		mean $\pm$ SD*	range	number
GL	Jun-09	12.32 $\pm$ 1.07	10.7-13.80	9
OGM	Aug-09	11.00 $\pm$ 1.11	8.93-13.00	14
LK	Nov-09	14.47 $\pm$ 3.06	9.53-23.00	21
OG	Nov-09	13.16 $\pm$ 3.84	6.65-21.00	20
RV	Nov-09	16.62 $\pm$ 3.39	10.8-21.30	14
EH	Jul-10	9.39 $\pm$ 3.57	3.82-16.90	20
OL	Jul-10	9.66 $\pm$ 4.29	3.24-21.30	25
M	Jul-10	8.04 $\pm$ 4.52	2.33-17.10	20
LOG	Jan-11	7.69 $\pm$ 3.05	0.10-13.70	22
RVB	Jan-11	8.05 $\pm$ 2.45	3.50-13.10	13
FK	Jan-11	13.83 $\pm$ 6.39	8.15-29.93	10
LUV	Jun-11	9.25 $\pm$ 1.68	6.40-12.20	14
LOC	Jun-11	7.90 $\pm$ 2.12	4.20-12.00	16
CR	Jun-11	7.89 $\pm$ 1.34	4.20-10.20	20



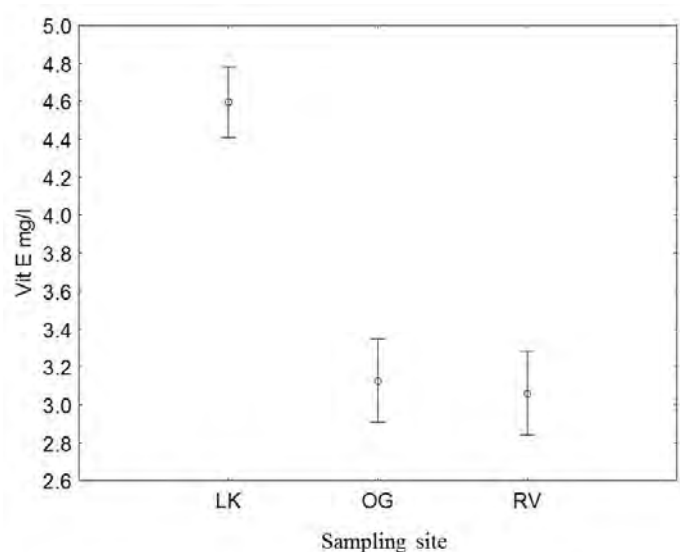
**Figure 3.32:** Comparison of mean blood haemoglobin concentrations (g/dl) of catfish sampled during November 2009. LK=Lunsklip Fisheries (n 21), OG=Olifants Gorge (n 20) and RV= Reënvoël Dam (n 14). (p=0.021, vertical bars denote +/- standard errors).

#### 3.2.3.4. Serum vitamin E

Mean serum vitamin E values for catfish sampled from all sites are presented in Table 3.10. Vitamin E values did not differ significantly between fish with and without pansteatitis. Although some fish from the Olifants Gorge had very low serum vitamin E values, analysis of variance showed that there was no significant difference in mean serum vitamin E values between fish sampled from the Olifants Gorge and Reënvoël Dam during November 2009 whereas the values in fish sampled from Lunsklip Fisheries were significantly higher at this time (Figure 3.33).

**Table 3.10:** Mean serum vitamin E values of catfish from all sites (Olifants Gorge=OGM, OG, OL; Lunsklip Fisheries=LK; Reënvoël Dam=RV; Engelhard Dam=EH; Mamba Weir=M) (\*standard deviation)

Sample site	Date	Vitamin E (mg/l)		
		mean $\pm$ SD*	range	number
OGM	Aug-09	4.67 $\pm$ 2.99	1.00-8.90	14
LK	Nov-09	4.60 $\pm$ 1.26	2.70-6.70	21
OG	Nov-09	3.13 $\pm$ 0.34	2.70-3.90	15
RV	Nov-09	3.06 $\pm$ 0.33	2.40-3.70	15
EH	Jul-10	3.33 $\pm$ 1.49	1.40-7.80	18
OL	Jul-10	2.75 $\pm$ 1.18	1.10-5.40	17
M	Jul-10	2.88 $\pm$ 1.40	0.80-5.70	16



**Figure 3.33:** Comparison of mean serum vitamin E values (mg/l) of catfish sampled during November 2009. LK=Lunsklip Fisheries (n 20), OG=Olifants Gorge (n 15), and RV=Reënvoël Dam (n 15). ( $p < 0.001$ , vertical bars denote  $\pm$  standard errors).

The lower fifth percentile of serum vitamin E values (2.7 mg/l) in healthy fish from Reënvoël Dam was used to identify fish with depressed vitamin E values and the data was subjected to chi-squared analysis ( $p < 0.05$ ). Whereas the percentage of fish with depressed serum vitamin

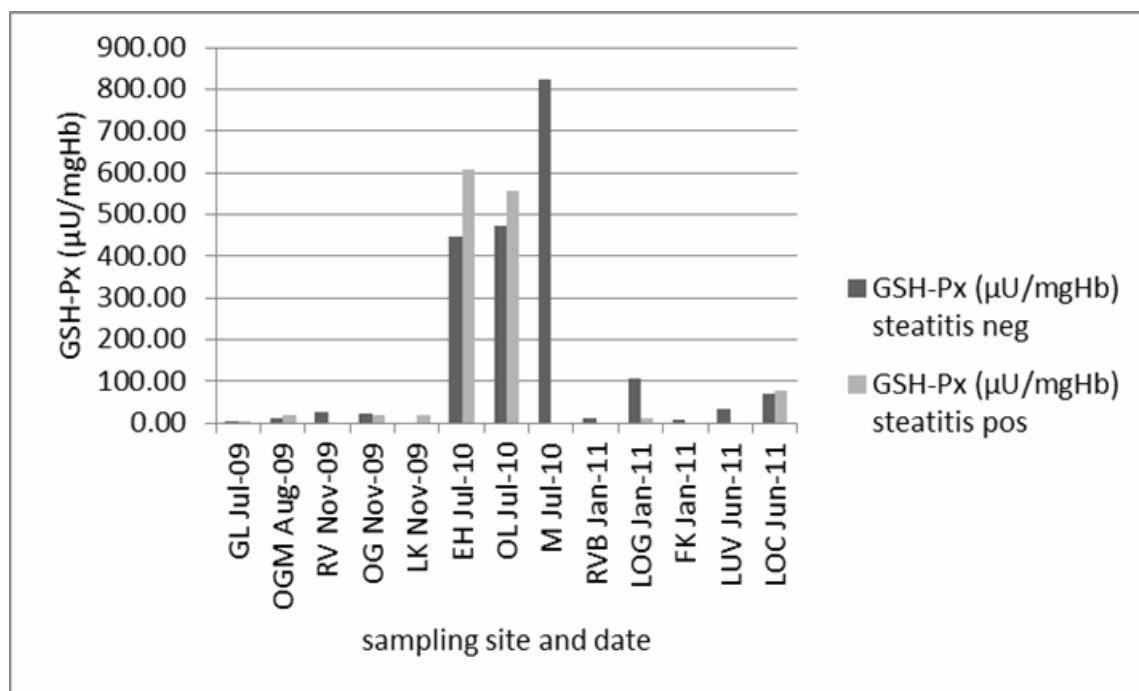
E values during the November 2009 sampling from the Olifants Gorge was similar to that of fish sampled from Reënvoël Dam and Lunsklip Fisheries in the same period, significantly higher percentages of fish with depressed serum vitamin E values were sampled from the Olifants Gorge and Mamba Weir during July 2010. Although at p values slightly above 0.05, numbers of fish with low serum vitamin E values sampled from the Olifants Gorge during August 2009 and from Engelhard Dam during July 2010 were indicative of a similar pattern of depression during these sampling episodes (Table 3.11).

**Table 3.11:** Percentage of catfish from the Olifants Gorge and other sites with serum vitamin E levels below the lower fifth percentile of values of healthy fish sampled from Reënvoël Dam. (Olifants Gorge=OGM, OG, OL; Lunsklip Fisheries=LK; Reënvoël Dam=RV; Engelhard Dam=EH; Mamba Weir=M)

Sampling site	Sampling date	% fish with vitamin E <2.7 mg/l	n
OGM	Aug-09	36	14
OG	Nov-09	7	15
RV	Nov-09	7	15
LK	Nov-09	10	21
OL	Jul-10	65	17
EH	Jul-10	33	18
M	Jul-10	50	16

### 3.2.3.5. Blood glutathione peroxidase

Exceptionally high erythrocyte glutathione peroxidase values were measured in catfish from three sampling sites during July 2010 (Figure 3.34). Fish with pansteatitis were found at all three of these sites. A comparison of erythrocyte glutathione peroxidase values measured in blood of catfish from the same sites in the Olifants Gorge on different sampling dates makes these high values appear suspicious and the results are inconclusive. No significant difference in erythrocyte glutathione peroxidase values could be demonstrated in fish sampled during November 2009 from the Olifants Gorge, Lunsklip Fisheries and Reënvoël Dam, and there was no significant difference in erythrocyte glutathione peroxidase values in fish with and without pansteatitis.



**Figure 3.34:** Mean glutathione peroxidase (GSH-Px) values ( $\mu\text{U}/\text{mgHb}$ ) of catfish with and without pansteatitis sampled from all sampling sites.

### 3.2.3.6. Discussion of haematology and blood chemistry

In catfish with pansteatitis from both the Olifants Gorge and Lunsklip Fisheries the oxidative stress resulting in steatitis appears to have remained limited to the adipose tissues as reflected in the pathology. For the selected haematology and blood chemistry parameters no significant differences could be detected between fish with and without pansteatitis from both the Olifants Gorge and Lunsklip Fisheries. This may have been a reflection of the chronic nature of the condition in these fish. At sites in the Olifants Gorge with high pansteatitis prevalence, significant numbers of catfish had depressed serum vitamin E values. Yet catfish from Lunsklip Fisheries with severe chronic pansteatitis showed normal serum vitamin E levels.

The increased number of polychromatocytes in blood smears from catfish from the Olifants Gorge and Lunsklip Fisheries (Table 3.7) indicated a higher erythrocyte turnover rate in these fish, possibly a result of dietary oxidative stress. Lipid peroxidation may be enhanced in erythrocytes due to direct exposure of the polyunsaturated fatty acids in the erythrocyte cell membrane to molecular oxygen (Tappel 1973). An increase in polychromatocytes has been described in channel catfish fed diets deficient in vitamin E and containing oxidised fish



oil (Murai & Andrews 1974) and in Atlantic salmon, *Salmo salar* L., fed diets deficient in vitamin E or selenium (Poston *et al.* 1976). In rainbow trout fed diets containing oxidised fish oils and deficient in vitamin E, crenation of immature erythrocytes was observed (Moccia *et al.* 1984). Under experimental conditions, severe anaemia developed after 13 weeks in rainbow trout when fed diets containing rancid fish oils and deficient in vitamin E (Smith 1979). In channel catfish fed vitamin E free diets in the absence of oxidised fish oil, anaemia developed after 16 weeks (Murai & Andrews 1974). It is unlikely that in the natural environment of the Olifants Gorge such extreme dietary conditions would prevail for this long. Examination of blood smears may provide an indication of current oxidative stress and hypovitaminosis E, but in this study did not assist the diagnosis of pansteatitis.

Changes in fluid partitioning between blood and lymph can be rapid, variable and pronounced during stressful episodes, such as occur during sampling of wild fish. This is a reflection of the close association of blood and lymph in fish (Branson 1993). Haematocrit levels in fish from all sampling sites were variable, and no significant variation could be demonstrated in haematocrit values between fish with and without pansteatitis. Osmotic disruption was impossible to avoid when catching fish despite attempts to minimise sampling stress. Catfish sampled from the KNP sites were caught on hook and line with the added risk of haemorrhage, particularly where the hooks had been swallowed. These fish had lower mean haematocrit levels than catfish sampled by netting from Lunsklip Fisheries (Figure 3.31). The different factors resulting in stress during sampling would have impacted on haematocrit values of the fish, limiting the usefulness of this parameter in the study of pansteatitis in wild fish.

Blood haemoglobin values represent the haemoglobin released by erythrocyte lysis in the laboratory as well as plasma haemoglobin from *in vivo* lysis of erythrocytes, as might be expected with oxidative stress. Increased haemoglobin catabolism observed in vitamin E deficient rainbow trout, caused by the degeneration and failure of polychromatocytes to fully mature, resulted in splenic haemosiderosis (Moccia *et al.* 1984). During the November 2009 sampling, the blood haemoglobin concentrations of fish sampled from Lunsklip Fisheries, which had a high prevalence of pansteatitis, were significantly lower than those in fish from Reënvoël Dam (Figure 3.32). Haemoglobin values of fish from the Olifants Gorge were even lower than those of fish from Lunsklip Fisheries. This may indicate a more protracted, higher erythrocyte turnover in affected fish, a change consistent with oxidative stress and reflected

in the observed haemosiderin deposits within hepatocytes and splenic and hepatic macrophages (Table 3.5). The wide range and the large differences in mean values in the fish from Reënvoël Dam measured during two sampling occasions (Table 3.9) indicated that factors other than pansteatitis were influencing the values. In experiments with blue tilapia, *Oreochromis aureus* (Steindachner), Roem, Kohler and Stickney (1990) found that haemoglobin concentrations remained unaffected by varying levels of dietary lipid and vitamin E. Under field conditions the interpretation of blood haemoglobin values in relation to pansteatitis may not be straightforward, limiting the usefulness of this test.

From the pathology in catfish from Lunsklip Fisheries it is evident that pansteatitis in these fish was chronic. The oxidative stress caused by prolonged ingestion of rancid dietary fats in the slaughter-house waste was the most likely inciting cause of the pansteatitis in these fish. During this study, only serum vitamin E levels were measured, and were normal in the catfish from Lunsklip Fisheries. Kelly *et al.* (1998) also ascribe a lipid protective role to ascorbic acid which acts through regeneration of tocopherol. Catfish from Lunsklip Fisheries might have benefited indirectly from the high vitamin E and ascorbic acid inclusion in the commercial diet fed to the trout, as some of the waste consumed by the catfish would have been fresh. Nevertheless, peroxidation of lipids in the adipose tissues of these fish leading to pansteatitis occurred. Serum vitamin E values may, therefore, not always reflect the increased consumption of vitamin E by the oxidative processes taking place in the adipose tissues.

Dietary sources of vitamin E in the natural aquatic habitat are numerous. Presence of steatitis lesions did not correlate with low serum vitamin E in catfish from the Olifants Gorge, but significant numbers of catfish with depressed vitamin E levels (Table 3.11) may have indicated a recent episode of dietary oxidative stress. Inconsistent results limited the usefulness of serum vitamin E as a monitoring tool for pansteatitis.

In aquatic systems oxidative stress studies have centred on depletion and induction of various antioxidant defences. In fish the antioxidant protective enzyme glutathione peroxidase shows higher basal activity than the enzymes superoxide dismutase and catalase when compared to other vertebrate systems, and it has been proposed that glutathione peroxidase is a suitable biomarker of oxidative damage in fish (Kelly *et al.* 1998). Measurement of blood values of glutathione peroxidase showed no statistical difference between catfish with and without pansteatitis from the Olifants Gorge. Differences in erythrocyte glutathione peroxidase values

were detected between sampling sites, but the significance of these occasional very high values is uncertain. There was no significant difference in mean erythrocyte glutathione peroxidase values between fish sampled from Lunsklip Fisheries and Reënvoël Dam, questioning the usefulness of this test for monitoring pansteatitis under field conditions.

The focus of this study was to determine whether some haematological and biochemical parameters in the blood and serum collected from live fish might serve as a monitoring tool for presence of pansteatitis in the fish of the KNP. Serum vitamin E and erythrocyte glutathione peroxidase measurements, shown to be useful in studying the acute manifestations of pansteatitis in cats (Fytianou *et al.* 2006), were of limited use for monitoring pansteatitis in catfish in the Olifants Gorge. The diagnosis of oxidative stress in live fish from the Olifants Gorge is complicated by the possible episodic exposure and the protracted chronic nature of the pansteatitis. More work needs to be done before these or similar tests can be used to monitor the status of fish non-lethally in these rivers. Determining malondialdehyde levels in the lipid fraction of serum by use of the thiobarbituric acid reactive substances assay still needs to be evaluated as a monitoring tool. Further markers of lipid peroxidation include the measure by mass spectrometry of F2-isoprostanes, prostanoids resulting from the *in vivo* free-radical-catalysed peroxidation of arachidonic acid (Awad *et al.* 1994). As free F2-isoprostanes in plasma reflect whole body lipid peroxidation these prostanoids may also be of value as a pro-oxidant marker in fish. The measure of F2-isoprostanes is used in the racehorse industry in South Africa but the cost of these tests was beyond the budget of this study. Although not a direct measure of lipid peroxidation, the associated damage to DNA structures provides a further opportunity for biomonitoring, and the comet assay has been suggested as a rapid, sensitive and inexpensive method of measuring DNA oxidation (Collins 2009; Klaude, Eriksson, Nygren & Ahnström 1996; Lee & Steinert 2003) and has been used to measure the effects of dietary antioxidants in human disease (Collins 2009).

#### **3.2.4. Pathology in other fish species**

Mozambique tilapia were difficult to catch in the Olifants Gorge. However a few specimens caught from the Letaba River at the confluence with the Olifants River at the entrance to the gorge appeared thin, despite presence of moderate mesenteric fat reserves. Distinctly demarcated pale areas of discolouration were noted in the livers of some of these fish. These were confirmed by histology to be zones of fat accumulation within hepatocytes. Such zones

are not uncommon in farmed tilapia. Gills of Mozambique tilapia specimens appeared normal. Mesenteric fat showed no evidence of steatitis. However, on histology one fish showed small amounts of lipopigment within macrophages associated with mesenteric adipose tissue. Distinct from catfish, Mozambique tilapia specimens showed no ceroid or haemosiderin deposition in the livers. All other organs appeared histologically normal.

Only one large specimen of the purple labeo, *Labeo congoro* Peters, was collected in the gorge. The gills of this fish manifested with an unusual severe fusion of the distal ends of the primary lamellae, a change that was not observed in either catfish or Mozambique tilapia. Similar gill lesions have been noted, with presence of cell bodies of the dinoflagellate *Ceratium* spp. trapped amongst the gill filaments, in rednose labeo from Lake Loskop during a *Ceratium* spp. bloom (J. Steyl, Faculty of Veterinary Science, University of Pretoria, pers. comm. 2012). Several smaller purple labeo specimens caught in the Olifants Gorge and the lower Letaba River did not show this gill fusion.

Pansteatitis could not be demonstrated in 5 tigerfish collected from the Olifants Gorge during September 2008 or in 21 tigerfish collected from the Olifants Gorge during June 2011. The fish were all in good condition with distinctly white mesenteric fat reserves. Fish sampled during June 2011 ranged in age from 1 to 10 years and both male and female fish were represented. All fish carried low numbers of larval nematodes in the peritoneal cavity; however, digenean trematode cysts were absent in all but one fish.

## **CHAPTER FOUR: PERSISTENCE OF PANSTEATITIS AFTER REMOVAL OF THE INCITING DIETARY CAUSE**

### **4.1. Introduction**

Pansteatitis has been identified in African sharptooth catfish in the Olifants River Gorge in the same area where crocodile deaths due to pansteatitis have occurred (see Chapter 3). An increasing prevalence of pansteatitis in catfish from the Olifants Gorge has been shown with repeated samplings from 2009 to 2011 (see Chapter 3). In some instances both old and recent lesions have been observed in the same fish. There is no published information on how long pansteatitis lesions persist after initiation of the lesions and whether the increasing prevalence was the result of increasing pro-oxidant challenge or whether it was the cumulative effect of repeated challenge at a lower level.

During investigation of pansteatitis in catfish the author identified a positive control group of fish suffering from pansteatitis, unrelated to developments in the Olifants River Gorge (see Chapter 3). A high proportion of catfish from this farm suffered from pansteatitis as a result of poor feeding practices. These fish provided a valuable control group to which the pathology of the KNP fish was compared; they also provided a unique opportunity to study the regression or progression of pathological lesions in the fat over time once the diet had been corrected. As far as the author is aware this has not been studied in fish before. In addition this information provides an insight to what has been happening in the Olifants Gorge crocodiles since the large die-off of crocodiles in 2008 and sheds light on whether the inciting cause of pansteatitis in the Olifants Gorge is on-going.

### **4.2. Hypothesis**

It is hypothesised that pansteatitis may change over time once the inciting cause has been removed; acute lesions will not continue to spread but lesions that have progressed to the chronic stage are unlikely to heal and will remain detectable in the fat of affected fish after prolonged periods. Furthermore, it is hypothesised that mobilisation of lipids from pansteatitis affected adipose tissues is likely to be compromised.

### **4.3. Objective**

The objective of this study was to study the regression/progression of nutritionally-induced pansteatitis lesions in catfish over time once affected fish had been removed from the inciting nutritional cause.

#### 4.4. Materials and Method

##### 4.4.1. Experimental design

Sharptooth catfish from a population of farmed fish suffering from pansteatitis, belonging to Lunsklip Fisheries (LK) (25°23'08,9"S 30°15'35"E), Mpumalanga Province, South Africa, were donated to the study. The fish were obese and weak as a result of the debilitating effects of pansteatitis, and experience from the farmer had shown that the survival of such fish was poor. The trial was started with 12 study fish with the anticipation that some might die as a consequence of the advanced pansteatitis. Ten control fish were sourced from Reënvoël Dam (RV) (23°58'37.2"S 31°19'38.4"E) in the KNP. The catfish in Reënvoël Dam have been identified as a reliable negative reference population (see Chapter 3). The mesenteric fat of LK fish was examined by laparotomy for gross lesions of steatitis, and a biopsy was taken for histological confirmation of the lesions. Both the control fish from Reënvoël Dam and the LK fish were kept in the same recirculated pond, mimicking a natural water body, for 11 months through the winter and into the next summer. At the end of this period both the LK and RV fish were euthanized, and post-mortem examinations were performed to establish whether pansteatitis was present. Mesenteric fat samples were collected and histological sections prepared by standard histological technique. Sections were stained with haematoxylin eosin and examined under a standard compound microscope to confirm presence of steatitis in both the biopsy and post-mortem sections of adipose tissue.

##### 4.4.2. Experimental facility

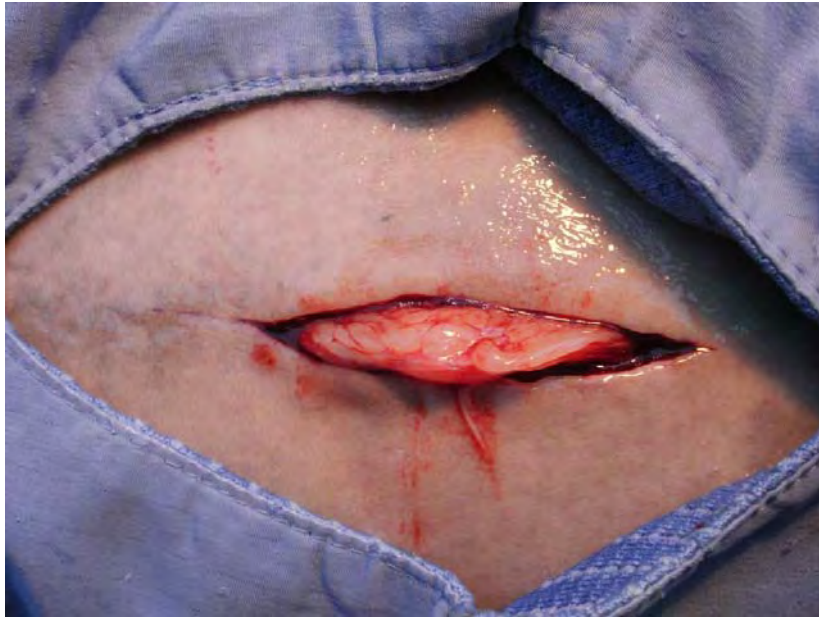The author's private recirculated fish facility was used for the experiment. This consisted of a 5 m<sup>3</sup> portable holding pond (Minurphy Tarpaulins, Pietermaritzburg) connected to a mechanical high pressure swimming pool filter filled with coarse sand, and a trickle tower filled with high surface area plastic media. The experimental pond consisted of a 150 m<sup>3</sup> concrete pool connected to a vortex chamber filled with nylon brushes, an artificial wetland and a mechanical gravel filter. Water was continuously recirculated through both systems. Water lost through daily flushing of the filters and through evaporation was added to the system from a borehole through a fine garden sprinkler to allow supersaturated gasses from the borehole water to escape. The experimental pond was in full sun and had a natural growth of phytoplankton. In addition to the experimental fish, the pond was stocked with koi carp, *Cyprinus carpio* L. and Mozambique tilapia. All fish were fed a commercial fish feed (Avi Feeds trout pellet), containing a standard vitamin premix including vitamin E, on a daily basis. The catfish were also able to feed *ad lib* on Mozambique tilapias that were breeding



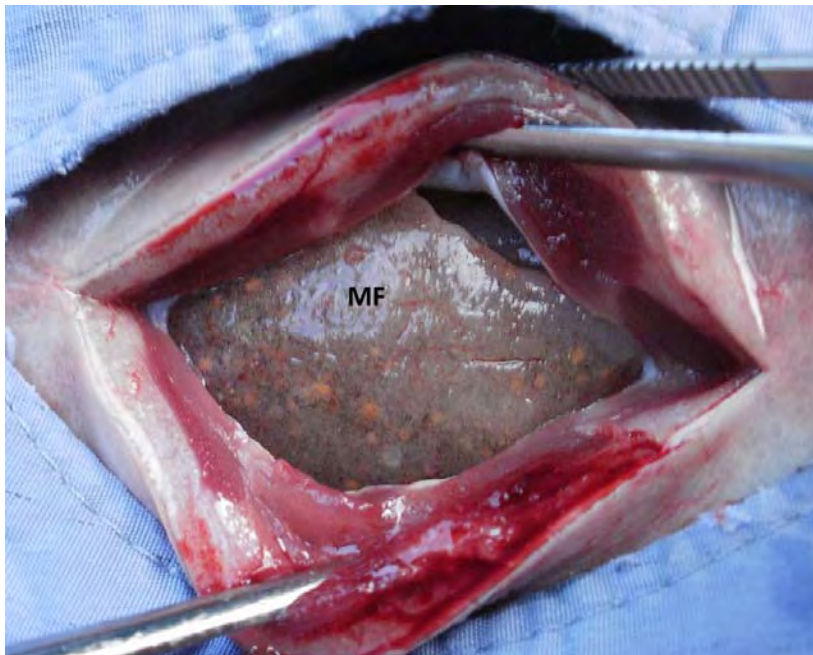
prolifically in the pond, providing a further natural food source. After 6 of the LK fish escaped from the pond 23 days from the start of the trial, the pond was fenced in with a 60 cm high chicken mesh wire fence.

#### **4.4.3. Experimental animal procedures**

Fish were caught live by scoop net and transported from Lunsklip Fisheries to the author's facility in a water-filled, 500 L fish transport container. The fish from Reënvoël Dam were caught by baited hook and line and were transported in a water-filled 250 L fish transport water container. Sharptooth catfish, being air-breathing fish, were transported without additional aeration of the transport water. The LK fish were initially held in the 5 m<sup>3</sup> holding pond. On the 1<sup>st</sup> and 2<sup>nd</sup> February 2011 the fish were individually anaesthetised in an anaesthetic bath containing 30 ppm benzocaine (Kyron Laboratories, Johannesburg). Once the fish had been anaesthetised they were weighed and the length measured, and the condition score determined. The condition score was assigned on a scale from 1 (emaciated) to 5 (obese). The anaesthetised fish were then placed into a wet cradle on their backs, and the head and gills covered by a clean wet towel. The surgical area along the ventral midline was prepared for surgery by disinfection with F10 Surgical Wound Preparation (Health and Hygiene, Johannesburg). The surgical field was covered by a window drape, and a 50 mm long midline incision was made through the skin with a scalpel, ending approximately 25-50 mm cranial to the pelvic bones (50-75 mm cranial to the cloaca) (Figure 4.1). The incision was extended through the skin, linea alba and peritoneum to reveal the underlying mesenteric fat (Figure 4.2).

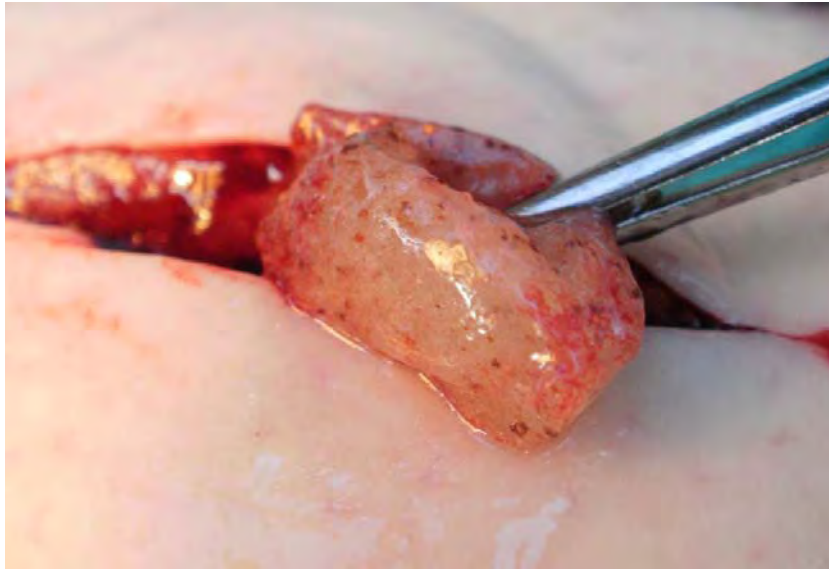


**Figure 4.1:** Laparotomy incision along the ventral midline of the abdomen of a test fish with mesenteric fat protruding from the incision.



**Figure 4.2:** Incision through skin, linea alba and parietal peritoneum of a catfish to access the underlying mesenteric fat (MF). Note severe steatitis of the mesenteric fat evidenced by the grey-brown colour and presence of granulomata visible beneath the surface of the fat.

The underlying mesenteric fat was inspected through the incision for signs of steatitis and a biopsy of affected adipose tissue, measuring approximately 10x10x15 mm, was removed and placed into 10% buffered formalin (Figure 4.3).



**Figure 4.3:** Removal of a fat biopsy through a ventral midline abdominal incision in a test fish. Note the obvious signs of steatitis in the fat biopsy.

Once the biopsy had been taken, enrofloxacin (Baytril 5% injectable, Bayer) at a dose of 5 mg/kg was injected into the peritoneal cavity. The wound was closed by tightly placed, simple interrupted sutures using 3/0 nylon with an atraumatic needle, each suture passing through skin, linea alba and peritoneum. The wound was sealed with Wound Gel Powder (in-house proprietary formulation for aquatic animals, Sterkspruit Veterinary Clinic, Lydenburg). Nylon mattress sutures (1/0) were placed into the soft tissue of the pelvic fins between the fin rays to identify individual fish numerically. The fish were then placed into the 150 m<sup>3</sup> recirculated fish pond and allowed to recover.

Control fish from Reënvoël Dam were received on 24 March 2011, 50 days after the laparotomies had been performed on the LK fish. They were initially placed into the 5 m<sup>3</sup> holding facility. Anaesthesia took place in an anaesthetic bath containing 30 ppm benzocaine. Once anaesthetised, the fish were weighed and measured, and condition scores were determined. No laparotomies were performed on the control fish, and the fish were not given

identification marks. The control fish were released into the same recirculated 150 m<sup>3</sup> pond with the trial fish.

At the end of the trial, from the 6<sup>th</sup> to 10<sup>th</sup> of January 2012, both the LK and RV catfish were euthanized by an overdose of clove oil. For euthanasia, fish were held in the anaesthetic bath until all life signs had ceased. All fish were again weighed and measured, and a detailed post-mortem examination was performed on each fish. The amount of mesenteric and pectoral fat was recorded as a score of 1 (negligible fat) to 5 (large amount of fat). The mesenteric fat was then dissected away from the organs and weighed. The various fat depots were evaluated for gross lesions of steatitis. Data sheets were completed for all gross observations and measurements. Samples of mesenteric fat, pectoral fat, intermuscular fat, liver, spleen and caudal kidney were collected from each fish and fixed in 10% buffered formalin. Five micron sections were prepared by standard histological technique, stained with haematoxylin eosin and examined under a standard light microscope. Data sheets were completed for all histological observations.

#### **4.5. Results**

At the beginning of the trial the LK fish were very much larger than the fish from Reënvoël Dam and carried considerable amounts of fat (Table 4.1 & 4.3). The laparotomies were performed on the 1<sup>st</sup> and 2<sup>nd</sup> February 2011. Fish took from 5 to 10 minutes to reach full surgical anaesthesia in the benzocaine anaesthetic bath. Surgical anaesthesia was indicated by a reduction in opercular movement, loss of voluntary movement and loss of the righting reflex when the fish were turned onto their backs. The anaesthetic level attained in the benzocaine bath was sufficient to last for the 10 to 15 minute duration of the surgical procedure. The laparotomy procedure through the abdominal midline required no haemostasis. Full recovery from anaesthesia took 10 to 20 minutes and was uneventful in all operated fish. Water temperature in the experimental pond varied from 24 to 26°C during February.

**Table 4.1:** Measurements of test fish at the start of the trial

Sample no.	Sex	Body mass (g)	Length (mm)	Body condition
LT1	M	8740	1050	5
LT2	M	8580	1100	3
LT3	F	9500	940	5
LT4	M	7000	980	4
LT5	M	6940	960	4
LT6	M	6500	900	4
LT7	F	9100	1080	4
LT8	F	6400	890	4
LT9	M	7800	960	5
LT10	M	10000	1200	2
LT11	M	6100	980	2
LT12	F	4780	890	3

**Table 4.2:** Measurements of surviving test fish at the end of the trial

Sample no.	Sex	Body mass (g)	Length (mm)	Body condition	Mesenteric fat mass (g)	Mesenteric fat score	Pectoral fat score
LT2	M	7000	1100	3	178	4	2
LT4	M	7000	980	5	652	5	3
LT5	M	6000	920	5	1110	5	3
LT7	F	7500	1080	4	42	2	3
LT8	F	7000	920	5	566	5	3
LT12	F	4000	860	3	240	4	3

**Table 4.3:** Measurements of control fish at the start of the trial

Sample no.	Sex	Body mass (g)	Length (mm)	Body condition
LC1	M	4660	820	3.0
LC2	F	380	400	3.0
LC3	M	440	540	2.5
LC4	F	380	400	2.0
LC5	M	400	410	2.5
LC6	M	500	400	3.0
LC7	F	460	390	2.5
LC8	F	560	420	3.0
LC9	M	480	390	3.0
LC10	F	380	400	3.0

**Table 4.4:** Measurements of control fish at the end of the trial

Sample no.	Sex	Body mass (g)	Length (mm)	Body condition	Mesenteric fat mass (g)	Mesenteric fat score	Pectoral fat score
LC1	M	3580	830	2	10	2.0	2
LC2	F	1006	470	4	22	3.0	3
LC3	M	1800	610	4	14	2.5	3
LC4	F	1100	615	4	8	2.0	3
LC5	M	1300	550	4	26	3.0	3
LC6	M	1100	540	4	12	3.0	3
LC7	F	1600	570	4	40	4.0	3
LC8	F	1100	500	4	8	2.0	3
LC9	M	1300	570	3	12	3.0	3
LC10	F	1050	520	3	30	4.0	3

The laparotomies in all 12 test fish revealed prominent mesenteric fat stores (Figure 4.1) with clear signs of pansteatitis consisting of a greyish discolouration of the fat and presence of numerous focally-disseminated to coalescing small (1 to 5 mm diameter) brown and white granulomata throughout the fat (Figure 4.2). The affected adipose tissue was rubbery in consistency. Removal of a biopsy from the mesenteric fat (Figure 4.3) was possible with



minimal bleeding and required no suturing of the mesenteric adipose tissue. Several of the female fish had large gravid ovaries that were visible through the laparotomy incision. Measurements of test and control fish are given in Table 1 and 3 respectively

A heavy rainstorm 23 days after the start of the trial enabled 6 of the LK fish to migrate out of the pond during the night. When found the next day they were still alive, however all six died over the next few days. The laparotomy wounds had healed completely and the sutures were still in place. Autopsies on these fish indicated that the abdominal incisions had healed without complications. Lesions of pansteatitis had remained unchanged over the 23 day period. Enclosure of the pond with a chicken mesh wire fence prevented further escapes.

During the first 6 months of the trial none of the LK fish were observed to take feed. They were shy to come to the surface other than to gulp air and, when seen, showed slow swimming movements. By comparison, the RV fish were observed to take commercial feed when fed at night within a few days of being released into the experimental pond. During the winter months of May, June, July and August the pond water reached a minimum temperature of 12°C, measured one meter below the surface, and neither the LK nor the RV fish were observed to take feed during this period. From the end of August onwards both LK and RV fish started to take commercial feed actively. The LK fish were, however, slower in their movements than the RV fish, and one particular fish was often observed hanging near the surface belly up as if dead. Whereas the RV fish would actively search for floating fish pellets on the pond surface using their feelers, the LK fish would appear at the feeding spot hanging vertically in the water, slowly rising to where their feelers would detect pellets, which would then be sucked into their mouths. Swimming movements of the LK fish remained sluggish. The RV fish in contrast made strong dashing movements and were quick to be startled. Both groups of fish could only be observed after dark using a torch. It was not possible to establish whether the catfish were feeding on the Mozambique tilapia; active hunting of these fish was not observed.

Both the test and control fish were euthanized after the 11 month trial period. The measurements of the test and control fish at the end of the trial are given in Table 4.2 and 4.4 respectively. Four of the surviving test fish had lost weight over the trial period; one fish maintained the same weight and one fish gained in weight. Over the same period all of the test fish either maintained the same body condition or gained condition. A 30 to 40 mm

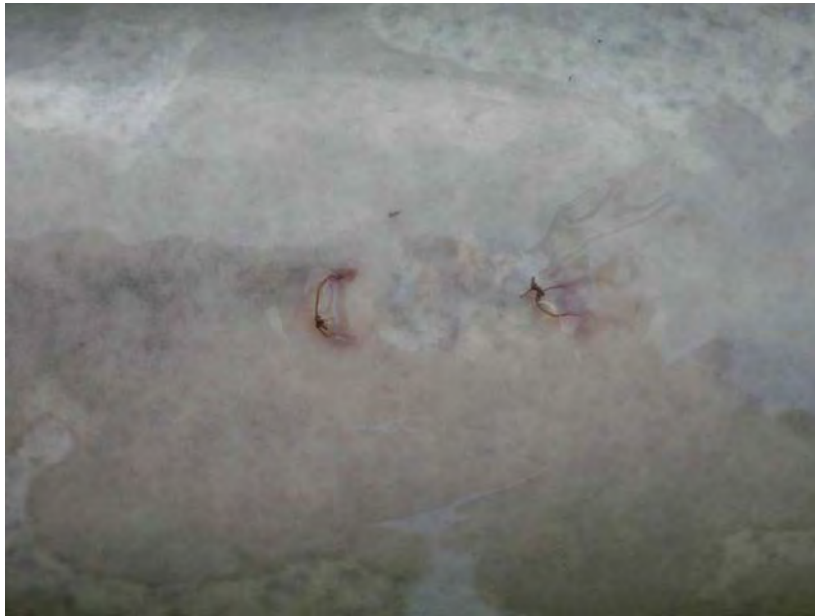length reduction was measured in two of the test fish at the end of the trial. With the exception of the largest of the control fish, all the control fish increased in weight, the majority more than doubling in mass over the trial period.

At the end of the trial all 3 female test fish had mature gonads and were gravid with eggs, despite the severe degree of pansteatitis present. The 3 male fish showed only moderate testicular development. Of the control fish 3 of the 5 female fish had mature gonads and were gravid with eggs, one female had a moderately mature ovary and one female had an immature ovary. As in the case of the test fish, the gonads of the five male control fish showed only moderate testicular development.

The laparotomy wounds of the test fish had healed completely leaving barely discernible scars after the 11 month trial period (Figure 4.4a). All but one fish had rejected the nylon sutures used to close the wounds (Figure 4.4b).

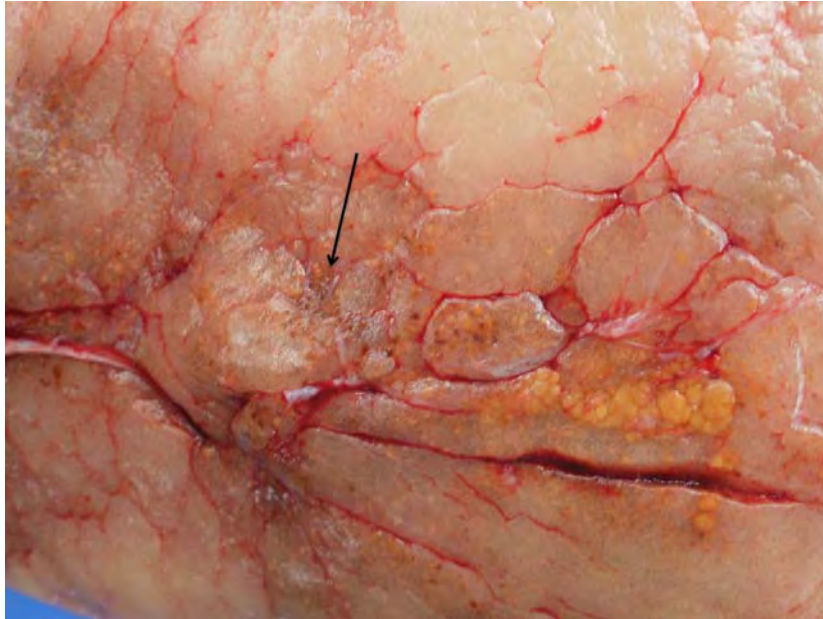


**Figure 4.4a:** Male test fish showing the scar of the laparotomy incision in the ventral abdominal skin, at the end of the 11 month trial period. This fish had rejected all of the original nylon sutures.

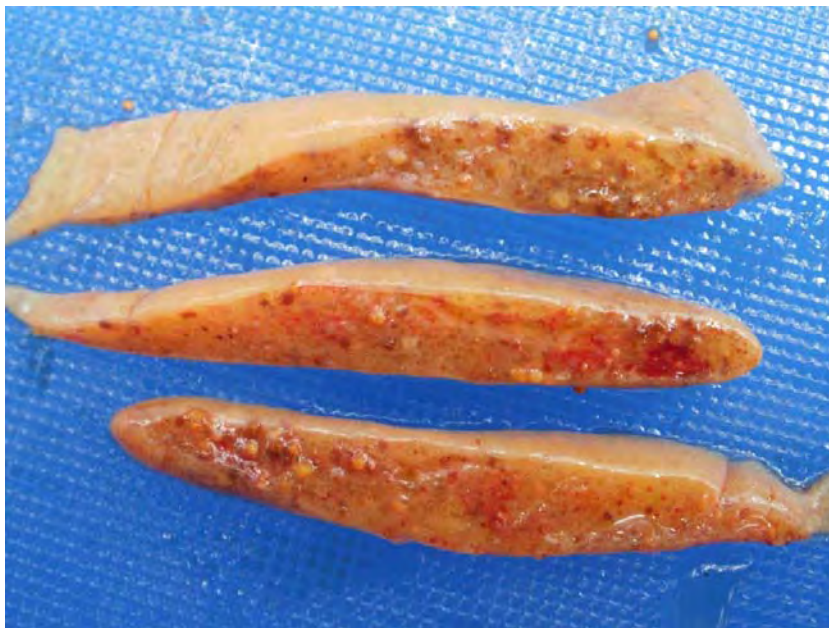

**Figure 4.4b:** Laparotomy scar in the abdominal skin of a test fish after the 11 month trial period showing good healing despite retention of 2 nylon sutures.

The majority of sutures placed in the pelvic fins to identify the fish had been rejected, but it was possible to identify individual fish from their sex and length measurements. At post-mortem examination no adhesions were observed between the parietal peritoneum covering the laparotomy scar and the visceral peritoneum covering the adjacent mesenteric adipose tissue. A barely discernible fibrous scar could be observed at the site from which the biopsy had been taken (Figure 4.5). Re-examination of the adipose tissues of the test fish, 11 months after the original biopsies were taken, confirmed that a severe degree of steatitis was still present throughout the adipose tissues of the fish (Figures 4.6a & 4.6b).



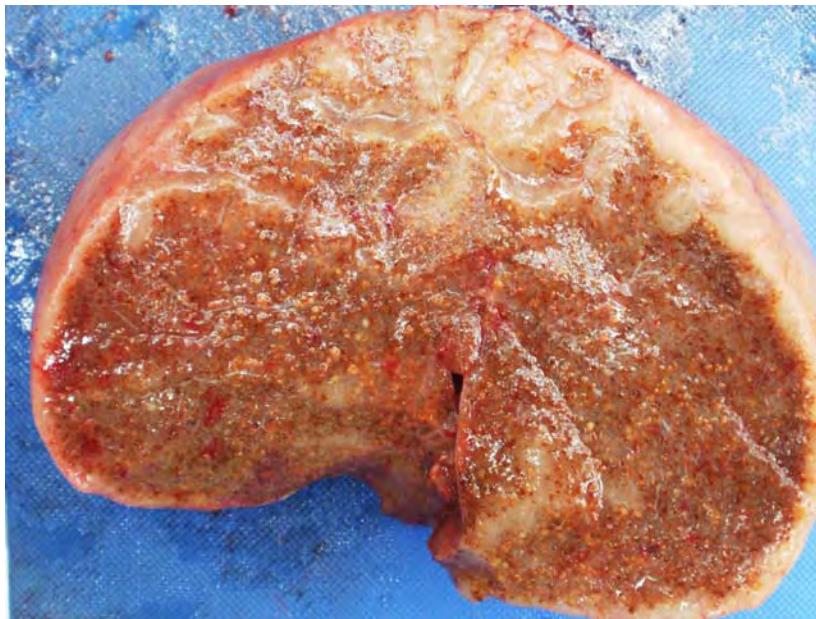**Figure 4.5:** Surface of mesenteric fat body of a test fish after the 11 month trial period showing minimal scar formation where the biopsy had been taken (arrow).



**Figure 4.6a:** Cross section from the edge of mesenteric fat of a test fish at the end of the 11 month trial period showing distinct yellow and brown granulomata and smaller brown spots dispersed throughout the fat.

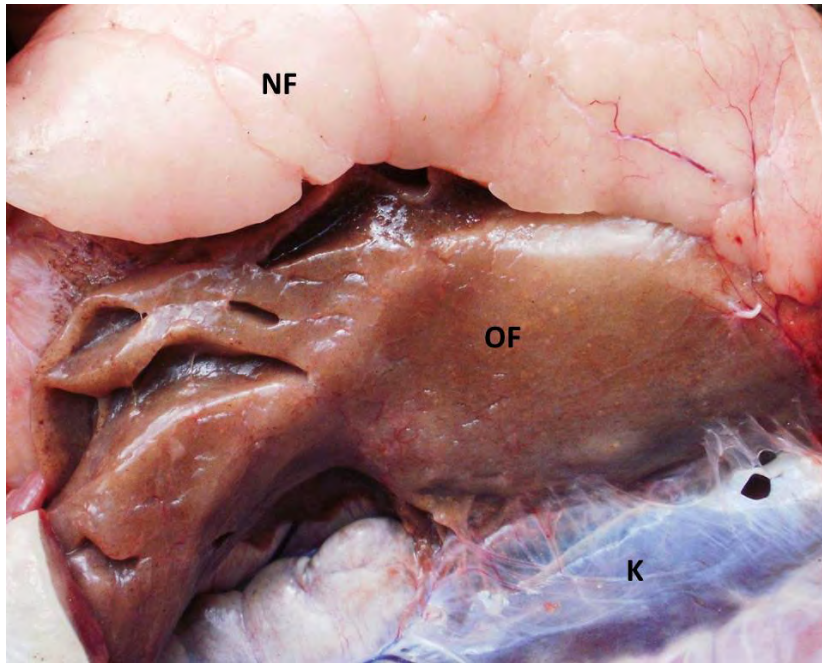


The mesenteric fat bodies had not reduced in size visibly since the start of the trial and retained the rubbery texture noticed at the outset of the trial. Numerous focally disseminate to coalescing small brown granulomata (1-5 mm diameter) were dispersed throughout the mesenteric fat, and in some fish there was a clear demarcation of areas of fat with varying severity of steatitis (Figure 4.6b).

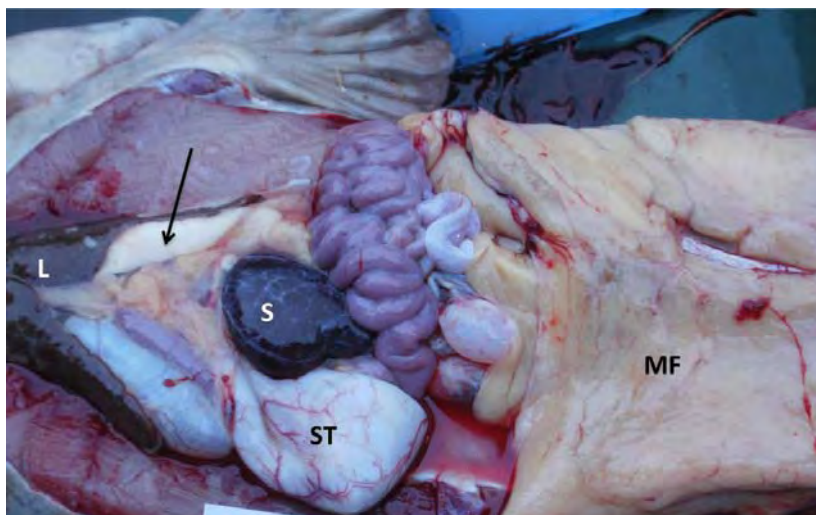


**Figure 4.6b:** Cross section of mesenteric fat body retained after the 11 month trial period. Note more recently deposited white fat on the surface of the fat body, whereas the bulk of the fat body shows intense granulomata formation imparting the brown colour.

This was particularly evident in one fish that died after escaping from the pond 23 days after the laparotomies had been performed (Figure 4.7). Mesenteric fat, severely affected by steatitis, was greyish brown in this fish, whereas adjacent mildly affected fat appeared almost white with only a few widely dispersed small brown spots and may have been deposited more recently. The whiter fat had the typical oily feel of fish fat, whereas the grey brown fat had the rubbery consistency typical of the fat of catfish with severe pansteatitis. At the end of the trial one fish showed deposition of what appeared to be new white fat without granulomata in the mesentery between the liver and the main body of pansteatitis-affected fat in the caudal mesentery (Figure 4.8).



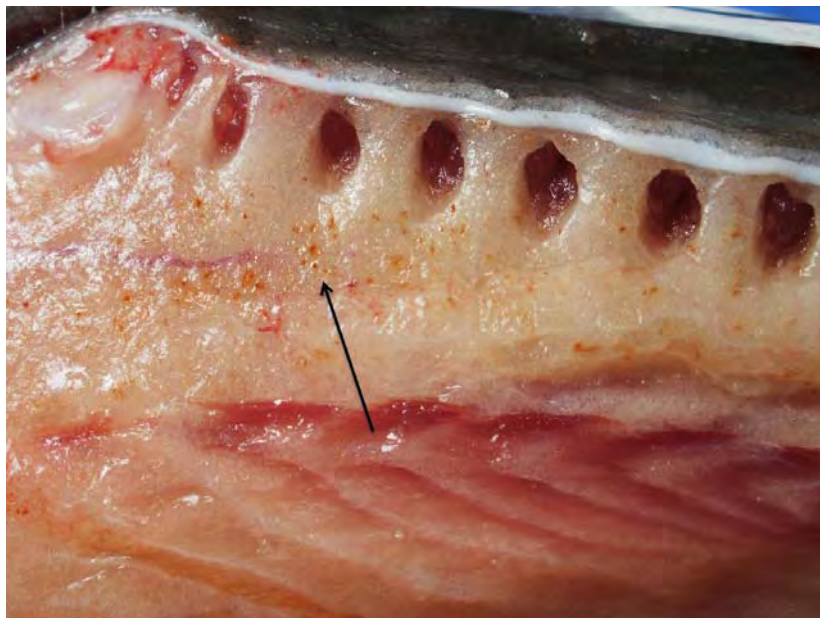
**Figure 4.7:** Mesenteric fat of a test fish that died 23 days after the start of the trial. Note the severely affected older fat (OF) deposited in the mesentery closest to the kidney (K) that has taken on a diffuse brown colour due to the intensity of small granulomata in the fat, and the white more recently deposited fat (NF).



**Figure 4.8:** Ventro-dorsal view of the abdominal cavity of a dissected test fish at the end of the 11 month trial. Note the large amount of mesenteric fat (MF). Recently deposited white fat (arrow) can be observed in the mesentery caudal to the liver (L). Also note the large rounded spleen (S). Stomach (ST).



Steatitis was not observed in the pectoral fat of any of the test fish, however, several test fish showed presence of steatitis in the intermuscular fat. This was particularly evident in the fat adjacent to the pterygiophores (Figure 4.9).



**Figure 4.9:** Steatitis of the intermuscular fat in the region of the pterygiophores of a test fish at the end of the 11 month trial period. Note focally disseminated small brown spots in the adipose tissue (arrow).

Histological examination of sections of mesenteric fat from the start and end of the trial revealed the same type of lesions. These consisted of focal to coalescing, roughly circular, areas of lipopigment surrounded by a prominent macrophage reaction with presence of Langhans giant cells. Affected foci were variably infiltrated with fibroblasts and showed some deposition of connective tissue. On histological examination the mesenteric fat from the control fish showed no abnormality. Adipocyte cell walls were well defined, the cell content appearing as empty space due to the solvent extraction of the fat content of the cells, and a narrow nucleus could be observed on the margin of the cells. No inflammatory cells could be detected, and the sections were devoid of fibroblasts and connective tissue. Sections of pectoral fat of both the test and control fish showed no sign of steatitis. Whereas some test fish showed steatitis in the intermuscular fat, control fish showed no lesions.

#### 4.6. Discussion

Visual assessment of the mesenteric fat reserves of the test fish, through the laparotomy incision at the start of the trial, indicated that these fish carried a large amount of fat in the mesenteries. Histological examination of biopsies of this fat indicated that the fat was severely affected by pansteatitis. At the end of the 11 month trial, the test fish, having survived the winter and losing body weight, had all retained large fat reserves, affected severely by pansteatitis. Utilization of fat reserves is dependant on lypolysis of the adipose tissues. In non-feeding fish, concomitant with a loss in body weight, the mesenteric fat reserves would be expected to reduce visibly after the winter. In the test fish, these fat reserves, evaluated subjectively, appeared to remain unchanged. This lends support to the observations of Danse and Verschuren (1978b) that, in rats, lipolysis, although unaffected in early stages of steatitis, is blocked in the more advanced stages of the disease. The decrease in hormone-stimulated lypolysis was found to be proportional to the number of degenerated fat cells, most likely as a result of membrane damage in the affected fat cells preventing activation of lipase (Danse & Verschuren 1978b).

Histological examination of biopsies taken from the fat at the start and end of the trial confirmed that the histological appearance of the lesions in the fat had not changed. A reduction in body mass of the test fish compared to the weight gains of the control fish over the trial period appeared to support the observation that the test fish were markedly compromised by the pansteatitis affecting their adipose tissues. The reduction in body length noted in two of the test fish at the end of the trial was a result of erosion and shortening of the tail fin. Most of the control fish were much smaller and probably younger than the test fish. Age related factors may also have contributed to the reduction in body mass observed in the test fish, as the only very large control fish also lost weight during the trial. This may have been a result of senescence, as the fish was very large and showed no other signs of pathology.

During the last 4 months of the trial the test fish fed actively, and when euthanized at the end of the trial small amounts of healthy fat were found adjacent to the pansteatitis-affected mesenteric fat in a few fish. Persistence of pansteatitis-affected fat, while new healthy fat appears to have been deposited, supports the argument that, in catfish, fat tissues severely affected by pansteatitis are irreversibly damaged. Once the initial incitement of fat necrosis by oxidative processes has passed or the intake of vitamin E has improved, newly deposited

fat appears to remain unaffected by the inflammatory processes attempting to deal with the fat necrosis in the adjacent disturbed tissues. In cats, early cases of pansteatitis are treatable, and recovery occurs after administration of vitamin E and corticosteroids and correction of the diet (Niza *et al.* 2003). In older cats with severe chronic pansteatitis, the prognosis for recovery is poor despite treatment (Niza *et al.* 2003; White 2000).

During the first two months of the trial, which were warm, the test fish refused to take feed, nor did they feed during the subsequent winter months. Most poikilothermic animals will reduce feed intake or stop feeding when ambient temperatures drop too low. Sharptooth catfish have a wide distribution throughout the whole of Africa and are more temperature tolerant than many indigenous fish species, yet they will stop feeding during the winter at the temperatures experienced in Lydenburg. The fish were released into the experimental pond during February when water temperature was still between 24 and 26°C. Water temperatures only dropped below 20°C from April onwards, reaching 12°C by June. When the water warmed up after the winter the test fish started to feed for the first time. This was 6 months from the start of the trial. The failure to feed during the first 2 months may have had several reasons. It was not possible to establish whether the test fish were feeding at the time when they were caught at Lunsklip Fisheries and moved to the experimental facility. As they had been caught by scoop net, it can be presumed that they would have been amongst the weaker fish in the population. The debilitating effects of advanced pansteatitis, evidenced by the observed weak swimming movements and abnormal bouyancy, may have initially discouraged the test fish from actively seeking feed. These fish, previously fed exclusively on trout slaughterhouse waste, may have become conditioned to this type of diet and needed time to become accustomed to a commercial pelleted diet. The control fish, which were smaller and probably much younger and used to a diverse natural diet, may have been more adaptable, as they were keenly taking the commercial pellets within days of the start of the trial. Tilapia sleep at night, and the numerous fry and fingerlings in the pond were easy prey for the nocturnally feeding catfish. Limited visibility in the water, due to phytoplankton growth, restricted feeding observations to the surface of the pond, and the extent to which the fish were preying on tilapia could not be established.

Even though they were severely affected by pansteatitis the condition was not rapidly fatal in the test catfish. Steatitis has been reported as an incidental finding at slaughter from apparently healthy farmed channel catfish (Goodwin 2006) and American alligators (Larsen

*et al.* 1983). Pansteatitis is a painful condition in cats (Fytianou *et al.* 2006; Niza *et al.* 2003) and horses (de Bruijn *et al.* 2006), and probably also in other species. In contrast to crocodiles, where the intermuscular fat was most severely affected in cases of pansteatitis (F. Huchzermeyer, Faculty of Veterinary Science, University of Pretoria, pers. comm. 2009), the intermuscular fat of catfish was often unaffected or only mildly affected, even in individuals where steatitis of the mesenteric fat reserves had progressed to an advanced stage. This difference in susceptibility of the different adipose reserves of the body of catfish may provide the explanation why these animals remain reasonably mobile even when severely affected by pansteatitis.

#### **4.7. Conclusion**

After the diet had been changed, pansteatitis lesions persisted in the adipose tissues of the test fish virtually unaltered over the 11 month period of the trial, and control fish fed the same diet remained healthy. The results suggest that pansteatitis in catfish is not rapidly fatal, and the presence of chronic pansteatitis lesions does not imply recent exposure. Lesions may accumulate over time, with periodic or seasonal exposure to dietary oxidative stress. The retention of large mesenteric fat stores, affected by pansteatitis, after prolonged starvation, suggests a reduction in lipolysis in pansteatitis-affected adipose tissue. Deposition of healthy fat adjacent to pansteatitis-affected fat indicated that, despite the severe degree of pansteatitis, adipogenesis was not compromised in the test fish. The cold-tolerance of the test fish appeared unaffected by the severe degree of pansteatitis in the fish. Compared to control fish, test fish showed weaker swimming movements and some were unable to regulate buoyancy.

## CHAPTER FIVE: EXPOSURE OF FISH TO SEDIMENTS FROM SITES WHERE PANSTEATITIS HAS OCCURRED

### 5.1. Introduction

Pansteatitis was found to be the cause of death of large crocodiles in the Olifants Gorge in the KNP in 2008 (Ferreira & Pienaar 2011) and to a lesser extent in the Sabie River in the Sabiepoort of the KNP in 2009 (D. Pienaar and D. Govender, SANParks, Skukuza, pers. comm. 2009). Pansteatitis was identified in African sharptooth catfish inhabiting the Olifants Gorge in the same area where crocodile mortalities occurred. Large dams in the Olifants River catchment act as traps for sediments, nitrates, phosphates and heavy metals and are regarded as the epicentre of recent mortalities of fish and crocodiles (Heath *et al.* 2010). Over time, changing water quality may cause sediment-bound contaminants to become bio-available and result in bio-accumulation in fish tissues.

When the pansteatitis deaths amongst the KNP crocodiles were first noticed in 2008, SANParks opened a docket with the South African Police (SAP) in the belief that the crocodiles might have been poisoned. A pollution-related aetiology was suspected stemming from the known high levels of pollution impacting the Olifants River catchment (Botha *et al.* 2011; Coetzee, du Preez & van Vuuren 2002; de Villiers & Mkwelo 2009; Heath *et al.* 2010; Oberholster *et al.* 2011). As a result the SAP Forensics Laboratory became involved in the on-going investigation. The forensics team was working in association with Prof H. Bouwman from the University of the North West to carry out toxicological evaluation of the sediments from the Olifants Gorge and Sabiepoort and tissues of fish and crocodiles.

During a sampling trip along the Olifants River gorge from 3 to 7 August 2009 the team of researchers, including the author, was given the opportunity to inspect and collect samples from the normally inaccessible section of the gorge that lies on the Mozambique border and opens into the inlet to Lake Massingir. It is in this area that the river deposits a large part of its load of silt since the raising of the Massingir dam wall in 2007 (Figure 5.1). On 8<sup>th</sup> July 2009, for the first time, a large scale fish die-off involving almost exclusively large sharptooth catfish was noticed over this area (D. Pienaar and D. Govender, SANParks, Skukuza, pers. comm. 2009). The fish kill remained localized in space and time. Unfortunately the fish carcasses were already in an advanced stage of autolysis when detected and cause of death could not be established. It was however noted that the catfish



carcasses were obese. This portion of the river is remote, and periodic fish kills may have gone unnoticed in the past. Large crocodiles favour the same area due to the presence of mud banks that provide suitable basking spots. During the period that the team worked in this area the carcasses of four large crocodiles were found that had succumbed from the effects of pansteatitis. There was a suspicion that sediments in this area of the Olifants Gorge might contain toxic pollutants and the opportunity was taken to collect samples for a bio-assay trial.



**Figure 5.1:** Silt deposits in the Olifants Gorge at the inlet to Lake Massingir on the South African-Mozambique border in KNP.

## 5.2. Objective

The objective of this experiment was to establish whether or not pansteatitis or other pathology could be induced in juvenile catfish held in water over sediments from the Olifants Gorge and the Sabie River.

## 5.3. Materials and Method

Sediments were collected on 6 August 2009, using a sediment grabber manufactured by the SAP Forensics Laboratory. Samples were collected from several random sites of differing depth at the inlet of Lake Massingir where the Olifants Gorge opens into the lake on the Mozambique border (S:23°57'48" E:031°52'97"). The collected samples were pooled and transferred wet into 20 L plastic containers for transportation. Control sediments were



collected from a pool in the Bangu River, a tributary of the Olifants River in KNP that is regarded as relatively unpolluted.

Two days later SANParks collected further sediment samples from the Sabie River where this river flows into Lake Corumana in the Sabiepoort on the South African-Mozambique border of the KNP. The sediment samples were all transported wet to Lydenburg where an experimental facility was put in place.

Three duplicate pairs of trial tanks were set up for the respective sediments from the Olifants Gorge, Bangu River and Sabie River on 9<sup>th</sup> August 2009 (Table 5.1). The tanks were cylindrical and manufactured of polyethylene (Sinvac Plastics, Pretoria). A further 3 glass aquaria of 26 L volume were set up containing a portion of the same sediments.

**Table 5.1:** Respective experimental tank and sediment volumes used for the bio-assay trial

Tank number	Sediment source	Tank volume (L)	Sediment volume (L)
OG1	Olifants Gorge	262	86
OG2	Olifants Gorge	159	29
B1	Bangu River	262	49
B2	Bangu River	146	29
S1	Sabiepoort	262	45
S2	Sabiepoort	108	20

The tanks were housed in a plastic-covered greenhouse and were used as a stagnant water system. Being intended for use with catfish, an air-breathing species, no provision was made for aeration or filtration of the water, and bacteria from the sediments, suspended in the water column, were expected to supply sufficient biological filtration capacity for the relatively small fish biomass. The respective sediments were added to each tank (Table 5.1) and borehole water was added to fill the tanks. A sample of approximately 250 ml of each sediment was retained and frozen for future toxicological analysis. Sediment made up between 18% and 32% of the trial tank volume (Table 5.1). The sediments were mixed thoroughly with the water and then left to stand. Suitably sized catfish fingerlings were not available until 3<sup>rd</sup> January 2010, when 23 fingerlings (25-45 mm body length) were

transferred into each of the larger tanks (OG1, B1 and S1) containing the respective Olifants Gorge, Bangu and Sabie River sediments. The smaller tanks (OG2, B2 and S2) were each stocked with 35 Mozambique tilapia fingerlings (20-25 mm body length). Further tilapia fingerlings were added to tanks OG1, B1 and S1 as an extra food source for the catfish. The fish were all fed a commercial trout diet (Aquanutro).

The aquaria were placed indoors on a sunny window sill and stocked with *Daphnia* spp. (an aquatic filter-feeding crustacean). *Daphnia* in the aquaria were observed from 10<sup>th</sup> August until 26<sup>th</sup> August, after which algal growth on the tank sides made observations difficult.

The fish were kept in the trial tanks until 3 March 2011 and were not fed for 24 hours before the tanks were drained and the fish removed and euthanized with an overdose of benzocaine. The catfish were dissected and examined for gross pathology. Tissue samples from the mesenteric and pectoral adipose tissues, the liver, pancreas, spleen, kidney, heart, gonad (where sufficiently developed), muscle, skin and gills were collected and immediately fixed in 10% buffered formalin. The remainder of the carcasses were frozen for future toxicological analysis. Mozambique tilapia that had survived in the trial tanks were not examined.

Formalin fixed tissue samples were prepared by standard histological technique and 5 µm sections were stained with haematoxylin and eosin and examined by standard light microscopy.

#### **5.4. Results**

During the 16 day period during which the *Daphnia* were observed they appeared to thrive in all three aquaria and no adverse effects were observed.

Water temperature in the tanks at the start of the trial was 16°C. The temperature dropped to 12°C during the winter and reached a high of 26°C during the summer months. Within 24 hours of stirring up the sediments in the experimental tanks at the outset of the trial the colloidal suspended clay particles started to settle out, and the water began to clear. Once the catfish fry were added to the tanks the water increased in turbidity within days, as the catfish began to stir up the sediments. The tanks remained turbid due to suspended sediment for the duration of the trial. Except for 2 catfish that had jumped out of the B1 tank, on 21<sup>st</sup> October 2010, no mortalities were observed amongst the catfish during the trial period. The catfish

were observed to feed actively, mainly at night. In the turbid water it was not possible to monitor the actual numbers of fish in the tanks. Some catfish appeared to grow rapidly and were most often observed at the surface during feeding times. The tilapia fingerlings remained deep in the tanks and even at feeding times were seldom seen. Between 25<sup>th</sup> December 2010 and 14<sup>th</sup> March 2011 the tilapia died in the S2 tank as a result of oxygen depletion. No deaths were noted in the S1 tank. On 14<sup>th</sup> March 2011, 7 and 8 tilapia also died of oxygen depletion in the OG2 and B2 tanks respectively.

Measurements of the surviving catfish at the end of the 14 month trial are presented in Table 5.2. From this table it can be seen that of the original 23 catfish stocked into each trial tank 17% survived up to the end of the trial in the Olifants Gorge sediment tank and ranged in mass from 36 to 260 gram and in length from 175 to 330 mm. In the Sabiepoort sediment tank, 52% of the catfish survived and ranged in mass from 12 to 72 gram and in length from 130 to 230 mm. In the Bangu sediment tank, 30% survived with a range in body mass from 14 to 80 gram and a length of 135 to 315 mm.

**Table 5.2:** Measurements of surviving catfish at the end of the 14 month trial period (OGST1-OGST4=Olifants Gorge sediment; SST1-SST12= Sabiepoort sediment; BST1-BST7=Bangu sediment)

Fish no.	Sex	Mass (g)	Length (mm)	Body condition score	Mesenteric fat score
OGST1	M	260	330	3	3
OGST2	M	80	200	3	4
OGST3	F	86	222	3	4
OGST4	F	36	175	3	3
SST1	M	38	183	3	3
SST2	F	72	216	3	3
SST3	F	22	149	3	4
SST4	F	12	130	2	1
SST5	F	22	155	3	4
SST6	M	70	230	3	2
SST7	F	44	190	3	3
SST8	M	36	180	3	3
SST9	F	28	160	3	3
SST10	F	50	200	3	4
SST11	M	44	190	3	4
SST12	F	24	153	3	3
BST1	F	50	205	3	3
BST2	F	64	210	3	4
BST3	M	80	235	3	2
BST4	F	44	190	4	4
BST5	F	78	315	4	4
BST6	F	18	140	3	3
BST7	F	14	135	2	2

Dissection of the organs revealed white to pale cream mesenteric fat in all the fish. Livers of fish from all three sediment tanks were a pale ochre colour. No abnormalities were discernible in the other organs and tissues. The fish from all three tanks showed no signs of parasitosis. Sand grains were found in the stomachs of 2 of the 4 OGST fish, and sediment

detritus and clay was found in the intestines of all the OGST fish. Sediment detritus was found in the stomach content of 3 of the 12 SST fish, and 5 SST fish had sediment detritus and clay in the intestines. All the BST fish had empty stomachs, and 5 had sediment detritus and clay in the intestines. Despite the relatively small size, two female SST fish and one female OGST fish had almost fully mature ovaries; the gonads of the remaining fish showed mild to moderate development. Histological examination revealed no abnormalities in the organs and tissues examined. Steatitis could not be detected in the adipose tissues of any of the trial fish.

The Mozambique tilapia had grown slowly throughout the trial, and because of the small size, it was felt that nothing would be gained from dissecting them. No mortalities other than those caused by oxygen depletion were noticed in the OG2, S2 and B2 tanks. Survival of tilapia in the OG1, S1 and B1 tanks where they were stocked together with the catfish was poor, with 3 and 4 fish surviving to the end of the trial in the OG2 and B2 tanks respectively.

## 5.5. Discussion

As a result of the *ad hoc* decision to utilize sediments for a bio-assay, a makeshift experimental facility was put up at very short notice. The benthic habits of the catfish became evident within days of stocking the fish into the experimental tanks, and for the duration of the trial the fish actively kept sediment suspended in the water column, confirming the close association of this species with the sediments. Examination of stomach and intestinal content at the conclusion of the trial confirmed that the catfish were ingesting sediment prior to being euthanized. The results of this trial showed that the catfish thrived normally in the tanks containing sediments from the Olifants Gorge, the Sabiepoort and the Bangu River over the 14 month trial period. No differences could be detected in the gross and microscopic appearance of the organs of the three groups of fish, and pansteatitis was not detected in any of the fish. *Daphnia* survived for a full 16 days during which they were exposed to the respective sediments, suggesting that the sediments were not acutely toxic to this invertebrate filter feeder.

Mozambique tilapia fingerlings used in the duplicate trial tanks were not the ideal target fish for the trial and were found to grow slowly under the experimental conditions. During the later stages of the trial the duplicate sediment tanks, OG2, S2 and B2 proved to be too small for the tilapia biomass in the tanks, and tilapia died as a result of oxygen depletion. Tilapias

are known to sleep at night, resting near the bottom of waters, where they become easy prey for catfish that are nocturnally active (Bruton 1979). In the OG1, S1 and B1 tanks most of the tilapias were consumed by the catfish, tilapia being a favoured prey species of catfish (Bruton 1979). Catfish are also renowned for their cannibalistic tendencies when young, and have been observed to prey on other catfish up to half their own length (Groenewald 1964). In the confined space of the experimental tanks it was obvious that the catfish had preyed on each other. This was most noticeable in the OG1 tank where one fish reached a size of 260 gram over the trial period. This represented a 722% size increase over the smallest surviving fish in this tank.

This study attempted to address the question of whether possible bio-accumulation of contaminants released from sediments resulted in pathology in fish exposed to such sediments. Results of the field study (see Chapter 3.2.1.1) indicated that, in the Olifants Gorge, pansteatitis was not present in catfish under 3 years of age and the 14 month sediment-exposure study may have been too short to demonstrate development of pansteatitis. Although not conclusive, the results of this trial suggest that the Olifants Gorge and Sabiepoort sediments were not significantly toxic to sharptooth catfish fingerlings, and attempts to induce pansteatitis or other pathology by exposure to these sediments was unsuccessful in these fish within the limited scope of the trial. Chemical analysis of the sediments and tissue samples, by other researchers, was beyond the scope of the study and was still on-going at the time of completion of the study.



## CHAPTER 6: GENERAL DISCUSSION

### 6.1. Introduction

When crocodiles were found to die of pansteatitis in the KNP in 2008, the author suggested to SANParks that, as pansteatitis was believed to be a nutritional disease, and crocodiles in the Olifants Gorge were likely to feed on fish, similar pathology might be found in fish inhabiting the waters of the gorge. The author subsequently discovered pansteatitis in wild African sharptooth catfish in the Olifants Gorge and several other localities in the KNP, in particular the Sabiepoort on the Sabie River where crocodiles have also died from pansteatitis. As far as the author is aware pansteatitis has not been described before from wild African sharptooth catfish in their natural habitat. This finding adds important information to the scientific knowledge on pansteatitis and dietary oxidative stress.

The objectives of this study were met in that the pathology of pansteatitis in wild catfish was described and compared to the pathology of known nutritionally-induced pansteatitis in farmed catfish. During the study an increasing prevalence of pansteatitis was found in catfish in the Olifants Gorge, and a lack of regression of lesions over time was demonstrated in captive pansteatitis-affected catfish. By showing that lesions do not regress, the author has been able to explain how lesions in wild fish are able to accumulate over time with repeated exposure to oxidative stress. The author has demonstrated that pansteatitis in catfish in the KNP was associated with damming of rivers. The author and co-workers have been able to show through comparative analysis of stomach contents, stable isotopes and analysis of fatty acids, in healthy and pansteatitis-affected catfish from the KNP, that consumption of phytoplankton-feeding fish, by both catfish and crocodiles, at certain localities in the KNP, was the most likely aetiology of the pansteatitis in these animals. The author has also demonstrated that certain haematological and blood chemistry parameters known to reflect oxidative stress are not suitable for the study of pansteatitis in wild catfish, particularly where exposure to oxidative stress is likely to have been intermittent, as the lesions in catfish can be chronic and persist long after the exposure occurred. With this study the author has contributed significant knowledge to help SANParks and South Africa's authorities to better conserve keystone aquatic species such as the Nile crocodile. The information from this study has also provided a valuable perspective on the far reaching consequences of anthropogenic impacts on our country's water catchments.

## 6.2. Prevalence of Pansteatitis

The results of this project provide the first insight into a serious and increasing condition in wild sharptooth catfish in some rivers in the KNP. Circumstantially the pansteatitis diagnosed in the catfish appears to be linked to outbreaks of pansteatitis in Nile crocodiles inhabiting the same stretches of these rivers. During the two year period of field sampling, the prevalence of pansteatitis in catfish steadily increased from 33% to 67% in the Olifants Gorge. Prevalence during the summer samplings was slightly lower than during the preceding winter samplings, but overall an increasing prevalence was evident in both winter and summer samplings. The author's study on persistence of pansteatitis lesions in catfish indicated that the condition was not rapidly fatal, but that pansteatitis-affected catfish were weakened by the disease. Furthermore, as lipolysis in pansteatitis-affected adipose tissue appears to be suppressed by the condition, such fat is retained, and pansteatitis lesions persist in the affected fat over long periods of time. In the wild, affected fish are likely to be more prone to predation by crocodiles. This may explain the lower prevalence of pansteatitis observed in the catfish of the Olifants Gorge during the summer, when crocodiles are feeding actively, when compared to the previous winter. Similarly, the higher prevalence during the following winter may indicate recruitment of new cases on a seasonal basis. This is supported by the pathology observed in some catfish from the Olifants Gorge that showed presence of both new and old lesions in the adipose tissues. Observations on captive catfish suffering from long-standing pansteatitis revealed the presence of pansteatitis-affected adipose tissue adjacent to more recently deposited healthy fat, reflecting periodic episodes of nutritional oxidative stress.

Pansteatitis was also identified in catfish sampled from the Sabiepoort on the Sabie River, an area topographically similar to the Olifants Gorge. Prevalence of pansteatitis in these fish was of a similar high magnitude to that recorded from the Olifants Gorge. Crocodiles have also died from pansteatitis in the Sabiepoort (D. Govender, SANParks, Skukuza, pers. comm. 2010), and, as in the case of the Olifants Gorge, a large man-made lake extends from Mozambique into the gorge of the Sabiepoort. Compared to the catchment area of the Olifants River, which is heavily impacted by a multitude of human activities such as mining, industrial, forestry, agricultural and urban developments, and is subject to extensive erosion resulting in heavy silt loads, the catchment of the Sabie River lies on the Drakensberg escarpment in areas that are extensively afforested (Anon 2001). The river passes through

some areas of agricultural development and receives municipal discharges from the town of Sabie (Thaba Chweu Municipality) before entering conservation areas and the KNP.

Pansteatitis was present at a much lower level at two further sites in the KNP, Engelhard Dam and Mamba Weir. Engelhard Dam is situated on the Letaba River just above the gorge through which the Letaba River passes before its confluence with the Olifants River in the Olifants Gorge. To the north of the Olifants River catchment, the rivers feeding the Letaba River arise in the Great Escarpment Mountains in an area dominated by afforestation, and have been dammed in many places. In the middle reaches the Letaba River flows through subtropical fruit plantations and rural settlements and agriculture before entering the KNP (Anon 2001). The low prevalence of pansteatitis identified in fish from Engelhard Dam may be explained by upstream migration of pansteatitis-affected catfish from the Olifants Gorge. Mamba Weir is a small gauging barrier across the Olifants River near the western entry point of the Olifants River into the KNP. The low prevalence of pansteatitis in catfish from this site may also be explained by upstream movement of pansteatitis-affected fish from the Olifants Gorge. The section of river around Mamba Weir differs from the Olifants Gorge in that riparian vegetation along this section of the Olifants River includes sycamore fig trees. Compared to the predominantly piscivorous diet of catfish from the Olifants Gorge, fruit of the sycamore fig trees was the most common constituent of the stomach content of catfish sampled from Mamba Weir, reflecting a clear dietary difference at this site.

No pansteatitis was found in catfish examined from several other sites in and on the outskirts of the KNP. The Crocodile River is not dammed in or near the KNP but has a similar catchment area to the Sabie River, with extensive afforestation and industrial and waste water discharges from the city of Nelspruit (Mbombela Municipality). Catfish from the Crocodile River were however healthy. The Levuvhu River and its tributaries arising in the Soutpansberg are perennial. As in the case of the Letaba River the upper catchment of the Levuvhu River is dominated by forestry. In the middle reaches of the catchment the Levuvhu River and its tributaries flow through subtropical fruit plantations and areas of rural settlement and subsistence agriculture before entering the KNP (Anon 2001). Catfish from the Levuvhu River were found to be healthy. Reënvoël Dam, an entirely rain-fed water body in the KNP represented a further reference site. Catfish from this site were found to be healthy, as were catfish from a dam at the phosphate mine on the outskirts of the town of Phalaborwa on the western side of the KNP.

Comparing the prevalence of pansteatitis in catfish in the Olifants, Sabie and Crocodile rivers in the KNP, the similarity between the Sabie and Crocodile River catchment areas and the widely different anthropogenic impacts in the Olifants River catchment provide an argument against a primary pollution-related aetiology.

The high levels of erosion in sections of the Olifants river catchment result in large amounts of sediment being deposited where the river enters Lake Massingir. The crocodile deaths of 2008 coincided with the rising level of the lake brought about by completion of the rehabilitation of the dam wall in late 2006. Since then the lake extends into the Olifants Gorge, and the sediments carried by the river are now deposited in the gorge where they have drastically altered the aquatic habitat (Ferreira & Pienaar 2011). Upstream of Mamba Weir the Phalaborwa Barrage dams the Olifants River near the town of Phalaborwa. In anticipation of arriving flood waters the sluices of the Phalaborwa Barrage are from time to time opened to remove sediment and create space for incoming water. This in itself is problematic for the KNP, as low dissolved oxygen levels associated with the high oxygen demand of the stirred up sediments have occasionally resulted in the deaths of oxygen sensitive species downstream in the KNP (J. Venter, SANParks, Skukuza, pers. comm. 2012). During such episodes, for example in February 1999 and January 2004, large numbers of silver carp, were identified amongst the dead fish in the Olifants River within KNP, confirming the presence of this species during these months (J. Venter, SANParks, Skukuza, pers. comm. 2012). Such episodes, however, did not coincide with the crocodile deaths in 2008 or the pansteatitis prevalence in catfish since then.

Presence of pansteatitis in the Olifants Gorge was positively correlated with age, weight and length of the catfish. No pansteatitis was observed in fish under 3 years of age. The age, weight and length correlations with pansteatitis incidence may indicate a size-associated nutritional preference or selection. This is supported by the analysis of stomach contents of catfish sampled from the Olifants Gorge and other reference sites in and around KNP. Stomach content may only reveal the most recent food ingested by a fish, but repeated samplings from the Olifants Gorge, and other sites where pansteatitis was found, indicated a high prevalence of fish in the diet of catfish with pansteatitis. This suggests a strong link between consumption of fish and the development of pansteatitis and supports the findings of many researchers who have studied pansteatitis in various poikilothermic and homothermic animals. The condition has repeatedly been linked to high intake of polyunsaturated fats,

usually of fish origin, and the relative hypovitaminosis E that is often caused by this type of diet (Danse & Verschuren 1978a; Davis & Gorham 1954; Fytianouet *al.* 2006; Goodwin 2006; Nizaet *al.* 2003; Roberts & Agius 2008; Roberts & Rodger 2001; Wallach & Hoessle 1968; White 2000).

In the Olifants Gorge the causes of pansteatitis may be multi-factorial (see section 6.5). Although unlikely, if bio-accumulation of one or more xenobiotics had been involved as inciting agent in the aetiology of the pansteatitis, this process might have needed time and could have been reflected by the absence of pansteatitis in fish under 3 years of age. While the action of many xenobiotics is through a process of oxidative stress exerted on the lipids of biological membranes similar to the lipid peroxidation taking place in adipose tissues of pansteatitis-affected animals, there is little evidence in the literature linking xenobiotic bio-accumulation to the aetiology of pansteatitis. Furthermore, Coetzee *et al.* (2002) found that in the Klein Olifants River, in the heavily polluted upper catchment of the Olifants River, bio-accumulation of metals in catfish and other fish was size-related, with higher metal concentrations being found in smaller fish.

The high prevalence of pansteatitis in captive catfish at Lunsklip Fisheries could be ascribed to the excessive intake of trout slaughterhouse waste which was likely to contain rancid fats and was observed rotting in the catfish pond. Under such nutritional conditions development of pansteatitis is not surprising. The debilitating effects of pansteatitis were clearly observed in these fish, both on the farm when they were caught and during the subsequent trial to establish the persistence of the pansteatitis lesions (see Chapter 4). Such debilitating effects were also observed in pansteatitis-affected crocodiles in the Olifants Gorge and have been reported in other species suffering from pansteatitis (de Bruijn *et al.* 2006; Ginn *et al.* 2007; Niza *et al.* 2003). This is the first time that the debilitating effects of pansteatitis have been reported in sharptooth catfish.

### **6.3. Pathology**

Necrosis of the adipose tissue resulting in pansteatitis was the main pathological change repeatedly observed in catfish from the Olifants Gorge and was a consistent indicator of oxidative stress. The fat of sharptooth catfish is distinct from that of other fish species in that a variation in colour of the mesenteric adipose tissues appears to be normal, and yellow discolouration of the fat cannot be used as an indication of lipid peroxidation as in other

species. In moderate to severely affected catfish, the lesions may be extensive and easily recognized. Histological confirmation is based on demonstrating ceroid-containing macrophages and giant cells in the extensive inflammatory reaction surrounding foci of fat necrosis.

During the study, specific pathology relating to lipid autoxidation and pansteatitis was also observed in a captive population of sharptooth catfish suffering from known nutritionally-induced pansteatitis. Observation of these fish indicated that even in severely affected fish, though debilitating, the condition was not rapidly fatal. Results of the trial done by the author to establish the fate of pansteatitis lesions confirmed persistence of pansteatitis in catfish from Lunsklip Fisheries after an 11 month period. During this period the fish were kept in a recirculated facility on a combination of live natural as well as commercial trout food. Despite a 6 month period through the winter during which the fish refused to feed and lost body condition, there was no reduction in the amount of stored mesenteric fat nor in the degree of steatitis in the fat. Similar observations were made in channel catfish (Goodwin 2006) and in captive alligators (Larsen *et al.* 1983).

Various degrees of hepatic lipidosis and ceroidosis were observed in fish with severe pansteatitis. The clustering of haemosiderin around the perimeter of fat accumulation in livers of fish with pansteatitis is interesting in that redox cycling of iron has been implicated as a cause of iron-catalysed lipid peroxidation (Kibanova *et al.* 2009; Minotti & Aust 1992). Ferric iron compounds may, however, be derived predominantly from haemoglobin catabolism (Moccia *et al.* 1984) in which case, bound to transferrin or sequestered as haemosiderin, the iron is well tolerated by the liver (Hayes 2004). Splenomegaly was a consistent finding in fish with pansteatitis, as was splenic haemosiderosis, indicative of increased haemoglobin catabolism. Reduced feed intake by fish suffering from pansteatitis is a possible cause of the observed atrophy of the pancreatic acinar tissues.

Nutritional myopathy as described in association with vitamin E deficiency and pansteatitis in some species of fish (Cowey *et al.* 1984; Helder 1979; Murai & Andrews 1974; Poston *et al.* 1976; Roberts *et al.* 1979) was not observed in fish with pansteatitis from either the Olifants Gorge or Lunsklip Fisheries. This may reflect adequate dietary intake of vitamin E and selenium in these fish. Although vitamin E levels are known to deplete with acute pro-oxidant exposure, dietary vitamin E deficiency, rather than lipid peroxidation, has been



implicated as the cause of myopathy observed in various species (Ginn *et al.* 2007; van Vleet & Valentine 2007). Although an integral part of the aetiology of pansteatitis, from the results of this study a primary vitamin E deficiency appears unlikely.

Compared to catfish from Lunsklip Fisheries, catfish from most other sampling sites carried heavy burdens of parasites. Frequent and varied pathology associated with parasites was observed in most of the wild-caught fish. This varied between sampling sites depending on parasite burdens and prevalence of specific parasites. Despite the associated pathology, presence of parasites appeared to be well tolerated by the fish. Fish from Reënvoël Dam, a population where pansteatitis could not be demonstrated, showed the heaviest parasite burdens. Focal steatitis with minimal lipopigment formation was observed only infrequently in association with parasites and no correlation could be demonstrated between parasite burden and pansteatitis. The steatitis described in association with lipidosis and streptococcosis in cultured silver perch (Deng *et al.* 2012), was similarly characterised by an absence of ceroid within the necrotic lesions in fat deposits in various organs. It is interesting to note the presence of metacercariae of *Centrocestus formosanus* in gills of catfish from KNP. Spread of this zoonotic parasite, that causes marked deformity of the gill cartilage, has been associated elsewhere with introduction of carp from Asia (Velez-Hernandez *et al.* 1998).

#### **6.4. Haematology, Blood Chemistry and Bio-monitoring**

The variable intensity of pansteatitis observed in the catfish from the Olifants Gorge, and the chronic nature of the disease in these fish, provided challenges for the interpretation of the haematology and blood chemistry results. The unpredictable response of anti-oxidant defences, showing either induction or depletion, and their ability to adapt to chronic oxidant exposure further complicate interpretation (Di Giulio *et al.* 1989). However, in the Olifants Gorge, significant numbers of catfish did have low serum vitamin E values at certain times. Under field conditions in the Olifants Gorge, where exposure to oxidative stress may have been episodic, it was not possible to establish whether or not oxidative stress was present at the time when fish were sampled. In contrast to pathological changes that remained present long after the oxidative insult had occurred, the selected haematology and blood chemistry parameters that were used in this study appeared in many instances to reflect normal variation. These tests, shown to be suitable indicators of oxidative stress under experimental

conditions in the laboratory (Bell *et al.* 1985; Fytianou *et al.* 2006; Moccia *et al.* 1984; Smith 1979), were not suitable under the conditions being experienced by catfish in the Olifants Gorge. Other more sensitive tests suitable for non-sacrificial monitoring of fish in the KNP warrant further investigation but were beyond the scope of this study.

Tests that merit investigation for field monitoring of oxidative stress in catfish in the KNP include determining malondialdehyde levels in the lipid fraction of serum, by use of the thiobarbituric acid reactive substances assay, and the measure by mass spectrometry of F<sub>2</sub>-isoprostanes, which are prostanoids resulting from the *in vivo* free-radical-catalysed peroxidation of arachidonic acid (Awad *et al.* 1994). As free F<sub>2</sub>-isoprostanes in plasma reflect whole body lipid peroxidation, these prostanoids may also be of value as a pro-oxidant marker in fish. The measure of F<sub>2</sub>-isoprostanes is used in the racehorse industry in South Africa but the cost of these tests was beyond the budget of this study. Although not a direct measure of lipid peroxidation, the associated damage to DNA structures provides a further opportunity for bio-monitoring, and the comet assay has been suggested as a rapid, sensitive and inexpensive method of measuring DNA oxidation (Collins 2009; Klaude *et al.* 1996; Lee & Steinert 2003) and has been used to measure the effects of dietary antioxidants in human disease (Collins 2009).

Catfish are an abundant and ubiquitous, benthic feeding species, with a relatively long life span. This study has shown that they are an ideal monitoring species in the rivers of the KNP, and may be used to monitor, indirectly, oxidant exposure in crocodiles inhabiting the same waters. Pansteatitis is not necessarily lethal in catfish, and lesions in the adipose tissues indicative of oxidant exposure persist over long periods. This allows monitoring at times of the year when access to and conditions along rivers in the KNP are conducive to sampling fish.

### **6.5. Xenobiotics as Possible Cause of Pansteatitis**

Concern about the KNP Olifants River crocodile demise stems from the possible influence of anthropogenic effects on the Olifants River catchment, which covers some 74 500 km<sup>2</sup> and is home to about 8% of South Africa's population (Ashton 2010). Approximately 90% of the country's saleable coal is mined in this catchment and is used to generate 55% of South Africa's electricity, resulting in serious pollution concerns (Coetzee *et al.* 2002; de Villiers & Mkwelo 2009). The area contains numerous dams, including 38 major dams as well as the

country's second largest irrigation scheme (Anon 2001). In addition, large areas of the landscape have been changed by afforestation and agriculture. Huge increases in urban wastewater discharge and on-going high nutrient run-off from agricultural practices raise added concerns of eutrophication (Heath *et al.* 2010). A large phosphate mine is situated near the town of Phalaborwa just west of the KNP near the entry point of the Olifants River into the KNP. For a number of years prior to 2004, and once in 2008, abnormally high phosphate levels were recorded in the Olifants River within the KNP (J. Venter, SANParks, Skukuza, pers. comm. 2012). These were ascribed to the discharge of tailings from the phosphate mine into the Selati River, a tributary of the Olifants River, and to municipal sewerage discharges from the town of Phalaborwa. Phosphate discharges would have added to the inorganic nutrient load trapped in sediments of Lake Massingir and have contributed to the eutrophication of the lake (Mussagy 2008). Dissolved phosphate is often the limiting nutrient governing phytoplankton growth in fresh water, and phosphates released from sediments will continue to drive the nutrient cycle of the lake. The high levels of phosphate reaching Lake Massingir may have been a significant stimulus for phytoplankton growth resulting in the blooms observed in 2008 (J. Myburgh, Faculty of Veterinary Science, University of Pretoria, pers. comm. 2008) and may have contributed to an increasing biomass of fish in the lake.

Contamination of surface waters in the catchment, with accumulation of heavy metals within sediments through adsorption and precipitation processes, has long been recognised as a serious pollution concern. Site specific bio-accumulation of metals has been demonstrated in sharptooth catfish in the upper catchment of the Olifants River (Coetzee *et al.* 2002), and Oberholster *et al.* (2011) have suggested that aluminium and iron bio-accumulation by Mozambique tilapia in Lake Loskop may have induced their yellow fat at that site. Large dams in the catchment act as traps for sediments, nitrates, phosphates and heavy metals and are regarded as the epicentre of recent mortalities of fish and crocodiles (Heath *et al.* 2010). Over time, changing water quality may cause sediment-bound contaminants to become bio-available and result in bio-accumulation in fish tissues. Certain species of phytoplankton have been shown to bio-accumulate high concentrations of aluminium and iron from the environment in Lake Loskop in the polluted upper catchment of the Olifants River (Oberholster *et al.* 2011). A similar process in Lake Massingir, though speculative, may contribute to metal bio-accumulation in fish entering the Olifants Gorge and may contribute to a multifactorial aetiology of the pansteatitis in catfish at this site. Juvenile catfish held under experimental conditions over sediments collected from the Olifants Gorge as part of

this study grew normally and did not develop pansteatitis or other pathology (see Chapter 5). This part of the study could not, however, reflect all the factors that may have been present in the Olifants Gorge, nor the role of phytoplankton in bio-accumulation of metals.

Redox cycling of iron is known to be an initiator of lipid peroxidation (Baker *et al.* 1997; Demopoulos 1973; Minotti & Aust 1992; Tappel 1973), and depletion of tissue vitamin E levels by high dietary iron intake may render polyunsaturated fats in the tissues of the fish vulnerable to peroxidation (Baker *et al.* 1997). Avenant-Oldewage and Marx (2000) demonstrated bio-accumulation of various metals including iron in catfish in the Olifants River within the KNP. However numerous abiotic and biotic factors appeared to influence the degree of bio-accumulation in individual fish, and metal levels in fat tissues were not examined by these authors. Low bio-concentration factors of a number of metals, including iron, in various tissues, indicated low bioavailability of these metals in tigerfish from the Olifants River in the KNP in a study done by du Preez and Steyn (1992). Contrary to the findings of Oberholster *et al.* (2011) that indicated high levels of iron and aluminium bio-accumulation in the yellow fat of Mozambique tilapia in Lake Loskop, du Preez and Steyn (1992) found that mean iron levels in the fat of tigerfish were much lower than in the liver and gills. It has not been established to what extent iron bio-accumulates in the adipose tissues of catfish and whether such bio-accumulation has played a role in the initiation of the pansteatitis observed in the catfish sampled from the Olifants Gorge.

Pansteatitis-affected catfish caught during September of 2008 and from January to November of 2009 in the lower Letaba and Olifants Rivers were shown by special histological staining to have accumulated large amounts of iron in the form of haemosiderin in the melanomacrophages of the liver, spleen, ovary and to a lesser extent in the kidney (see Chapter 3). However, haemosiderin was not detected in the intense macrophage reaction associated with steatitis in the adipose tissues. Blood smears of many of these fish showed an abundance of immature erythrocytes as well as irregular erythrocyte shapes as described in cases of vitamin E deficiency in fish (Murai & Andrews 1974; Smith 1979; Stewart 1993), and increased erythrocyte turnover may have been the source for the increased haemosiderin carried by macrophages. Stomach contents of fish caught in the gorge at the confluence yielded mainly remnants of large fish, whereas specimens caught directly over the silt deposits on the Mozambique border only contained detritus and silt. These findings suggested bio-accumulated iron as an additional oxidative trigger, possibly ingested in polluted

sediment. Baker *et al.* (1997) have, however, proposed that African catfish efficiently regulate iron status and are able to prevent tissue assimilation of dietary iron intake. This is an important adaptation to their benthic habitat, in which they are likely to consume sediment-burrowing organisms with inadvertent ingestion of sediment. Results from a preliminary study indicated that hepatic iron levels in fish from the Olifants Gorge were lower than in fish from Lunsklip Fisheries (Dixon, Huchzermeyer, Espach & Huchzermeyer 2011). This, and the absence of haemosiderin in macrophages associated with steatitis in the adipose tissues of catfish from the Olifants Gorge, suggests that the role of iron in the aetiology of pansteatitis in catfish in the Olifants Gorge remains uncertain and needs further investigation.

Water-borne pollutants or bio-accumulated xenobiotics moving up the food chain would be expected to exert similar pathology in fish feeding at the same trophic level. Isotopic studies of the lotic food web in the Olifants Gorge have indicated that catfish from this locality had changed their dietary niche to a trophic level similar to that of tigerfish, an obligate piscivore. Both tigerfish and catfish occupy a higher trophic level in the Olifants Gorge than in other river systems in the KNP (Woodborne *et al.* 2012) [see Appendix A.3], yet tigerfish in the Olifants Gorge do not develop pansteatitis. Measurement of metallothionins, acetylcholinesterase and ethoxyresorufin-O-deethylase, biomarkers respectively of metal, organophosphate and carbamate, and organochlorine exposure, have been proposed for monitoring exposure of tigerfish to these pollutants in the KNP (van Vuuren, Wepener, Smit & Vlok 2012) and may be found suitable for future monitoring of catfish.

Many xenobiotics exert their harmful effects through oxidative damage to phospholipid structures in tissues. Exposure to such pollutants would be expected to result in detectable pathology in various organs. In catfish from the Olifants Gorge, significant pathology was restricted to the adipose tissues, with the most intense and frequent lesions being present in the mesenteric fat. Changes in the liver, spleen and pancreas were secondary to the pansteatitis. Further pathology that might have indicated xenobiotic exposure or bio-accumulation was not evident.

## 6.6. Dietary Change and Pansteatitis in the KNP

The sharptooth catfish is a benthic opportunistic scavenger, feeds indiscriminately, and is known to hunt actively, and predation on other fish is part of the natural feeding habit of this species (Bruton 1979; Groenewald 1964; Skelton 2001; Spataru, Viveen & Gophen 1987; Willoughby & Tweddle 1978). Food source varied distinctly between sampling sites, and prevalence of fish in the diet correlated with presence of pansteatitis in catfish from the Olifants Gorge and the Sabiepoort. Fish remnants observed in the stomach content of catfish from the Olifants Gorge, often in an advanced stage of digestion, frequently consisted of bones and scales of noticeably large unidentified fish. In the Olifants Gorge, both crocodiles and catfish have been observed feeding off the carcasses of dead crocodiles (D. Pienaar, SANParks, Skukuza, pers. comm. 2009), and crocodile fat afflicted with steatitis was found in the stomach contents of some catfish sampled from the Sabiepoort. In contrast, stomach content of catfish from van Ryssen Dam contained only Mozambique tilapia. These catfish showed no signs of pansteatitis.

The extension of Lake Massingir into the KNP has caused a habitat change in the Olifants Gorge that may have favoured a change in access to certain species of fish not normally consumed in large numbers by crocodiles and catfish. This could have exposed these animals to levels of polyunsaturated fatty acids in the diet to which they are not adapted. An increase in dietary polyunsaturated fat intake has been reported to result in pansteatitis in various animals. Wallach and Hoessle (1968) concluded that a change in diet from smelt (6.7% fat) to mackerel (29.9% fat) was the precipitating cause of pansteatitis in captive American alligators. Goodwin (2006) stressed the dangers of using diets high in fish oils for inappropriate species, and a change from Baltic and Mediterranean clupeids to Moroccan Atlantic pilchards was suspected to have been the cause of pansteatitis in northern bluefin tuna reported by Roberts and Agius (2008). Similarly pansteatitis is known to be induced in cats by feeding oil rich fish-based diets (Fytianou *et al.* 2006).

Examination of fatty acid ratios sheds important light on the possible aetiology of pansteatitis in the Olifants Gorge (Huchzermeyer *et al.* in press) [see Appendix A.4]. The n-6 and n-3 fatty acids derived from linoleic and  $\alpha$ -linolenic acids respectively are essential fatty acids that cannot be synthesized by animals (Steffens 1997). The relative abundance of these fatty acids in the diet of animals is reflected in the composition of their fat tissues (Hoffman & Prinsloo 1995; Steffens 1997). The fatty acid composition of marine fish oils, and in



particular the high n-3 to n-6 ratio of polyunsaturated fatty acids contained in these oils, is a reflection of the fatty acid composition of marine phytoplankton (Steffens 1997). The ratio of total n-3 to n-6 fatty acids in marine fish oils typically lies between 5 and more than 10, whereas that of freshwater fish is much lower, ranging from 1 to 4 (Steffens 1997). In freshwater fish, as in marine fish, these fatty acid ratios are influenced by the composition of the diet. In nutrition trials the n-3 to n-6 fatty acid ratio in muscle lipid of sharptooth catfish could be manipulated from 0.1 in fish on a sunflower oil diet to 1.8 in fish on a cod liver oil diet (Hoffman & Prinsloo 1995). The fat of captive farmed crocodiles, receiving a diet of chicken, beef and horse meat, had an n-3 to n-6 fatty acid ratio of 0.08 (Osthoff, Hugo, Bouwman, Buss, Govender, Joubert&Swarts 2010). By contrast the n-3 to n-6 ratio of fatty acids in the fat of wild crocodiles suffering from pansteatitis from the Olifants and lower Letaba Rivers was found to be 2 (Osthoff *et al.* 2010). Compared to the fat of farmed crocodiles, this reflected a much higher intake of n-3 fatty acids by crocodiles in the Olifants Gorge. Mean ratios of n-3 to n-6 fatty acids in catfish with mild or no steatitis sampled from Lunsklip Fisheries, Reënvoël Dam and the Olifants Gorge in November 2009 were 0.8, 1.32 and 0.96 respectively (Huchzermeyer *et al.* in press) [see Appendix A.4]. There appeared to be no significant difference in n-3 to n-6 ratio between fish from Lunsklip Fisheries with varying degree of severity of pansteatitis. The fish with severe pansteatitis sampled from the Olifants Gorge, however, had an n-3 to n-6 fatty acid ratio of 2.87 (Huchzermeyer *et al.* in press) [see Appendix A.4]. From these results it can be inferred that rancidity rather than high polyunsaturated fatty acid intake was the cause of the pansteatitis observed in catfish from Lunsklip Fisheries. By extension of this argument it would seem unlikely that rancidity associated with intake of dead rotting fish could have been the cause of pansteatitis in the Olifants Gorge catfish and crocodiles.

Silver carp, an invasive species outside of its home range in East Asia (Kolar, Chapman, Courtenay, Housel, Williams& Jennings2005), were introduced into Mozambique from Cuba and are known to occur in Lake Massingir (Skelton 2001). Silver carp are also known to have escaped into the Olifants River in South Africa and may have spread downstream (P. Skelton, South African Institute of Aquatic Biodiversity, Grahamstown, pers. comm. 2012). This fish is a specialised plankton feeder that by preference feeds off phytoplankton and is an important consumer of cyanobacterial blooms, with *Microcystis* constituting 20-98% of the food bolus during some seasons (Kolar *et al.* 2005). Such blooms have been observed near the inlet to Lake Massingir (D. Pienaar, SANParks, Skukuza, pers. comm. 2009).

Phytoplankton naturally contain large quantities of  $\alpha$ -linolenic acid and other n-3 polyunsaturated fatty acids, in particular EPA and DHA (Steffens 1997). Intake of these fatty acids is reflected in the adipose tissues of silver carp, with these two fatty acids, in one study, making up to 5.28% and 3.4% of body fat triacylglycerols respectively (Buchtová & Ježek 2011). As a result of the high levels of C20 and C22 fatty acids, consumption of the fat of silver carp has been proposed to have health benefits to humans equivalent to those of oil-rich marine fish (Buchtová & Ježek 2011; Steffens 1997).

A significant proportion of the essential fatty acids derived from the diet are stored in the adipose tissues of animals, and of these DHA is deposited into the adipose tissues preferentially over EPA (Lin & Connor 1990). Although the polyunsaturated fatty acids are mobilised more rapidly from the adipose tissues than saturated fats, DHA, the most polyunsaturated fatty acid, has been shown to be poorly mobilised (Connor, Lin & Colvis 1996). The higher levels of DHA found in the mesenteric fat of catfish with pansteatitis from the Olifants Gorge (11.06%) compared to mesenteric fat of those without pansteatitis (5.09%) strongly points to a higher intake of DHA in the diet of those fish that developed pansteatitis at this site (Huchzermeyer *et al.* in press) [see Appendix A.4]. A similar differentiation was not observed in the mesenteric fat of catfish with mild and severe pansteatitis from Lunsklip Fisheries, supporting the argument for a different dietary aetiology, most likely associated with rancidity of fats in the slaughterhouse waste fed to these fish.

Pansteatitis was not present in tigerfish sampled from the Olifants Gorge. Tigerfish, having evolved as obligate piscivores, may have developed anti-oxidant protective mechanisms better enabling them to cope with the consumption of higher levels of dietary polyunsaturated fats than the omnivorous catfish. Differences in prey preference and size may provide a further reason why this species has remained healthy in the Olifants Gorge.

Catfish are concentrated feeders, utilising specific food sources almost exclusively at times when these are abundant (Bruton 1979), and, although euryphagous, the role of fish in the diet of sharp-tooth catfish can be substantial. When circumstances allow easy access to prey, the most common species of suitable size is taken most frequently (Willoughby & Tweddle 1978). Catfish are stalking rather than active predators and, despite their generally sluggish movements, can be powerful and fast swimmers when hunting in rapids (Bell-Cross 1976). Silver carp, a schooling species, seasonally migrate upstream into rivers from the still waters

of lakes to spawn (Skelton 2001). Spawning is associated with an increase in suspended alluvium and a rise in water level of the river and occurs over an 8 to 10 week period (Kolar *et al.* 2005). The spawning migration takes place during early to midsummer, and in the Olifants Gorge this mass migration may account for intense dietary exposure of crocodiles and catfish to this species and the consequential intake of excessive polyunsaturated fats during a short period each year. This may explain the increase in crocodile mortality during the subsequent autumn and winter as observed in 2008 and to a lesser extent in the following years. In the Olifants Gorge, fish surveys are conducted by KNP scientists during the winter months when the river can be safely accessed and the waters of the river become clearer (A. Deacon, SANParks, Skukuza, pers. comm. 2012). The migratory movement of silver carp into the Olifants Gorge may thus easily have been over-looked.

The unnatural habitat in the Olifants Gorge is compounded by the presence of silver carp. In the Sabiepoort the natural habitat has been disturbed by Lake Corumana, which also acts as an inorganic nutrient trap. This has likely consequences for phytoplankton composition and growth, and plankton-feeding fish in this lake may also carry high levels of polyunsaturated fats. The similarity in habitat to the Olifants Gorge points to consumption of fish rich in polyunsaturated fats as the cause of pansteatitis at both sites, but it is not clear whether silver carp have been introduced into Lake Corumana, and other dietary factors, that have not yet been elucidated, may be involved in the Sabiepoort. Alternatively, large scale fish die-off episodes could account for a high intake of rancid fats by both catfish and crocodiles leading to pansteatitis. Both gorges are remote and difficult to access from the KNP. From the Mozambique side local fishermen frequent the gorges on the border with South Africa to set nets, and fish die-offs of the scale that caused the pansteatitis deaths of crocodiles in Lake Loskop should have alerted Mozambican fishermen. As such die-offs have seldom been reported, the possibility of rancid fat ingestion remains unlikely.

Further investigation is needed to confirm the role of dietary fatty acid composition in the development of pansteatitis in catfish in the Olifants Gorge. The influence of phytoplankton composition on fatty acid assimilation by plankton-feeding fish species, that are likely to be preyed on by catfish, also needs to be researched. The seasonal migratory movements of plankton-feeding fish species out of lakes Massingir and Corumana into the Olifants and Sabie rivers respectively needs to be studied to confirm, in particular, the role of silver carp in the diets of catfish and crocodiles.

### 6.7. Pansteatitis in Catfish and the Crocodile Mortality

The discovery of pansteatitis in catfish at sites in the KNP where crocodiles have died of this disease has raised several questions. Was the pansteatitis in crocodiles linked to consumption of catfish suffering from pansteatitis or was there a common inciting factor for the disease in both species; why were crocodile and catfish deaths in the Olifants Gorge restricted to the winter months; why did surviving crocodiles become emaciated; and why have crocodile deaths declined while prevalence in catfish has increased? These questions and other points are addressed in the following paragraphs.

It is unlikely that consumption of pansteatitis-affected catfish could have led to pansteatitis in crocodiles, and the likelihood of a common nutritional cause has been discussed in the preceding point 6.6 of this chapter and in two publications (Huchzermeyer *et al.* in press, [see Appendix A.4]; Woodborne *et al.* 2012 [see Appendix A.3]). Crocodiles would have had to ingest a large number of affected catfish over a short period to consume sufficient polyunsaturated fatty acids to deplete the antioxidant mechanisms that limit the oxidative stress associated with such a diet. Pansteatitis-affected catfish from the Olifants Gorge did have higher levels of n-3 fatty acids, but the total fat content of the adipose tissues was lower than that of healthy catfish (Huchzermeyer *et al.* in press) [see Appendix A.4]. Except for occasional pack-hunting and spawning migration, catfish are mostly solitary benthic fish. Whether sporadic concentration of numbers could lead to sufficiently increased consumption by crocodiles to cause pansteatitis remains unknown.

There are several possible reasons why crocodile deaths from pansteatitis in the Olifants Gorge were restricted to winter (Ferreira & Pienaar 2011). In many aquatic poikilotherms, such as fish and crocodiles, acclimation to colder water temperatures in winter involves an increase in membrane polyunsaturated fatty acids, in particular DHA (Hazel 1979; Hulbert 2003; Seebacher, Murray & Else 2009). The greater number of double bonds in these fatty acids increases the risk of damage by reactive oxygen species released by energy-regulating metabolic pathways used during cold acclimation (Seebacher *et al.* 2009). This may be exacerbated where antioxidant mechanisms, particularly vitamin E, are depleted through oxidative stress, such as that following concentrated dietary polyunsaturated fat intake (Niki, Yamamoto, Takahashi, Komuru & Miyama 1989).

Steatitis is largely a foreign-body type reaction following on breakdown of fat cells, and presence of the lesion may imply either continuous or preceding oxidative stress. Where oxidation of lipids is not currently taking place in the adipose tissues, vitamin E levels may return to normal, as appeared to be the case in catfish from the Olifants Gorge. Depletion of vitamin E may also exert a negative effect on membrane lipids in other tissues. The only observed catfish mortality in the Olifants Gorge occurred during winter (see Chapter 1 section 1.1.2), and, although the cause of death was not established, live catfish sampled around this time were affected by pansteatitis. Under experimental conditions, catfish severely affected by pansteatitis survived water temperatures down to 12°C, well below the lowest water temperature (18°C during the study period) experienced in the Olifants Gorge (see Chapter 4). Yet, despite the severe degree of pansteatitis and the long period of fasting, female test fish had either retained or developed newly gravid ovaries by the end of the trial (see Chapter 4). It is likely that bio-membranes in critical tissues were not impaired in these fish and hence their adaptation to cold remained uncompromised.

The effect of pansteatitis on cold adaptation in crocodiles remains speculative. Crocodiles regulate their energy metabolism during cold acclimation by increased basking (Seebacher *et al.* 2009). A reduction in basking space may have occurred following the flooding of the Olifants Gorge by Lake Massingir. This may have necessitated greater reliance on cold-acclimated energy metabolism, possibly at an increased cost of oxidative stress. The reduced mobility observed in pansteatitis-affected crocodiles in the Olifants Gorge may also have impaired the basking behaviour of the animals, further compromising cold adaptation. It is not known whether hypovitaminosis E occurred in the crocodiles prior to death.

Although poikilothermic animals do not need energy to maintain homeothermy, the energy requirements needed to maintain basal metabolic processes will lead to eventual starvation if the animals stop feeding. When feeding is interrupted by crocodiles during the winter, available fat reserves provide energy. Once fat reserves become depleted or are no longer accessible, amino-acids from muscles are metabolised as a source of energy. As in the case of rats, where Danse and Verschuren (1978b) have shown that stimulated lipolysis was reduced in adipose tissues affected by steatitis, pansteatitis-affected catfish, and probably also crocodiles, are unable to fully access fat reserves damaged by pansteatitis. The catabolic processes needed to meet energy requirements explain the emaciation observed in both crocodiles (D. Govender, SANParks, Skukuza, pers. com. 2009) and catfish (see Chapter 3

section 3.2.1.1.) chronically affected by pansteatitis. Typical of pansteatitis-affected crocodiles in the Olifants Gorge (D. Govender and D. Pienaar, SANParks, Skukuza, pers. comm. 2008; personal observation 2009) was their inability to move effectively. Reduced mobility was also observed in pansteatitis-affected farmed catfish (Chapter 4). In the wild, inability to hunt prey would have exacerbated loss of condition in pansteatitis-affected animals.

Since 2008 crocodile deaths in the Olifants Gorge have declined, indicating a decreasing problem. Yet the prevalence of pansteatitis in catfish has increased. This apparent paradox can be explained by the better survival rate of catfish with pansteatitis. At the time of the first crocodile mortalities most of the dead crocodiles were large and noticeably obese (D. Govender and D. Pienaar, SANParks, Skukuza, pers. comm. 2008), as were catfish sampled at this time. The level of obesity has declined in the catfish during the study period, and SANParks scientists have observed a greater number of lean and wasted crocodiles since 2008. These crocodiles have also been diagnosed with pansteatitis (D. Govender and D. Pienaar, SANParks, Skukuza, pers. comm. 2010). Similar wasting of catfish, suffering from pansteatitis, has been observed in the Olifants Gorge, but was not present in farmed catfish with pansteatitis. This suggests that the observed muscle atrophy was an indirect consequence of the pansteatitis, most likely due to an inability to find or catch food. The trial on persistence of nutritionally induced pansteatitis (see Chapter 4) showed that lesions in the fat of catfish remained unchanged over time and that even severely affected fish survived protracted periods provided they found food. In the wild, recruitment of new cases may have contributed to the rising prevalence in the Olifants Gorge. The 2011 aerial crocodile survey by SANParks has indicated that more recently smaller crocodiles have moved into the Olifants Gorge (D. Pienaar, SANParks, Skukuza, pers. comm. 2011). Time will tell whether these animals will develop pansteatitis as they grow larger.

Catfish have been shown to be a suitable monitoring species for possible pansteatitis in crocodiles as they appear to show similar sensitivity to pansteatitis within their overlapping habitat, and a common dietary factor appears to be involved in the aetiology of the condition. Whereas the Nile crocodile is classed as endangered, the sharptooth catfish is an abundant species that in the Olifants Gorge and Sabiepoort is relatively easy to sample.



## 6.8. Conclusion and Recommendations

The objective of this study was to investigate the occurrence of pansteatitis in catfish inhabiting the waters in the KNP where crocodiles had died of pansteatitis, and to establish the probable causes of the pansteatitis. Catfish were sampled repeatedly over a two year period from the Olifants Gorge and from other sites in and around KNP. This study has shown that sharptooth catfish in the Olifants Gorge and several other sites in the KNP, most notably the Sabiepoort on the Sabie River, are affected with pansteatitis. During the study period an increasing prevalence of pansteatitis was recorded in catfish from the Olifants Gorge. Co-existence of old and recent lesions indicated an on-going incitement of pansteatitis in the catfish. In both the Olifants Gorge and the Sabiepoort, development of pansteatitis in both catfish and crocodiles appears to be linked to dam building and drastic alteration of the aquatic habitat of the respective gorges.

The pathology of pansteatitis in catfish in the Olifants Gorge and from other sites in the KNP is similar to that described in other animals. The pathology differed only in degree of severity from pansteatitis in catfish from a farmed population suffering from nutritionally-induced pansteatitis. Catfish, with pansteatitis, from the farmed population were found to retain lesions in the adipose tissues, unaltered, 11 months after the dietary factors had been corrected. Furthermore, these fish were shown to retain pansteatitis-affected mesenteric fat stores during a protracted period of starvation, supporting the finding of other workers that pansteatitis prevents use of fat reserves as a source of energy.

A number of haematological and blood chemistry parameters were examined to determine whether pansteatitis could be confirmed in live fish. Whilst suitable for experimental studies of pansteatitis under laboratory conditions, these tests were not appropriate for field evaluation of pansteatitis. Other tests that might be suitable, such as the thiobarbituric acid reactive substances test, the measure of F<sub>2</sub>-isoprostanes and the comet assay, need to be evaluated before non-sacrificial monitoring of pansteatitis in catfish in the KNP can be recommended.

Several explanations for the cause of pansteatitis in crocodiles and fish in the Olifants Gorge have been proposed. Bio-accumulation of one or more xenobiotics resulting from upstream pollution cannot be ruled out; yet juvenile catfish, held under experimental conditions over sediments collected from the Olifants Gorge, grew normally and did not develop pansteatitis

or other pathology. Lack of recognisable pollutant-related pathology in organs other than adipose tissue in catfish from the Olifants Gorge, and the fact that pansteatitis was found in catfish in the Sabiepoort, which has a different pollution profile, makes this aetiology seem unlikely. It is unclear whether a pathway of bio-accumulation of iron via phytoplankton similar to that in Lake Loskop exists in Lakes Massingir and Corumana, and this question provides an area for further study.

The consumption of large quantities of dead rotting fish, containing rancid fats, also seems unlikely as an inciting factor, as mass fish mortality has not been a consistent finding at the sites where pansteatitis was observed, and the fatty acid profile of farmed catfish fed rancid fish fats differed from that of catfish suffering from pansteatitis in the Olifants Gorge. The possibility cannot be precluded that consumption of catfish suffering from pansteatitis by itself could have precipitated the pansteatitis outbreak in the crocodiles, but seems unlikely.

This study raises the possibility that seasonal abundance of other fish species rich in n-3 polyunsaturated fats in the diet of catfish and crocodiles in the Olifants Gorge may have resulted in development of pansteatitis in these two species. The habitat change brought about by damming of rivers extending into KNP likely influenced access to such fish. The increasing prevalence of pansteatitis in catfish in the Olifants Gorge, and the accumulation of lesions over time, points to episodic or seasonal exposure to dietary oxidative stress. The presence of large schools of the invasive alien silver carp, benefiting from the nutrient-rich raised water level of Lake Massingir, and known for its high content of n-3 polyunsaturated fatty acids, likely formed much of the summer diet of the catfish and crocodiles, either alive or as dead remains, and is thus proposed as a cause of the obesity and pansteatitis in these animals. It is not yet clear whether silver carp occur in Lake Corumana. A study of the diet of crocodiles and catfish during the summer when migratory fish are likely to be present in the Olifants Gorge and the Sabiepoort may verify these proposals.

The study emphasizes the ecological importance and complexity of oxidative stress in a disturbed aquatic environment. The association between nutrient pollution of the aquatic environment, eutrophication, and the influence of phytoplankton on fatty acid composition of fish consuming such phytoplankton needs further study. The role of phosphate discharges into the Olifants River, the impact of dam building and subsequent silt and nutrient entrapment on relative fish species abundance, and particularly the presence of alien silver

carp within the KNP need to be researched. Pansteatitis in wild catfish is a unique finding, and although work is being done on fish from Lake Loskop (J. Myburgh and J. Steyl, Faculty of Veterinary Science, University of Pretoria, pers. comm. 2009), further work needs to be done to establish the extent to which pansteatitis may be present in fish in other artificial impoundments in polluted catchments. It is recommended that the distribution of alien fish species within rivers traversing the KNP is investigated, and that in dams within KNP and elsewhere in South Africa the long-term effects of hydrodynamic change and nutrient entrapment on the aquatic food chain are monitored, with particular reference to the health of top aquatic predators such as crocodiles.

## REFERENCES

- Adams S.M., Brown A.M. & Goede R.W. (1993) A quantitative health assessment index for rapid evaluation of fish condition in the field. *Transactions of the American Fisheries Society* **122**, 63-73.
- Agius C. (1979) The role of melano-macrophage centres in iron storage in normal and diseased fish. *Journal of Fish Diseases* **2**, 337-343.
- Agius C. & Agbede S.A. (1984) An electron microscopical study on the genesis of lipofuscin, melanin and haemosiderin in the haemopoietic tissues of fish. *Journal of Fish Biology* **24**, 471-488.
- Agius C. & Roberts R.J. (2003) Melanomacrophage centres and their role in fish pathology. *Journal of Fish Diseases* **26**, 499-509.
- Agresti A. & Franklin C. (2007) *Statistics: The Art and Science of Learning from Data*. Pearson Prentice Hall, Pearson Education, Inc., New Jersey, pp. 693.
- Åkerman G., Amcoff P., Tjärnlund U., Fogelberg K., Torrissen O. & Balk L. (2002) Paraquat and menadione exposure of rainbow trout (*Oncorhynchus mykiss*)—Studies of effects on pentose-phosphate shunt and thiamine levels in liver and kidney. *Chemico-Biological Interactions* **142**, 269-283.
- Anon (2001) State of the Rivers Report: Crocodile, Sabie-Sand and Olifants River Systems, 2001, viewed 2011 from [http://www.dwaf.gov.za/iwqs/rhp/state\\_of\\_rivers/crocsabieolif\\_01\\_toc.html](http://www.dwaf.gov.za/iwqs/rhp/state_of_rivers/crocsabieolif_01_toc.html)
- Ashton P. J. (2010) The demise of the Nile crocodile (*Crocodylus niloticus*) as a keystone species for aquatic ecosystem conservation in South Africa: The case of the Olifants River. *Aquatic Conservation: Marine and Freshwater Ecosystems* **20**, 489-493.
- Avenant-Oldewage A. & Marx H.M. (2000) Bioaccumulation of chromium, copper and iron in the organs and tissues of *Clarias gariepinus* in the Olifants River, Kruger National Park. *Water SA* **26**, 569-582.

- Awad J.A., Morrow J.D., Hill K.E., Roberts L.J. & Burk R.F.(1994) Detection and localization of lipid peroxidation in selenium- and vitamin E-deficient rats using F<sub>2</sub>-isoprostanes. *Journal of Nutrition***124**, 810-816.
- Bachowski S., Xu Y., Stevenson D.E., Walborg Jr. E.F. & Klaunig J.E. (1998) Role of oxidative stress in the selective toxicity of dieldrin in the mouse liver. *Toxicology and Applied Pharmacology* **150**, 301-309.
- Bainy A.C.D., Saito E., Carvalho P.S.M. & Junqueira V.B.C.(1996) Oxidative stress in gill, erythrocytes, liver and kidney of Nile tilapia (*Oreochromis niloticus*) from a polluted site. *Aquatic Toxicology***34**, 151-162.
- Baker R.T.M. & Davies S.J.(1996a) Changes in tissue  $\alpha$ -tocopherol status and degree of lipid peroxidation with varying  $\alpha$ -tocopherol acetate inclusion in diets for the African catfish. *Aquaculture Nutrition***2**, 71-79.
- Baker R.T.M. & Davies S.J. (1996b) Oxidative nutritional stress associated with feeding rancid oils to African catfish, *Clarias gariepinus* (Burchell) and the protective role of  $\alpha$ -tocopherol. *Aquaculture Research***27**, 795-803.
- Baker R.T.M. & Davies S.J. (1997a) Modulation of tissue  $\alpha$ -tocopherol in African catfish, *Clarias gariepinus* (Burchell), fed oxidized oils, and the compensatory effect of supplemental dietary vitamin E. *Aquaculture Nutrition***3**, 91-97.
- Baker R.T.M. & Davies S.J.(1997b) Muscle and hepatic fatty acid profiles and  $\alpha$ -tocopherol status in African catfish (*Clarias gariepinus*) given diets varying in oxidative state and vitamin E inclusion level.*Animal Science***64**, 187-195.
- Baker R.T.M., Martin P. & Davies S.J. (1997) Ingestion of sub-lethal levels of iron sulphate by African catfish affects growth and tissue lipid peroxidation. *Aquatic Toxicology***40**, 51-61.

- Begg G.S., Bruno D.W. & McVicar A.H. (2000) The histopathology and ultrastructure of steatitis affecting common dab *Limanda limanda*. *Diseases of Aquatic Organisms***41**, 123-133.
- Bell J.G., Cowey C.B., Adron J.W. & Shanks A.M. (1985) Some effects of vitamin E and selenium deprivation on tissue enzyme levels and indices of tissue peroxidation in rainbow trout (*Salmo gairdneri*). *British Journal of Nutrition***53**, 149-157.
- Bell-Cross G. (1976) *The Fishes of Rhodesia*. National Museums and Monuments, Harare, Zimbabwe, pp. 268.
- Bernet D., Schmidt H., Meier W., Burkhardt-Holm P. & Wahli T (1999) Histopathology in fish: proposal for a protocol to assess aquatic pollution. *Journal of Fish Diseases***22**, 25-34.
- Bonar C.J. & Wagner R.A. (2003) A third report of “golf ball disease” in Amazon River dolphin (*Inia geoffrensis*) associated with *Streptococcus iniae*. *Journal of Zoo and Wildlife Medicine* **34**, 296-301.
- Botha H., van Hoven W. & Guillette Jr. L.J. (2011) The decline of the Nile crocodile population in Loskop Dam, Olifants River, South Africa. *Water SA***37**, 103-108.
- Branson E. (1993) Basic anatomy and physiology. In: *Aquaculture for Veterinarians: Fish Husbandry and Medicine* (ed. by L. Brown), pp. 1-30. Pergamon Press, Oxford, New York, Seoul, Tokyo.
- Bricknell I.R., Bruno D.W., Bowden T.J. & Smith P. (1996) Fat cell necrosis syndrome in Atlantic halibut *Hippoglossus hypoglossus* L. *Aquaculture***144**, 65-69.
- Bruton M.N. (1979) The food and feeding behaviour of *Clarias gariepinus* (Pisces: Clariidae) in Lake Sibaya, South Africa, with emphasis on its role as a predator of cichlids. *Transactions of the Zoological Society of London***35**, 47-114.



- Buchtová H. & Ježek F. (2011) A new look at the assessment of silver carp (*Hypophthalmichthys molitrix* Val.) as a food fish. *Czech Journal of Food Science***29**, 487-497.
- Burton G.W.(1994) Vitamin E: molecular and biological function. *Proceedings of the Nutrition Society***53**, 251-262.
- Bury N. & Grosell M.(2003) Iron acquisition by teleost fish. *Comparative Biochemistry and Physiology Part C* **135**, 97-105
- Bus J.S., Aust S.D. & Gibson J.E. (1976) Paraquat toxicity: proposed mechanism of action involving lipid peroxidation. *Environmental Health Perspectives***16**, 139-146.
- Case L.P., Carey D.P. & Hirakawa D.A. (1995) Vitamin deficiencies and excesses. In: *Canine and Feline Nutrition. A Resource for Companion Animal Professionals* (ed. by L.L. Duncan), pp. 303–308. Mosby-Year Book, St. Louis.
- Coetzee L., du Preez H.H. & van Vuuren J.H.J. (2002) Metal concentrations in *Clarias gariepinus* and *Labeo umbratus* from the Olifants and Klein Olifants River, Mpumalanga, South Africa: Zinc, copper, manganese, lead, chromium, nickel, aluminium and iron. *Water SA***28**, 433-448.
- Collins A.R. (2009) Investigating oxidative DNA damage and its repair using the comet assay. *Mutation Research***681**, 24-32.
- Connor W.E., Lin D.S. & Colvis C. (1996) Differential mobilization of fatty acids from adipose tissue. *Journal of Lipid Research***37**, 290-298.
- Cowey C.B., Degener E., Tacon A.G.J., Youngson A. & Bell J.G. (1984) the effect of vitamin E and oxidized fish oil on the nutrition of rainbow trout (*Salmo gairdneri*) grown at natural varying temperatures. *British Journal of Nutrition***51**, 443-451.
- Danse L.H.J.C.& Verschuren P.M. (1978a) Fish oil-induced yellow fat disease in rats. I. Histological changes. *Veterinary Pathology***15**, 114-124.

- Danse L.H.J.C. & Verschuren PM (1978b) Fish oil-induced yellow fat disease in rats. III. Lipolysis in affected adipose tissue. *Veterinary Pathology***15**, 544-548.
- Davis C.L. & Gorham J.R. (1954) The pathology of experimental and natural cases of “yellow fat disease” in swine. *American Journal of Veterinary Research***15**, 55-59.
- de Bruijn C.M., Veldhuis Kroeze E.J.B. & Sloet van Oldruitenborgh-Oosterbaan M.M. (2006) Yellow fat disease in equids. *Equine Veterinary Education***18**, 38-44.
- Demopoulos H.B. (1973) Control of free radicals in biologic systems. *Federation Proceedings***32**, 1903-1908.
- Deng C.Y., Peng J.H., Chen M.M., Chen M.H. & Chang P.H. (2012) Lipoidosis, steatitis, and streptococcosis in mariculture of silver perch (*Bidyanus bidyanus*). *Bulletin of the European Association of Fish Pathologists***32**, 49-55.
- de Villiers S. & Mkwelo S.T. (2009) Has monitoring failed the Olifants River, Mpumalanga? *Water SA***35**, 671-676.
- Di Giulio R.T., Washburn P.C., Wenning R.J., Winston G.W. & Jewell C.S. (1989) Biochemical responses in aquatic animals: a review of determinants of oxidative stress. *Environmental Toxicology and Chemistry* **8**, 1103-1123.
- Diplock A.T., Green J., Bunyan J., Mchale D. & Muthy I.R. (1967) Vitamin E and stress. 3. The metabolism of D- $\alpha$ -tocopherol in the rat under dietary stress with silver. *British Journal of Nutrition***21**, 115-125.
- Dixon R., Huchzermeyer D., Espach H. & Huchzermeyer F. (2011) Baseline metal levels in *Clarias gariepinus* and *Crocodylus niloticus* in the Kruger National Park in relation to pansteatitis. South African National Parks 9<sup>th</sup> Annual Savannah Science Network Meeting. 13-18 March 2011. Skukuza.
- Draper H.H., James M.F. & Johnson B.C. (1952) Tri-o-cresyl phosphate as a vitamin E antagonist for the rat and lamb. *Journal of Nutrition***47**, 583-599.

- Driescher A.C. (2007) A water quality study of Loskop Dam and the upper catchment of the Olifants River. MSc thesis. University of the Free State.
- Dubey J.P. & Hartley W.J. (1992) Steatitis in a red kangaroo (*Macropus rufus*) associated with a coccidia-like protozoon. *Journal of Veterinary Diagnostic Investigation* **4**, 93-96.
- du Preez H.H. & Steyn G.J. (1992) A preliminary investigation of the concentration of selected metals in the tissues and organs of the tigerfish (*Hydrocynus vittatus*) from the Olifants River, Kruger National Park, South Africa. *Water SA* **18**, 131-136.
- Elleder M. (1991) Primary extracellular ceroid type lipopigment. A histochemical and ultrastructural study. *Histochemical Journal* **23**, 247-258.
- Ferreira S.M. & Pienaar D. (2011) Degradation of the crocodile population in the Olifants River Gorge of Kruger National Park, South Africa. *Aquatic Conservation: Marine and Freshwater Ecosystems* **21**, 155-164.
- Frye F.L. & Schelling S.H. (1973) Steatitis in a captive caiman. *Veterinary Medicine / Small Animal Clinician* **68**, 143-145.
- Fytianou A., Koutinas A.F., Saridomichelakis M. N. & Koutinas C. K. (2006) Blood  $\alpha$ -tocopherol, selenium, and glutathione peroxidase changes and adipose tissue fatty acid changes in kittens with experimental steatitis (yellow fat disease). A comparative study between the domestic shorthaired and Siamese breed. *Biological Trace Element Research* **112**, 131-143.
- Gallagher M.L. (1993) Nutrition and nutritional diseases of temperate freshwater fishes. In: *Fish Medicine* (ed. by M.K. Stoskopf), pp. 247-250. W.B. Saunders Company. Harcourt Brace Javanovich, Inc., Philadelphia.
- Geraci J.R. & St. Aubin D.J. (1980) Nutritional disorders of captive fish-eating animals. In: *The Comparative Pathology of Zoo Animals* (ed. by R.J. Montali and G. Migaki), pp. 41-49. The Symposia of the National Zoological Park. Smithsonian Institution Press. Washington DC.

- Gingerich W.H. (1982) Hepatic toxicology of fishes. In: *Aquatic Toxicology* (ed. by L.J. Weber), pp. 55-105. Plenum Press, New York,
- Ginn P.E., Mansell J.E.K. & Rakich P.M. (2007) Skin and appendages. In: *Jubb, Kennedy and Palmer's Pathology of Domestic Animals*, 5<sup>th</sup> edn (ed. by M.G. Maxie), pp. 553-781. Elsevier Saunders, London, New York, Oxford, Philadelphia, St. Louis, Sydney, Toronto.
- Gonzalez M.J., Gray J.I., Schemmel R.A., Dugan Jr. L. & Welsch C.W. (1992) Lipid peroxidation products are elevated in fish oil diets even in the presence of added antioxidants. *Journal of Nutrition* **122**, 2190-2195.
- Goodman G.C., Bunting H. & Melnick J.L. (1952) The histopathology of coxsackie virus infection in mice. I. Morphologic observations with four different viral types. *American Journal of Pathology* **28**, 223-257.
- Goodwin A.E.(2006) Steatitis, fin loss and skin ulcers of channel catfish, *Ictalurus punctatus* (Rafinesque), fingerlings fed salmonid diets. *Journal of Fish Diseases* **29**, 61-64.
- Groenewald A.A. van J.(1964) Observations on the food habits of *Clarias gariepinus* Burchell, the South African freshwater barbel (Pisces: Clariidae) in Transvaal. *Hydrobiologia* **28**, 287-291.
- Guarda F., Bertoja G., Zoccarato I., Tartari E. & Biolatti B. (1997) Spontaneous steatitis of epicardial fat in farmed white sturgeon (*Acipenser transmontanus*). *Aquaculture* **158**, 167-177.
- Gutteridge J.M.C., Paterson S.K., Segal A.W. & Halliwell B. (1981) Inhibition of lipid peroxidation by the iron-binding protein lactoferrin. *Biochemistry Journal* **199**, 259-261.
- Halare A.V., Seiler T-B. & Hollert H.(2011)The versatile, changing, and advancing roles of fish in sediment toxicity assessment—a review. *Journal of Soils and Sediments* **11**, 141-173.

- Hassoun E., Bagchi M., Bagchi D. & Stohs S.J. (1993) Comparative studies on lipid peroxidation and DNA-single strand breaks induced by lindane, DDT, chlordane and endrin in rats. *Comparative Biochemistry and Physiology***104C(3)**, 427-431.
- Hayes A.M. (2004) Pathophysiology of the liver. In: *Veterinary Pathophysiology*, 1<sup>st</sup> edn (ed. by R.H. Dunlop and C-H. Malbert), pp. 371-399. Blackwell Publishing Professional, Ames Iowa, USA; Carlton, Victoria, Australia.
- Hazel J.R.(1979) Influence of thermal acclimation on membrane lipid composition of rainbow trout liver.*American Journal of Physiology – Regulatory, Integrative and Comparative Physiology***236**, 91-101.
- Heath R., Coleman T. & Engelbrecht J.(2010) Water quality overview and literature review of the ecology of the Olifants River *WRC Report No. TT452/10*.
- Heath R., du Preez H., Genthe B. & Avenant-Oldewage A.(2004)Freshwater Fish and Human Health Reference Guide.A report to the Water Research Commission*WRC Report No TT212/04*.
- Helder T.H.(1979) Myopathy and steatitis in the common guppy, *Poecilia (Lebistes) reticulata* (Peters).*Laboratory Animals***13**, 225-226.
- Herman R.L. & Kircheis F.W.(1985) Steatitis in Sunapee trout, *Salvelinus alpinus oquassa* Girard.*Journal of Fish Diseases***8**, 237-239.
- Hinchcliff K.W. & Piercy R.J. (2000) Oxidant stress, oxidant damage, and antioxidants: Review and studies in Alaskan sled dogs. In: *Recent Advances in Canine and Feline Nutrition, Volume III, 2000 IAMS Nutrition Symposium Proceedings*, (ed. by G.A. Reinhart and D.P. Carey), pp. 517-529. Orange Frazer Press, Wilmington, Ohio.
- Hinton D.E. & Laurén D.J. (1990) Integrative histopathological approaches to detecting effects of environmental stressors on fishes.*American Fisheries Society Symposium***8**, 51-66.

- Hoffman L.C. & Prinsloo J.F. (1995) Genetic and nutritional influence on the total lipid fatty acid profile of *Clarias gariepinus* muscle. *Aquatic Living Resources***8**, 415-421.
- Hove E.L. (1955) Anti-vitamin E stress factors as related to lipid peroxides. *American Journal of Clinical Nutrition***3**, 328-336.
- Huchzermeyer F.W.(2003)*Crocodiles.Biology, Husbandry and Diseases*.CABI Publishing Wallingford, Cambridge, pp. 337.
- Huchzermeyer K.D.A.(2012) Prevalence of pansteatitis in African sharptooth catfish, *Clarias gariepinus* (Burchell), in the Kruger National Park, South Africa.*Journal of the South African Veterinary Association***83**(1) Art.#916,9 pages. <http://dx.doi.org/10.4102/jsava.v83i1.916>
- Huchzermeyer K.D.A., Govender D., Pienaar D.J. & Deacon A.R.(2011) Steatitis in wild sharptooth catfish, *Clarias gariepinus* (Burchell), in the Olifants and Lower Letaba Rivers in the Kruger National Park, South Africa. *Journal of Fish Diseases***34**, 489-498.
- Huchzermeyer K.D.A., Osthoff G., Hugo A. & Govender D. (in press) Comparison of the lipid properties of healthy and pansteatitis-affected African sharptooth catfish, *Clarias gariepinus* (Burchell), and the role of diet in pansteatitis outbreaks in the Olifants River in the Kruger National Park, South Africa. *Journal of Fish Diseases*.
- Hulbert A.J.(2003) Life, death and membrane bilayers.*Journal of Experimental Biology***206**, 2303-2311.
- Hung S.S.O., Cho C.Y. & Slinger S.J. (1980) Measurement of oxidation in fish oil and its effect on vitamin E nutrition of rainbow trout (*Salmo gairdneri*). *Canadian Journal of Fisheries and Aquatic Sciences* **37**, 1248-1253.
- Jolly R.D. & Dalefield R.R.(1990)Lipopigments in veterinary pathology: pathogenesis and terminology. In: *3rd International Symposium on Lipofuscin and Ceroid Pigments, 1989, Wailea, Maui, Hawaii*(ed.by E.A. Porta), pp. 157-168. Plenum Press, New York.



- Jones D., Howard A.N. & Gresham G.A. (1969) Aetiology of “yellow fat disease” (pansteatitis) in the wild rabbit. *Journal of Comparative Pathology* **79**, 329-337.
- Juan-Sallés C., Prats N., Resendes A., Domingo M., Hilton D., Ruiz J.M., Garner M.M., Valls X. & Marco A.J. (2003) Anemia, myopathy, and pansteatitis in vitamin E-deficient captive marmosets (*Callithrix* spp.). *Veterinary Pathology* **40**, 540–547.
- Kelly S.A., Havrilla C.M., Brady T.C., Abramo K.H. & Levin E.D. (1998) Oxidative stress in toxicology: established mammalian and emerging piscine model systems. *Environmental Health Perspectives* **106**, 375-384.
- Kennedy-Stoskopf S. (1993) Immunology. In: *Fish Medicine* (ed. by M.K. Stoskopf), pp. 149-159. W.B. Saunders Company, Harcourt Brace Jovanovich, Inc., Philadelphia.
- Kibanova D., Nieto-Camacho A. & Cervini-Silva J. (2009) Lipid peroxidation induced by expandable clay minerals. *Environmental Science and Technology* **43**, 7550-7555.
- Klaude M., Eriksson S., Nygren J. & Ahnström G. (1996) The comet assay: mechanisms and technical considerations. *Mutation Research* **363**, 89-96.
- Kolar C.S., Chapman D.C., Courtenay Jr. W.R., Housel C.M., Williams J.D. & Jennings D.P. (2005) Asian carps of the genus *Hypophthalmichthys* (Pisces, Cyprinidae) –A biological synopsis and environmental risk assessment. *Report to US Fish and Wildlife Service per Interagency Agreement 94400-3-0128* pp.175.
- Kumar V., Cotran R.S. & Robbins S.L. (1997) Environmental diseases. In: *Basic Pathology*, 6<sup>th</sup> edn. pp. 221-262. W.B. Saunders, Philadelphia, London, Toronto, Montreal, Sydney, Tokyo.
- Ladds P.W., Mangunwirjo H., Sebayang D. & Daniels P.W. (1995) Diseases in young farmed crocodiles in Irian Jaya. *Veterinary Record* **136**, 121-124.
- Langham R.F., Zydek F.A. & Bennet R.R. (1971) Steatitis in a captive Marley garter snake. *Journal of the American Veterinary Medical Association*. **159**, 640-641.

- Larsen R.E., Buergelt C., Cardeilhac P.T. & Jacobson E.R. (1983) Steatitis and fat necrosis in captive alligators. *Journal of the American Veterinary Medical Association***11**, 1202-1204.
- Lee R.F. & Steinert S. (2003) Use of the single cell gel electrophoresis/comet assay for detecting DNA damage in aquatic (marine and freshwater) animals. *Mutation Research***544**, 43-64.
- Levander O.A. & Beck M.A. (1997) Interacting nutritional and infectious etiologies of Keshan disease. *Biological Trace Element Research***56**, 5-21.
- Lin D.S. & Connor W.E. (1990) Are the n-3 fatty acids from dietary fish oil deposited in the triglyceride stores of adipose tissue? *American Journal of Clinical Nutrition***51**, 535-539.
- Lübcker N. (2011) Potential distribution of silver carp (*Hypophthalmichthys molitrix*) in South Africa. B.Sc. Honours Thesis, University of Pretoria.
- Metcalf C.D. (1998) Toxicopathic responses to organic compounds. In: *Fish Diseases and Disorders. Volume 2: Non-infectious Disorders* (ed. by J.F. Leatherhead and T.K. Woo), pp. 133-162. CABI Publishing, Wallingford, UK; New York, USA.
- Minotti G. & Aust S.D. (1992) Redox cycling of iron and lipid peroxidation. *Lipids***27**, 219-226.
- Moccia R.D., Hung S.S.O., Slinger S.J. & Ferguson H.W. (1984) Effect of oxidized fish oil, vitamin E and ethoxyquin on the histopathology and haematology of rainbow trout, *Salmo gairdneri* Richardson. *Journal of Fish Diseases***7**, 269-282.
- Murai T. & Andrews J.W. (1974) Interactions of dietary  $\alpha$ -tocopherol, oxidized menhaden oil and ethoxyquin on channel catfish (*Ictalurus punctatus*). *Journal of Nutrition***104**, 1416-1431.
- Mussagy A. (2008) Plankton monitoring program MIDSAR DP04, annual report. Massingir Dam and small holder agricultural rehabilitation project. National Directorate of Water. Ministry of Public Works and Housing. Mozambique.

- Neagari Y., Arie S., Udagawa M., Onuma M., Odaya Y., Kawasaki T., Tenpaku M., Hayama H., Harada K., Mizukami M. & Murata K.(2011) Steatitis in egrets and herons from Japan.*Journal of Wildlife Diseases***47**, 49-55.
- Nichols D.K., Campbell V.L. & Montali R.J.(1986) Pansteatitis in great blue herons.*Journal of the American Veterinary Medical Association***189**, 1110-1112.
- Niki E., Yamamoto Y., Takahashi M., Komuru E. & Miyama Y.(1989) Inhibition of oxidation of biomembranes by tocopherol. In: *Vitamin E: Biochemistry and Health Implications* (ed. by A.T. Diplock, L.J. Machlin, L. Packer & W.A. Pryor) *Annals of the New York academy of Science***570**, 23-31.
- Niza M.M.R.E., Vilela C.L. & Ferreira L.M.A. (2003) Feline pansteatitis revisited: hazards of unbalanced home-made diets. *Journal of Feline Medicine and Surgery***5**, 271-277.
- Oberholster P.J., Myburgh J.G., Ashton P.J., Coetzee J.J. & Botha A-M.(2011) Bioaccumulation of aluminium and iron in the food chain of Lake Loskop, South Africa.*Ecotoxicology and Environmental Safety***75**, 134-141.
- Osthoff G., Hugo A., Bouwman H., Buss P., Govender D., Joubert C.C. & Swarts J.C. (2010) Comparison of the lipid properties of captive, healthy wild, and pansteatitis-affected wild Nile crocodiles (*Crocodylus niloticus*). *Comparative Biochemistry and Physiology A*. **155**, 64-69.
- Parvez S. & Raisuddin S. (2006) Effects of paraquat on freshwater fish *Channa punctata* (Bloch): Non-enzymatic antioxidants as biomarkers of exposure. *Archives of Environmental Contamination and Toxicology***50**, 392-397.
- Pearson M.D., Chinabut S., Karnchanakharn S. & Somsiri T. (1994) Jaundice disease in the farmed catfish hybrid, *Clarias macrocephalus* (Gunther) x *C. gariepinus* (Burchell), in Thailand. *Journal of Fish Diseases***17**, 325-336.

- Pollock C.G., Sleeman J.M. Houle, C.D. & Ramsay E.C. (1999) Vitamin E deficiency and pancreatitis in juvenile boat-billed herons (*Cochlearius cochlearius*). *Journal of Zoo and Wildlife Medicine***30**, 297–300.
- Porter N.A. (1989) Autoxidation of polyunsaturated fatty acids: initiation, propagation, and product distribution (basic chemistry). In: *Free Radicals in Biology and Medicine*. 2<sup>nd</sup> edn (ed. by B. Halliwell and J.M.C Gutteridge), pp. 34-62. Clarendon Press. Oxford.
- Post G.W. (1993) Nutrition and nutritional diseases of salmonids. In: *Fish Medicine* (ed. by M.K. Stoskopf), pp. 343-358. W.B. Saunders Company. Harcourt Brace Javanovich, Inc., Philadelphia.
- Poston H.A., Combs Jr. G.F. & Leibovitz L. (1976) Vitamin E and selenium interrelations in the diet of Atlantic Salmon (*Salmo salar*): Gross, histological and biochemical deficiency signs. *Journal of Nutrition***106**, 892-904.
- Puertollano M.A., Puertollano E., Álvarez de Cienfuegos G. & de Pablo M.A. (2011) Dietary anti-oxidants: immunity and host defence. *Current Topics in Medicinal Chemistry***11**, 1752-1766.
- Raynard R.S., McVicar A.H., Bell J.G., Youngson A., Knox D. & Fraser C.O. (1991) Nutritional aspects of pancreas disease of Atlantic salmon: the effects of dietary vitamin E and polyunsaturated fatty acids. *Comparative Biochemistry and Physiology***98A(1)**, 125-131.
- Roberts R.J. & Agius C. (2003) Melanomacrophage centres and their role in fish pathology. *Journal of Fish Diseases***26**, 499-509.
- Roberts R.J. & Agius C.(2008) Pan-steatitis in farmed northern bluefin tuna, *Thunnus thynnus* (L.), in the eastern Adriatic. *Journal of Fish Diseases***31**, 83-88.
- Roberts R.J., Richards R.H. & Bullock A.M.(1979) Pansteatitis in rainbow trout *Salmo gairdneri* Richardson: a clinical and histopathological study. *Journal of Fish Diseases***2**, 85-92.

- Roberts R.J. & Rodger H.D.(2001)The pathophysiology and systemic pathology of teleosts. In: *Fish Pathology*, 3<sup>rd</sup>edn (ed. by R.J. Roberts), pp. 55-132. W.B. Saunders, London, Edinburgh, New York, Philadelphia, St. Louis, Sydney, Toronto.
- Roem A.J., Kohler C.C. & Stickney R.R. (1990) Vitamin E requirements of the blue tilapia, *Oreochromis aureus* (Steindachner), in relation to dietary lipid level. *Aquaculture***87**, 155-164.
- Seebacher F., Murray S.A. & Else P.L. (2009) Thermal acclimation and regulation of metabolism in a reptile (*Crocodylus porosus*): The importance of transcriptional mechanisms and membrane composition. *Physiological and Biochemical Zoology***82(6)**, 766–775.
- Skelton P. 2001 *A Complete Guide to the Freshwater Fishes of Southern Africa*. 2<sup>nd</sup> edn. Struik Publishers, Cape Town, pp. 395.
- Smith C.E. (1979) The prevention of liver lipid degeneration (ceroidosis) and microcytic anaemia in rainbow trout *Salmo gairdneri* Richardson fed rancid diets: a preliminary report. *Journal of Fish Diseases***2**, 429-437.
- Spataru P., Viveen W.J.A.R. & Gophen M. (1987) Food composition of *Clarias gariepinus* (= *C. lazera*) (Cypriniformes, Clariidae) in Lake Kinneret (Israel). *Hydrobiologica***144**, 77-82.
- Steffens W.(1997) Effects of variation in essential fatty acids in fish feeds on nutritive value of freshwater fish for humans. *Aquaculture***151**, 97-119.
- Stewart L.J. (1993) Nutrition of koi, carp and goldfish.In: *Fish Medicine* (ed. by M.K. Stoskopf), pp. 461-470. W.B. Saunders Company. Harcourt Brace Javanovich, Inc., Philadelphia.
- Stoskopf M. K.(1993) Fish histology. In: *Fish Medicine* (ed. by M.K. Stoskopf), pp. 31-47. W.B. Saunders Company. Harcourt Brace Javanovich, Inc., Philadelphia.

Tappel A.L. (1973) Lipid peroxidation damage to cell components. *Federation Proceedings* **32** (8), 1870-1874.

van den Broek A.H.M., Thoday K.L. (1994) Skin. In: *Feline Medicine and Therapeutics*. 2<sup>nd</sup> edn (ed. by E.A. Chandler, C.J. Gaskell and R.M. Gaskell), pp. 44-45. British Small Animal Veterinary Association. Blackwell Science Ltd. Oxford, London, Edinburgh; Malden, USA; Carlton, Victoria, Australia.

van Vleet J.A. & Valentine B.A. (2007) Muscle and Tendon. In: *Jubb, Kennedy and Palmer's Pathology of Domestic Animals*. 5<sup>th</sup> edn (ed. by M.G. Maxie), pp. 185-280. Elsevier Saunders, London, New York, Oxford, Philadelphia, St. Louis, Sydney, Toronto.

van Vuuren J.H.J., Wepener V., Smit N.J. & Vlok W. (2012) Biomarkers of pollution in tigerfish, *Hydrocynus vittatus*. South African National Parks 10<sup>th</sup> Annual Savannah Science Network Meeting. 5-9 March 2012. Skukuza.

Vélez-Hernández E.M., Constantino-Casas F., García-Márquez L.J. & Osorio-Sarabia D. (1998) Gill lesions in common carp, *Cyprinus carpio* L., in Mexico due to the metacercariae of *Centrocestus formosanus*. *Journal of Fish Diseases* **21**, 229-232.

Wada S., Hatai K. & Kubota S. (1991) A histopathological study of cultured striped jack with yellow fat disease. *Fish Pathology* **26**(2), 61-67.

Wagenaar G.M., Smith W.C. & Smit N.J. (2012a) The health status of tigerfish, *Hydrocynus vittatus*, in two rivers in the Kruger National Park using histology as a bio-monitoring tool. South African National Parks 10<sup>th</sup> Annual Savannah Science Network Meeting. 5-9 March 2012. Skukuza.

Wagenaar G.M., Smith W.C. & Smit N.J. (2012b) Histology as a bio-monitoring tool to assess the health status of selected fish species in the Levuvhu and Olifants rivers in the Kruger National Park. South African National Parks 10<sup>th</sup> Annual Savannah Science Network Meeting. 5-9 March 2012. Skukuza.



- Wallach J.D. & Hoessle C. (1968) Steatitis in captive crocodilians. *Journal of the American Veterinary Medical Association* **153**, 845-847.
- Watanabe T., Takeuchi T., Wada M. & Uehara R. (1981) The relationship between dietary lipid levels and  $\alpha$ -tocopherol requirement of rainbow trout. *Bulletin of the Japanese Society of Scientific Fisheries* **47**, 1463-1471.
- Weyl O.L.F. & Booth A.J. (2008) Validation of annulus formation in otoliths of a temperate population of adult African sharptooth catfish *Clarias gariepinus* using fluorochrome marking of wild fish. *Journal of Fish Biology* **73**, 1033-1038.
- White S.D. (2000) Skin as a sensor of internal medical disorders. In: *Textbook of Veterinary Internal Medicine. Diseases of the dog and cat*, 5<sup>th</sup> edn (ed. by S.J. Ettinger and E.C. Feldman), pp. 26-29. WB Saunders Company. Philadelphia, London, New York, St. Louis, Sydney, Toronto.
- Willoughby N.G. & Tweddle D. (1978) The ecology of the catfish *Clarias gariepinus* and *Clarias ngamensis* in the Shire valley, Malawi. *Journal of Zoology* **186**, 507-534.
- Winston G.W. (1991) Oxidants and antioxidants in aquatic animals. Mini-review. *Comparative Biochemistry and Physiology* **100C**, 173-176.
- Winston G.W. & Di Giulio R.T. (1991) Prooxidant and antioxidant mechanisms in aquatic organisms. *Aquatic Toxicology* **19**, 137-161.
- Wolf J.C. & Wolfe M.J. (2005) A brief overview of nonneoplastic hepatic toxicity in fish. *Toxicologic Pathology* **33**, 75-85.
- Wong E., Mikaelian I., Desnoyers M. & Fitzgerald G. (1999) Pansteatitis in a free-ranging red-tailed hawk (*Buteo jamaicensis*). *Journal of Zoo and Wildlife Medicine* **30**, 584-586.
- Woodborne S., Huchzermeyer K.D.A., Govender D., Pienaar D.J., Hall G., Myburgh J.G., Deacon A.R., Venter J. & Lückner N. (2012) Ecosystem change and the Olifants River

crocodile mass mortality events. *Ecosphere***3(10)**,87. <http://dx.doi.org/10.1890/ES12-00170.1>



## Review

## Steatitis in wild sharptooth catfish, *Clarias gariepinus* (Burchell), in the Olifants and Lower Letaba Rivers in the Kruger National Park, South Africa

K D A Huchzermeyer<sup>1,2</sup>, D Govender<sup>3</sup>, D J Pienaar<sup>3</sup> and A R Deacon<sup>3</sup>

1 Sterkspruit Veterinary Clinic, Lydenburg, South Africa

2 Department of Paraclinical Sciences, Faculty of Veterinary Science, University of Pretoria, Pretoria, South Africa

3 Scientific Services, South African National Parks, Skukuza, South Africa

### Abstract

Large numbers of adult Nile crocodiles, *Crocodylus niloticus* (Laurenti), died from pansteatitis during autumn and winter 2008 in the lower Letaba and Olifants River gorge in the Kruger National Park, South Africa. Consequently, the health status of fish from these waters was investigated. The study presents the pathological findings in fish inhabiting these rivers within the boundaries of the Park. Changes typical of steatitis were diagnosed in many of the larger specimens of sharptooth catfish, *Clarias gariepinus* (Burchell), caught within the Olifants River gorge. These fish carried large amounts of mesenteric fat with characteristic small brown granulomata within the adipose tissue. Necrosis and inflammation of the adipose tissues, with characteristic ceroid accumulation within the resultant granulomata and the associated aggregation of ceroid-containing macrophages, were demonstrated histologically and were typical of steatitis. Other changes included mild thickening and pallor of the gill tissues and swollen, orange, fatty livers. Focal hepatic lipidosis was demonstrated histologically, and special stains revealed storage of large amounts of iron in the livers. Blood smears revealed chromatin clumping in erythrocyte nuclei and nuclear and cell membrane irregularities. This is the first record of steatitis in wild-caught *C. gariepinus*.

**Correspondence** K D A Huchzermeyer, Sterkspruit Veterinary Clinic, P.O. Box 951, Lydenburg 1120, South Africa (e-mail: aquavet@telkomsa.net)

**Keywords:** *Clarias gariepinus*, crocodiles, fat, Kruger National Park, Olifants River, steatitis.

### Introduction

Unexplained fish and crocodile deaths in the Olifants River, in the north-east of South Africa, have raised concern for a number of years (De Villiers & Mkwelo 2009). Altered hydrodynamics and extensive industrial, mining and agricultural activities in the catchment in Mpumalanga Province have resulted in this river becoming one of the most threatened aquatic ecosystems in South Africa (De Villiers & Mkwelo 2009). The Olifants River flows from west to east, for a distance of some 90 km, through the Kruger National Park (KNP) before being joined by the Letaba River in the Olifants Gorge. The gorge extends for a further 9 km to the Mozambique border where it opens into the Massingir Dam.

The Olifants River gorge and the confluence with the lower Letaba River are home to one of the most dense populations of large Nile crocodiles, *Crocodylus niloticus* (Laurenti), in South Africa. Large numbers of adult crocodiles were found dead during autumn and winter 2008, in both the Olifants and Letaba Rivers in an area stretching from about 10 km upstream of the confluence through the gorge to the Mozambique border. Some 180 dead crocodiles out of a known population of at least 600 were found. Other crocodiles showed impaired movement and an inability to swim. Apparently healthy crocodiles as well as those obviously affected were observed in the same area.

Autopsies performed on some of the crocodiles by KNP veterinarians revealed exceptionally fat carcasses with an abnormal hardening and yellow discolouration of the fat. Histological examination confirmed an inflammation of the fat typical of pansteatitis (E.P. Lane, F.W. Huchzermeyer, D. Govender, R.G. Bengis, E.B. Bus, M. Hofmeyr, J.G. Myburgh, J.C.A. Steyl, D.J. Pienaar & A. Kotze, University of Pretoria, personal communication). A further 24 crocodile carcasses were found during the winter of 2009. The Olifants Gorge consists of a steep sided ravine where the Olifants River cuts through the Lebombo Mountains creating a habitat of sandbanks, deep sand bottomed pools and fast flowing rapids. Since the raising of the Massingir Dam wall in Mozambique in 2008, many of the pools and rapids in the gorge have been flooded and clay-rich sediments carried by the river have been deposited in the gorge where they have inundated the pools.

The Olifants Gorge lies in a remote area where fish mortalities may go unnoticed, but for the first time, in July 2009, a large fish mortality was observed within the gorge. Affected fish were almost exclusively large sharp-tooth catfish, *Clarias gariepinus* (Burchell), and were found in waters overlying the clay-rich deposits at the point where the gorge widens into the dam. Fish carcasses were observed to be very fat. The fish kill remained localized in space and time, and no mortalities were observed in either the Olifants or Letaba Rivers upstream of the gorge, and fish in Massingir Dam also appeared unaffected.

Pansteatitis is a nutritionally mediated condition characterized by necrosis and inflammation of the adipose tissues. The condition has been described from many species of both warm- and cold-blooded animals, associated with the feeding of rancid or unsaturated fats, often of fish origin, particularly in the absence of sufficient vitamin E (Murai & Andrews 1974; Roberts, Richards & Bullock 1979; Herman & Kircheis 1985; Fytianou, Koutinas, Saridomichelakis & Koutinas 2006; Goodwin 2006; Roberts & Agius 2008). Previously described cases of pansteatitis in crocodiles were associated with consumption of large numbers of dead and rancid fish consumed by farmed crocodiles (Huchzermeyer 2003). Larsen, Buergelt, Cardeilhac & Jacobson (1983) reported steatitis at slaughter in apparently healthy alligators fed an exclusive fish diet. Mass fish mortality, caused by acid mine seepage, was found to be the most likely cause of the

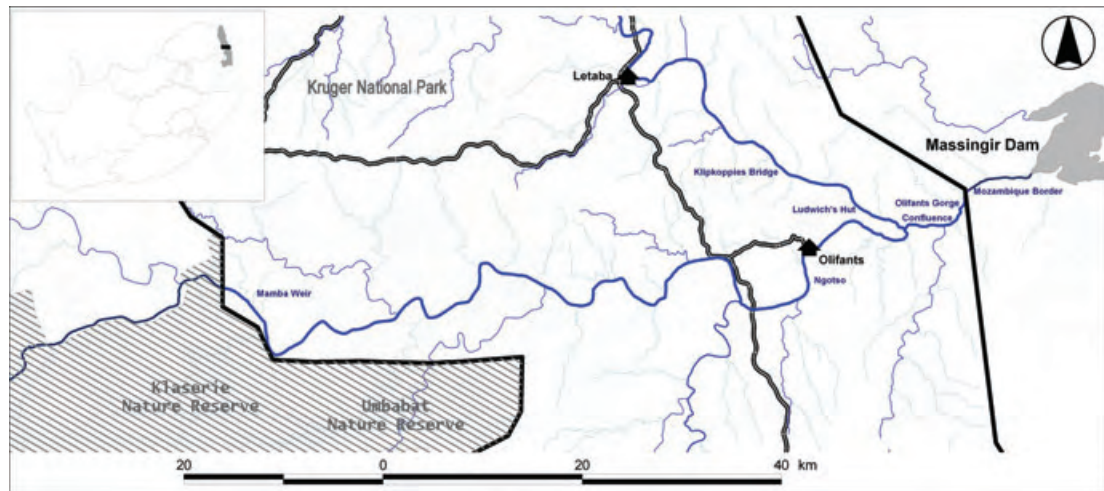
deaths of significant numbers of crocodiles and terrapins as a result of pansteatitis in Loskop Dam, higher up on the Olifants River, in 2007 (J.G. Myburgh, J.C.A. Steyl, F.W. Huchzermeyer, M.C. Williams, D.G. Booyse, L.J. Guillette Jr. & J.J. Coetzee, University of Pretoria, personal communication). The 2008 episode of crocodile pansteatitis in the KNP was noteworthy by the absence of observed fish mortality, although circumstantial evidence pointed to illegal fishing activity with gill nets within the gorge as a possible source of dead, rancid fish. This led to extensive sampling and examination of fish from the Olifants and Letaba Rivers within the KNP in an attempt to identify precipitating factors that may have contributed to the development of pansteatitis in the crocodiles.

Fish specimens were collected from the Olifants and Letaba Rivers in the KNP on various occasions as the pansteatitis-related deaths of crocodiles first became apparent in 2008. This project forms part of the multidisciplinary research into the causes of the crocodile mortalities under the auspices of the Consortium for the Restoration of the Olifants Catchment (CROC) initiative.

## Materials and methods

Various species of fish, comprising a total of 145 specimens, were collected from five different localities along the Olifants and Letaba Rivers: Olifants Gorge, from the confluence with the Letaba River (S:23°59'32" E:031°49'57") to the Mozambique border (S:23°57'48" E:031°52'97"), Klipkoppies Bridge (S:23°56'58" E:031°43'89") above the cascade on the Letaba River and Ludwig's Hut (S:23°58'29" E:031°47'41") below the cascade on the Letaba River, Ngotso (S:24°02'96" E:031°44'24") on the Olifants River and at Mamba Weir (S:24°03'32" E:031°14'14") on the Olifants River near the western boundary of the KNP (Fig. 1). Samplings took place during September 2008 and January, June, July, August and November 2009. Autopsies, blood smears and histological examination were used to determine the degree and variation of pathological changes present in the fish. Initially, a broad range of fish represented in these rivers was examined but sampling was later restricted to *C. gariepinus*.

Baited hook and cast netting were used to catch fish. All fish were anaesthetized for blood collection using a benzocaine hydrochloride bath at approx-



**Figure 1** Sampling sites along the Olifants and Letaba rivers in the Kruger National Park, South Africa.

imately 30 ppm strength prior to being killed. Fish were killed through an overdose of benzocaine hydrochloride. Blood samples were drawn from the vessels just ventral to the vertebral column, either from the tail region in the case of anaesthetized fish or through the kidney during post-mortem dissection of the fish. Fresh blood smears were taken from all fish. Gill wet mounts were examined microscopically for gill condition and the presence of parasites. Fish were examined by autopsy for gross pathological changes, and data sheets were compiled. Data included length and weight measurements, body condition, organ descriptions, level of parasitism and stomach and intestinal contents. Samples from a range of organs and tissues were fixed in 10% buffered formalin for histological examination.

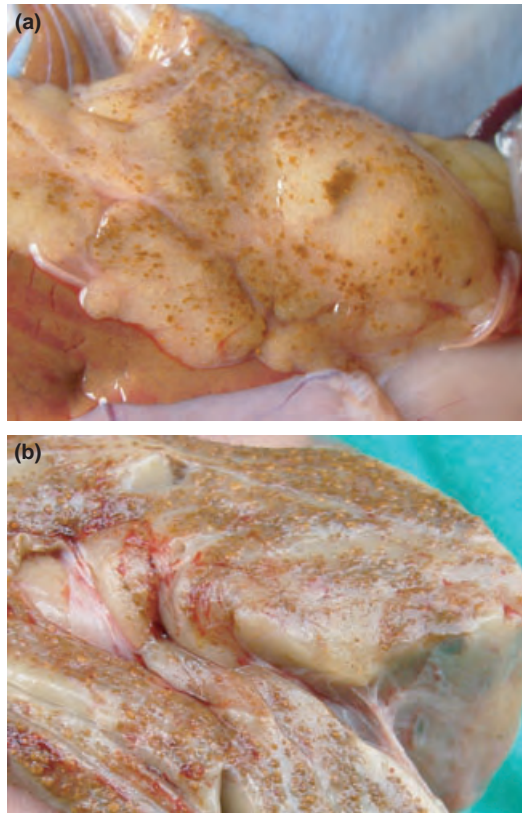
Formalin-fixed tissue specimens were processed using standard histological techniques, and 5- $\mu$ m sections were prepared and stained with haematoxylin and eosin (H&E). Periodic acid-Schiff (PAS), Gomori's aldehyde fuchsin (GAF) and Perl's Prussian blue stain were used to stain selected sections. Blood smears were stained with a CAM's quick stain (Kyro-Quick stain; Kyron Laboratories). Blood smears and histological sections were examined by standard light microscopy.

## Results

Characteristic of the *C. gariepinus* specimens collected from the Olifants Gorge and lower Letaba River were the large amount of variably coloured fat

in the body cavity and between the muscles of the tail and the distinct white and brown spots observed within the mesenteric fat of some fish. By contrast, other species of fish collected had white fat devoid of lesions. In *C. gariepinus*, fat colour, particularly prominent in the mesenteric fat reserves, varied from almost pure white through shades of cream to yellow. Leaner fish with only small amounts of mesenteric fat invariably had dark yellow to orange fat. Various nodular reactions were observed in the adipose tissues of *C. gariepinus* specimens. Parasitic granulomata were distinguishable from foci of inflammation and granuloma formation associated with non-parasitic causes. Parasitic granulomata in the mesenteric fat of some of the *C. gariepinus* specimens were typically well circumscribed and white in appearance, ranging from 2 to 15 mm in diameter. On incision, these revealed a central encysted parasite and consisted of a well-defined white connective tissue reaction. These parasitic granulomata differed from smaller granulomata of varying shades of brown which when present, were numerous and mostly did not exceed 5 mm in diameter (Fig. 2a). These granulomata were often focally disseminated throughout the entire mesenteric fat, in severe cases imparting a granular grey brown discolouration and in milder cases appearing to cluster along blood vessels. Advanced granulomata presented with a central, < 1 mm in diameter orange area, imparting a granular or rough appearance with a diffuse increase in consistency and in some cases with almost total obliteration of normal fat tissue (Fig. 2b).





**Figure 2** Macroscopic appearance of mesenteric adipose tissue from steatitis affected *Clarias gariepinus* from the Olifants Gorge. (a) Small golden brown granulomata from a mildly affected fish. (b) Advanced lesions from a severely affected fish.

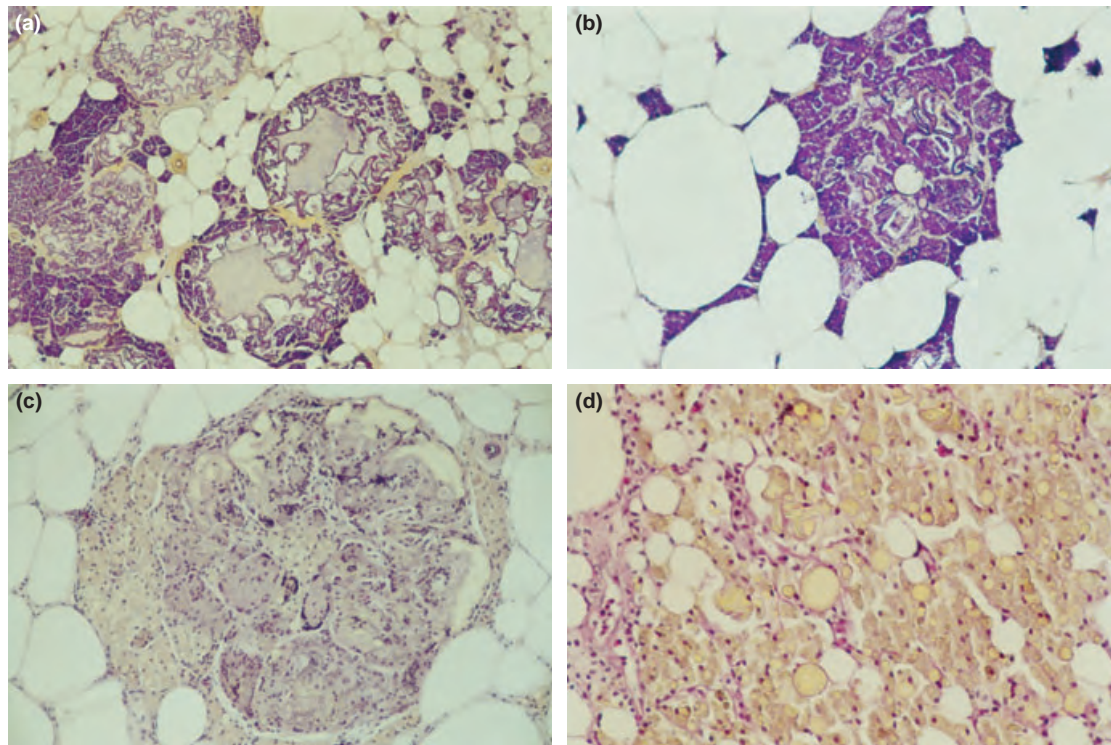
The histological appearance of the non-parasitic granulomata in the adipose tissues was typical of lesions expected with steatitis and consisted of varying enlarged as well as ruptured adipocytes surrounded by a dense mass of ceroid-containing macrophages (Fig. 3a), with presence of variable numbers of fibroblasts. These lesions were focally disseminated throughout the affected mesenteric adipose tissue and represented the brown granulomata noted macroscopically. Smaller lesions consisted primarily of ceroid-containing macrophage aggregations within the interstitium of the fat tissues. Presence of ceroid in the macrophages was confirmed by staining with GAF (Fig. 3a, b) and PAS stains. Multinucleate Langhans giant cells surrounding an irregular central necrotic area were evident in most of these granulomata (Fig. 3c). These central areas often consisted of an irregular refractile substance, described by Begg, Bruno & McVicar (2000) as lipopigment (Fig. 3a), evident as yellowish, amorphous material in haematoxylin-

and eosin-stained smears. Similar yellow, granular and refractile inclusions of varying size were present in many of the surrounding macrophages of most lesions (Fig. 3d). In some lesions, more compact macrophages were arranged in the form of an epithelioid type sheath surrounding the ruptured fat cells. Advanced cases presented with a clear lacuna surrounded by organized layers of epithelioid cells that in places coalesced and became embedded in fibrous connective tissue. Granulomata were found primarily in the mesenteric fat reserves and could not be demonstrated in the fat cushion behind the pectoral fin or in the epicardial fat, the hypodermal or intermuscular fat. A distinct exudative peritonitis associated with signs of steatitis was observed in a single *C. gariepinus* specimen that was caught in the gorge on the Mozambique border. Parasitic granulomata of varying sizes were common in the mesenteric, hypodermal and intermuscular fat but were not noted in the pectoral fat.

Brown granulomata in the fat were observed in both male and female fish but were absent in specimens under 2 kg body mass and measuring <70 cm in length. The prevalence of macroscopically characteristic lesions of steatitis on various sampling occasions during 2008 and 2009 is illustrated in Table 1. In the week after the July 2009 fish die-off in the gorge, six *C. gariepinus* specimens were caught in the area of the fish kill. All these fish showed presence of brown granulomata in the fat. The same granulomata were again observed in 4 out of 12 specimens caught on the Mozambique border during August 2009.

Livers of *C. gariepinus* from the gorge ranged in colour but appeared distinctly orange, fatty and swollen in appearance compared with fish caught in other sections of the river. A varying degree of fat vacuolation in the livers, often within clearly defined zones, was characteristic of fish collected from the gorge (Fig. 4a). Large amounts of ceroid, golden brown breakdown products of oxidized unsaturated fat as well as iron or haemosiderin were visible within the hepatocytes. In places, well-demarcated foci of fat vacuolation contained distinctly less iron than in surrounding hepatocytes. In other areas, the haemosiderin appeared clumped within the zone of fat vacuolation (Fig. 4b). Adventitious macrophages were numerous in the liver where they contained large deposits of both ceroid and iron, imparting a pronounced golden brown colour in the haematoxylin- and eosin-stained sections with the macrophages staining





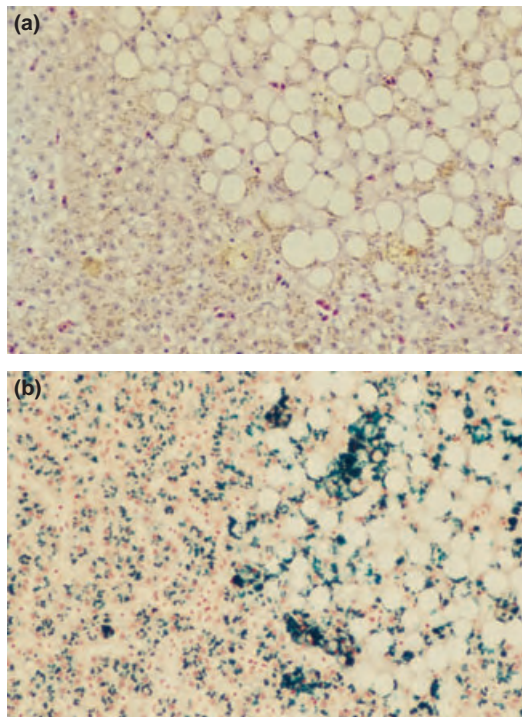
**Figure 3** Histological sections of granulomata in the mesenteric fat of *Clarias gariepinus* from the Olifants Gorge. (a) Central area of fat necrosis consisting of lipopigment surrounded by ceroid-containing macrophages and fibroblast reaction (GAF,  $\times 40$ ). (b) Ruptured adipocytes surrounded by ceroid-containing macrophages (GAF,  $\times 100$ ). (c) Multinucleate giant cells surrounding areas of fat cell necrosis and lipopigment (H&E  $\times 100$ ). (d) Xylene-insoluble lipopigment inclusions in macrophages surrounding necrotic fat cells (H&E  $\times 400$ ).

**Table 1** Prevalence of macroscopically detectable steatitis lesions in *Clarias gariepinus* from the Olifants and Letaba River sampling sites on various sampling occasions

Date	Site	Fish with steatitis	Total fish sampled
September 2008	Gorge Letaba confluence	1	8
September 2008	Letaba Ludwig's hut	0	4
September 2008	Letaba Klipkoppies bridge	0	1
September 2008	Olifants Mamba weir	0	1
January 2009	Gorge Letaba confluence	0	7
January 2009	Letaba Klipkoppies bridge	0	2
January 2009	Olifants Ngotso	0	9
January 2009	Olifants Mamba weir	0	4
June 2009	Gorge Letaba confluence	3	9
June 2009	Gorge Letaba confluence	3	4
June 2009	Letaba Klipkoppies bridge	0	5
June 2009	Olifants Ngotso	0	10
July 2009	Gorge Letaba confluence	6	6
August 2009	Gorge Letaba confluence	1	2
August 2009	Gorge Mozambique border	4	12
November 2009	Gorge Letaba confluence	6	21

strongly for iron with Perl's Prussian blue stain. Melanomacrophages in the spleen and kidneys of these fish were replete with ceroid, and the splenic macrophages carried large amounts of haemosiderin. Iron was also observed in the macrophages of the

kidney, but to a lesser extent than in the spleen and liver. Positive Perl's staining material was observed in some of the renal tubular epithelial cells. Sections of the ovaries of these fish showed numerous adventitious macrophage aggregates containing



**Figure 4** Histological section of liver of *Clarias gariepinus* from the Olifants Gorge. (a) Clearly demarcated zone of lipid vacuoles adjacent to non-vacuolated hepatocytes. Note pigment granules within macrophages and hepatocytes (H&E,  $\times 200$ ). (b) Positive staining reaction for haemosiderin. Note irregular haemosiderin deposition within zone of lipid vacuolation (Perl's Prussian blue,  $\times 200$ ).

large amounts of iron, whereas testicular macrophage centres were devoid of iron. Macrophage aggregations associated with fat cell necrosis in the adipose tissues did not contain iron neither did the macrophages in the hypodermis nor the macrophage centres in the pancreas.

Foci of inflammatory cells were observed in the heart, kidney and liver. In the liver, these were associated with ducts and blood vessels. In the cranial and caudal kidney, they appeared as focally disseminated clusters of dense basophilic cells. Well-encapsulated parasitic granulomata of varying sizes were a common finding in many of the livers. Secondary haemopoietic cell activity was prevalent in the heart and liver of many of the *C. gariepinus* specimens from the gorge. Some of these specimens showed signs of excessive haemolysis and an increase in the phagocytic lining of the ventricle. Pancreatic acinar and islet cells appeared normal in all of the fish, although the prominence of pancreatic tissues, macroscopically, was quite variable.

Gills of many *C. gariepinus* specimens collected from the Olifants Gorge and the lower Letaba River appeared paler than normal and mildly hyperplastic. Some of these gills, particularly in the *C. gariepinus* specimens from the gorge and lower Letaba River collected during January 2009, presented with a two- to threefold increase in the thickness of the epithelium of the secondary lamellae. In many of these specimens, the epithelial hyperplasia increased towards the base of the secondary lamellae imparting a wedge-shaped appearance. These changes were less evident in fish sampled from the same site in November 2009.

Examination of blood smears revealed an abundance of immature erythrocytes in many of the fish collected from the gorge particularly during the January 2009 sampling. Many erythrocytes showed irregular shapes. Nuclear shapes were similarly irregular with a high prevalence of chromatin clumping visible within the nuclei.

Stomach contents from *C. gariepinus* specimens collected in the gorge near the confluence yielded mainly fish remnants, in many cases from fairly large fish. Specimens collected from waters directly over the silt deposits in the gorge on the Mozambique border appeared to have been ingesting only detritus and silt. This area was characterized by a general paucity of other fish species.

A variety of parasites including monogenean trematodes and the cysts of digenetic trematode larvae were found in low to moderate numbers on the gills of many of the *C. gariepinus* specimens. *Argulus japonicus* were found in low numbers on the gills of two *C. gariepinus* specimens. Various parasitic cysts were found in the mesenteric tissues, livers and serosa of the intestines and in the musculature of many of these fish. The peritoneal cavity of many of the *C. gariepinus* specimens yielded low to moderate numbers of nematodes. No difference in the pattern of parasitism between sampling sites could be detected; however, it was noteworthy that no protozoan parasites were observed.

## Discussion

*Clarias gariepinus* was the only fish species found in the Olifants Gorge to show significant lesions in the adipose tissues. Histological examination of the adipose tissues confirmed the presence of steatitis. The presence of ceroid-laden macrophages and characteristic foreign body giant cells surrounding

degenerating and ruptured adipocytes as well as the associated granuloma formation are typical findings in all species suffering from pansteatitis, and microscopically, the lesions in *C. gariepinus* resembled those described in other species (Murai & Andrews 1974; Roberts *et al.* 1979; Herman & Kircheis 1985; Begg *et al.* 2000; Goodwin 2006; Roberts & Agius 2008). The macroscopic appearance of the adipose tissues of *C. gariepinus* differed from most other freshwater fish species that have characteristically white fat. A variation in colour from white through various shades of cream and yellow to dark orange appears to be normal in wild *C. gariepinus*. In contrast to pansteatitis in crocodiles and mammalian species, where affected fat tissue takes on a characteristic yellow colour, fat colour alone may be misleading when looking for signs of pansteatitis in *C. gariepinus*. Although fat consistency did change with steatitis in *C. gariepinus*, it did not take on the typically hard consistency noted in crocodiles (Larsen *et al.* 1983; Osthoff, Hugo, Bouwman, Buss, Govender, Joubert & Swarts 2010).

The livers of *C. gariepinus* specimens caught in the gorge were characteristically fatty and showed signs of fatty degeneration of the hepatocytes with accumulation of both ceroid and haemosiderin in hepatocytes and melanomacrophages. Melanomacrophage centres are known to store lipofuscin, a breakdown product of unsaturated fatty acid peroxidation, as well as melanin and haemosiderin (Kennedy-Stoskopf 1993) and represent possible forerunners of the germinal centres in the spleen and lymph nodes of higher animals (Agius 1979). They are a unique feature of the lymphomyeloid tissue of fish (Kennedy-Stoskopf 1993) and play a role in iron storage (Agius 1979). Perl's Prussian blue stain demonstrates the presence of ferric iron. Agius (1979) looked at the pattern of iron storage in the melanomacrophage centres in various organs of 14 different species of healthy and diseased fish. The spleen was the main organ of iron storage by melanomacrophages, whereas melanomacrophage centres in the liver and kidney were found to store insignificant amounts of iron. Whilst certain diseases including pansteatitis resulted in the accumulation of iron in splenic macrophage centres, the same did not happen in hepatic and renal macrophage centres (Agius 1979). In *C. gariepinus* specimens from the gorge, it was noted that the splenic melanomacrophages carried heavy deposits of iron. In the majority of fish, this was also the case in the

hepatic melanomacrophage centres and even renal melanomacrophages contained obvious amounts of iron, albeit less than in the liver. Adventitious macrophage aggregations in the ovaries also contained large amounts of iron, whereas macrophage aggregations associated with fat cell necrosis in the adipose tissues and macrophage centres in the pancreas, testes and hypodermis did not contain iron. It is not clear whether the iron deposits represent increased iron storage as haemosiderin because of excessive haemolysis or whether they are indicative of abnormal uptake of iron from the environment. However, Baker, Martin & Davies (1997) have demonstrated heightened oxidative stress in *C. gariepinus* ingesting increased levels of iron under experimental conditions.

The erythrocyte changes observed in blood smears from *C. gariepinus* in the gorge showed the irregularity in shape described by Post (1993) and Murai & Andrews (1974) in cases of vitamin E deficiency in fish. The observed nuclear and cell membrane abnormalities in the blood smears may point towards an increase in apoptosis. Reduced haemopoiesis in the kidney as well as an increase in erythrocyte turnover may explain the secondary haemopoiesis observed in the heart and liver in *C. gariepinus* from the gorge.

Lesions associated with steatitis, other than those observed in the adipose tissues, appear to be variable depending on species involved. Exudative diathesis as described by Murai & Andrews (1974) in channel catfish *Ictalurus punctatus* (Rafinesque), and muscular dystrophy described in channel catfish (Murai & Andrews 1974) and rainbow trout, *Oncorhynchus mykiss* (Walbaum) (Roberts *et al.* 1979) were not a consistent feature of the pansteatitis observed in *C. gariepinus*, although an exudative peritonitis was noted in one fish suffering from steatitis. Fin loss and skin ulceration described in channel catfish in association with steatitis by Goodwin (2006) were not observed in *C. gariepinus* nor was a granulomatous infiltration between the pterygophores as described in wild common dab, *Limanda limanda* (L.), by Begg *et al.* (2000). The swimbladder changes described by Roberts *et al.* (1979) in rainbow trout suffering from pansteatitis could not be demonstrated in *C. gariepinus*, which has a reduced, displaced swimbladder enveloped by a bony capsule formed by the lateral processes of the fourth and fifth vertebrae (Petrick 1975). Roberts & Agius (2008) described lethargy and erratic swimming bursts as presenting signs in farmed northern



bluefin tuna, *Thunnus thynnus* (L.), suffering from pansteatitis. No specific pathological changes were observed in the brain tissues of *C. gariepinus* specimens from the Olifants Gorge, but lethargy and frenzied swimming would rapidly attract crocodiles, making it unlikely that such advanced cases would be represented amongst the sampled fish.

There are few references in the literature describing pansteatitis in wild-caught freshwater fish. The condition has been described in various species of farmed fish where it is primarily a nutritional problem involving feeding of unsuitable quantities or types of unsaturated fats (Bricknell, Bruno, Bowden & Smith 1996; Goodwin 2006; Roberts & Agius 2008) and where the condition can be mediated by the presence of adequate vitamin E or addition of ethoxyquin in the diet (Murai & Andrews 1974). Begg *et al.* (2000) reported steatitis in two species of wild marine fish, common dab and long rough dab, *Hippoglossoides platessoides* (Fabricius), with suspicion of a pollution-related aetiology. Bairy, Saito, Carvalho & Junqueira (1996) have linked the effects of oxidative stress from polluted water to changes in antioxidant parameters in Nile tilapia, *Oreochromis niloticus* L. The initiation of lipid peroxidation by cyclic reduction/oxidation has been linked to ingested iron (Minotti & Aust 1992; Elbaraasi, Mézes, Balogh, Horváth & Csengeri 2004) and the iron fraction in expandable clay minerals (Kibanova, Nieto-Camacho & Cervini-Silva 2009). That *C. gariepinus* must have considerable antioxidant protective mechanisms is evidenced by their survival despite extensive lesions. It is noteworthy that lesions appeared to be restricted to the mesenteric fat, possibly indicating differing susceptibility of the various adipose reserves. Similarly, Goodwin (2006) found differences in the susceptibility of various fat tissues in channel catfish suffering from steatitis. In the case of channel catfish, the peritoneal fat reserves appeared to remain intact, whereas lesions were found in the fin bases, the hypodermis and the fat surrounding the brain. This may reflect differences in lipid type stored in the different fat tissues as proposed by Goodwin (2006). Some fat reserves may be more critical to the survival of wild fish, reducing the likelihood of fish with extensive pansteatitis surviving to be caught on hook and line. For the same reason, it is possible that some changes observed in other species of fish under aquaculture conditions would rarely be seen in wild-caught specimens. In the Olifants River gorge,

high predator pressure would rapidly remove weakened fish.

Stomach and intestinal contents of the steatitis-affected *C. gariepinus* specimens indicated that appetite was not completely suppressed. This was confirmed by the willingness of the fish to take baited hooks. Similarly, in bluefin tuna suffering from pansteatitis, Roberts & Agius (2008) found that the stomachs and intestines of even moribund fish contained food. *Clarias gariepinus* is an omnivorous benthic scavenger that is also known to actively hunt other fish (Bruton 1996). Significant differences in stomach and intestinal contents were noted between the various sampling sites. Of significance was the presence of clay containing sediment in the intestines of fish caught in waters overlying the clay-rich silt deposits in the gorge as well as in the presence of fish remnants in the stomachs of specimens caught near the Olifants and Letaba confluence, at the entrance to the gorge. This was in contrast to the predominantly vegetable and invertebrate content found in the gastrointestinal tracts of specimens caught at other sampling sites where steatitis did not occur. In the Olifants Gorge, *C. gariepinus* reach a body mass of 9 kg and more. Remnants from often quite large fish were found in the stomach contents of these specimens, confirming that they were either preying on other weakened fish or scavenging off dead fish in the gorge.

The presence of diverse parasites at mild to moderate numbers reflected a relatively healthy host–parasite relationship in the fish. The majority of the parasites noted have a multihost lifecycle, indicating that both the invertebrate intermediate host and the vertebrate final host must be present within the broader ecosystem.

*Clarias gariepinus* has a broad distribution and is ubiquitous in South African river systems and is hence worthy of investigation where anthropogenic activity has seriously impacted aquatic ecosystems. The variation in pathology that was observed in the fish from the Olifants Gorge appears consistent with oxidative stress. The most significant lesion identified during this fish health assessment was the steatitis present in the adipose tissues of *C. gariepinus* specimens from the Olifants Gorge. Poikilothermic (cold-blooded) animals, such as fish, depend on lipoprotein polyunsaturated fats to maintain membrane fluidity and normal metabolic function especially at colder ambient temperatures (Stewart 1993). They

are thus likely to be more sensitive to the effects of lipid autooxidation than warm-blooded animals. This may explain the observed mortalities in both crocodiles and sharp-tooth catfish during the winter months and the absence of mortality during the summer months.

It is unusual for a benthic scavenger such as *C. gariepinus* to develop steatitis in the wild. This is the first record of steatitis in wild *C. gariepinus* as far as the authors are aware. This species of fish is hardy and well adapted to a wide habitat and food range explaining its extensive distribution throughout Africa. We conclude that it is unlikely that steatitis observed in the sharp-tooth catfish in the Olifants River is pure coincidence and propose that the finding is significant in relation to the development of pancreatitis in crocodiles occupying the same section of river.

### Acknowledgements

The assistance received by Ampath Pathologists Laboratory who kindly prepared many of the histological tissue sections is gratefully acknowledged. We also thank the SAN Parks staff that facilitated the fieldwork and the fishermen who assisted with catching fish. From the Department of Paraclinical Science at the Faculty of Veterinary Science, University of Pretoria, Dr Johan Steyl is thanked for the preparation of specially stained histology sections and Prof John Lawrence for his editorial comments. Dr Philippa Colly of Sterkspruit Veterinary Clinic is thanked for assistance with editing. The colleagues from the clinic are thanked for helping with dissections and standing in during the principal author's absence doing fieldwork. This project was partially funded by the Water Research Commission, South Africa, Consultancy K8/948.

### References

- Agius C. (1979) The role of melano-macrophage centres in iron storage in normal and diseased fish. *Journal of Fish Diseases* **2**, 337–343.
- Bainy A.C.D., Saito E., Carvalho P.S.M. & Junqueira V.B.C. (1996) Oxidative stress in gill, erythrocytes, liver and kidney of Nile tilapia (*Oreochromis niloticus*) from a polluted site. *Aquatic Toxicology* **34**, 151–162.
- Baker R.T.M., Martin P. & Davies S.J. (1997) Ingestion of sub-lethal levels of iron sulphate by African catfish affects growth and tissue lipid peroxidation. *Aquatic Toxicology* **40**, 51–61.
- Begg G.S., Bruno D.W. & McVicar A.H. (2000) The histopathology and ultrastructure of steatitis affecting common dab *Limanda limanda*. *Diseases of Aquatic Organisms* **41**, 123–133.
- Bricknell I.R., Bruno D.W., Bowden T.J. & Smith P. (1996) Fat cell necrosis syndrome in Atlantic halibut, *Hippoglossus hippoglossus* L. *Aquaculture* **144**, 65–69.
- Bruton M.N. (1996) Alternative life-history strategies of catfishes. In: *The Biology and Culture of Catfishes* (ed. by M. Legendre & J.-P. Proteau), *Aquatic Living Resource* **9**, Hors série, 35–41.
- De Villiers S. & Mkwelo S.T. (2009) Has monitoring failed the Olifants River, Mpumalanga? *Water SA* **35**, 671–676.
- Elbaraasi H., Mézes M., Balogh K., Horváth L. & Csengeri I. (2004) Effects of dietary ascorbic acid/iron ratio on some production traits, lipid peroxide state and amount/activity of glutathione redox system in African catfish *Clarias gariepinus* (Burchell) fingerlings. *Aquaculture Research* **35**, 256–262.
- Fytianou A., Koutinas A.F., Saridomichelakis M.N. & Koutinas C.K. (2006) Blood  $\alpha$ -tocopherol, selenium, and glutathione peroxidase changes and adipose tissue fatty acid changes in kittens with experimental steatitis (yellow fat disease). A comparative study between the domestic shorthaired and Siamese breed. *Biological Trace Element Research* **112**, 131–143.
- Goodwin A.E. (2006) Steatitis, fin loss and skin ulcers of channel catfish, *Ictalurus punctatus* (Rafinesque), fingerlings fed salmonid diets. *Journal of Fish Diseases* **29**, 61–64.
- Herman R.L. & Kircheis F.W. (1985) Steatitis in Sunapee trout, *Salvelinus alpinus oquassa* Girard. *Journal of Fish Diseases* **8**, 237–239.
- Huchzermeyer F.W. (2003) *Crocodiles. Biology, Husbandry and Diseases*. CABI Publishing, Wallingford, Cambridge, pp. 337.
- Kennedy-Stoskopf S. (1993) Immunology. In: *Fish Medicine* (ed. by M.K. Stoskopf), pp. 149–159. W.B. Saunders Company, Harcourt Brace Jovanovich, Inc., Philadelphia.
- Kibanova D., Nieto-Camacho A. & Cervini-Silva J. (2009) Lipid peroxidation induced by expandable clay minerals. *Environmental Science and Technology* **43**, 7550–7555.
- Larsen R.E., Buergelt C., Cardeilhac P.T. & Jacobson E.R. (1983) Steatitis and fat necrosis in captive alligators. *Journal of the American Veterinary Medical Association* **11**, 1202–1204.
- Minotti G. & Aust S.D. (1992) Redox cycling of iron and lipid peroxidation. *Lipids* **27**, 219–226.
- Murai T. & Andrews J.W. (1974) Interactions of dietary  $\alpha$ -tocopherol, oxidized menhaden oil and ethoxyquin on channel catfish (*Ictalurus punctatus*). *Journal of Nutrition* **104**, 1416–1431.
- Osthoff G., Hugo A., Bouwman H., Buss P., Govender D., Joubert C.C. & Swarts J.C. (2010) Comparison of the lipid properties of captive, healthy wild, and pancreatitis-affected wild Nile crocodiles (*Crocodylus niloticus*). *Comparative Biochemistry and Physiology, Part A* **155**, 64–69.

- Petrick F.O. (1975) Anatomy of the swimbladders of seven families of Transvaal freshwater fishes. *Journal of the Limnological Society of Southern Africa* **1**, 17–22.
- Post G.W. (1993) Nutrition and nutritional diseases of salmonids. In: *Fish Medicine* (ed. by M.K. Stoskopf), pp. 343–358. W.B. Saunders Company, Harcourt Brace Jovanovich, Inc., Philadelphia.
- Roberts R.J. & Agius C. (2008) Pan-steatitis in farmed northern bluefin tuna, *Thunnus thynnus* (L.), in the eastern Adriatic. *Journal of Fish Diseases* **31**, 83–88.
- Roberts R.J., Richards R.H. & Bullock A.M. (1979) Pansteatitis in rainbow trout *Salmo gairdneri* Richardson: a clinical and histopathological study. *Journal of Fish Diseases* **2**, 85–92.
- Stewart L.J. (1993) Nutrition of koi, carp, and goldfish. In: *Fish Medicine* (ed. by M.K. Stoskopf), pp. 461–470. W.B. Saunders Company, Harcourt Brace Jovanovich, Inc., Philadelphia.

Received: 18 September 2010

Revision received: 16 January 2011

Accepted 24 January 2011



# Prevalence of pansteatitis in African sharptooth catfish, *Clarias gariepinus* (Burchell), in the Kruger National Park, South Africa

**Author:**K. David A. Huchzermeyer<sup>1,2</sup>**Affiliations:**<sup>1</sup>Sterkspruit Veterinary Clinic, Lydenburg, South Africa<sup>2</sup>Department of Paraclinical Sciences, University of Pretoria, South Africa**Correspondence to:**

David Huchzermeyer

**Email:**

aquavet@telkomsa.net

**Postal address:**

PO Box 951, Lydenburg 1120, South Africa

**Dates:**

Received: 19 Jan. 2012

Accepted: 08 Aug. 2012

Published: [To be released]

**How to cite this article:**Huchzermeyer, K.D.A., 2012, 'Prevalence of pansteatitis in African sharptooth catfish, *Clarias gariepinus* (Burchell), in the Kruger National Park, South Africa', *Journal of the South African Veterinary Association* 83(1), Art. #916, 9 pages. <http://dx.doi.org/10.4102/jsava.v83i1.916>

© 2012. The Authors.  
Licensee: AOSIS  
OpenJournals. This work  
is licensed under the  
Creative Commons  
Attribution License.

Pansteatitis was confirmed in sharptooth catfish, *Clarias gariepinus* (Burchell), from three main locations within the Kruger National Park (KNP); the Olifants River Gorge, Engelhard Dam on the Letaba River and from the Sabie River in the Sabiepoort. An increasing prevalence of pansteatitis was observed in catfish during repeated samplings from the Olifants Gorge from 2009 to 2011 and co-existence of old and recent lesions indicated on-going incitement of pansteatitis. Only a low prevalence of pansteatitis was observed in catfish sampled from the Olifants River upstream of the Gorge in the KNP and no pansteatitis was observed in catfish sampled from a rain-filled dam not connected to the Olifants River. Common to both the Olifants Gorge and the Sabiepoort is the damming of the rivers in Mozambique to form lakes Massingir and Corumana respectively. Anthropogenic activities resulting in potential pollution of the rivers differ greatly between these two catchments, providing argument against a primary pollution-related aetiology of the pansteatitis found at these two sites. Compared with other sites, analysis of stomach contents of catfish from the Olifants Gorge and the Sabiepoort strongly suggested that consumption of a predominantly fish diet was associated with the development of pansteatitis in these fish. In a farmed population of catfish used as positive control, development of pansteatitis could be ascribed to consumption of rancid fish waste from a trout slaughterhouse. In the Olifants Gorge, alien invasive silver carp, *Hypophthalmichthys molitrix* (Valenciennes), seasonally migrate upstream out of Lake Massingir to spawn. This schooling species is an obligate phytoplankton feeder with consequent high levels of adipose tissue n-3 polyunsaturated fatty acids. In the Olifants Gorge, at least, this may explain seasonal exposure to levels of polyunsaturated fats in the diets of catfish and crocodiles to which these animals are not adapted. The possible roles of diet, membrane lipid composition and metabolic rate of fish, sediment pollution and seasonal drop in environmental temperature in the pathogenesis of pansteatitis in the catfish are discussed. Further studies are needed to verify some of these speculations.

## Introduction

Much attention has been focused on the state of the Olifants River in Mpumalanga Province, South Africa. From its origins on the Highveld plateau the river flows eastwards down the escarpment traversing the Kruger National Park (KNP) and Mozambique before discharging into the Indian Ocean. The catchment has been heavily impacted by human activity including mining, coal-fired electricity generation, industrial and urban wastewater discharges, agricultural practices and water impoundments. As a result, the Olifants River is regarded as one of the most threatened aquatic ecosystems in Mpumalanga (Ashton 2010; De Villiers & Mkwelo 2009; Heath, Coleman & Engelbrecht 2010). Since 2003, increasing Nile crocodile, *Crocodylus niloticus* Laurenti, mortalities in Lake Loskop, situated in the upper Olifants catchment, have coincided with periodic mass fish mortalities (Botha, Van Hoven & Guillette 2011). In the KNP, an estimated 180 large crocodiles died in the Olifants River Gorge during the winter of 2008 following the raising of the sluice gates of the Lake Massingir dam wall in Mozambique during 2007 (Ferreira & Pienaar 2011; Huchzermeyer *et al.* 2011). Fewer deaths were recorded in the subsequent two winters. South African National Parks (SANParks) veterinarians established the cause of death as pansteatitis.

Steatitis, the inflammation associated with fat cell necrosis, has been described from many species of warm and cold-blooded animals, including fish. This nutritional disorder is found mainly in farmed and captive animals and rarely in free-living wild animals. Feeding of large amounts of unsaturated fat, particularly if rancid, or diets deficient in vitamin E are known to cause pansteatitis (Goodwin 2006; Herman & Kircheis 1985; Roberts & Agius 2008; Roberts, Richards & Bullock 1979). The condition has been reported in farmed crocodiles fed fish that was no longer fresh (Huchzermeyer 2003; Ladds *et al.* 1995). In Lake Loskop, large-scale fish

mortality was observed as a result of acid mine drainage and may explain the development of pansteatitis in the resident crocodiles after the fish die-off (J. Myburgh and co-workers, University of Pretoria, pers. comm., 2009). It has been proposed that bio-accumulation, via algae, of aluminium and iron within body fat was the cause of yellow discolouration of fat of Mozambique tilapia, *Oreochromis mossambicus* (Peters), in Lake Loskop and that this bio-accumulation may have provided a trigger for development of pansteatitis in higher trophic level predators (Oberholster *et al.* 2011). In the Olifants Gorge, significant overt fish mortality has seldom been observed, with the exception of a single localised event affecting almost exclusively large African sharp-tooth catfish, *Clarias gariepinus* (Burchell), during the winter of 2009 (D. Pienaar & D. Govender, SANParks, Skukuza, pers. comm., 2009). During the 2011 aerial crocodile survey by SANParks, however, three large dead catfish were observed in the Olifants Gorge and in Lake Massingir (D. Pienaar, SANParks, Skukuza, pers. comm., 2011) suggesting that low level mortality was occurring.

There are numerous references in the literature linking lipid peroxidation to pollutants in the aquatic environment (Bainy *et al.* 1996; Baker, Martin & Davies 1997; Kelly *et al.* 1998; Kibanova, Nieto-Camacho & Cervini-Silva 2009), but little has been published linking these effects to pansteatitis, which is regarded as a nutritional disease. Because of a possible link between pansteatitis in catfish and crocodiles, the study of pansteatitis in catfish was initiated as part of the multidisciplinary investigation into the crocodile mortality in the KNP under the auspices of the Consortium for the Restoration of the Olifants Catchment (CROC).

## Materials and methods

Sharp-tooth catfish were collected during the winter and summer months from various localities within and outside the KNP, including two negative reference populations, namely Reënvoël Dam (23°58'37.2"S 31°19'38.4"E) that has its entire catchment within the KNP, and Van Ryssen Dam (24°00'13.6"S 31°05'36.9"E) at the FOSKOR phosphate mine in Phalaborwa just west of the KNP. A farmed population of sharp-tooth catfish at Lunsklip Fisheries near Lydenburg, Mpumalanga, served as a positive reference population. Subject to catch success, up to 20 fish were collected on each sampling occasion (Table 1). From 2009, fish were sampled repeatedly from the Olifants Gorge. This section of river stretches eastwards from the confluence of the Olifants and Letaba rivers (23°59'21.8"S 31°49'35.6"E), through a 9 km long gorge in the Lebombo Mountains, to where it enters Lake Massingir on the Mozambique border (23°57'48"S 31°52'97"E). Further samplings took place from the Olifants River at Mamba Weir (24°03'32"S 31°14'14"E), where the Olifants River enters the western boundary of the KNP, from Engelhard Dam (23°50'19"S 31°28'28"E) on the Letaba River, and further south in the KNP from the Sabiepoort (25°10'25.41"S 32°02'23.42"E), where the Sabie River enters Lake Corumana on the Mozambique border. In the north of the KNP, fish were sampled from the Levuvhu River (22°25'51.0"S 31°18'04.4"E) and on the southern boundary of

the Park from the Crocodile River (25°23'57.1"S 31°57'29.9"E). Fish were caught by baited hook and line and by netting. During the June 2011 sampling in the Olifants Gorge, 21 tiger fish, *Hydrocynus vittatus* Castelnau, were also sampled from the confluence of the Olifants and Letaba rivers.

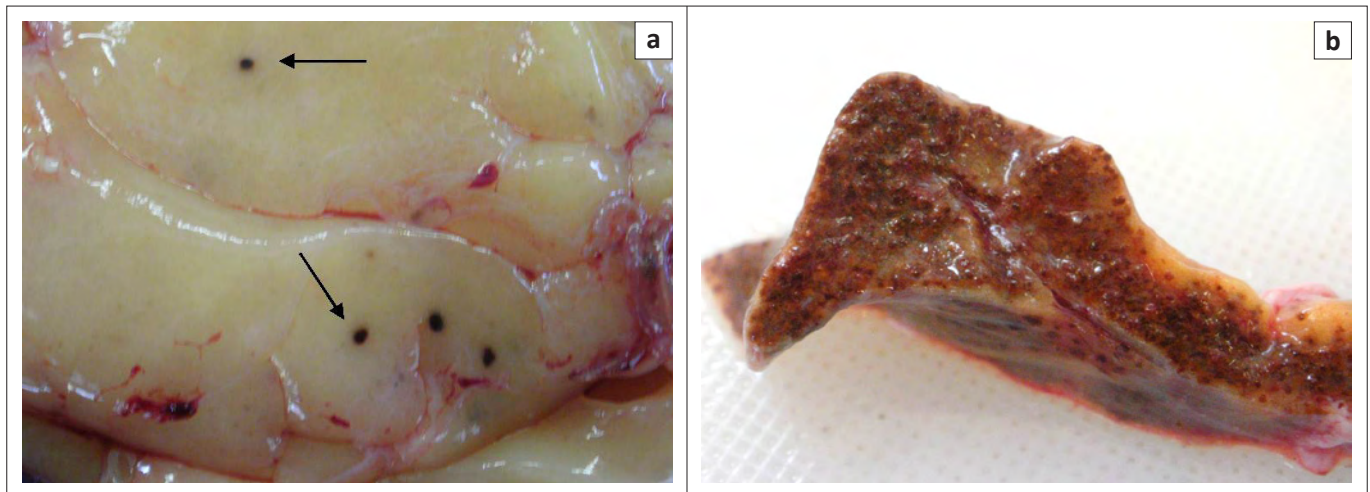
All fish were anaesthetised using benzocaine hydrochloride (Kyron Laboratories, Johannesburg, South Africa) and subjected to body mass and length measurements, body condition scoring and sexing. Body condition was scored on a scale ranging from 1 (*emaciated*) to 5 (*obese*). Blood was collected from the vessels ventral to the vertebral column in the tail region. Each fish was euthanized with an overdose of benzocaine hydrochloride and a detailed autopsy was performed. Positive pansteatitis cases were identified by presence of grossly observable lesions in the fat. Tissue specimens from organs and abdominal and subcutaneous adipose tissues were collected in 10% buffered formalin from all sampled fish and subjected to standard histological techniques. All tissue sections were stained with haematoxylin and eosin and examined by light microscopy. Selected sections were stained with Gomori's Aldehyde Fuchsin to demonstrate presence of ceroid within the adipose tissues and in macrophages associated with necrotic lesions in the fat. The stomach contents of each fish were examined and recorded. The sagittal otoliths were removed from all sampled catfish, embedded in resin and sectioned transversely at 0.4 mm thickness by microtome according to the method of Weyl and Booth (2008). Mounted sections were examined under the light microscope and growth zones were counted for age determination.

## Ethical considerations

The project was approved by the Animal Use and Care Committee of the University of Pretoria under Protocol VO13/10.

## Results

During the period from June 2009 to June 2011, 265 specimens of *C. gariepinus* were examined during 15 sampling episodes from the various localities within and outside of KNP, including the positive and negative control populations (Table 1). Pansteatitis was observed in mesenteric adipose tissues of fish from the Olifants Gorge, Sabiepoort, Engelhard Dam, Mamba Weir and Lunsklip Fisheries and differed little except in degree of severity. Gross lesions consisted of small focally disseminated to coalescing granulomata up to 5 mm in diameter characterised by a brown colour, sometimes with an orange-coloured centre (Figure 1). Affected fat in severe cases had a rubbery consistency. In the adipose tissues, gross lesions of pansteatitis were confirmed histologically by the presence of foci of adipocyte necrosis with extracellular lipopigment surrounded by an intense infiltration of ceroid-containing macrophages. The detailed pathology and histopathology of the organs and the specific lesions associated with fat necrosis in fish from the Olifants Gorge have been published elsewhere (Huchzermeyer *et al.* 2011). Pansteatitis was not found in the 21 tiger fish collected from the Olifants Gorge during June 2011.



**FIGURE 1:** (a) Early pansteatitis lesion in mesenteric fat of a sharptooth catfish sampled from the Olifants Gorge during July 2010. Note the sharply circumscribed foci of fat cell necrosis and associated lipopigment deposition imparting the characteristic brown colour (arrow). (b) Advanced pansteatitis of mesenteric fat of a sharptooth catfish sampled from Engelhard Dam during July 2010. Note the diffuse brown granular appearance of the fat and virtual absence of normal-appearing fat.

**TABLE 1:** Prevalence of gross pansteatitis lesions and fish stomach content, mean body mass, and median body condition and mesenteric fat scores in populations of sharptooth catfish sampled from June 2009 to June 2011.

Site	n	Date	% with pansteatitis	% with fish in stomach content	Body mass (grams)		Body condition score (scale 1–5)		Mesenteric fat score (scale 1–5)	
					Mean	Range	Median	Range	Median	Range
G-OL	9	June 2009	33	33	2362	840–4760	3	3–5	2	1–5
G-M	14	Aug. 2009	43	58	3087	1280–5340	3	2–4	2.25	0.5–4
G-OL	21	Nov. 2009	29	43	2679	320–9300	4	3–5	4	2–5
G-OL	25	July 2010	60	20	2730	520–6560	3	2–4	2	1–4
G-OL	22	Jan. 2011	55	82	2570	940–5620	3	2–4	1	0–3
G-OL	21	June 2011	67	57	3220	640–10 000	3	1–4	3	0.5–4
MW	20	July 2010	5	15	1453	580–4600	3	1–4	1	0–3
EHD	21	July 2010	10	33	2175	680–6700	2	1–3.5	1	0–3.5
SP	11	July 2010	45	82	3020	880–7740	3	3–4	2	0–2.5
LKF	21	Nov. 2009	66	38	6893	2820–8680	3	1.5–4	2	0.5–4
RVD	23	Nov. 2009	0	13	4419	2280–8820	3	1–4	2	1–3
RVD	13	Jan. 2011	0	31	1660	540–5860	4	2–4	0.5	0–2
VRD	10	Jan. 2011	0	90	4300	960–6340	3	2–4	3	1–4
LR	14	June 2011	0	7	3174	480–1250	3	1–4	1.5	0.5–4
CR	20	June 2011	0	0	1689	710–4690	3	2–4	0.75	0–2

G-OL, Gorge Olifants Letaba confluence; G-M, Gorge Mozambique border; MW, Mamba Weir; EHD, Engelhard Dam; SP, Sabiepoort; LKF, Lunsklip Fisheries; RVD, Reënvoël Dam; VRD, Van Ryssen Dam; LR, Levuvhu River; CR, Crocodile River.

Mesenteric fat reserves varied from sparse to prominent in catfish represented in samplings from most sites but mesenteric fat stores of most catfish from the Olifants Gorge were larger than those of catfish sampled from other localities in KNP. Catfish from Reënvoël Dam, Engelhard Dam, the Crocodile River and Mamba Weir were leaner. Most fish from Lunsklip Fisheries had prominent mesenteric fat reserves.

Catfish sampled from the Olifants Gorge and from Reënvoël Dam ranged in age from 1 to 19 years. In the Olifants Gorge, pansteatitis was detected in catfish ranging from 3 to 19 years with both sexes equally affected. The main focus of the study was on the Olifants River Gorge, where an increase in prevalence of pansteatitis in sampled catfish was detected since structured sampling began in 2009 (Figure 2). Presence of gross lesions was used to determine prevalence of pansteatitis (Figures 2 and 3). Microscopic examination of histological sections of fat from sampled fish confirmed the macroscopic

diagnosis of pansteatitis (Figure 4). Co-existence of coalescing granulomata, scarring of the adipose tissues, and more recent lesions characterised by small foci of brown discolouration of the fat suggested on-going incitement of fat necrosis and attempts at healing in catfish from the Olifants Gorge.

Catfish from Lunsklip Fisheries were fed almost exclusively on untreated waste, rich in polyunsaturated fat, from the trout slaughterhouse on this farm. This waste, consisting largely of fat rich innards, was dumped into the catfish pond where it decomposed until consumed by the fish. These fish showed a high prevalence of pansteatitis as expected under such nutritional conditions, and provided the study with a positive reference population (Table 1). In the Olifants Gorge, analysis of stomach contents showed that catfish fed predominantly on fish as well as insects and small reptiles that had been washed into the river during flood conditions. On the Mozambique border where the Olifants River flows into Lake Massingir and where the sand-bottomed pools



and rapids have been inundated with clay deposits, sampled catfish appeared to be feeding off the surface of the clay, and ingesta consisted of algal detritus and clay. In the Sabie River, the Sabiepoort has also been partially inundated with clay sediments as a result of Lake Corumana in Mozambique damming this gorge. A single sampling revealed a similar prevalence of pansteatitis in catfish to that found in the Olifants Gorge (Figure 2). Several of these fish appeared to have been feeding off a dead crocodile with pansteatitis. In the Olifants Gorge both crocodiles and catfish have been observed feeding off the carcasses of dead crocodiles (D. Pienaar, SANParks, Skukuza, pers. comm., 2009). Fish

from Mamba Weir were lean and had fed heavily on the fruit of sycamore fig trees, *Ficus sycomorus*, which overhang the river embankment. Prevalence of pansteatitis was significantly lower than that in the Olifants Gorge (Figure 2). Fish sampled from Van Ryssen Dam showed no lesions of pansteatitis (Table 1). They appeared to have fed exclusively on Mozambique tilapia. The stomachs of the majority of fish sampled from the Crocodile River during June 2011 were distended with ingested filamentous algae. Microscopic examination of fluid expressed from stomach contents revealed large numbers of diatoms together with filamentous algae. Fish sampled from the Levuvhu River during June 2011

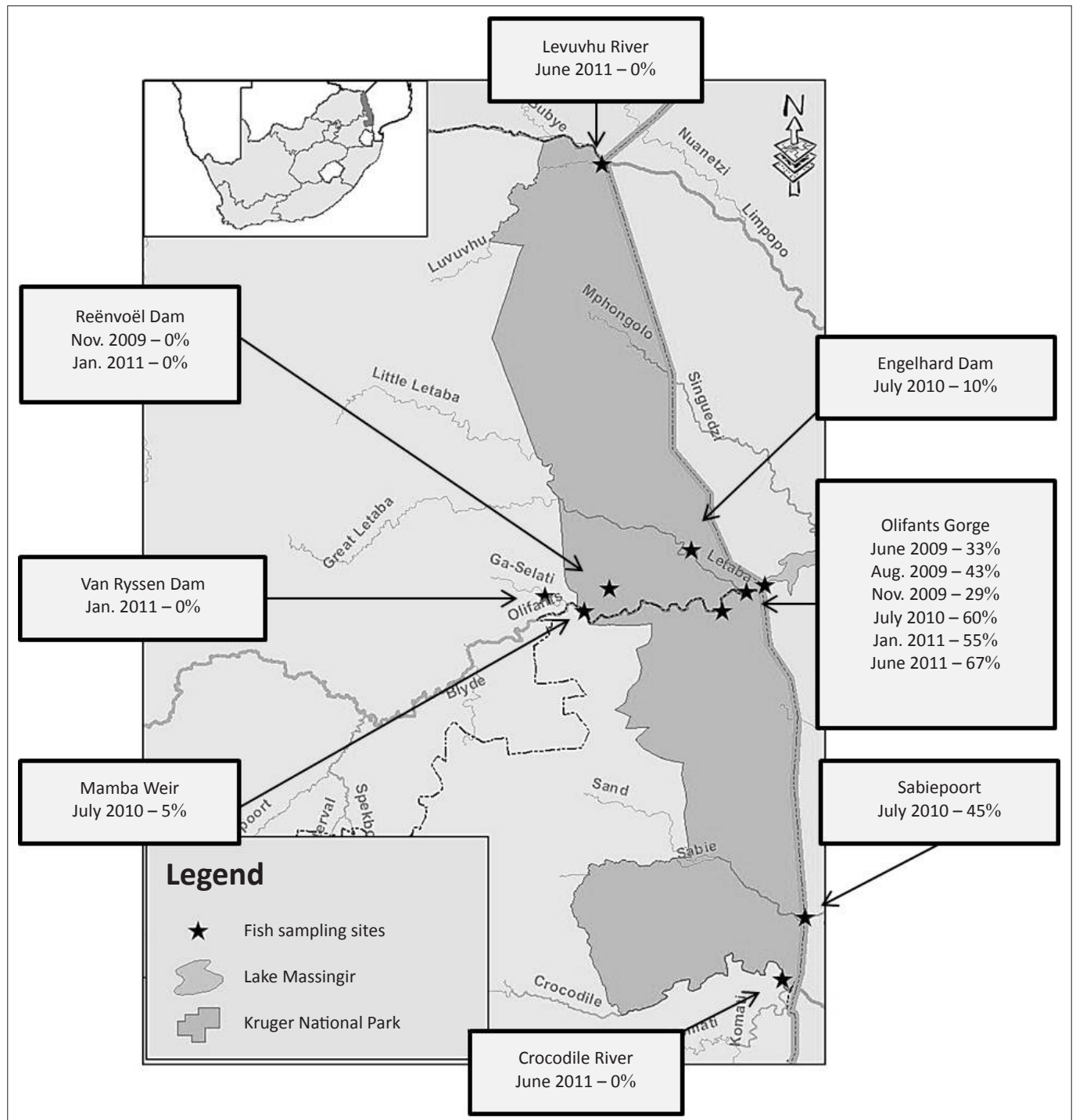
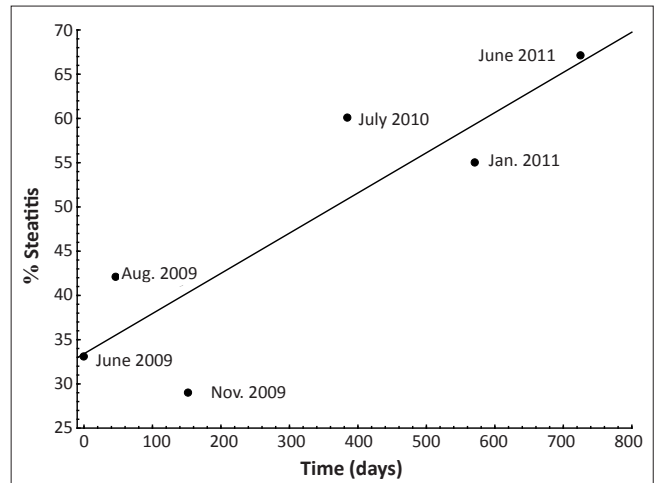


FIGURE 2: Prevalence of pansteatitis in sharp-toothed catfish sampled from various localities in the Kruger National Park from 2009 to 2011.

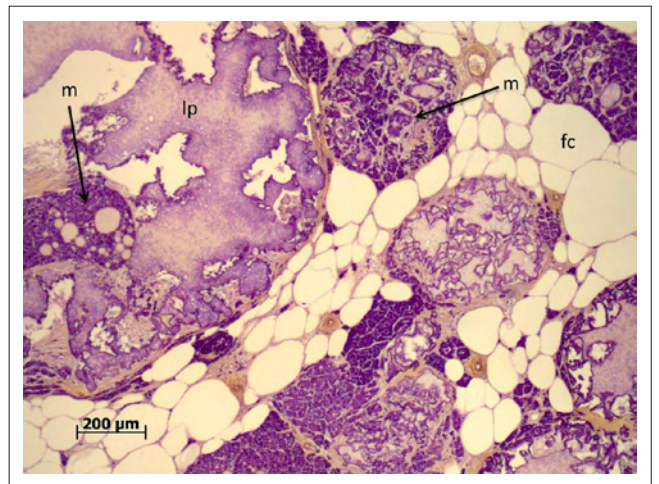
had been feeding off algae and sycamore figs. No pansteatitis was detected in fish from the Crocodile and Levuvhu rivers (Table 1). Fish remnants, vegetation, invertebrate and algal detritus were equally represented in stomach contents of fish from Reënvoël Dam. Gross steatitis was not detected (Table 1). Histological examination, however, revealed small numbers of lipopigment-containing macrophages within the mesenteric adipose tissue in one fish (3.6% of sampled fish [ $n = 41$ ]) from Reënvoël Dam. The associated small focus of lipopigment-containing necrotic cell remnants was in the proximity of a large parasitic cyst. Stomach contents of fish from Engelhard Dam included fish remnants, plant and algal detritus. Pansteatitis prevalence was 10% ( $n = 21$ ) (Figure 2).

## Discussion

Poikilothermic animals such as fish require inclusion of highly polyunsaturated fatty acids within biological membranes to maintain membrane fluidity necessary for normal metabolism at the relatively colder temperatures at which these animals function (Hulbert 2003). In rainbow trout, *Oncorhynchus mykiss* (Walbaum), it has been shown that the relative proportions of polyunsaturated fatty acids in membranes change with cold acclimation, with particularly the n-3 fatty acids increasing (Hazel 1979). The greater the degree of unsaturation of fatty acids, the more vulnerable they are to oxidative breakdown and intact antioxidant protective mechanisms, particularly presence of adequate vitamin E, are required to prevent *in vivo* autoxidation in bio-membranes (Niki *et al.* 1989). Oxidative stress associated with intense intake of polyunsaturated fat in fresh fish consumed over a short period, or due to ingestion of rancid fish remains, is likely to deplete vitamin E reserves and to result in pansteatitis in catfish as it is known to do in other animals. Vitamin E levels in rainbow trout liver were found to be inversely proportional to dietary level of lipid unsaturation, showing a higher utilisation of vitamin E associated with unsaturated lipid intake, and feeding of such diets may induce apparent vitamin E deficiency symptoms (Watanabe *et al.* 1981). Under conditions of dietary oxidant overload, depletion of vitamin E has also been shown to occur in muscle, liver and plasma of sharptooth catfish (Baker & Davies 1996, 1997). Where vitamin E is insufficient to provide adequate protection against the peroxidation of unsaturated lipids, necrosis and inflammation of the adipose tissues ensues, giving rise to the clinical picture of pansteatitis. Steatitis is the lesion that follows on an oxidative insult to the adipose tissues and the author has demonstrated (unpublished data) that in catfish such lesions can persist for protracted periods of time. From field measurements done by the author (unpublished data) of serum vitamin E values in catfish with pansteatitis in the Olifants Gorge, it would appear that many but not all of these fish had normal serum vitamin E values at the time of sampling, indicating that the oxidative stress exposure was not continuous. Where oxidation of lipids is not currently taking place in the adipose tissues, vitamin E levels may return to normal in animals chronically affected by pansteatitis.



**FIGURE 3:** Gross pansteatitis prevalence as percentage of sampled sharptooth catfish from the Olifants Gorge during the period June 2009 to June 2011.



Gomori's Aldehyde Fuchsin used to stain ceroid.

lp, lipopigment; m, the intense ceroid containing macrophage reaction; fc, fat cells.

**FIGURE 4:** Microscopic appearance of granulomata associated with pansteatitis in mesenteric fat of a sharptooth catfish sampled from the Olifants Gorge during November 2009. Note the coalescing fat breakdown product and lipopigment, the intense ceroid containing macrophage reaction and fat cells.

Pansteatitis was confirmed in catfish from three main locations within the KNP: the Olifants Gorge and lower Letaba River at the confluence with the Olifants River, Engelhard Dam on the Letaba River upstream of the Olifants-Letaba confluence, and the Sabiepoort. Pansteatitis in crocodiles was first reported from the Olifants Gorge when large numbers of crocodiles died in this section of the Olifants River in the winter of 2008 (Ferreira & Pienaar 2011). During subsequent samplings from 2009 to 2011 an increasing prevalence of pansteatitis was observed in sharptooth catfish in the Olifants River gorge, yet only a low prevalence was found in catfish inhabiting the Olifants River upstream of the gorge, with none in catfish from a rain-filled dam not connected to the Olifants River. Common to both the Olifants Gorge and the Sabiepoort is the damming of the rivers in Mozambique to form lakes Massingir and Corumana respectively. The inlets of both lakes extend westwards back into the KNP, flooding the respective gorges where these rivers previously traversed the Lebombo Mountains as fast flowing rapids. During 2009, SANParks staff found several dead crocodiles in the Sabie River in the

vicinity of the Sabiepoort with pansteatitis also found to be the cause of death (D. Govender, SANParks, Skukuza, South Africa, pers. comm., 2010). A single sampling of catfish from the Sabiepoort, where the Sabie River enters Lake Corumana on the Mozambique border, revealed pansteatitis prevalence similar to that found in the Olifants Gorge, suggesting that the aquatic environment in the two rivers is similar. As in the case of Lake Massingir, Lake Corumana supports a freshwater fishery in Mozambique. Catfish with pansteatitis may have migrated from the Olifants Gorge upstream to Engelhard Dam and this may be one explanation for the presence of pansteatitis-affected fish at this site, but the Sabiepoort has an entirely separate catchment. The anthropogenic activities resulting in potential pollution of the rivers differ greatly between these two catchments, providing argument against primary pollution-related aetiology of pansteatitis at these two sites.

Crocodile mortalities have declined in the Olifants Gorge since the mass die-off of 2008 but co-existence of old and recent lesions in sampled catfish point to an on-going incitement of pansteatitis. Analysis of catfish stomach contents in KNP strongly suggested that consumption of a predominantly fish diet within the Olifants Gorge was associated with the high prevalence of pansteatitis in catfish in this location. Catfish are primarily omnivorous benthic scavengers with wide dietary options but may form schools that actively hunt fish (Skelton 2001) and are known to feed on fish elsewhere (Spataru, Viveen & Gophen 1987). Under natural circumstances, a diet of fish may be well tolerated by sharptooth catfish (Uys 1988), but an intense intake of polyunsaturated fat over a short period is likely to deplete vitamin E reserves and to result in pansteatitis, especially if combined with other oxidative stressors. The Van Ryssen Dam collects treated wastewater from a phosphate mine, and fish from this dam showed no signs of pansteatitis despite a high prevalence of Mozambique tilapia in the stomach contents. The captive population of catfish of Lunsklip Fisheries was fed an excess of fish waste that was observed rotting in the water before being consumed. Under such conditions, pansteatitis could be expected as a result of rancidity of ingested fats leading to oxidative stress and depletion of vitamin E stores.

Tiger fish included in the preliminary samplings of fish from the Olifants Gorge during the winter of 2008, soon after the initial crocodile deaths were discovered, did not have pansteatitis. This finding was repeated during a sampling in June 2011 at a time when prevalence of pansteatitis in catfish from the gorge was high. Tiger fish, being obligate piscivorous predators, possibly evolved more effective antioxidant mechanisms to deal with a higher polyunsaturated fat intake. Being near the top of the aquatic food chain, they would be expected to develop pansteatitis if an inciting agent was bio-accumulated via the fish they kill and eat, or was assimilated from the water. The development of pansteatitis in sharptooth catfish must therefore be linked rather to their benthic scavenging habits or to a change in food source and/or other simultaneous environmental factors to which they are not adequately adapted.

Pansteatitis in free ranging wild animals has rarely been reported except from aquatic birds. Recently an outbreak of steatitis in wild egrets and herons was reported from a reservoir in Japan (Neagari *et al.* 2011). However, steatitis has been reported in wild marine fish, the common dab, *Limanda limanda* (L.), with a suspected pollution-related aetiology (Begg, Bruno & McVicar 2000). Concern about the KNP Olifants River crocodile demise stems from the possible influence of anthropogenic effects on the Olifants River catchment, which covers some 74 500 km<sup>2</sup> and is home to about 8% of South Africa's population (Ashton 2010). Approximately 90% of the country's saleable coal is mined in this catchment and is used to generate 55% of South Africa's electricity, resulting in serious pollution concerns (Coetzee, Du Preez & Van Vuuren 2002; De Villiers & Mkwelo 2009). The area contains numerous dams, including 38 major dams, as well as the country's second largest irrigation scheme (Anon 2001). In addition, large areas of the landscape have been changed by afforestation and agriculture. Huge increases in urban wastewater discharge and on-going high nutrient run-off from agricultural practices raise added concerns of eutrophication (Heath *et al.* 2010). A large phosphate mine is situated near the town of Phalaborwa just east of the KNP near the western entry point of the Olifants River into the KNP. For a number of years prior to 2004, and once in 2008, abnormally high phosphate levels were recorded in the Olifants River within the KNP (J. Venter, SANParks, Skukuza, South Africa, pers. comm., 2012). These were ascribed to the discharge of tailings from the phosphate mine into the Selati River, a tributary of the Olifants River, and to municipal sewerage discharges from the town of Phalaborwa. Such phosphate discharges would have contributed to the inorganic nutrient load trapped in sediments of Lake Massingir. Dissolved phosphate is often the limiting nutrient governing phytoplankton growth in fresh water and phosphates released from sediments will continue to drive the nutrient cycle of the lake. This seasonal stimulus for phytoplankton growth may have contributed to an increasing biomass of fish in the lake.

Contamination of surface waters in the catchment, with accumulation of heavy metals within sediments through adsorption and precipitation processes, has long been recognised as a serious pollution concern, and site specific bio-accumulation of metals has been demonstrated in sharptooth catfish in the upper catchment of the Olifants River (Coetzee *et al.* 2002). Oberholster *et al.* (2011) have suggested that aluminium and iron bio-accumulation by Mozambique tilapia in Lake Loskop may have induced the yellow fat observed from fish at that site. Baker *et al.* (1997) have, however, proposed that sharptooth catfish efficiently regulate iron status and are able to prevent tissue assimilation of dietary iron intake. This is an important adaptation to their benthic habitat, in which they are likely to consume sediment burrowing organisms with inadvertent ingestion of sediment. Large dams in the catchment act as traps for sediments, nitrates, phosphates and heavy metals and are regarded as the epicentre of recent mortalities of fish and crocodiles (Heath *et al.* 2010). Over time, changing water quality may cause sediment-bound contaminants to become bio-available and result in bio-accumulation in fish tissues.



Redox cycling of iron is known to be an initiator of lipid peroxidation (Baker & Davies 1997; Demopoulos 1973; Minotti & Aust 1992; Tappel 1973) and depletion of tissue vitamin E levels by high dietary iron intake may render polyunsaturated fats in the tissues of the fish vulnerable to peroxidation (Baker & Davies 1997). In another study (Huchzermeyer *et al.* 2011), pansteatitis-affected catfish caught during September of 2008 and from January to November of 2009 in the lower Letaba and Olifants Rivers were shown by special histological staining to have accumulated large amounts of iron in the form of haemosiderin in the melanomacrophages of the liver, spleen, ovary and to a lesser extent in the kidney. However, haemosiderin was not detected in the intense macrophage reaction associated with pansteatitis in the adipose tissues. Blood smears of many of these fish showed an abundance of immature erythrocytes as well as irregular erythrocyte shapes as described in cases of vitamin E deficiency in fish (Murai & Andrews 1974; Post 1993; Smith 1979) and increased erythrocyte turnover may have been the source for the increased haemosiderin carried by macrophages. Stomach contents of fish caught in the gorge at the confluence yielded mainly remnants of large fish, whereas specimens caught directly over the silt deposits on the Mozambique border only contained detritus and silt. These findings suggested bio-accumulated iron as an additional oxidative trigger possibly ingested in polluted sediment. As stated before, however, catfish are able to prevent tissue assimilation of dietary iron (Baker *et al.* 1997). This and the absence of haemosiderin in macrophages associated with pansteatitis in the adipose tissues of catfish from the Olifants Gorge thus suggest that the role of iron in the aetiology of pansteatitis in catfish in the Olifants Gorge remains speculative.

As a consequence of raising the dam of Lake Massingir, the heavy silt load of the Olifants River has been deposited in flooded parts of the narrow gorge extending into the KNP. The now inundated sand-bottomed pools between previously fast flowing rapids once formed a favoured habitat for large crocodiles. This altered habitat in the Olifants Gorge may have favoured access to certain fish species not normally consumed in large numbers by crocodiles and catfish. Such species may provide higher levels of polyunsaturated fatty acids than those to which the animals are adapted. An increase in dietary polyunsaturated fat intake has been reported to result in pansteatitis in various animals. Wallach and Hoessle (1968) concluded that a change in diet from smelt (6.7% fat) to mackerel (29.9% fat) was the precipitating cause of pansteatitis in captive American alligators, *Alligator mississippiensis* (Daudin). Goodwin (2006) stressed the dangers of using diets high in fish oils for inappropriate species, and a change from Baltic and Mediterranean clupeids to Moroccan Atlantic pilchards was suspected to have been the cause of pansteatitis in northern bluefin tuna, *Thunnus thynnus* (L.), reported by Roberts and Agius (2008). Similarly pansteatitis could be induced in cats by feeding an oil-rich fish-based diet (Fytianou *et al.* 2006).

Silver carp, *Hypophthalmichthys molitrix* (Valenciennes), an alien invasive schooling species from East Asia (Kolar *et al.* 2005), were introduced into Mozambique from Cuba and

also escaped into the Olifants River from South Africa. They are known to occur in Lake Massingir (Skelton 2001) and have been observed on occasion in the Olifants River in large numbers (J. Venter, SANParks, Skukuza, South Africa, pers. comm., 2012). This fish is a specialised plankton feeder that by preference feeds off phytoplankton and is an important consumer of cyanobacterial blooms (Kolar *et al.* 2005), a niche no indigenous South African fish species occupies (P. Skelton, South African Institute of Aquatic Biodiversity, Grahamstown, South Africa, pers. comm., 2012). Such blooms have been observed near the inlet to Lake Massingir (D. Pienaar, SANParks, Skukuza, South Africa, pers. comm., 2009). Phytoplankton naturally contains large quantities of  $\alpha$ -linolenic acid and other n-3 polyunsaturated fatty acids, in particular eicosapentaenoic acid C20:5n-3 (EPA) and docosahexaenoic acid C22:6n-3 (DHA) (Steffens 1997). Intake of these fatty acids is reflected in the adipose tissues of silver carp. In one study, these two fatty acids were found to constitute up to 5.28% and 3.41% of body fat triacylglycerols respectively (Buchtová & Ježek 2011). The n-6 and n-3 fatty acids derived from linoleic and  $\alpha$ -linolenic acids respectively are essential fatty acids that cannot be synthesised by animals (Steffens 1997). The relative abundance of these fatty acids in the diet of animals is reflected in the composition of their fat tissues (Hoffman & Prinsloo 1995; Steffens 1997). Compared with the fat of farmed crocodiles, a much higher intake of n-3 fatty acids was reflected in the fat of crocodiles in the Olifants Gorge (Osthoff *et al.* 2010). In another study, Huchzermeyer *et al.* (in press) demonstrated that the mesenteric fat of catfish with pansteatitis from the Olifants Gorge showed a similarly high inclusion of n-3 fatty acids, whereas mesenteric fat of healthy catfish from the same site reflected a lower inclusion of n-3 fatty acids.

Seasonal spawning migration of silver carp out of still water bodies into fast flowing rivers occurs over an 8–10 week period once rivers reach their peak summer flows (Kolar *et al.* 2005). During this time, the fish congregate in large numbers and become easy prey for crocodiles and catfish. In the Olifants Gorge this would occur from January to March, a time when fish in the river are difficult to monitor (A. Deacon, SANParks, Skukuza, South Africa, pers. comm., 2012). This may provide an explanation for intense dietary exposure to polyunsaturated fats that could have led to development of obesity and pansteatitis in crocodiles in the Olifants Gorge during the winter of 2008 and to a lesser extent during subsequent winters and to the on-going prevalence of pansteatitis in sharptooth catfish.

The only recorded catfish die-off in the Olifants Gorge was observed during the winter of 2009. The major crocodile die-offs in the Olifants Gorge occurred in 2008 and 2009 respectively and to a lesser extent in subsequent years, after the first really cold weather was experienced around the end of May each year. In many aquatic poikilotherms, especially fish, acclimation to colder water temperatures in winter involves an increase in membrane polyunsaturated fatty acids, in particular DHA (Hazel 1979; Hulbert 2003). Where antioxidant mechanisms have been depleted through oxidative stress, such as that produced by intense dietary

polyunsaturated fat intake, compromised bio-membranes in critical tissues might result in impairing adaptation to cold. In an unpublished study the author has demonstrated, however, that catfish severely affected by pansteatitis have survived protracted periods at water temperatures as low as 12 °C with no undue effect. This is well below the lowest water temperature experienced in the Olifants Gorge during winter. Pansteatitis is largely a foreign-body type reaction following on breakdown of fat cells, and presence of the lesion may imply either continuous or preceding oxidative stress. The effect of pansteatitis on cold tolerance may therefore differ depending on the time that has lapsed since the oxidative insult took place.

## Conclusion

The deaths of a large number of Nile crocodiles, a keystone species in aquatic conservation, in the Olifants Gorge in the KNP, has raised serious questions about the consequences of anthropogenic activity resulting in altered hydrodynamics and pollution in the catchment of the Olifants River. The objective of this study was to investigate the occurrence of pansteatitis in catfish inhabiting the same waters in the KNP where crocodiles had died of pansteatitis. Catfish were sampled repeatedly over a two-year period from the Olifants Gorge as well as from other sites in and around KNP. In the KNP, pansteatitis in both catfish and crocodiles has been observed in areas where the natural habitat has been drastically altered as a result of damming of rivers, and where the associated deposition of large clay deposits is a potential source of pollution. The increasing prevalence of pansteatitis in catfish in the Olifants Gorge, and the accumulation of lesions over time, points to periodic or seasonal episodes of dietary oxidative stress in these animals. Pansteatitis has also been identified in catfish at other sites in the KNP. The catchment areas feeding these sites differ from that of the Olifants River, providing argument against a primary pollution-related oxidative stress. To date, the only factor common to both the Olifants Gorge and the Sabiepoort, both epicentres of crocodile mortality, and both sites where pansteatitis has been identified in catfish, is the extension of man-made lake inlets into areas favoured by crocodiles. Increasing phosphate levels from anthropogenic activities upstream and in the catchment area of the Olifants River have led to an increase in phytoplankton blooms in Lake Massingir. Whereas this suggests that hydrodynamic change and pollution are the main drivers of this condition in the Olifants Gorge, the presence of large schools of the invasive alien silver carp, benefiting from the nutrient-rich raised water level of Lake Massingir, and known for its high content of n-3 polyunsaturated fatty acids, likely formed much of the seasonal diet of the catfish and crocodiles, either alive or as dead remains, and are thus proposed as the cause of the obesity and a pansteatitis-initiating factor in these animals. The role of bioaccumulation of iron from polluted sediments in initiating lipid autoxidation in catfish is speculative and needs further investigation. The effects on poikilotherm membranes and metabolic rate of a sudden seasonal drop

in environmental temperature may have contributed to the die-off of the pansteatitis-affected crocodiles, yet catfish survive cold even when severely affected by pansteatitis. It is not yet clear whether silver carp occur in Lake Corumana and further studies are needed to verify these proposals and answer outstanding questions.

## Acknowledgements

The assistance of SANParks and in particular Mr D.J. Pienaar, Drs D. Govender and A.R. Deacon as well as Mr J. Venter and the SANParks rangers and fishermen is gratefully acknowledged. Mss P. Shikwambana and N. Tyaqana, and Mr K. Deenadayalan of SANParks are thanked for help with the field laboratory. Messrs C., R., and N. Huchzermeyer are thanked for assistance with catching and handling fish and with field logistics. Mr J. Muller and IDEXX laboratory and Drs J. Myburgh and J. Steyl from the Department of Paraclinical Sciences at the Faculty of Veterinary Science, University of Pretoria are thanked for assistance with sampling. Dr Steyl is thanked for preparing histological sections and special stains. Mr T. Boikhutlo and Ms G. Taylor from the Department of Ichthyology and Fisheries Science, Rhodes University are thanked for preparing otolith sections. Prof. J. Lawrence is thanked for scientific and editorial comments. Dr P.A. Colly is thanked for help with sampling and logistic, editing and financial support. The assistance by Lunsklip Fisheries is gratefully acknowledged. Mr M. Lotter is thanked for preparing the map of the sampling sites. Colleagues from Sterkspruit Veterinary Clinic are thanked for standing in during the author's absence with fieldwork.

Financial assistance for this study was provided by WRC consultancy contract K8/948 and by the South African Veterinary Foundation. The project was approved by SANParks and the Animal Use and Care Committee of the University of Pretoria under Protocol VO13/10.

## Competing interests

The author declares that he has no financial or personal relationship(s) which may have inappropriately influenced him in writing this paper.

## References

- Anon, 2001, *State of the rivers report: Crocodile, Sabie-Sand and Olifants River systems, 2001*, viewed 2011, from [http://www.dwaf.gov.za/iwqs/rhp/state\\_of\\_rivers/crocsabieolif\\_01\\_toc.html](http://www.dwaf.gov.za/iwqs/rhp/state_of_rivers/crocsabieolif_01_toc.html)
- Ashton, P.J., 2010, 'The demise of the Nile crocodile (*Crocodylus niloticus*) as a keystone species for aquatic ecosystem conservation in South Africa: The case of the Olifants River', *Aquatic Conservation: Marine and Freshwater Ecosystems* 20, 489–493. <http://dx.doi.org/10.1002/aqc.1132>
- Baker, R.T.M. & Davies, S.J., 1996, 'Oxidative nutritional stress associated with feeding rancid oils to African sharptooth catfish, *Clarias gariepinus* (Burchell) and the protective role of  $\alpha$ -tocopherol', *Aquaculture Research* 27, 795–803. <http://dx.doi.org/10.1046/j.1365-2109.1996.t01-1-00814.x>
- Baker, R.T.M. & Davies, S.J., 1997, 'Muscle and hepatic fatty acid profiles and  $\alpha$ -tocopherol status in African catfish (*Clarias gariepinus*) given diets varying in oxidative state and vitamin E inclusion level', *Animal Science* 64, 187–195. <http://dx.doi.org/10.1017/S1357729800015708>
- Baker, R.T.M., Martin, P. & Davies, S.J., 1997, 'Ingestion of sub-lethal levels of iron sulphate by African catfish affects growth and tissue lipid peroxidation', *Aquatic Toxicology* 40, 51–61. [http://dx.doi.org/10.1016/S0166-445X\(97\)00047-7](http://dx.doi.org/10.1016/S0166-445X(97)00047-7)

- Bainy, A.C.D., Saito, E., Carvalho, P.S.M. & Junqueira, V.B.C., 1996, 'Oxidative stress in gill, erythrocytes, liver and kidney of Nile tilapia (*Oreochromis niloticus*) from a polluted site', *Aquatic Toxicology* 34, 151–162. [http://dx.doi.org/10.1016/0166-445X\(95\)00036-4](http://dx.doi.org/10.1016/0166-445X(95)00036-4)
- Begg, G.S., Bruno, D.W. & McVicar, A.H., 2000, 'The histopathology and ultrastructure of steatitis affecting common dab *Limanda limanda*', *Diseases of Aquatic Organisms* 41, 123–133. <http://dx.doi.org/10.3354/dao041123>, PMID:10918980
- Botha, H., Van Hoven, W. & Guillette, L.J., 2011, 'The decline of the Nile crocodile population in Loskop Dam, Olifants River, South Africa', *Water SA* 37, 103–108. <http://dx.doi.org/10.4314/wsa.v37i1.64109>
- Buchtová, H. & Ježek, F., 2011, 'A new look at the assessment of silver carp (*Hypophthalmichthys molitrix* Val.) as a food fish', *Czech Journal of Food Science* 29, 487–497.
- Coetzee, L., Du Preez, H.H. & Van Vuuren, J.H.J., 2002, 'Metal concentrations in *Clarias gariepinus* and *Labeo umbratus* from the Olifants and Klein Olifants River, Mpumalanga, South Africa: Zinc, copper, manganese, lead, chromium, nickel, aluminium and iron', *Water SA* 28, 443–448. <http://dx.doi.org/10.4314/wsa.v28i4.4917>
- Demopoulos, H.B., 1973, 'Control of free radicals in biologic systems', *Federation Proceedings* 32, 1903–1908. PMID:4718907
- De Villiers, S. & Mkwelo, S.T., 2009, 'Has monitoring failed the Olifants River, Mpumalanga?', *Water SA* 35, 671–676. <http://dx.doi.org/10.4314/wsa.v35i5.49193>
- Ferreira, S.M. & Pienaar, D., 2011, 'Degradation of the crocodile population of Kruger National Park, South Africa', *Aquatic Conservation: Marine and Freshwater Ecosystems* 21, 155–164. <http://dx.doi.org/10.1002/aqc.1175>
- Fytianou, A., Koutinas, A.F., Saridomichelakis, M.N. & Koutinas, C.K., 2006, 'Blood  $\alpha$ -tocopherol, selenium, and glutathione peroxidase changes and adipose tissue fatty acid changes in kittens with experimental steatitis (yellow fat disease): A comparative study between the domestic shorthaired and Siamese breed', *Biological Trace Element Research* 11, 131–143. <http://dx.doi.org/10.1385/BTER:112:2:131>
- Goodwin, A.E., 2006, 'Steatitis, fin loss and skin ulcers of channel catfish, *Ictalurus punctatus* (Rafinesque), fingerlings fed salmonid diets', *Journal of Fish Diseases* 29, 61–64. <http://dx.doi.org/10.1111/j.1365-2761.2005.00686.x>, PMID:16351699
- Hazel, J.R., 1979, 'Influence of thermal acclimation on membrane lipid composition of rainbow trout liver', *American Journal of Physiology – Regulatory, Integrative and Comparative Physiology* 236, 91–101.
- Heath, R., Coleman, T. & Engelbrecht, J., 2010, 'Water quality overview and literature review of the ecology of the Olifants River', *WRC Report No. TT452/10*.
- Herman, R.L. & Kircheis, F.W., 1985, 'Steatitis in Sunapee trout, *Salvelinus alpinus aquasasa* Girard', *Journal of Fish Diseases* 8, 237–239. <http://dx.doi.org/10.1111/j.1365-2761.1985.tb01219.x>
- Hoffman, L.C. & Prinsloo, J.F., 1995, 'Genetic and nutritional influence on the total lipid fatty acid profile of *Clarias gariepinus* muscle', *Aquatic Living Resources* 8, 415–421. <http://dx.doi.org/10.1051/alr:1995049>
- Huchzermeyer, F.W., 2003, *Crocodiles: Biology, husbandry and diseases*, CABI Publishing, Wallingford. <http://dx.doi.org/10.1079/9780851996561.0000>
- Huchzermeyer, K.D.A., Govender, D., Pienaar, D.J. & Deacon, A.R., 2011, 'Steatitis in wild sharp-toothed catfish, *Clarias gariepinus* (Burchell), in the Olifants and Lower Letaba Rivers in the Kruger National Park, South Africa', *Journal of Fish Diseases* 34, 389–398. <http://dx.doi.org/10.1111/j.1365-2761.2011.01267.x>, PMID:21675995
- Huchzermeyer, K.D.A., Osthoff, G., Hugo, A. & Govender, D., in press, 'Comparison of the lipid properties of healthy and pansteatitis-affected African sharp-toothed catfish, *Clarias gariepinus* (Burchell), and the role of diet in pansteatitis outbreaks in the Olifants River in the Kruger National Park, South Africa', *Journal of Fish Diseases*, (accepted for publication 31 August 2012).
- Hulbert, A.J., 2003, 'Life, death and membrane bilayers', *Journal of Experimental Biology* 206, 2303–2311. <http://dx.doi.org/10.1242/jeb.00399>, PMID:12796449
- Kelly, S.A., Havrilla, C.M., Brady, T.C., Abramo, K.H. & Levin, E.D., 1998, 'Oxidative stress in toxicology: Established mammalian and emerging piscine model systems', *Environmental Health Perspectives* 106, 375–384. <http://dx.doi.org/10.1289/ehp.98106375>, PMID:9637794
- Kibanova, D., Nieto-Camacho, A. & Cervini-Silva, J., 2009, 'Lipid peroxidation induced by expandable clay minerals', *Environmental Science and Technology* 43, 7550–7555. <http://dx.doi.org/10.1021/es9007917>
- Kolar, C.S., Chapman, D.C., Courtenay, Jr. W.R., Housel, C.M., Williams, J.D. & Jennings, D.P., 2005, 'Asian carps of the genus *Hypophthalmichthys* (Pisces, Cyprinidae) – A biological synopsis and environmental risk assessment', *Report to US Fish and Wildlife Service per Interagency Agreement 94400-3-0128*, viewed 2012, from <http://www.fws.gov/contaminants/OtherDocuments/ACBSRAFinalReport2005.pdf>
- Ladds, P.W., Mangunwirjo, H., Sebayang, D. & Daniels, P.W., 1995, 'Diseases in young farmed crocodiles in Irian Jaya', *Veterinary Record* 136, 121–124. <http://dx.doi.org/10.1136/vr.136.5.121>, PMID:7740731
- Minotti, G. & Aust, S.D., 1992, 'Redox cycling of iron and lipid peroxidation', *Lipids* 27, 219–226. <http://dx.doi.org/10.1007/BF02536182>, PMID:1326072
- Murai, T. & Andrews, J.W., 1974, 'Interactions of dietary  $\alpha$ -tocopherol, oxidized menhaden oil and ethoxyquin on channel catfish (*Ictalurus punctatus*)', *Journal of Nutrition* 104, 1416–1431. PMID:4423571
- Neagari, Y., Arij, S., Udagawa, M., Onuma, M., Odaya, Y., Kawasaki, T. et al., 2011, 'Steatitis in egrets and herons from Japan', *Journal of Wildlife Diseases* 47, 49–55. PMID:21629996
- Niki, E., Yamamoto, Y., Takahashi, M., Komuru, E. & Miyama, Y., 1989, 'Inhibition of oxidation of biomembranes by tocopherol', in A.T. Diplock, L.J. Machlin, L. Packer & W.A. Pryor (eds.), *Vitamin E: Biochemistry and health implications*, pp. 23–31, Annals of the New York Academy of Sciences 570.
- Oberholster, P.J., Myburgh, J.G., Ashton, P.J., Coetzee, J. & Botha, A.-M., 2011, 'Bioaccumulation of aluminium and iron in the food chain of Lake Loskop, South Africa', *Ecotoxicology and Environmental Safety* 75, 134–141. <http://dx.doi.org/10.1016/j.ecoenv.2011.08.018>, PMID:21924494
- Osthoff, G., Hugo, A., Bouwman, H., Buss, P., Govender, D., Joubert, C.C. et al., 2010, 'Comparison of the lipid properties of captive, healthy wild, and pansteatitis affected wild Nile crocodiles (*Crocodylus niloticus*)', *Comparative Biochemistry and Physiology Part A: Molecular and Integrative Physiology* 155, 64–69. <http://dx.doi.org/10.1016/j.cbpa.2009.09.025>
- Post, G.W., 1993, 'Nutrition and nutritional diseases of salmonids', in M.K. Stoskopf (ed.), *Fish Medicine*, pp. 343–358, W.B. Saunders Company, Harcourt Brace Jovanovich, Philadelphia, London, Toronto, Montreal, Sydney, Tokyo.
- Roberts, R.J. & Agius, C., 2008, 'Pan-steatitis in farmed northern bluefin tuna, *Thunnus thynnus* (L.) in the eastern Adriatic', *Journal of Fish Diseases* 31, 83–88. <http://dx.doi.org/10.1111/j.1365-2761.2007.00901.x>, PMID:18234015
- Roberts, R.J., Richards, R.H. & Bullock, A.M., 1979, 'Pansteatitis in rainbow trout *Salmo gairdneri* Richardson: A clinical and histological study', *Journal of Fish Diseases* 2, 85–92. <http://dx.doi.org/10.1111/j.1365-2761.1979.tb00145.x>
- Skelton, P., 2001, *A complete guide to the freshwater fishes of Southern Africa*, Struik Publishers, Cape Town.
- Spataru, P., Viveen, W.J.A.R. & Gophen, M., 1987, 'Food composition of *Clarias gariepinus* (= *C. lazera*) (Cypriniformes, Claridae) in Lake Kinneret (Israel)', *Hydrobiologica* 144, 77–82. <http://dx.doi.org/10.1007/BF00008053>
- Smith, C.E., 1979, 'The prevention of liver lipid degeneration (ceroidosis) and microcytic anaemia in rainbow trout *Salmo gairdneri* Richardson fed rancid diets: A preliminary report', *Journal of Fish Diseases* 2, 429–437. <http://dx.doi.org/10.1111/j.1365-2761.1979.tb00394.x>
- Steffens, W., 1997, 'Effects of variation in essential fatty acids in fish feeds on nutritive value of freshwater fish for humans', *Aquaculture* 151, 97–119. [http://dx.doi.org/10.1016/S0044-8486\(96\)01493-7](http://dx.doi.org/10.1016/S0044-8486(96)01493-7)
- Tappel, A.L., 1973, 'Lipid peroxidation damage to cell components', *Federation Proceedings* 32, 1870–1874. PMID:4352451
- Uys, W., 1988, 'Nutrition', in T. Hecht, W. Uys & P.J. Britz (eds.), *The culture of sharp-toothed catfish, *Clarias gariepinus* in southern Africa*, South African National Scientific Programmes Report no. 153, pp. 47–61, CSIR, Pretoria.
- Wallach, J.D. & Hoessle, C., 1968, 'Steatitis in captive crocodilians', *Journal of the American Veterinary Medical Association* 153, 845–847. PMID:5692919
- Watanabe, T., Takeuchi, T., Wada, M. & Uehara, R., 1981, 'The relationship between dietary lipid levels and  $\alpha$ -tocopherol requirement of rainbow trout', *Bulletin of the Japanese Society of Scientific Fisheries* 47, 1463–1471. <http://dx.doi.org/10.2331/suisan.47.1463>
- Weyl, O.L.F. & Booth A.J., 2008, 'Validation of annulus formation in otoliths of a temperate population of adult African sharp-toothed catfish *Clarias gariepinus* using fluorochrome marking of wild fish', *Journal of Fish Biology* 73, 1033–1038. <http://dx.doi.org/10.1111/j.1095-8649.2008.01975.x>



## Ecosystem change and the Olifants River crocodile mass mortality events

S. WOODBORNE,<sup>1,†</sup> K. D. A. HUCHZERMAYER,<sup>2,3</sup> D. GOVENDER,<sup>3,4</sup> D. J. PIENAAR,<sup>4</sup> G. HALL,<sup>1</sup>  
 J. G. MYBURGH,<sup>3</sup> A. R. DEACON,<sup>4</sup> J. VENTER,<sup>4</sup> AND N. LÜBKER<sup>5</sup>

<sup>1</sup>Natural Resources and the Environment, CSIR, Meiring Naude Road, Pretoria 0001 South Africa

<sup>2</sup>Sterkspruit Veterinary Clinic, P.O.Box 951, Lydenburg 1120 South Africa

<sup>3</sup>Department of Paraclinical Sciences, Faculty of Veterinary Science, University of Pretoria, Onderstepoort 0110 South Africa

<sup>4</sup>Scientific Services, SANParks, Private Bag X402, Skukuza 1350 South Africa

<sup>5</sup>Department of Zoology and Entomology, University of Pretoria, Pretoria 0002 South Africa

**Citation:** Woodborne, S., K. D. A. Huchzermeyer, D. Govender, D. J. Pienaar, G. Hall, J. G. Myburgh, A. R. Deacon, J. Venter, and N. Lübker. 2012. Ecosystem change and the Olifants River crocodile mass mortality events. *Ecosphere* 3(10):87. <http://dx.doi.org/10.1890/ES12-00170.1>

**Abstract.** Nile crocodile (*Crocodilus niloticus*) mass mortality events in the Olifants River between the Letaba River confluence in South Africa and Lake Massingir in Mozambique have been attributed to pansteatitis: a disease that affects fat depots of the animals. The disease is also found in sharp-toothed catfish (*Clarias gariepinus*) in the same area, and the cause of the disease is attributed to pollution. Although the Olifants River Valley is polluted, the impact of interventions such as dam construction on biodiversity receives little attention. We show that the onset of the pansteatitis epidemic in crocodiles and sharp-toothed catfish at the Olifants/Letaba confluence coincided with back-flooding of Lake Massingir that changed the Olifants River from a rock and sand substrate river to a clay substrate lake. Isotopic analysis shows that sharp-toothed catfish shifted from a predominantly vegetarian to a piscivorous diet that is highly correlated with pansteatitis prevalence, and crocodiles and tiger fish (*Hydrocynus vittatus*) show coincident trophic level increases. The evidence suggests that the ecosystem change altered the structure of the lotic foodweb and that an exotic or extralimital fish has invaded the confluence and is the vector of the pansteatitis epidemic. The invasive fish species is yet to be identified. The pansteatitis epidemic is an unintended ecological consequence of damming this river.

**Key words:** aquatic biodiversity; *Clarias gariepinus*; *Crocodilus niloticus*; *Hydrocynus vittatus*; lotic foodwebs; pansteatitis; stable isotopes.

**Received** 12 June 2012; revised 12 August 2012; accepted 13 August 2012; final version received 25 September 2012; **published** 18 October 2012. Corresponding Editor: D. P. C. Peters.

**Copyright:** © 2012 Woodborne et al. This is an open-access article distributed under the terms of the Creative Commons Attribution License, which permits restricted use, distribution, and reproduction in any medium, provided the original author and sources are credited.

† **E-mail:** [Swoodbor@csir.co.za](mailto:Swoodbor@csir.co.za)

### INTRODUCTION

Pansteatitis is an inflammatory reaction accompanying fat cell necrosis that can cause death in a wide range of species (Roberts et al. 1979, Herman and Kircheis 1985, Ladds et al. 1995, Wong et al. 1999, Niza et al. 2003, Goodwin 2006, Roberts and Agius 2008, Neagari et al. 2011).

Although the disease is rare in wild animals it has brought the Nile crocodile, *Crocodilus niloticus* Laurenti, population at Lake Loskop in the upper Olifants River Valley, South Africa, to the brink of extinction (Ashton 2010, Botha et al. 2011). Since 2008 crocodile mass mortalities from pansteatitis have also become a seasonally recurring event downstream in an area known

as the Olifants River Gorge between the confluence of the Olifants River with the Letaba River in the Kruger National Park, South Africa, and Lake Massingir, Mozambique (Osthoff et al. 2010, Ferreira and Pienaar 2011). The condition affects fat depots and renders the crocodiles stiff and lethargic and unable to hunt, and death is thought to be through starvation or drowning. Pansteatitis is also diagnosed in sharptooth catfish, *Clarias gariepinus* (Burchell), in the same area of Kruger National Park in which the crocodile mass mortalities occur (Huchzermeyer et al. 2011) and in Lake Loskop it is prevalent in Mozambique tilapia, *Oreochromis mossambicus* (Peters) (Oberholster et al. 2011). Although the cause of the disease is dietary, the co-occurrence of pansteatitis in crocodiles and fish at two different locations of the same river catchment is not related to a potential trophic relationship as the disease is not contagious through ingestion. Pansteatitis may be caused by the consumption of rancid, dead fish (Ladds et al. 1995, Huchzermeyer 2003) but it is the intrinsic fatty composition of the diet (Brooks et al. 1985, Goodwin 2006) rather than pre-existing pansteatitis that affects higher trophic levels.

The pansteatitis epidemic in Lake Loskop followed mass fish die-offs and is attributed indirectly to water pollution from upstream mining, agriculture and human urban waste (Ashton 2010, Oberholster et al. 2011). If the bioaccumulation of pollutants is causing the disease, then it has severe implications for other water users in the catchment. The Olifants River Valley hosts commercial and subsistence agriculture and livestock farmers that irrigate or water directly from the river; it flows through the Kruger National Park where biodiversity is at risk; and there are trans-boundary issues as the river drains the commercial heartland of South Africa into neighbouring Mozambique. Although environmental law in South Africa imposes a “polluter pays” policy in respect of remediation (South African Government Gazette 1998) there is reluctance to impose measures that might affect the coal production and coal-based power generation that support the South African economy. In addition the scientific basis to link specific pollutants with specific industries or land-use patterns in a multi-industry catchment, and the basis to link pollutants with their

ecological consequences are poorly developed. As a result it remains unclear if pollution is the underlying cause of the pansteatitis epidemics. Bioaccumulation of pollutants has yet to be demonstrated in the crocodiles or other top predators in the Olifants River system. As Nile crocodiles mature they typically shift from an aquatic foodweb dependence to a terrestrial foodweb (Cott 1961, Wallace and Leslie 2008, Radloff et al. 2012), and so a bioaccumulation mechanism should lead to higher pansteatitis prevalence in juveniles. Affected juveniles may be underrepresented through their vulnerability to predation, but the pansteatitis mortality profiles of crocodiles in the Olifants River Gorge includes large numbers of mature individuals. In addition water pollution is ubiquitous throughout the Olifants River Valley yet substantial reaches remain unaffected by pansteatitis. Lake Flag Boshielo, for example, is located downstream of Lake Loskop and upstream of the Olifants River Gorge and it hosts a crocodile population without apparent pansteatitis symptoms. The dispersed distribution of pansteatitis outbreaks suggests that there may be other factors that are causing the disease.

Since pansteatitis is a dietary disease this research focuses on establishing the structure of the aquatic foodweb in the Olifants River Gorge and to determine if this differs from other systems where no pansteatitis occurs. The objective is to clarify possible exposure pathways for the bioaccumulation of pollutants, or to explore a possible localised ecological trigger that may underpin the pansteatitis epidemic. We use stomach content analysis and stable isotope analysis to determine the dietary niche of healthy and pansteatitis affected populations of sharptooth catfish and crocodiles from Kruger National Park (Fig. 1). The trophic positions of the sharptooth catfish and crocodiles are compared with tiger fish, *Hydrocynus vittatus* Castlenau, because the latter is an obligate piscivore at the top of the fish aquatic foodweb in the Kruger National Park river systems, and also with invertebrate communities lower in the foodweb. The two dietary analysis approaches that are used are complimentary to one another. Carbon and nitrogen isotopes elucidate the trophic relationships between different organisms with  $\delta^{13}\text{C}$  values reflecting the  $\text{C}_3$  or  $\text{C}_4$  plant source of

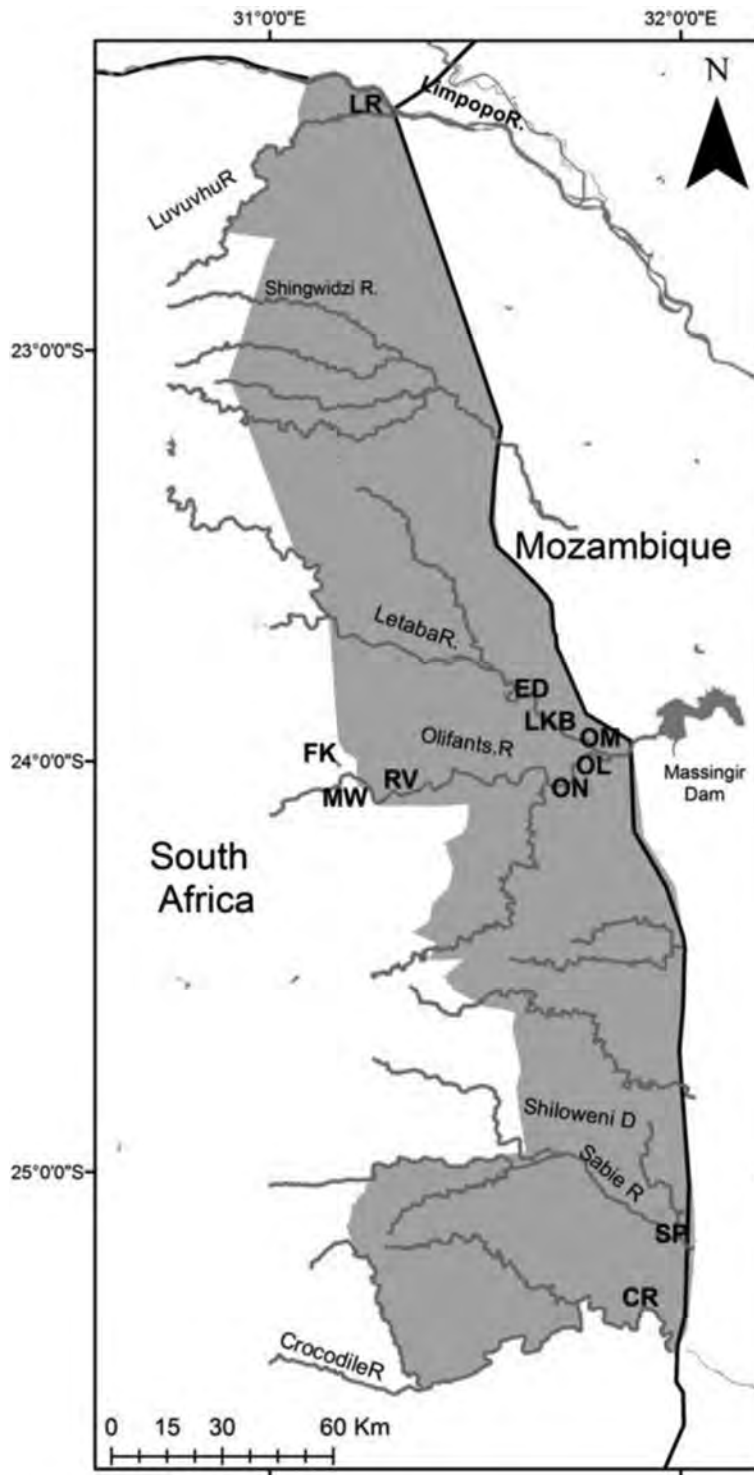

Fig. 1. Location of sampling sites in Kruger National Park. Sampling sites are identified by the site acronyms.



the foodweb with low (<1‰) increases between diet and tissue carbon, while  $\delta^{15}\text{N}$  values increase by approximately 3–5‰ per trophic level (Minagawa and Wada 1984, Peterson and Fry 1987, Fry 1991, Van der Zanden and Rasmussen 2001). The stomach content of an organism will reflect possibly only the last meal while the carbon and nitrogen isotope values integrate the dietary variance through the turnover time of the tissue, and in Nile crocodile keratin it may be in the order of months (Radloff et al. 2012). The majority of our sample sites were from different river systems and there is no possibility that the organisms might have migrated between the sample sites. However the Letaba River is a tributary of the Olifants River and in this system it is possible that organisms could migrate between the different sampling locations. In order to differentiate the river of origin for fish and crocodiles we analysed sulfur isotope values as this reflects the geology of the different catchments.

## METHODS

### *Sampling*

Fish samples were collected for histopathological and stomach content analysis in June 2009, August 2009, November 2009, July 2010, January 2011 and June 2011 from rivers and dams in the Kruger National Park (Fig. 1). Sample sites include the confluence of the Letaba and Olifants Rivers (23°59'21.8" S, 31°49'35.6" E) and from 1.3km upstream of the confluence in the Letaba River (23°55'57.9" S, 31°49'02.1" E) (for sharp-tooth catfish and tiger fish it can be assumed that these two locations represent a single population) (site OL). Further samples were taken from the Olifants River at Ngotso located 28.5 km upstream of the Letaba confluence (24°03'10.8" S, 31°43'50.6" E) (site ON), the headwaters of Lake Massingir near the Mozambique border (23°57'48" S, 031°52'97" E) (site OM) and Mamba Weir (24°03'32" S, 031°14'14" E) (site MW). Samples were also taken from Reënvoël Dam (23°58'37.2" S, 031°19'38.4" E) (site RV) and van Ryssen Dam (24°00'13.6" S, 31°05'36.9" E) (site FK) located on tributaries of the Olifants River. The Letaba River was sampled upstream of the confluence at Klipkoppies Bridge (23°56'58" S, 031°43'89" E) (site LKB) and from Engelhard

Dam (23°50'19" S, 31°28'28" E) (site ED) located 17km upstream of the Olifants River confluence. Other river systems that were sampled include the Sabie River in the Sabiepoort (25°10'25.41" S, 32°2'23.42" E) (site SP), the Levuvhu River (22°25'51.0" S, 31°18'04.4" E) (site LR) and the Crocodile River (25°23'57.1" S, 31°57'29.9" E) (site CR). Sharp-tooth catfish and tiger fish were caught on baited hooks or artificial lures, while other species were sampled using an electrofisher (Samus). The fish that were subject to isotopic analysis comprise a subsample of the June 2011 collection from the OL, LR and CR sites. Invertebrates, diatoms, riparian and aquatic vegetation, sediments and organic detritus were also sampled for isotopic analysis. On 4–7 September 2011 tiger fish samples were collected from the Crocodile River, and both sharp-tooth catfish and tiger fish were sampled from below the Engelhard Dam wall (considered the same as site ED).

Fish were euthanized in a benzocaine solution. The protocol was approved under the University of Pretoria Animal Care and Use Protocol V013/10 and sanctioned by South African National Parks (SANParks). Crocodile claws were collected from animals that were euthanized as part of the SANParks research into pansteatitis in 2010.

### *Isotopic analysis*

Fish muscle tissues for isotopic analyses were taken from the abdominal area and were degreased in a 2:1 chloroform:ethanol mixture and dried overnight at 70°C. Invertebrates and organic samples were reacted with a 1% HCl solution to remove any trace of carbonates, rinsed to pH neutral in distilled water and dried overnight at 70°C. Analyses were performed on homogenised whole invertebrate samples (Pinnegar and Polunin 1999), and on a time series of samples taken from the dorsal aspect of the crocodile claws extending from the base to the tip of the claw. Claw samples were cleaned by boiling in distilled water during the extraction process but were not further pre-treated. Carbon and nitrogen isotope analyses were undertaken on 0.5–1.0 mg aliquots, while sulphur isotope analyses required 5 mg aliquots. Analyses were done on a Flash EA 1112 Series elemental analyser coupled to a Delta V plus isotope ratio mass spectrometer by a ConFloIV interface (all

equipment supplied by ThermoFisher, Bremen, Germany). Each sample was measured in duplicate with laboratory standards and blanks run after every 12 unknown samples. Precision was <0.1‰ for all analyses.

The degreasing process influences both  $\delta^{13}\text{C}$  and  $\delta^{15}\text{N}$  values. The effect on  $\delta^{15}\text{N}$  values is in the order of 0.25‰ (Post et al. 2007) which is considered negligible in the context of this study, while the effect on  $\delta^{13}\text{C}$  values is more substantial and a correction based on the C/N ratio (derived from the mass spectrometer measurement) was applied (Post et al. 2007).

Carbon and nitrogen isotope values were corrected against an in-house standard (Merck Gel) while sulphur isotopes were referenced against sulphanilamide and NIST bovine liver (Fry et al. 2002). Results are reported using the standard delta notation for stable light isotopes using the equation  $\delta^{13}\text{C}$  or  $\delta^{15}\text{N} = [(R_{\text{sample}}/R_{\text{standard}}) - 1]/1000$ , where  $R$  is  $^{13}\text{C}/^{12}\text{C}$  or  $^{15}\text{N}/^{14}\text{N}$ , respectively. The reference standards against which results are reported are Vienna PeeDee belemnite (VPDB) for  $\delta^{13}\text{C}$ , atmospheric nitrogen (Air) for  $\delta^{15}\text{N}$  and Vienna Canyon Diablo Troilite (VCDT) for  $\delta^{34}\text{S}$ .

### Statistical analysis

The statistical test for significance for the association of pancreatitis with stomach content excluded fish that had empty stomachs. The fish sample was divided into three populations: those that had pancreatitis (P++), those that were sampled at a site at which pancreatitis prevalence was recorded, but did not show any symptoms (P+-), and those sampled at sites from which no pancreatitis was recorded (P-). Stomach contents of fish were classified into three categories: fish, vegetation and mixed. The null hypothesis assumed that the three stomach content categories would be equally sampled in a random selection strategy by the fish populations. The chi-squared test value of 63.9 is significant ( $P < 0.0001$ ) using 4 degrees of freedom and the null hypothesis is rejected implying that there is preferential dietary selection in the three populations.

## RESULTS AND DISCUSSION

The results of the sulphur isotope analysis of

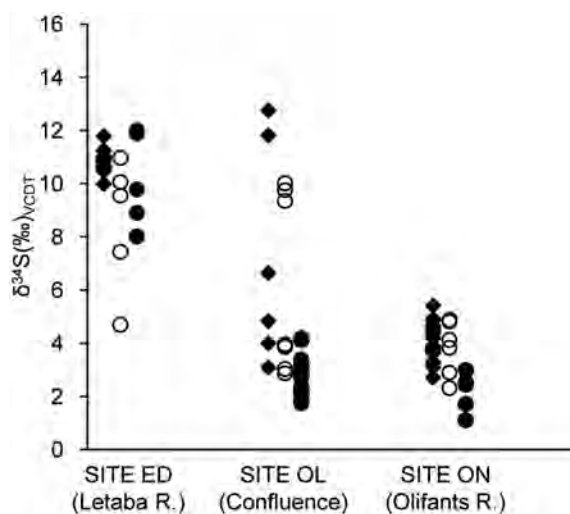


Fig. 2. The  $\delta^{34}\text{S}$  values for fish characterise the Olifants River source (site ON) and the Letaba River source (site LE). Solid circles represent tiger fish, open circles represent sharptooth catfish and diamonds represent other fish. Fish from the confluence (site OL) show mixed or intermediate  $\delta^{34}\text{S}$  values.

fish from the Olifants River/Letaba River system are plotted in Fig. 2. Distinction is made between sharptooth catfish and tiger fish that are both migratory in river systems versus other fish species that are less likely to migrate (see Appendix A for the species that were sampled). The results for sites ON and ED that are located upstream in the Olifants and Letaba Rivers respectively provide unambiguous sulphur isotope signatures for each river that can be used to trace migratory behavior of fish sampled at the confluence. Migratory-limited fish sampled upstream in the Olifants River had  $\delta^{34}\text{S}$  values of  $4.1 \pm 0.7$  (mean  $\pm$  SD,  $n = 21$ ) and those sampled upstream in the Letaba River had  $\delta^{34}\text{S}$  values of  $10.8 \pm 0.4$ ‰ (mean  $\pm$  SD,  $n = 13$ ). Fish sampled at the confluence showed  $\delta^{34}\text{S}$  that ranged between the baseline values for the two rivers. It is not necessary to characterise the sulphur isotope values for the other sample sites as there is no possibility of migration between these systems, but it is necessary to explore the basis for isotopic foodweb structure comparisons between isolated sites (Post 2002).

Isotopic foodweb analysis is based on the predictable diet-to-tissue fractionation of carbon and nitrogen isotopes that leads to isotopic

enrichment in organisms at higher trophic levels. Within a site this allows trophic comparisons to be made between different organisms, but the approach is more complicated if trophic levels are to be compared between sites in different river systems. Local sources of carbon and nitrogen in lotic systems may vary, particularly where rivers flow through different catchment land-uses that may result in different isotopic characteristics at the base of the foodweb (Cabana and Rasmussen 1996, Post 2002). In this study we used the isotopic values for invertebrates as a proxy for the isotopic values for the base of the site-specific foodwebs. We compared species of invertebrates found at all the sampling locations (Appendix B) on the assumption that they will occupy the same trophic level, but only *Gomphidae* (dragonfly larvae) were represented at all sites, and *n* values at each site were not always sufficient to give confidence to the inter-site comparison. Several other species of invertebrates were represented at most, but not all of the sites. The inter-site isotopic baseline that emerged for selected invertebrate species presented a consistent pattern, and an alternative approach was adopted to overcome the sample bias. Instead of considering individual invertebrate species, the analysis focussed on the averaged isotopic values for all invertebrate species found on each site irrespective of the different trophic levels they represented (Fig. 3). The result that emerged from this approach is very similar to the results observed for individual invertebrate species and the pattern is robust. The average invertebrate values for all sites except the ED site (below the Engelhard Dam on the Letaba River) showed a linear dependence of  $\delta^{15}\text{N}$  on  $\delta^{13}\text{C}$  that is described by Eq. 1.

$$\delta^{15}\text{N} = -0.32\delta^{13}\text{C} + 3.69 \dots (r^2 = 0.986). \quad (1)$$

The dependence of  $\delta^{15}\text{N}$  on  $\delta^{13}\text{C}$  is related to the variation in the isotopic base of the foodweb between sites, and this equation defines a particular trophic level (in this case the invertebrates). For higher trophic levels the relationship will be defined by Eq. 2.

$$\delta^{15}\text{N} = -0.32\delta^{13}\text{C} + 3.69 + \Delta n \quad (2)$$

where *n* represents the trophic level of an organism relative to the invertebrates, and  $\Delta$  represents the diet-to-tissue fractionation factor

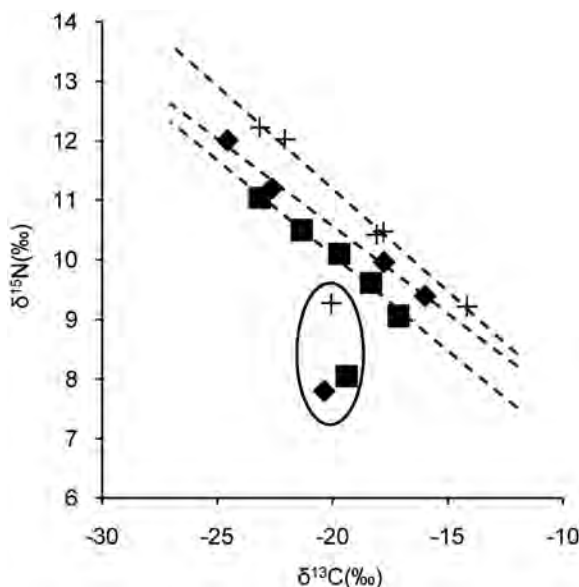


Fig. 3. The isotopic values for aquatic invertebrates are used to define an “isotrophic” comparison between sites from different catchments. *Gomphidae*, represented by crosses, and *Pleurocerida*, represented by diamonds, are represented at most of the sample sites, and display a linear relationship between  $\delta^{13}\text{C}$  and  $\delta^{15}\text{N}$  values. To better represent all invertebrate trophic levels and to provide larger sample size for the comparisons, the isotrophic line regression is based on the average of all invertebrate species from each site, represented by solid squares. The isotopic values for site ED (circled) deviate from the other sites. Regressions through the respective datasets are represented with dotted lines and exclude the ED site.

for nitrogen isotopes. We define the lines in isotope space that are expressed by Eq. 2 as isotrophic lines. We use three isotrophic lines defined by Eqs. 3, 4 and 5.

$$\delta^{15}\text{N} = -0.32\delta^{13}\text{C} + 3.6 \quad (3)$$

$$\delta^{15}\text{N} = -0.32\delta^{13}\text{C} + 6.16 \quad (4)$$

$$\delta^{15}\text{N} = -0.32\delta^{13}\text{C} + 9.16. \quad (5)$$

The first isotrophic line was selected to distinguish fish and invertebrates, the second to represent the population of sharptooth catfish and tiger fish at the confluence of the Olifants and Letaba Rivers, and the third is equally spaced between these endpoints for reference

purposes. Coincidentally the trophic separation in the trophic lines of 3‰ on the nitrogen isotope scale is relatively close to the typical value observed for the trophic level fractionation of  $\delta^{15}\text{N}$  in a foodweb.

The isotrophic lines apply to all the sites except ED where  $\delta^{15}\text{N}$  values are systematically offset by a factor of  $-1.84\text{‰}$  across all organisms that were analysed. The reason for this excursion is not clear but it may be related to construction work on the Engelhard Dam that involves earthworks and concrete casting that commenced in July 2011 and was still ongoing during foodweb sampling in September. For the remainder of the analysis the isotrophic lines for the ED site are adjusted by  $-1.84\text{‰}$ .

Trophic results from the Olifants River, the Letaba River, and for reference purposes from the Crocodile and Levuvhu Rivers, are presented in Fig. 4. Emphasis is placed on the relative trophic separation between sharptooth catfish from different river systems and between sharptooth catfish and tiger fish. Stomach contents of tiger fish from the Olifants/Letaba confluence comprised fish remains ( $n=4$ ) or were empty ( $n=17$ ) confirming previous observations that this species is an obligate piscivore (Munro 1967, Skelton 1993). The sharptooth catfish is typically a benthic omnivore (Spataru et al. 1987, Bruton 1988, Skelton 1993, Van Weerd 1995) that should occupy a lower trophic level than tiger fish. In the Crocodile River (Fig. 4A) and in the Olifants River upstream from the confluence (Fig. 4B), tiger fish occupy a higher trophic level than sharptooth catfish as expected. In the Letaba River upstream from the confluence a single sharptooth catfish specimen occupies a higher trophic level than tiger fish (Fig. 4C). The sulphur isotope value for this individual was  $4.7\text{‰}$  suggesting that it migrated from the Olifants River system and the carbon and nitrogen isotope signal may not reflect its positioning in the local foodweb. At the Olifants/Letaba confluence (Fig. 4D) sharptooth catfish and tiger fish occupy the same trophic level and the trophic level for both species is higher than any of the other sampled sites. This observation confirms stomach content analysis: of 21 sharptooth catfish sampled at the Olifants/Letaba confluence in June 2011, four had vegetable matter in their stomachs while 11 contained pure fish remnants

(Appendix C). One sharptooth catfish specimen with only vegetation in its stomach yielded the lowest trophic level of the isotopic analysis subsample, and its sulphur isotope value of  $9.3\text{‰}$  indicates it was a recent immigrant from the Letaba River.

At the Olifants/Letaba confluence the frequency of pure fish stomach contents in sharptooth catfish varied seasonally between  $81.8\%$  in November/January samples (high flow) and  $48.7\%$  in June/July samples (low flow). The stomach content analysis only reflects the last food intake of each specimen and cannot be used to infer the overall diet or seasonal variation of each individual fish, but the isotopic analysis aggregates tissue turnover times and reflects the modal diet of each individual. Our combined isotope and stomach content data confirms that there is a high prevalence of piscivory in the Olifants/Letaba sharptooth catfish population. Since the trophic level of both sharptooth catfish and tiger fish at this site is higher than tiger fish from other sites we can make some inference regarding their diet. The trophic similarity between sharptooth catfish and tiger fish seems to indicate predation on a narrow range of fish species at the Olifants/Letaba confluence rather than opportunistic feeding that leads to a broader spread of trophic levels for both species at the comparative sites. The prey species is unlikely to be among the low trophic level fish such as yellowfish, *Labeobarbus marequensis* (Smith), that are extremely abundant. Instead the prey species will have  $\delta^{15}\text{N}$  values associated with a slightly higher trophic level, or a vegetarian species with a high  $\delta^{15}\text{N}$  diet. It is noted that diatoms and organic sediment samples from Lake Massingir have elevated  $\delta^{15}\text{N}$  values relative to all the other sites that were sampled (Appendix D).

This diet specificity appears to underlie the vulnerability of sharptooth catfish to pansteatitis. There is a significant correlation between the frequency of fish stomach contents and the prevalence of pansteatitis:  $73.5\%$  of sharptooth catfish with pansteatitis had pure fish stomach contents and  $16.3\%$  had pure vegetation in their stomachs compared with  $22.2\%$  pure fish stomach contents and  $59.3\%$  pure vegetation content from sites without any pansteatitis (Fig. 5, Appendix C). It is not clear if the vulnerability to pansteatitis is a metabolic consequence that is



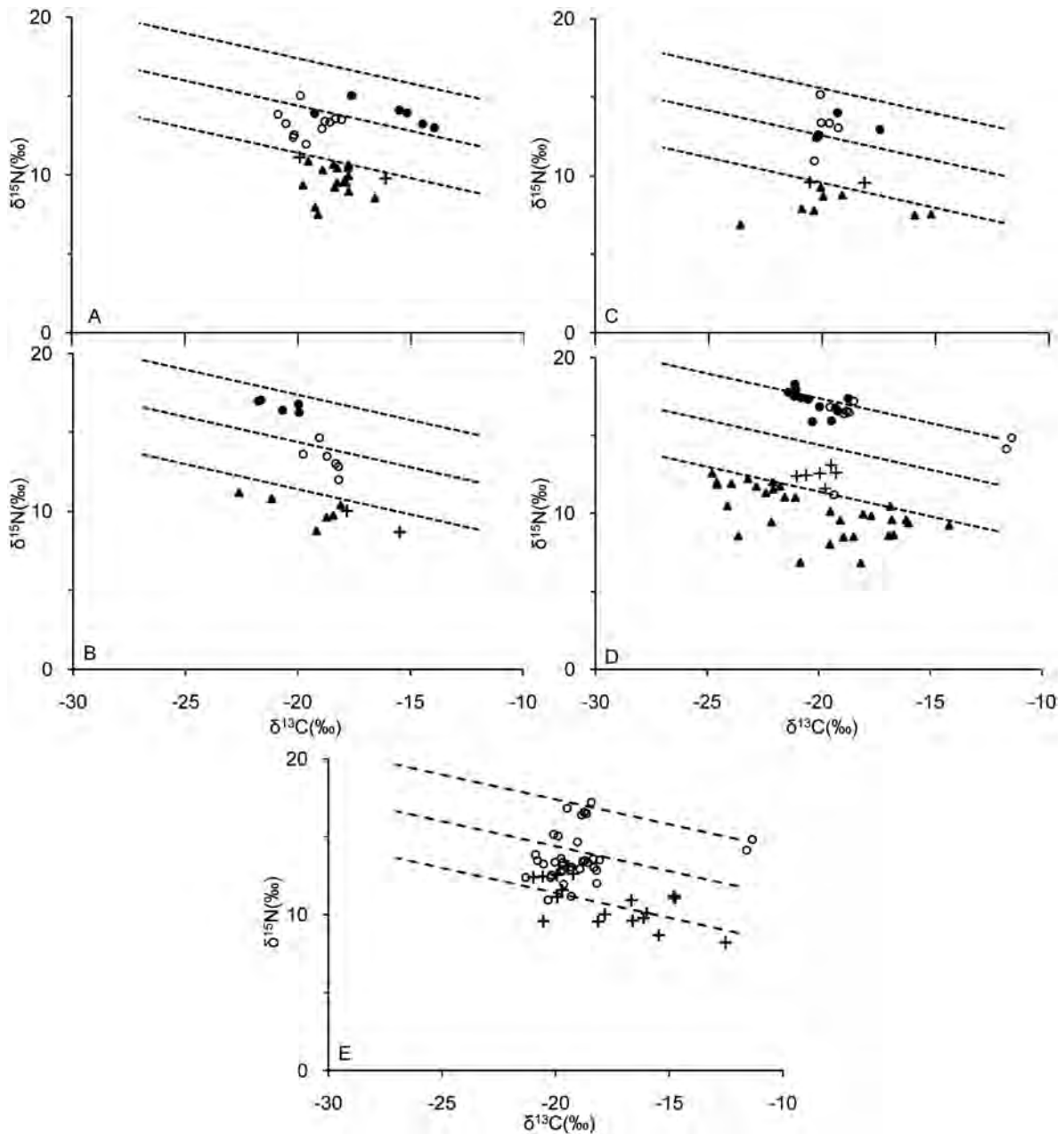


Fig. 4. The relative trophic position of individual sharptooth catfish, tiger fish invertebrate genera and co-occurring crocodiles are represented relative to lines of equal trophic level for sites CR (A), ON (B), ED (C) and OL (D). The relative trophic level of the entire sample of crocodiles ( $n = 17$ ) is compared with all sharptooth catfish samples (E). Sharptooth catfish are represented by open circles, tiger fish by solid circles, invertebrates by solid triangles and crocodiles by crosses. The isotrophic lines for site ED are adjusted by  $-1.84\text{‰}$  to compensate for a foodweb base value offset.

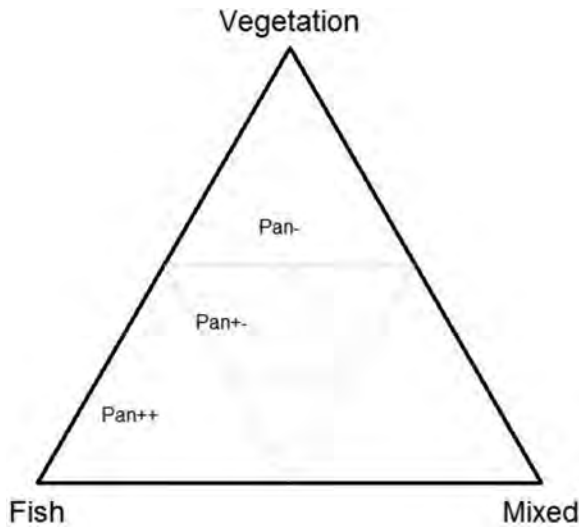


Fig. 5. The population of sharp-tooth catfish with pansteatitis (Pan++) have stomach contents with a higher proportion of fish than vegetation, or invertebrates and detritus (mixed) when compared with the population of fish from areas that have pansteatitis prevalence, but do not have pansteatitis (Pan+-), and the population from areas without pansteatitis prevalence (Pan-).

unique to sharp-tooth catfish with a piscivorous diet, as the disease does not occur in lower trophic level fish species or in tiger fish at the Letaba/Olifants confluence. It may be caused by an intrinsic quality of the fish that is ingested as pansteatitis is associated with increased intake of polyunsaturated fatty acids or from a rancid fish fat diet (Brooks et al. 1985, Goodwin 2006). Pansteatitis was, for example, observed in sharp-tooth catfish fed on rotting trout offal at Lunsklip Fisheries in November 2009 (Huchzermeyer et al., *in press*), but fish die-offs that might be a source of rancid fats are rare at the confluence. A linear regression of pansteatitis prevalence through time suggests that the epidemic started in sharp-tooth catfish at the beginning of 2007 (Fig. 6).

Interestingly, the role of fish in the crocodile diet is not as high as anticipated. Of the 11 crocodiles for which stomach contents inventories were taken in this study, 6 were empty, 4 contained terrestrial remains, and two contained fish remains. In support of this the isotope values of the crocodiles plot well below sharp-tooth

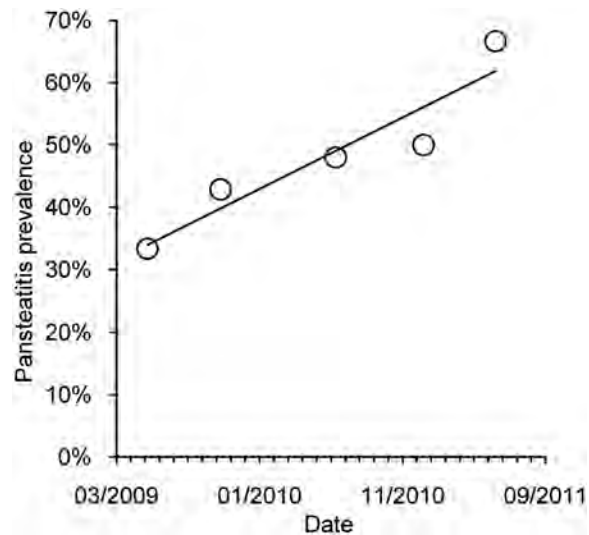


Fig. 6. The trend in the prevalence of pansteatitis in the sharp-tooth catfish samples through time suggests that the epidemic started in the 2006/2007 austral summer.

catfish and most other fish species that were sampled (Fig. 4, Appendix E), implying that terrestrial food sources make up the bulk of their diet. Within the crocodile population that was subject to isotopic analysis, those from the Olifants River Gorge have the highest trophic status and probably consume more fish than in other areas, but it still remains a relatively small part of their overall diet. Time series stable isotope analysis of crocodile claws shows that four of the five animals sampled from the Olifants River Gorge show an unprecedented increase in nitrogen isotope values before their deaths (Fig. 7A–D). This suggests a trophic level increase that may be associated with dietary changes with increased ontogenic age or size (Radloff et al. 2012), but none of the other twelve crocodile claw time series from rivers and dams throughout KNP show this trend. The trophic increase in the Olifants River Gorge crocodiles is similar to that noted in sharp-tooth catfish and may indicate increased fish intake before the crocodiles died.

A single Olifants River crocodile from the Olifants/Letaba confluence that did not show the gradual nitrogen isotope increase had values that remained within a tight range over most of its growth, but it showed regularly spaced high



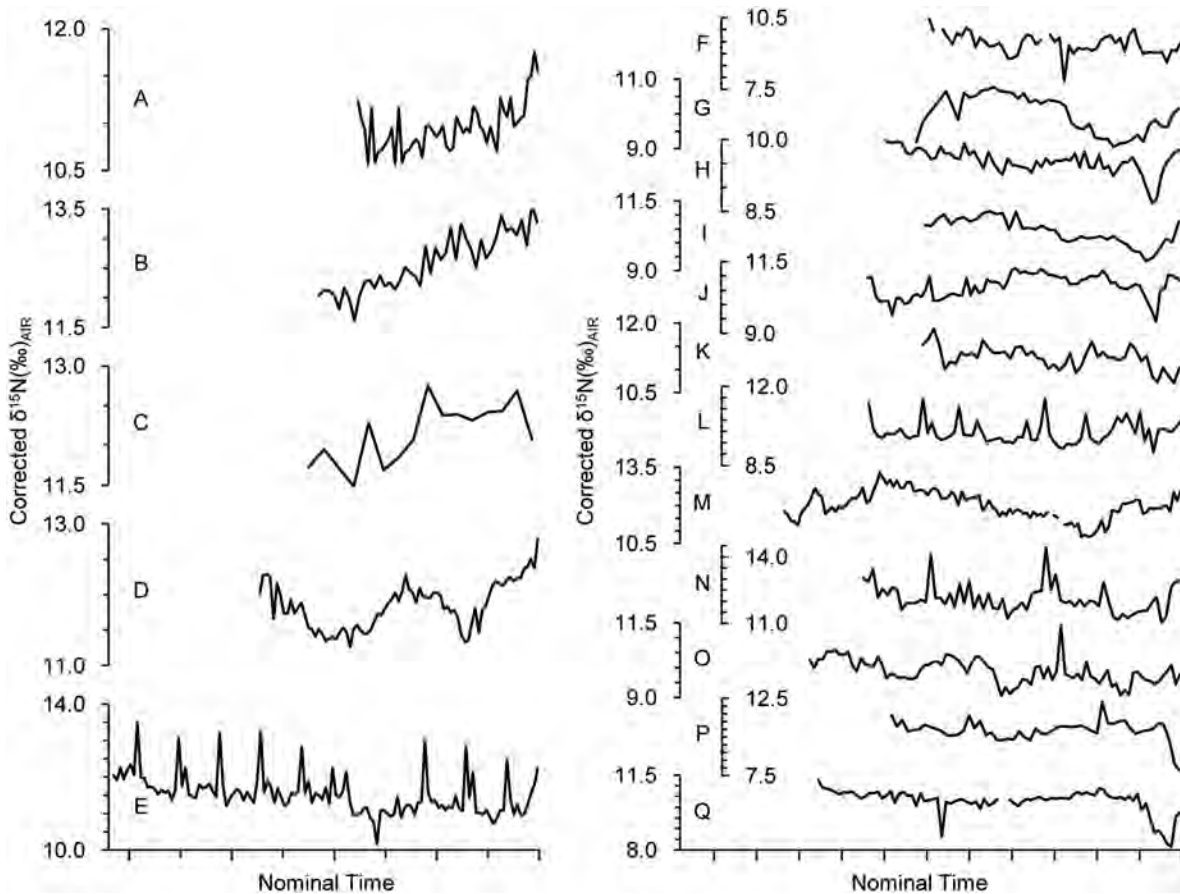


Fig. 7. Most of the crocodiles sampled between the confluence of the Olifants and Letaba Rivers and the Mozambique border show an unprecedented trophic level increase before their death (A–D). A regular spike in one of the crocodile claw time series (E) is thought to be a seasonal signal suggesting that the trophic level increases commenced in the last 3 years. Other crocodiles from Mamba Weir (F, G), the Letaba River (H, I), the Levuvhu River (J, K), the Shingwedzi River (L), Shiloweni Dam (M, N), the Sabie River (O) and the Crocodile River (P, Q) do not show this trend. The  $\delta^{15}\text{N}$  values have been normalised to the mean  $\delta^{13}\text{C}$  value of the crocodile claw samples ( $-17.74\text{‰}$ ). The x-axis is a nominal time axis with the value for the tip of each claw plotted on the left, and the base of each claw on the right so that time moves from oldest to youngest in a left to right direction. The crocodiles were sampled in 2010 so the base of each claw represents this date.

nitrogen isotope excursions (Fig. 7E). This pattern is typical of organisms that have a seasonal dietary shift between food sources with distinct isotopic baseline values, for example, in the baleen of migratory whale species that migrate between different food sources in the ocean (Best and Schell 1996, Lee et al. 2005). In some instances the positive nitrogen isotope excursions in the crocodiles are up to 3‰ in magnitude which indicates one trophic level shift. Since the crocodile diet in Kruger National Park appears to be dominated by terrestrial

animals the alternative dietary source may be seasonal exploitation of fish which is demonstrated in Fig. 4 to have a higher nitrogen isotope value. We suggest that the regular nitrogen isotope spike is a seasonal marker related to the exploitation of fish breeding migrations during the early rainy season when river flows increase (December to January in Kruger National Park). Determining the precise seasonality of the nitrogen spikes will require further research, but the presumption that it is a seasonal marker provides a means of calibrating the claw growth rate so

that the onset of the trophic shift can be dated. The nitrogen isotope (trophic) increase commenced between 2 and 3 years before the crocodile sample was collected in 2010.

We associate the trophic increase in the sharptooth catfish with the trophic level increase in crocodiles on the basis of geographic and temporal consistencies. The trophic increase in sharptooth catfish and tiger fish without a corresponding shift in invertebrates implies feeding behavior change in the fish. In addition the matching trophic levels of sharptooth catfish and tiger fish populations at the Olifants/Letaba confluence suggest that they are feeding on the same limited range of species. The fish trophic level data requires the presence of a prey fish species that previously did not exist in the region. The same logic does not apply to the trophic increase in crocodiles as this may reflect either increased fish intake or the intake of fish with higher  $\delta^{15}\text{N}$  values. The latter may be pansteatitis affected sharptooth catfish as the disease renders them vulnerable to predation although eating pansteatitis affected fish will not cause pansteatitis in crocodiles. Controlled feeding experiments in which crocodiles were fed sharptooth catfish from the Olifants/Letaba confluence and pansteatitis affected crocodile tissue have not led to the development of pansteatitis in those crocodiles (J. Myburgh, *personal observations*). Instead it is the presence of fat that is rich in highly polyunsaturated fatty acids in the diet that causes the disease. The simplest explanation for the trophic shift in sharptooth catfish, tiger fish, and crocodiles is a geographically limited, dietary cause brought about by the invasion of a single fish species. The completion of the Lake Massingir sluice gates in 2007 led to back-flooding of the Olifants River Gorge and deposition of large amounts of fine clay where previously there was a rock and sand substrate gorge environment. Rapids that hosted filamentous algae and diverse habitats for fish fauna were lost. We hypothesise that this ecosystem change allowed the invasion of an exotic or extralimital fish species that contains fat rich in highly polyunsaturated fatty acids that causes pansteatitis when eaten either by sharptooth catfish and crocodiles, but apparently not tiger fish. The invasive fish species has yet to be identified, but we hypothesise that the ecosystem

change brought about by the back-flooding of Lake Massingir may have allowed silver carp (*Hypophthalmichthys molitrix*, Vallenciennes) that have historically occurred in Lake Massingir to invade the Olifants River gorge. Silver carp were not represented in our fish sample because the sampling methods were inappropriate for this species, and accordingly we cannot place them into the emerging foodweb. The species is not reported in the Sabie River where pansteatitis has been noted in a limited number of crocodiles, and it is abundant in Lake Flag Boshielo where crocodiles do not have pansteatitis. This does not exclude silver carp as the vector for pansteatitis at the Olifants/Letaba confluence as the localised diet of the fish will determine the composition of its fat. Our ongoing research is focussing on the fat composition of the fish in the Olifants River Gorge in order to identify which species are causing the pansteatitis epidemic.

#### ACKNOWLEDGMENTS

This research was partially funded by the Water Research Commission of South Africa (Consultancy K8/948).

#### LITERATURE CITED

- Ashton, P. J. 2010. The demise of the Nile crocodile (*Crocodylus niloticus*) as a keystone species for aquatic ecosystem conservation in South Africa: The case of the Olifants River. *Aquatic Conservation—Marine and Freshwater Ecosystems* 20:489–493.
- Best, P. B., and D. M. Schell. 1996. Stable isotopes in southern right whale (*Eubalaena australis*) baleen as indicators of seasonal movements, feeding and growth. *Marine Biology* 124:483–494.
- Botha, H., W. van Hoven, and L. J. Guillette. 2011. The decline of the Nile crocodile population in Loskop Dam, Olifants River, South Africa. *Water SA* 37:103–108.
- Brooks, H. V., C. G. Rammell, J. J. L. Hoogenboom, and D. E. S. Taylor. 1985. Observations on an outbreak of nutritional steatitis (yellow fat disease) in fitch (*Mustella putorius furo*). *New Zealand Veterinary Journal* 33:141–145.
- Bruton, M. N. 1988. Systematics and biology of *clariid* catfish. Pages 1–11 in T. Hecht, W. Uys, and P. J. Britz, editors. *The culture of sharptooth catfish, Clarias gariepinus in southern Africa*. South African Scientific Programmes Report 153. CSIR, Pretoria, South Africa.

- Cabana, G., and J. B. Rasmussen. 1996. Comparison of aquatic food chains using nitrogen isotopes. *Proceedings of the National Academy of Sciences* 93:10844–10847.
- Cott, H. B. 1961. Scientific results of an enquiry into the ecology and economic status of the Nile crocodile (*Crocodylus niloticus*) in Uganda and Northern Rhodesia. *Transactions of the Royal Society of London* 29:211–356.
- Ferreira, S. M., and D. Pienaar. 2011. Degradation of the crocodile population of Kruger National Park, South Africa. *Aquatic Conservation—Marine and Freshwater Ecosystems* 21:155–164.
- Fry, B. 1991. Stable isotope diagrams of freshwater foodwebs. *Ecology* 72:2293–2297.
- Fry, B., S. R. Silva, C. Kendall, and R. K. Anderson. 2002. Oxygen isotope corrections for online  $\delta^{34}\text{S}$  analysis. *Rapid Communications in Mass Spectrometry* 16:854–858.
- Goodwin, A. E. 2006. Steatitis, fin loss and skin ulcers of channel catfish, *Ictalurus punctatus* (Rafinesque), fingerlings fed salmonid diets. *Journal of Fish Diseases* 29:61–64.
- Herman, R. L., and F. W. Kircheis. 1985. Steatitis in Sunapee trout, *Salvelinus alpinus oquassa* Girard. *Journal of Fish Diseases* 8:273–239.
- Huchzermeyer, F. W. 2003. Crocodiles: biology, husbandry and diseases. CABI Publishing, Wallingford, UK.
- Huchzermeyer, K. D. A., D. Govender, D. J. Pienaar, and A. R. Deacon. 2011. Steatitis in sharp-tooth catfish, *Clarias gariepinus* (Burchell), in the Olifants and Lower Letaba Rivers in the Kruger National Park, South Africa. *Journal of Fish Diseases* 34:489–498.
- Huchzermeyer, K. D. A., G. Osthoff, D. Govender. *In press*. Comparison of the lipid properties of healthy and pansteatitis-affected African sharp-tooth catfish, *Clarias gariepinus* (Burchell), and the role of diet in pansteatitis outbreaks in the Olifants River in the Kruger National Park, South Africa. *Journal of Fish Diseases*. doi:10.1111/jfd.1210
- Ladds, P. W., H. Mangunwirjo, D. Sebayang, and P. W. Daniels. 1995. Diseases in young farmed crocodiles in Irian Jaya. *Veterinary Record* 136:121–124.
- Lee, S. H., D. M. Schell, T. L. McDonald, and W. J. Richardson. 2005. Regional and seasonal feeding of bowhead whales *Balaena mysticetus* as indicated by stable isotope ratios. *Marine Ecology Progress Series* 285:271–287.
- Minagawa, M., and E. Wada. 1984. Stepwise enrichment of  $\delta^{15}\text{N}$  along food chains: Further evidence and the relationship between  $\delta^{15}\text{N}$  and animal age. *Geochimica et Cosmochimica Acta* 48:1135–1140.
- Munro, J. L. 1967. The food of a community of East African freshwater fishes. *Journal of Zoology* 151:389–415.
- Neagari, Y., S. Arii, M. Udagawa, M. Onuma, Y. Odaya, T. Kawasaki, M. Tenpaku, H. Hayama, K. Harada, M. Mizukami, and K. Murata. 2011. Steatitis in egrets and herons from Japan. *Journal of Wildlife Diseases* 47:49–55.
- Niza, N. M. R. E., C. L. Vilela, and L. M. A. Ferreira. 2003. Feline pansteatitis revisited: hazards of unbalanced home-made diets. *Journal of Feline Medicine and Surgery* 5:281–287.
- Oberholster, P. J., J. G. Myburgh, P. J. Ashton, J. J. Coetzee, and A.-M. Botha. 2011. Bioaccumulation of aluminium and iron in the food chain of Lake Loskop, South Africa. *Ecotoxicology and Environmental Safety* 75:134–141.
- Osthoff, G., A. Hugo, H. Bouwman, P. Buss, D. Govender, C. C. Joubert, and J. C. Swarts. 2010. Comparison of the lipid properties of captive, healthy wild and pansteatitis-affected wild Nile crocodiles (*Crocodylus niloticus*). *Comparative Biochemistry and Physiology Part A: Molecular and Integrative Physiology* 155:64–69.
- Peterson, B. J., and B. Fry. 1987. Stable isotopes in ecosystem studies. *Annual Review of Ecology and Systematics* 18:293–320.
- Pinnegar, J. K., and N. V. C. Polunin. 1999. Differential fractionation of  $\delta^{13}\text{C}$  and  $\delta^{15}\text{N}$  among fish tissues: Implications for the study of trophic levels. *Functional Ecology* 13:225–231.
- Post, D. M. 2002. Using stable isotopes to estimate trophic position: models, methods, and assumptions. *Ecology* 83:703–718.
- Post, D. M., C. A. Layman, D. A. Arrington, G. Takimoto, J. Quattrochi, and C. G. Montana. 2007. Getting to the fat of the matter: models, methods and assumptions for dealing with lipids in stable isotope analyses. *Oecologia* 152:179–189.
- Radloff, F. G. T., K. A. Hobson, and A. J. Leslie. 2012. Characterising ontogenic niche shifts in Nile crocodile using stable isotope ( $\delta^{13}\text{C}$ ,  $\delta^{15}\text{N}$ ) analysis of scute keratin. *Isotopes in Environmental and Health Studies* 1:1–18.
- Roberts, R. J., and C. Agius. 2008. Pan-steatitis in farmed northern bluefin tuna, *Thunnus thynnus* (L.), in the eastern Adriatic. *Journal of Fish Diseases* 31:83–88.
- Roberts, R. J., R. H. Richards, and A. M. Bullock. 1979. Pansteatitis in rainbow trout *Salmo gairdneri* Richardson: a clinical and histological study. *Journal of Fish Diseases* 2:85–92.
- Skelton, P. H. 1993. A comprehensive guide to the Freshwater Fishes of southern Africa. Southern Book Publishers, Halfway House, South Africa.
- South African Government Gazette. 1998. National Environmental Management Act, Act number 107, 1998. Republic of South Africa Government Gazette 401(19519):1–72.
- Spataru, P., W. J. A. R. Viveen, and M. Gophen. 1987.

- Food composition of *Clarias gariepinus* (= *C. lazera*) (Cypriniformes, Clariidae) in Lake Kinneret (Israel). *Hydrobiologia* 144:77–82.
- Van der Zanden, M. J., and J. B. Rasmussen. 2001. Variations in  $\delta^{13}\text{C}$  and  $\delta^{15}\text{N}$  trophic fractionation: Implications for aquatic foodweb studies. *Limnology and Oceanography* 46:2061–2066.
- Van Weerd, J. H. 1995. Nutrition and growth in *Clarias* species—a review. *Aquatic Living Resources* 8:395–401.
- Wallace, K. M., and A. J. Leslie. 2008. Diet of the Nile crocodile (*Crocodylus niloticus*) in the Okavango Delta, Botswana. *Journal of Herpetology* 43:361–368.
- Wong, E., I. Mikaelian, M. Desnoyers, and G. Fitzgerald. 1999. Pansteatitis in a free-ranging red-tailed hawk (*Buteo jamaicensis*). *Journal of Zoo and Wildlife Medicine* 30:584–586.

## SUPPLEMENTAL MATERIAL

## APPENDIX A

Table A1. Isotopic values from fish sampled from rivers in the Kruger National Park, South Africa.

Species	Site	$\delta^{15}\text{N}(\text{‰})_{\text{AIR}}$	$\delta^{13}\text{C}(\text{‰})_{\text{VPDB}}$	$\delta^{34}\text{S}(\text{‰})_{\text{VCDT}}$
<i>Clarias gariepinus</i>	CR	13.5	−18.1	5.5
<i>Clarias gariepinus</i>	CR	15.0	−19.9	6.1
<i>Clarias gariepinus</i>	CR	12.4	−20.2	6.6
<i>Clarias gariepinus</i>	CR	13.8	−20.9	6.5
<i>Clarias gariepinus</i>	CR	13.6	−18.4	5.8
<i>Clarias gariepinus</i>	CR	13.4	−18.8	5.8
<i>Clarias gariepinus</i>	CR	12.5	−20.2	6.6
<i>Clarias gariepinus</i>	CR	11.9	−19.6	5.7
<i>Clarias gariepinus</i>	CR	13.3	−18.6	4.9
<i>Clarias gariepinus</i>	CR	13.2	−20.5	6.2
<i>Clarias gariepinus</i>	CR	12.9	−18.9	6.5
<i>Clarias gariepinus</i>	LR	12.4	−21.3	8.9
<i>Clarias gariepinus</i>	LR	12.8	−19.7	7.2
<i>Clarias gariepinus</i>	LR	13.5	−20.8	7.0
<i>Clarias gariepinus</i>	LR	12.8	−19.8	7.6
<i>Clarias gariepinus</i>	LR	13.2	−19.7	7.5
<i>Clarias gariepinus</i>	OL	11.2	−19.3	9.3
<i>Clarias gariepinus</i>	OL	17.2	−18.4	2.9
<i>Clarias gariepinus</i>	OL	14.8	−11.3	10
<i>Clarias gariepinus</i>	OL	14.1	−11.6	9.8
<i>Clarias gariepinus</i>	OL	16.6	−18.8	4.0
<i>Clarias gariepinus</i>	OL	16.4	−18.9	3.9
<i>Clarias gariepinus</i>	OL	16.8	−19.5	3.0
<i>Clarias gariepinus</i>	OL	16.5	−18.6	3.9
<i>Clarias gariepinus</i>	ED	13.0	−19.3	11.0
<i>Clarias gariepinus</i>	ED	10.9	−20.3	9.6
<i>Clarias gariepinus</i>	ED	13.4	−20.0	7.4
<i>Clarias gariepinus</i>	ED	13.3	−19.7	10.1
<i>Clarias gariepinus</i>	ED	15.1	−20.1	4.7
<i>Clarias gariepinus</i>	ON	13.6	−19.8	4.9
<i>Clarias gariepinus</i>	ON	12.8	−18.2	4.1
<i>Clarias gariepinus</i>	ON	13.5	−18.7	2.9
<i>Clarias gariepinus</i>	ON	12.0	−18.2	4.8
<i>Clarias gariepinus</i>	ON	14.7	−19.0	3.8
<i>Clarias gariepinus</i>	ON	13.0	−18.3	2.3
<i>Hydrocynus vittatus</i>	CR	13.9	−19.3	6.2
<i>Hydrocynus vittatus</i>	CR	13.9	−15.2	3.0
<i>Hydrocynus vittatus</i>	CR	14.1	−15.5	3.4
<i>Hydrocynus vittatus</i>	CR	13.0	−14.0	2.7
<i>Hydrocynus vittatus</i>	CR	15.0	−17.6	5.3
<i>Hydrocynus vittatus</i>	CR	13.2	−14.5	4.5
<i>Hydrocynus vittatus</i>	OL	15.9	−20.3	4.1
<i>Hydrocynus vittatus</i>	OL	17.8	−21.4	3.2
<i>Hydrocynus vittatus</i>	OL	17.9	−21.0	2.2
<i>Hydrocynus vittatus</i>	OL	17.4	−18.7	4.2
<i>Hydrocynus vittatus</i>	OL	16.6	−19.1	2.8
<i>Hydrocynus vittatus</i>	OL	16.6	−19.2	3.4
<i>Hydrocynus vittatus</i>	OL	15.9	−19.4	2.3
<i>Hydrocynus vittatus</i>	OL	17.4	−20.8	2.8
<i>Hydrocynus vittatus</i>	OL	18.3	−21.1	2.8



Table A1. Continued.

Species	Site	$\delta^{15}\text{N}(\text{‰})_{\text{AIR}}$	$\delta^{13}\text{C}(\text{‰})_{\text{VPDB}}$	$\delta^{34}\text{S}(\text{‰})_{\text{VCDT}}$
<i>Hydrocynus vittatus</i>	OL	16.8	-20.0	2.0
<i>Hydrocynus vittatus</i>	OL	17.3	-20.5	2.7
<i>Hydrocynus vittatus</i>	OL	16.8	-19.3	2.9
<i>Hydrocynus vittatus</i>	OL	17.5	-21.1	1.7
<i>Hydrocynus vittatus</i>	ED	12.9	-17.5	9.8
<i>Hydrocynus vittatus</i>	ED	12.6	-20.1	8.9
<i>Hydrocynus vittatus</i>	ED	12.6	-20.2	12.0
<i>Hydrocynus vittatus</i>	ED	14.0	-19.3	8.0
<i>Hydrocynus vittatus</i>	ED	12.4	-20.3	11.9
<i>Hydrocynus vittatus</i>	ON	16.3	-20.0	3.0
<i>Hydrocynus vittatus</i>	ON	16.8	-20.0	2.4
<i>Hydrocynus vittatus</i>	ON	17.0	-21.8	1.1
<i>Hydrocynus vittatus</i>	ON	16.4	-20.7	1.7
<i>Hydrocynus vittatus</i>	ON	17.1	-21.7	2.5
<i>Glossogobius giuris</i>	OL	13.6	-22.0	...
<i>Glossogobius giuris</i>	OL	13.5	-21.5	...
<i>Glossogobius giuris</i>	OL	14.7	-22.4	...
<i>Glossogobius giuris</i>	OL	14.1	-17.6	...
<i>Labeo molybdinus</i>	OL	13.3	-21.2	3.1
<i>Labeo molybdinus</i>	OL	13.0	-24.8	4.0
<i>Labeo molybdinus</i>	OL	12.0	-21.7	7.7
<i>Labeo cylindricus</i>	OL	13.0	-22.0	6.6
<i>Labeobarbus marequensis</i>	OL	13.7	-17.6	12.8
<i>Labeobarbus marequensis</i>	OL	14.0	-16.6	11.8
<i>Labeobarbus marequensis</i>	OL	13.7	-17.7	12.0
<i>Labeobarbus marequensis</i>	ON	13.4	-22.2	2.7
<i>Labeobarbus marequensis</i>	ON	13.0	-21.4	3.1
<i>Labeobarbus marequensis</i>	ON	12.4	-22.9	3.8
<i>Labeobarbus marequensis</i>	ON	13.7	-21.5	3.8
<i>Labeobarbus marequensis</i>	ON	13.9	-21.2	3.7
<i>Labeobarbus marequensis</i>	ON	13.7	-20.1	3.7
<i>Labeobarbus marequensis</i>	ON	13.5	-20.8	3.6
<i>Labeobarbus marequensis</i>	ON	13.5	-20.0	3.9
<i>Labeobarbus marequensis</i>	ON	13.3	-19.7	3.3
<i>Labeobarbus marequensis</i>	ON	13.3	-20.4	4.5
<i>Microlestes acutidens</i>	OL	13.7	-15.7	11.2
<i>Oreochromis mossambicus</i>	OL	10.9	-12.6	8.6
<i>Oreochromis mossambicus</i>	OL	12.9	-15.3	7.2
<i>Oreochromis mossambicus</i>	ED	10.9	-18.3	10.9
<i>Oreochromis mossambicus</i>	ED	10.9	-19.9	10.7
<i>Chiloglanis paratus</i>	OL	16.8	-26.6	4.8
<i>Chiloglanis paratus</i>	OL	14.3	-18.4	11.8
<i>Chiloglanis paratus</i>	OL	14.2	-18.8	12.1
<i>Chiloglanis paratus</i>	OL	14.2	-18.5	14.3
<i>Chiloglanis paratus</i>	ED	12.8	-22.1	10.9
<i>Labeo molybdinus</i>	ED	12.1	-16.3	10.5
<i>Labeo molybdinus</i>	ED	11.3	-19.6	10.6
<i>Labeo molybdinus</i>	ON	12.8	-25.2	4.6
<i>Labeo molybdinus</i>	ON	12.3	-24.7	4.9
<i>Labeo cylindricus</i>	ON	13.6	-26.4	4.8
<i>Labeo cylindricus</i>	ON	12.9	-24.3	4.5
<i>Labeo cylindricus</i>	ON	13.3	-24.2	4.3
<i>Labeo cylindricus</i>	ON	12.3	-25.4	3.3
<i>Labeo cylindricus</i>	ON	12.4	-24.6	4.5
<i>Labeo cylindricus</i>	ON	13.2	-26.4	...
<i>Labeo cylindricus</i>	ON	13.5	-25.2	...
<i>Glossogobius giuris</i>	ED	12.4	-20.1	11.2
<i>Glossogobius giuris</i>	ED	12.3	-22.9	11.8
<i>Glossogobius giuris</i>	ED	11.9	-19.3	10.0
<i>Glossogobius giuris</i>	ED	11.4	-21.5	10.6
<i>Glossogobius giuris</i>	ED	11.5	-19.4	10.8
<i>Glossogobius giuris</i>	ED	12.1	-20.0	11.0
<i>Glossogobius giuris</i>	ED	11.7	-18.6	10.6
<i>Glossogobius giuris</i>	ED	11.6	-19.3	11.3
<i>Labeo spp.</i>	ON	12.1	-24.5	4.6
<i>Labeo spp.</i>	ON	12.1	-24.4	4.6
<i>Labeo spp.</i>	ON	12.1	-23.3	4.2
<i>Shilbe intermedius</i>	ON	12.0	-17.8	5.4

## APPENDIX B

Table B1. Isotopic values of aquatic invertebrates sampled from sites OM and OL in the Olifants and Letaba River systems in the Kruger National Park, South Africa.

Species	OM			OL		
	$\delta^{15}\text{N}$	$\delta^{13}\text{C}$	<i>n</i>	$\delta^{15}\text{N}$	$\delta^{13}\text{C}$	<i>n</i>
<i>Atiyidae</i>	...	...	...	10.5 ± 0.2	-16.8 ± 0.5	2
<i>Baetidae</i>	10.1 ± 1.3	-19.5 ± 0.7	7	9.3 ± 1.6	-21.6 ± 3.8	14
<i>Belastomatidae</i>	...	...	...	8.6 ± 0.9	-16.6 ± 0.9	5
<i>Coenagrionidae</i>	11.7 ± 0.4	-21.7 ± 0.6	5	10.2 ± 1.1	-20.1 ± 2.2	7
<i>Corbiculidae</i>	...	...	...	6.8	-18.1	1
<i>Gomphidae</i>	12.0 ± 0.4	-22.1 ± 0.6	2	10.7 ± 1.7	-18.7 ± 4.9	10
<i>Heptagenidae</i>	...	...	...	8.6	-23.6	...
<i>Hydropsychidae</i>	...	...	...	10.3 ± 1.2	-19.89 ± 2.1	7
<i>Leptoceridae</i>	11.0 ± 0.6	-21.5 ± 0.1	2	...	...	...
<i>Libellulidae</i>	...	...	...	9.8 ± 1.1	-22.0 ± 3.2	11
<i>Naucoridae</i>	11.9	-23.9	1	...	...	...
<i>Nepidae</i>	6.8	-20.8	1	10.0	-18.0	1
<i>Notonectidae</i>	11.6 ± 0.3	-22.0 ± 0.9	3	9.6 ± 0.3	-16.1 ± 0.2	4
<i>Physidae</i>	9.8 ± 0.3	-17.6 ± 1.8	3	...	...	...
<i>Pleuroceridae</i>	...	...	...	10.4 ± 1.5	-19.4 ± 5.3	5
<i>Simuliidae</i>	11.9	-24.6	1	...	...	...
<i>Tabanidae</i>	...	...	...	12.6 ± 0.2	-24.8 ± 1.4	2
<i>Vellidae</i>	8.0 ± 3.4	-19.5 ± 0.8	2	10.5 ± 0.2	-9.5 ± 3.0	12

Table B2. Isotopic values of aquatic invertebrates sampled from sites ED and ON in the Olifants and Letaba River systems in the Kruger National Park, South Africa.

Species	ED			ON		
	$\delta^{15}\text{N}$	$\delta^{13}\text{C}$	<i>n</i>	$\delta^{15}\text{N}$	$\delta^{13}\text{C}(\text{‰})$	<i>n</i>
<i>Atiyidae</i>	8.7 ± 0.8	-19.9 ± 0.9	15	8.8 ± 1.3	-19.2 ± 2.7	7
<i>Coenagrionidae</i>	8.8 ± 0.5	-19.1 ± 0.8	3	...	...	...
<i>Gomphidae</i>	9.3 ± 0.8	-20.1 ± 1.7	2	10.4 ± 0.5	-18.1 ± 0.6	10
<i>Gyrinidae</i>	...	...	...	10.8 ± 0.4	-21.2 ± 1.2	7
<i>Heptagenidae</i>	7.5 ± 0.8	-15.9 ± 0.5	3	...	...	...
<i>Hydropsychidae</i>	...	...	...	9.6 ± 0.9	-18.7 ± 0.9	2
<i>Libellulidae</i>	...	...	...	9.8 ± 0.3	-18.4 ± 0.5	2
<i>Notonectidae</i>	7.9 ± 1.8	-20.9 ± 4.3	3	...	...	...
<i>Pleuroceridae</i>	7.8 ± 1.3	-20.4 ± 1.6	6	11.2 ± 0.3	-22.6 ± 2.2	8
<i>Sphaeridae</i>	6.9 ± 0.5	-23.6 ± 0.4	8	...	...	...
<i>Potomanautidae</i>	7.6 ± 2.9	-15.2 ± 3.5	2	...	...	...

Table B3. Isotopic values of aquatic invertebrates sampled from site CR in the Crocodile River in the Kruger National Park, South Africa.

Species	CR		
	$\delta^{15}\text{N}$	$\delta^{13}\text{C}(\text{‰})$	<i>n</i>
<i>Atiyidae</i>	10.7 ± 0.8	-18.4 ± 0.9	20
<i>Baetidae</i>	8.0 ± 0.7	-19.2 ± 2.0	24
<i>Coenagrionidae</i>	10.5 ± 0.3	-18.3 ± 0.5	5
<i>Dytiscidae</i>	9.7 ± 0.3	-17.9 ± 0.4	6
<i>Gomphidae</i>	10.5 ± 0.6	-17.8 ± 0.7	13
<i>Gyrinidae</i>	9.5 ± 0.4	-17.9 ± 0.8	4
<i>Heptagenidae</i>	8.6 ± 0.5	-16.6 ± 1.5	8
<i>Hydropsychidae</i>	7.5	-19.1	1
<i>Muscidae</i>	9.4 ± 1.7	-19.8 ± 0.6	3
<i>Nepidae</i>	10.3	-18.9	1



Table B3. Continued.

Species	CR		n
	$\delta^{15}\text{N}$	$\delta^{13}\text{C}(\text{‰})$	
<i>Notonectidae</i>	9.0	-17.7	1
<i>Pleuroceridae</i>	10.0 ± 0.3	-17.8 ± 0.4	7
<i>Sphaeridae</i>	9.2	-18.4	1
<i>Tabanidae</i>	10.9	-19.5	1
<i>Vellidae</i>	9.5 ± 0.5	-18.3 ± 0.8	2
<i>Potomanautidae</i>	10.6	-17.8	1

## APPENDIX C

Table C1. Stomach content analysis for fish sampled in the Kruger National Park, South Africa.

Site	Date	Fish	Steatitis			Healthy			
			Invertebrate and mixed detritus	Vegetation	Empty	Fish	Invertebrate and mixed detritus	Vegetation	Empty
OL	Jun-09	1	0	0	2	2	3	0	1
OL	Aug-09	1	0	0	0	1	0	0	0
OL	Nov-09	5	0	1	3	4	1	0	7
OL	Jul-10	3	1	3	5	2	3	4	4
OL	Jan-11	9	2	0	0	9	2	0	0
OL	Jun-11	8	1	2	3	3	1	2	1
OM	Aug-09	4	0	0	1	3	1	0	3
ON	Jun-09	0	0	0	0	0	3	7	0
LKB	Jun-09	0	0	0	0	2	1	1	0
RV	Nov-09	0	0	1	0	3	2	5	12
RV	Jan-11	0	0	0	0	4	4	3	2
SP	Jul-10	4	0	0	1	5	0	0	1
ED	Jul-10	1	1	0	0	6	1	11	1
MW	Jul-10	0	0	1	0	3	0	13	3
FK	Jan-11	0	0	0	0	9	0	0	1
CR	Jun-11	0	0	0	0	0	2	15	3
LR	Jun-11	0	0	0	0	1	4	9	0

## APPENDIX D

Table D1. Isotopic values from diatoms, organics and riparian vegetation sampled from rivers in the Kruger National Park, South Africa.

Species	CR		OM		OL		LR		ON	
	$\delta^{15}\text{N}$	$\delta^{13}\text{C}$	$\delta^{15}\text{N}$	$\delta^{13}\text{C}$	$\delta^{15}\text{N}$	$\delta^{13}\text{C}$	$\delta^{15}\text{N}$	$\delta^{13}\text{C}$	$\delta^{15}\text{N}$	$\delta^{13}\text{C}$
Filamentous algae	7.5	-21.3	7.1	-16.9	6.6	-21.6	10.0	-15.8	6.0	-29.0
Diatoms	6.1	-20.7	13.1	-12.9	9.1	-18.3	3.7	-26.4	7.4	-19.6
Sediment	5.6	-18.8	6.8	-21.9	7.2	-19.7	5.3	-21.9	5.7	-19.9
Detritus	4.0	-16.1	...	...	6.4	-14.8	...	...	4.4	-15.7
Vegetation	4.2	-13.3	7.1	-31.6	9.0	-26.2	...	...	9.2	-13.2
Vegetation	...	...	10.3	-12.1	...	...	...	...	9.0	-27.3
Phragmites	8.1	-26.5	6.4	-12.0	14.1	-27.7	7.9	-27.5	8.8	-27.2

## APPENDIX E

Table E1. Isotopic values from crocodile claws sampled in the Kruger National Park, South Africa.

Location	$\delta^{15}\text{N}$	$\delta^{13}\text{C}$	<i>n</i>	$\delta^{34}\text{S}$
Olifants River Gorge	12.5 ± 0.4	-19.9 ± 0.3	81	5.1
Olifants River Gorge	12.4 ± 0.6	-20.6 ± 0.1	125	6.8
Olifants River Gorge	12.4 ± 0.3	-21.0 ± 0.7	76	...
Olifants River Gorge	13.1 ± 0.5	-19.4 ± 0.2	44	9.1
Olifants River Gorge	12.6 ± 0.5	-19.2 ± 0.4	15	...
Olifants River Gorge	11.6 ± 0.3	-19.7 ± 0.9	54	...
Olifants River, Mamba Weir	8.7 ± 0.6	-15.5 ± 1.1	53	6.5
Olifants River, Mamba Weir	10.0 ± 0.7	-17.8 ± 0.5	45	6.4
Letaba River, Engelhard Dam	9.6 ± 0.3	-18.1 ± 0.8	63	13.9
Letaba River, Hlanganini Inlet	9.6 ± 0.5	-20.5 ± 0.4	40	13.7
Levuvhu River	10.1 ± 0.3	-16.0 ± 0.8	77	12.0
Levuvhu River	10.9 ± 0.2	-16.7 ± 0.8	48	12.5
Shingwedzi River, Kannidood Dam	9.6 ± 0.6	-16.6 ± 0.8	70	13.3
Shiloweni Dam	11.0 ± 0.4	-14.8 ± 0.9	115	14.2
Shiloweni Dam	11.2 ± 0.6	-14.8 ± 0.6	67	13.6
Sabie River, Lower Sabie Weir	8.2 ± 0.4	-12.5 ± 0.8	88	11.5
Crocodile River	11.1 ± 0.6	-19.9 ± 0.6	53	7.7
Crocodile River	9.8 ± 0.4	-16.1 ± 1.2	84	8.9

# Comparison of the lipid properties of healthy and pansteatitis-affected African sharptooth catfish, *Clarias gariepinus* (Burchell), and the role of diet in pansteatitis outbreaks in the Olifants River in the Kruger National Park, South Africa

K D A Huchzermeyer<sup>1,2</sup>, G Osthoff<sup>3</sup>, A Hugo<sup>3</sup> and D Govender<sup>4</sup>

1 Sterkspruit Veterinary Clinic, Lydenburg, South Africa

2 Department of Paraclinical Sciences, Faculty of Veterinary Science, University of Pretoria, Pretoria, South Africa

3 Department of Microbial, Biochemical and Food Biotechnology, University of the Free State, Bloemfontein, South Africa

4 Veterinary Wildlife Services, South African National Parks, Skukuza, South Africa

## Abstract

Pansteatitis has been identified in wild populations of sharptooth catfish, *Clarias gariepinus* (Burchell), and Nile crocodiles, *Crocodylus niloticus* Laurenti, inhabiting the same waters in the Olifants River gorge in the Kruger National Park, South Africa. Mesenteric and pectoral fat tissue was investigated microscopically and by fatty acid analysis in healthy and pansteatitis-affected catfish from both captive and wild populations. Variation in fatty acid composition between pectoral and mesenteric fat was noted. Composition of mesenteric fat differed between fish from various localities as a result of differences in diet. Pansteatitis in the captive population, resulting from ingestion of high amounts of dietary oxidized fat, reflected higher levels of unsaturated fatty acids within the mesenteric fat. Mesenteric fat of pansteatitis-affected wild catfish was characterized by an increase in moisture content, a decrease in fat content and a decrease in stearic and linoleic acids. The n-3 to n-6 fatty acid ratio of mesenteric fat was higher in pansteatitis-affected wild catfish than in healthy catfish from the same locality, reflecting higher polyunsaturated fat intake by pansteatitis-affected fish. The possible role of alien, invasive,

phytoplankton-feeding silver carp, *Hypophthalmichthys molitrix* (Valenciennes), in the aetiology of pansteatitis in both catfish and crocodiles in the Olifants Gorge is discussed.

**Keywords:** *Clarias gariepinus*, lipid properties, pansteatitis, polyunsaturated fat, sharptooth catfish, silver carp.

## Introduction

During the winter of 2008, carcasses of more than 170 Nile crocodiles, *Crocodylus niloticus* Laurenti, were found close to the confluence of the Olifants and Letaba Rivers in the Kruger National Park (KNP) in South Africa (Anon 2008; Ferreira & Pienaar 2011). The cause of death was established to be a consequence of severe pansteatitis. Further crocodile mortalities occurred during subsequent winters, but in smaller numbers. Both rivers have their catchments in industrial and agricultural areas, before they enter the Kruger National Park. The Letaba River flows 97 km through the Park, and the Olifants River for some 90 km, where they join (the confluence 23°59'21.8"S 31°49'35.6"E) and flow a further 9 km through the Olifants River gorge before crossing into Mozambique, entering the upper reaches of Lake Massingir. Extensive sampling of fish from the Olifants River gorge has led to the discovery that

**Correspondence** K D A Huchzermeyer, Sterkspruit Veterinary Clinic, PO Box 951, Lydenburg 1120, South Africa (e-mail: aquavet@telkomsa.net)

pansteatitis also affected African sharptooth catfish, *Clarias gariepinus* (Burchell), inhabiting this section of the Olifants River (Huchzermeyer *et al.* 2011). Hydrodynamic change in the Olifants River gorge, brought about by the raising of the sluices of Lake Massingir downstream of the gorge, resulted in the inlet of Lake Massingir extending back into the Olifants Gorge, flooding the previously fast flowing rapids and pools of the gorge. Most of the dead and affected crocodiles were found in both rivers from about 10 km upstream of the confluence, up to the border with Mozambique in the same stretch of river where pansteatitis-affected catfish have been found. It has been speculated that pollutants may be concentrated in the clay deposits trapped by dams along the Olifants River (Heath, Coleman & Engelbrecht 2010) that, when released over time due to local changes in water quality, could be the inciting cause of the crocodile and fish mortalities. High phosphate levels attributed to the discharge of tailings from a phosphate mine and to municipal sewerage spills into the Olifants River near the town of Phalaborwa on the western boundary of KNP prior to 2004 (J. Venter, SANParks, Skukuza, personal communication 2012) have contributed to the nutrient enrichment of Lake Massingir.

Pansteatitis, also called yellow fat disease, has been reported in a variety of animals such as rainbow trout, *Oncorhynchus mykiss* (Walbaum) (Roberts, Richards & Bullock 2006), Sunapee trout, *Salvelinus alpinus oquassa* Girard (Herman & Kircheis 1985), channel catfish, *Ictalurus punctatus* (Rafinesque) (Goodwin 2006), white sturgeon *Acipenser transmontanus* Richardson (Guarda *et al.* 1997), Atlantic halibut *Hippoglossus hippoglossus* L. (Bricnell *et al.* 1996), northern bluefin tuna *Thunnus thynnus* (L.) (Roberts & Agius 2008), red-tailed hawk *Buteo jamaicensis* (Gmelin) (Wong *et al.* 1999), boat billed herons *Cochlearius cochlearius* (L.) (Pollock *et al.* 1999), the domestic cat (Niza, Vilela & Ferreira 2003), wild rabbit (Jones, Howard & Gresham 1969), marmoset, *Callithrix* spp. (Juan-Sallés *et al.* 2003), Amazon River dolphin *Inia geoffrensis* (Blainville) (Bonar & Wagner 2003) and Nile crocodile (Huchzermeyer 2003; Osthoff *et al.* 2010). The occurrence and pathology of pansteatitis in sharptooth catfish in the Olifants River has been described by Huchzermeyer *et al.* (2011). The term yellow fat disease may be misleading in this species as sharptooth catfish naturally show a variable fat colour.

Pansteatitis is defined as a nutritional disorder characterized by necrosis and inflammation of adipose tissue and deposition of a ceroid pigment within macrophages in the associated inflammatory reaction. The disease is linked to the consumption of high levels of unsaturated fatty acids and is exacerbated by intake of oxidized fats and depletion of vitamin E (Scott, Miller & Griffin 1995; Fytianou *et al.* 2006). In many species, the condition can be induced by vitamin E deficiency (Farwer *et al.* 1994). Unsaturated fatty acids in the lipids of cell membranes are vulnerable to oxidation through cyclic reduction–oxidation of oxidants resulting in the formation of lipid hydroperoxides (Bus, Aust & Gibson 1976). Lipid free radicals released from decomposition of lipid hydroperoxides initiate the subsequent lipid peroxidation of cell membranes (Bus *et al.* 1976). A lack of vitamin E may result in an accumulation of reactive peroxides in the tissue, which may lead to pansteatitis (Case, Carey & Hirakawa 1995). Treatment with vitamin E may alleviate the disease (Niza *et al.* 2003), but this is not always the case (Bonar & Wagner 2003; Juan-Sallés *et al.* 2003). The effect of pansteatitis on fatty acid composition has not been described by many researchers. Farwer *et al.* (1994) provided evidence that vitamin E depletion affected the fatty acid composition of liver lipids, and Fytianou *et al.* (2006) showed that the fatty acid composition of adipose tissue is affected by pansteatitis. Osthoff *et al.* (2010) have shown that the lipids of adipose tissue of healthy wild crocodiles differed minimally in the fatty acid composition from diseased ones and that the observed hardness of the fat tissue was not due to changes in fat composition, but rather to high moisture content, the result of physiological changes induced by interstitial inflammation similar to that observed by Niza *et al.* (2003).

Analysis of the fat composition of captive-raised African sharptooth catfish (Hoffman & Prinsloo 1995) and a comparison with the neutral lipids of heart muscle of free-living catfish in Ugandan lakes (Kwetegeyeka *et al.* 2011) showed that fatty acid composition of the total fat of captive fish and that of the heart muscle fat of free-living fish was similar. Captive fish were, however, found to contain higher levels of 20:4n3 and lower levels of 18:1 isomers than wild fish (Hoffman & Prinsloo 1995), and the fatty acid composition of the heart muscle fat differed between fish of different

localities (Kwetegeyeka *et al.* 2011). This comparison could not conclude whether the difference was due to tissue type, locality or diet. However, Steffens (1997) has reported the effect of diet on fatty acid composition. The effect of diet and health conditions on the fat composition of sharp-tooth catfish has not been reported before. The aim of our study was to determine the impact of pansteatitis on the fat composition of captive and wild African sharp-tooth catfish and to link this to dietary factors affecting the two populations.

### Materials and methods

During November 2009, a minimum of 20 sharp-tooth catfish were collected from each of three geographically distinct populations: Olifants River Gorge (OG) [23°59'21.8"S 31°49'35.6"E] in the vicinity of the confluence between the Letaba and Olifants rivers in the area regarded as the epicentre of the crocodile mortalities in the KNP; Reenvoël Dam (RV) [23°58'37.2"S 31°19'38.4"E], a rain-filled dam with its entire catchment within KNP; and Lunsklip Fisheries (LK) [25°23'08,9"S 30°15'35"E] on the Lunsklip River near Lydenburg in Mpumalanga Province. Wild fish were caught on baited hook and line. The fish from LK represented remnants of a farmed population of fish and were caught by scoop net.

The LK population of captive catfish was fed an exclusive diet of untreated trout slaughterhouse waste. Since the collapse of the catfish industry many years ago, these fish were no longer used commercially and hence remained in the system reaching a considerable body size. The slaughterhouse waste was made up to a large extent of fat-rich innards of slaughtered trout and was fed in such excess that at any given time a significant amount of waste could be observed uneaten and decomposing in the water.

Fish were killed by an overdose of benzocaine in the holding water. Detailed data sets were collected from all fish and included length and weight measurements, sex determination, macroscopic and histological descriptions of all organs, including adipose tissues. Age determinations were carried out according to the method of Weyl & Booth (2008) using sagittal otolith sections. In addition, samples of the two major adipose tissues, intra-abdominal mesenteric fat and hypodermal fat from the fat cushion behind the pectoral fin, were collected. The sharp-tooth catfish is unique in

that an extension of both the liver and the marrow or haemopoietic part of the anterior kidney extend through the body wall to lie bilaterally under a hypodermal fat cushion just caudal to the pectoral fin. Tissue samples for fat analyses were collected from those fish with adequate fat reserves and were kept on ice until samples could be frozen before being sent to the laboratory. All tissue samples were kept frozen until preparation for fat extraction, which was carried out within 5 days. Tissue samples for histological examination were immediately fixed in 10% buffered formalin before being processed by standard histological techniques. Five-micron-thick tissue sections stained with haematoxylin eosin and Gomori's aldehyde fuchsin were examined under the light microscope. Severity of pathology in the adipose tissues was scored histologically on a scale of 1–4, with 1 representing no steatitis or the presence of only a few lipopigment-containing macrophages in the fat tissue, but without necrosis of adipocytes and 4 showing the greatest degree of necrosis and inflammation.

Extraction of total fat from tissue samples was performed quantitatively according to Folch, Lees & Sloane-Stanley (1957) using chloroform and methanol in a ratio of 2:1. Total extractable fat content was determined gravimetrically and expressed as g fat per 100 g tissue.

Fatty acids were transesterified to form methyl esters (FAME) using 0.5 N NaOH in methanol and 14% boron trifluoride in methanol (Park & Goins 1994). The FAME were quantified using a Varian 430 flame ionization gas chromatograph (Varian), with a fused silica capillary column, Varian CPSIL 88 (100 m length, 0.25 mm ID, 0.2- $\mu$ m film thickness) (Varian). The column temperature was 40–230 °C (hold 2 min; ramp 4 °C min<sup>-1</sup>; hold 10 min). The FAME in hexane (1  $\mu$ L) was injected into the column using a Varian CP-8400 Autosampler (Varian) with a split ratio of 100:1. The injection port and detector were both maintained at 250 °C. Hydrogen was used as the carrier gas at 45 psi, and nitrogen was the make-up gas. Chromatograms were recorded using Galaxy, Chromatography, Data System (Varian). Identification of sample FAME was made by comparing the relative retention times of FAME peaks from samples with those of standards of all 37 fatty acids obtained from Supelco (Supelco 37 Component Fame Mix 47885-U; Supelco).



1 Significant differences in means amongst groups  
2 were determined using analysis of variance (ANOVA)  
3 and multiple comparisons using the Tukey–  
4 Kramer test at  $\alpha = 0.05$  (Anon 2007).

## 5 Results and discussion

6 The fish sampled from RV showed no macro-  
7 scopic signs of pansteatitis and, apart from infesta-  
8 tion with a variety of parasites natural to this  
9 habitat, appeared healthy. Fish from this popula-  
10 tion ranged in age from 4 to 19 years, with both  
11 sexes being represented in the sampling.

12 Pansteatitis was found in both male and female  
13 fish sampled from the wild population in the OG  
14 and from the captive population from LK. In  
15 affected fish, lesions were predominantly found in  
16 the mesenteric fat reserves. Only a few fish  
17 showed lesions in other fat reserves, including the  
18 pectoral and hypodermal fat, as well as in fat  
19 surrounding the brain. Steatitis was never observed  
20 in the pericardial fat. No correlation was observed  
21 between age or sex and the presence of pansteatitis  
22 in either the wild or captive catfish.

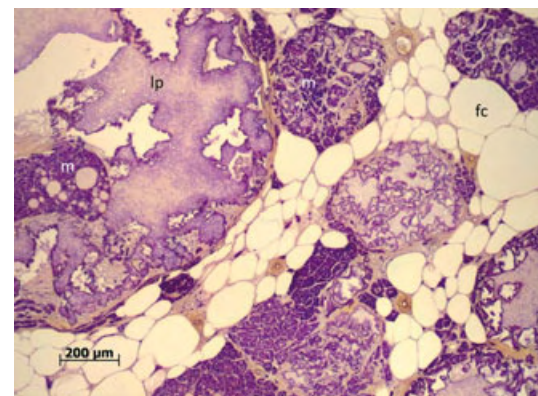
23 In the OG fish, ratio of adipose tissue to body  
24 mass showed little correlation with the presence of  
25 pansteatitis, lesions being present in both fat and  
26 lean fish. In contrast, easy access to fat-rich food  
27 in the captive fish population from LK was  
28 reflected in a significantly higher adipose tissue to  
29 body mass ratio than in fish from the OG. From  
30 the results of the captive fish, it is evident that  
31 pansteatitis is not rapidly fatal in these fish, even  
32 though the condition may be debilitating. When  
33 pansteatitis-affected and healthy fish were kept  
34 together in the same tank, clear behavioural differ-  
35 ences were observed, the former being slower in  
36 finding and taking feed (D. Huchzermeyer, per-  
37 sonal observation, 2011).

38 Comparisons of stomach and intestinal content  
39 of fish sampled from the different locations indi-  
40 cated that the sharptooth catfish in OG preyed  
41 heavily on other fish, whereas the ingesta of fish  
42 from RV reflected a more omnivorous diet  
43 consisting of a combination of plants, algae and  
44 invertebrates. Stomach content of the LK fish  
45 consisted exclusively of decomposing oily fish  
46 remnants.

47 The detailed pathology of pansteatitis in sharp-  
48 tooth catfish from the OG has been described by  
49 Huchzermeyer *et al.* (2011). Histological lesions  
50 of pansteatitis were similar in the OG and LK

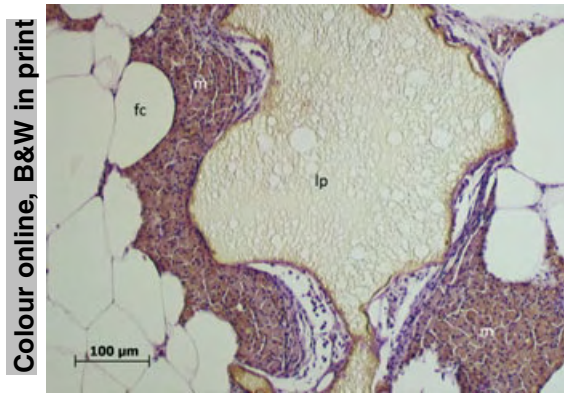
fish. Lesions consisted of ruptured adipocytes sur-  
rounded by an intense, predominantly macro-  
phage reaction (Figs 1 & 2). Macrophages stained  
positively for ceroid, a breakdown product of fat,  
in Gomori's aldehyde fuchsin stained sections  
(Fig. 1). Coalescing remnants of necrotic fat cells  
consisted of a refractive yellow staining lipopig-  
ment, a fat cell breakdown product, in haemat-  
oxylin–eosin-stained preparations (Fig. 2). The  
same refractive pigment could be observed in  
macrophages associated with such areas of fat cell  
necrosis. Fat cell necrosis appeared in distinct foci  
disseminated through the affected adipose tissue.  
Such foci were surrounded by macrophages and  
foreign body giant cells, which in areas coalesced  
to form epithelioid-like sheaths surrounding lipo-  
pigment-containing lacunae. The mononuclear  
cellular (predominantly macrophage) infiltrate  
associated with the inflammatory process may  
have been responsible for the higher moisture con-  
tent observed in affected fat.

The severest pansteatitis lesions were observed  
in older, larger fish specimens. In crocodiles, a  
similar trend was noted with degree of pansteatitis  
appearing to be related to size and therefore to  
age (Osthoff *et al.* 2010). On histological exami-  
nation, the granulomatous inflammation observed  
surrounding necrotic and ruptured fat cells in  
pansteatitis-affected catfish was similar to that  
noted in pansteatitis-affected crocodiles (Osthoff  
*et al.* 2010).



**Figure 1** Section of fat from a *Clarias gariepinus* specimen with steatitis, sampled from the Olifants River gorge during November 2009, stained specifically for the presence of ceroid with Gomori's aldehyde fuchsin. Note ceroid-positive staining of macrophages (m) and fat cell breakdown products. Lipopigment (lp), fat cell (fc).

Colour online, B&W in print



**Figure 2** Section of fat from a *Clarias gariepinus* specimen suffering from steatitis sampled from Lunsclip Fisheries during November 2009. Note fat breakdown product with lipopigment (lp) surrounded by macrophages (m). Fat cell (fc). Haematoxylin–eosin.

The fat composition of healthy fish (not affected by pansteatitis) from the three localities, LK, RV and OG is given in Table 1. The mean fatty acid composition of these catfish was in the same order of magnitude as that published by Hoffman & Prinsloo (1995). The monounsaturated acids were found to be higher than the published data, above 36%, mainly due to 16:0, and the levels of polyunsaturated acids were lower, <27% compared with the more than 35% reported. This difference might be ascribed to diet, because the fatty acids of the catfish from the three localities differed significantly (from  $P < 0.001$  to  $P < 0.05$ ) amongst each other (Table 1). The greatest differences were observed between the total polyunsaturated fatty acids, mainly due to 18:3c9, 12, 15(n-3), with  $1.75\% \pm 0.68$ ,  $1.11\% \pm 0.28$  and  $7.78\% \pm 1.20$  for LK, OG and RV respectively, and 20:4c5, 8, 11, 14(n-6), with  $0.54\% \pm 0.02$ ,  $1.01\% \pm 0.18$  and  $2.72\% \pm 0.66$ . Significant differences were also noted in monounsaturated fatty acids, the greatest being in 18:1c9, with respectively  $23.71\% \pm 0.48$ ,  $30.62\% \pm 4.35$  and  $16.03\% \pm 2.88$ . Smaller differences were noted in the content of 18:1c7, 15:0, 17:0 and 18:0. At a lower level of statistical significance, several more differences in fatty acid composition were noted, most obviously in the total unsaturated and polyunsaturated fatty acids. Differences in fatty acid content that might be ascribed to locality, and probably a difference in diet, were similarly reported for heart fat of various fish, including the catfish (Kwete-gyeka *et al.* 2011). Of interest is that the moisture

content of the fat tissue of fish from OG was lower than that of the other two localities ( $P < 0.043$ ), although the fat content and fat-free dry matter was the same. These results show that the fat of healthy and pansteatitis-affected catfish from the three localities have to be interpreted separately.

The fat composition of normal mesenteric and pectoral fat of captive catfish (LK) is shown in Table 2. Small but statistically significant ( $P < 0.001$ ) differences in content of 14:0, 18:0, 18:1c9, 22:0, 20:5c5, 8, 11, 14, 17(n-3) and 24:1c15 were observed. At a lower statistical significance,  $P < 0.05$ , more differences in fatty acid composition became apparent. The total saturated fatty acid content of mesenteric fat was higher than that of pectoral fat,  $36.37\% \pm 3.89$  vs.  $33.95\% \pm 3.27$ , whilst the total polyunsaturated content was lower,  $26.70\% \pm 3.80$  vs.  $30.70\% \pm 3.14$ . Mesenteric fat had a higher content of total monounsaturated and lower content of total omega-3 fatty acids, and also a lower content of the very long-chain fatty acids, longer than 18 carbon length, than pectoral fat. The fat content of mesenteric fat tissue was higher than that of pectoral fat tissue,  $78.46\% \pm 6.92$  vs.  $69.55\% \pm 4.19$  and the water content lower,  $16.01\% \pm 3.21$  vs.  $21.86\% \pm 4.44$ . Similar differences in fatty acid composition of fat of different body locations have been observed in other animals (Sinclair & O’Dea 1987).

In contrast to mesenteric fat, which frequently showed extensive areas of fat necrosis in pansteatitis-affected fish, the pectoral fat only rarely showed foci of fat necrosis. Little difference, as assessed by histological appearance and fat composition of pectoral fat, was observed between the healthy and pansteatitis-affected catfish. Differences observed between mesenteric and pectoral fat might be due to the specific function of the pectoral fat, which is embedded in a connective tissue matrix giving it a spongy feel. This suggests a protective rather than a metabolic function, as the pectoral fat overlies the area behind the pectoral fin where both the liver and anterior kidney extend through a fine canal in the musculature of the body wall to lie subdermally behind the pectoral fin. This is a unique and peculiar feature of sharptooth catfish that is shared with few other fish species. The higher water content of pectoral fat may explain the slightly glassy gross appearance of pectoral fat when compared to mesenteric fat.

**Table 1** Analysis of variance (ANOVA) on the effect of locality on chemical composition, fatty acid composition and fatty acid ratios of mesenteric fat of fish with a steatitis score of 1

Locality		LK (n = 3)	OG (n = 7)	RV (n = 4)	Significance level
Proximate analysis (%)					
% Fat		78.46 ± 6.92	85.75 ± 3.08	79.55 ± 8.08	P = 0.129
% Fat-free dry matter		5.53 ± 4.14	6.92 ± 0.86	8.91 ± 1.30	P = 0.119
% Moisture		16.01 ± 3.21 <sup>b</sup>	7.33 ± 2.96 <sup>a</sup>	11.54 ± 6.85 <sup>ab</sup>	P = 0.043
FAME (% of total fatty acids)					
Common name	Abbreviation				
Myristic	C14:0	3.41 ± 0.59 <sup>b</sup>	2.37 ± 0.49 <sup>a</sup>	2.05 ± 0.55 <sup>a</sup>	P = 0.016
Pentadecylic	C15:0	0.43 ± 0.12 <sup>a</sup>	0.43 ± 0.08 <sup>a</sup>	1.03 ± 0.18 <sup>b</sup>	P < 0.001
Palmitic	C16:0	27.05 ± 3.49	29.09 ± 3.90	28.79 ± 1.75	P = 0.679
Palmitoleic	C16:1c9	8.17 ± 0.64 <sup>b</sup>	5.89 ± 0.56 <sup>a</sup>	7.53 ± 1.43 <sup>b</sup>	P = 0.006
Margaric	C17:0	0.40 ± 0.12 <sup>a</sup>	0.64 ± 0.09 <sup>a</sup>	2.77 ± 0.35 <sup>b</sup>	P < 0.001
Heptadecenoic	C17:1c10	0.38 ± 0.10 <sup>b</sup>	0.07 ± 0.02 <sup>a</sup>	0.11 ± 0.01 <sup>a</sup>	P < 0.001
Stearic acid	C18:0	4.33 ± 0.48 <sup>a</sup>	6.93 ± 0.72 <sup>b</sup>	6.26 ± 0.26 <sup>b</sup>	P < 0.001
Elaidic	C18:1t9	0.31 ± 0.13 <sup>b</sup>	0.03 ± 0.02 <sup>a</sup>	0.15 ± 0.09 <sup>a</sup>	P < 0.001
Oleic	C18:1c9	23.71 ± 0.48 <sup>b</sup>	30.62 ± 4.35 <sup>c</sup>	16.03 ± 2.88 <sup>a</sup>	P < 0.001
Vaccenic	C18:1c7	4.25 ± 0.27 <sup>b</sup>	3.47 ± 0.11 <sup>a</sup>	6.14 ± 0.71 <sup>c</sup>	P < 0.001
Linoleic	C18:2c9,12 (n-6)	13.14 ± 1.80 <sup>b</sup>	8.11 ± 2.96 <sup>a</sup>	6.78 ± 0.90 <sup>a</sup>	P = 0.012
Arachidic	C20:0	0.18 ± 0.02 <sup>a</sup>	0.27 ± 0.04 <sup>ab</sup>	0.33 ± 0.08 <sup>b</sup>	P = 0.009
γ-Linolenic	C18:3c6,9,12 (n-6)	0.35 ± 0.11 <sup>ab</sup>	0.20 ± 0.08 <sup>a</sup>	0.56 ± 0.23 <sup>b</sup>	P = 0.006
α-Linolenic	C18:3c9,12,15 (n-3)	1.75 ± 0.68 <sup>a</sup>	1.11 ± 0.28 <sup>a</sup>	7.78 ± 1.20 <sup>b</sup>	P < 0.001
Heptacosanoic	C21:0	0.49 ± 0.11	0.73 ± 0.55	1.14 ± 0.29	P = 0.167
Eicosadienoic	C20:2c11,14 (n-6)	0.77 ± 0.03 <sup>b</sup>	0.41 ± 0.13 <sup>a</sup>	0.82 ± 0.15 <sup>b</sup>	P < 0.001
Behenic	C22:0	0.08 ± 0.01 <sup>a</sup>	0.11 ± 0.02 <sup>a</sup>	0.29 ± 0.11 <sup>b</sup>	P < 0.001
Eicosatrienoic	C20:3c11,14,17 (n-3)	0.47 ± 0.10 <sup>a</sup>	0.44 ± 0.08 <sup>a</sup>	0.76 ± 0.16 <sup>b</sup>	P = 0.002
Eicosatrienoic	C20:3c8,11,14 (n-6)	0.05 ± 0.02 <sup>a</sup>	0.14 ± 0.02 <sup>b</sup>	0.90 ± 0.09 <sup>c</sup>	P < 0.001
Arachidonic	C20:4c5,8,11,14 (n-6)	0.54 ± 0.02 <sup>a</sup>	1.01 ± 0.18 <sup>a</sup>	2.72 ± 0.66 <sup>b</sup>	P < 0.001
Eicosapentaenoic	C20:5c5,8,11,14,17 (n-3)	2.12 ± 1.29 <sup>ab</sup>	0.74 ± 0.25 <sup>a</sup>	2.69 ± 0.95 <sup>b</sup>	P = 0.004
Nervonic	C24:1c15	0.11 ± 0.02 <sup>b</sup>	0.01 ± 0.01 <sup>a</sup>	0.01 ± 0.01 <sup>a</sup>	P < 0.001
Docosapentaenoic	C22:5c7,10,13,16,19 (n-3)	1.81 ± 0.22	1.77 ± 0.71	1.75 ± 0.21	P = 0.990
Docosahexaenoic	C22:6c4,7,10,13,16,19 (n-3)	5.70 ± 1.39	5.41 ± 2.24	2.61 ± 0.63	P = 0.057
Fatty acid ratios					
Total Saturated Fatty Acids (SFA)		36.37 ± 3.89	40.57 ± 4.03	42.67 ± 1.03	P = 0.096
Total Mono-Unsaturated Fatty Acids (MUFA)		36.93 ± 0.50 <sup>ab</sup>	40.09 ± 3.85 <sup>b</sup>	29.95 ± 4.62 <sup>a</sup>	P = 0.004
Total Polyunsaturated Fatty Acids (PUFA)		26.70 ± 3.80 <sup>b</sup>	19.34 ± 0.89 <sup>a</sup>	27.38 ± 4.25 <sup>b</sup>	P < 0.001
Total Omega- 6 fatty acids (n-6)		14.85 ± 1.67 <sup>b</sup>	9.88 ± 2.93 <sup>a</sup>	11.79 ± 1.77 <sup>ab</sup>	P = 0.041
Total Omega- 3 fatty acids (n-3)		11.86 ± 2.13 <sup>ab</sup>	9.46 ± 2.86 <sup>a</sup>	15.59 ± 2.50 <sup>b</sup>	P = 0.012

Means with different superscripts in the same row differ significantly.

Statistical comparison of pansteatitis-affected fish across localities is not possible due to the effects of different diets on fatty acid composition of the fat. Further comparison of fatty tissue in pansteatitis-affected fat will refer only to the mesenteric fat. The comparison of the fat composition of the fish from LK with different scores of pansteatitis is presented in Table 3. No significant differences at  $P < 0.001$  were observed between the fats from healthy and pansteatitis-affected fish. At a lower significance level, the saturated fatty acid content of healthy fish at LK, 36.37% ± 3.89 was higher than that of the fish with pansteatitis score 4, 32.49% ± 1.05, the main difference being in 16:0 and 17:0, whereas the total omega-6 content was lower, 14.85% ± 1.67 vs. 17.81% ± 1.42, with 18:2c9, 12 (n-6) being the main component. Although not statistically significant in all aspects, the fatty acid

composition of the fish with pansteatitis scores 2 and 3 resembled that of score 4 and may have been a reflection of the uniform prolonged exposure of the fish to oxidized fish waste in the diet. These results are in agreement with Farwer *et al.* (1994) who found that pansteatitis in rats, which was induced by a depletion of vitamin E and a diet high in unsaturated fatty acids, was characterized by lower levels of saturated fatty acids and higher levels of unsaturated fats in the liver and serum. However, when pansteatitis was induced in cats due to a diet high in unsaturated fatty acids, a depletion of vitamin E resulted, and an increase in saturated fatty acids and a decrease in unsaturated fatty acids in the subcutaneous adipose tissue was noted (Fytianou *et al.* 2006). It therefore appears that the changes in tissue fat due to pansteatitis may vary amongst species.

**Table 2** Analysis of variance (ANOVA) on the effect of anatomical position (mesenteric vs. pectoral) of fat with a steatitis score of 1 on chemical composition, fatty acid composition and fatty acid ratios of fish from locality LK

Steatitis score		Mesenteric (n = 3)	Pectoral (n = 21)	Significance level	
Proximate analysis (%)					
	% Fat	78.46 ± 6.92	69.55 ± 4.19	P = 0.004	
	% Fat-free dry matter	5.53 ± 4.14	8.59 ± 1.57	P = 0.018	
	% Moisture	16.01 ± 3.21	21.86 ± 4.44	P = 0.040	
FAME (% of total fatty acids)					
	Common name	Abbreviation			
	Myristic	C14:0	3.41 ± 0.59	5.13 ± 0.71	P < 0.001
	Pentadecylic	C15:0	0.43 ± 0.12	0.50 ± 0.13	P = 0.372
	Palmitic	C16:0	27.05 ± 3.49	23.75 ± 2.41	P = 0.046
	Palmitoleic	C16:1c9	8.17 ± 0.64	9.35 ± 0.56	P = 0.003
	Margaric	C17:0	0.40 ± 0.12	0.32 ± 0.07	P = 0.133
	Heptadecenoic	C17:1c10	0.38 ± 0.10	0.53 ± 0.22	P = 0.255
	Stearic acid	C18:0	4.33 ± 0.48	3.36 ± 0.36	P < 0.001
	Elaidic	C18:1t9	0.31 ± 0.13	0.39 ± 0.14	P = 0.362
	Oleic	C18:1c9	23.71 ± 0.48	20.92 ± 0.96	P < 0.001
	Vaccenic	C18:1c7	4.25 ± 0.27	4.14 ± 0.15	P = 0.319
	Linoleic	C18:2c9,12 (n-6)	13.14 ± 1.80	15.12 ± 1.44	P = 0.041
	Arachidic	C20:0	0.18 ± 0.02	0.15 ± 0.02	P = 0.018
	γ-Linolenic	C18:3c6,9,12 (n-6)	0.35 ± 0.11	0.33 ± 0.10	P = 0.708
	α-Linolenic	C18:3c9,12,15 (n-3)	1.75 ± 0.68	1.45 ± 0.33	P = 0.197
	Heneicosanoic	C21:0	0.49 ± 0.11	0.73 ± 0.28	P = 0.163
	Eicosadienoic	C20:2c11,14 (n-6)	0.77 ± 0.03	0.70 ± 0.12	P = 0.310
	Behenic	C22:0	0.08 ± 0.01	0.01 ± 0.02	P < 0.001
	Eicosatrienoic	C20:3c11,14,17 (n-3)	0.47 ± 0.10	0.38 ± 0.06	P = 0.023
	Eicosatrienoic	C20:3c8,11,14 (n-6)	0.05 ± 0.02	0.06 ± 0.04	P = 0.535
	Arachidonic	C20:4c5,8,11,14 (n-6)	0.54 ± 0.02	0.66 ± 0.07	P = 0.011
	Eicosapentaenoic	C20:5c5,8,11,14,17 (n-3)	2.12 ± 1.29	4.02 ± 0.79	P = 0.001
	Nervonic	C24:1c15	0.11 ± 0.02	0.02 ± 0.03	P < 0.001
	Docosapentaenoic	C22:5c7,10,13,16,19 (n-3)	1.81 ± 0.22	1.64 ± 0.26	P = 0.284
	Docosahexaenoic	C22:6c4,7,10,13,16,19 (n-3)	5.70 ± 1.39	6.35 ± 1.44	P = 0.471
Fatty acid ratios					
	Total Saturated Fatty Acids (SFA)	36.37 ± 3.89	33.95 ± 3.27	P = 0.253	
	Total Mono-Unsaturated Fatty Acids (MUFA)	36.93 ± 0.50	35.35 ± 1.04	P = 0.018	
	Total Polyunsaturated Fatty Acids (PUFA)	26.70 ± 3.80	30.70 ± 3.14	P = 0.056	
	Total Omega- 6 fatty acids (n-6)	14.85 ± 1.67	16.86 ± 1.36	P = 0.028	
	Total Omega- 3 fatty acids (n-3)	11.86 ± 2.13	13.83 ± 2.30	P = 0.175	

Means with different superscripts in the same row differ significantly.

No difference in fat and moisture content was observed between the adipose tissues of healthy and pansteatitis-affected fish from LK. The data differ from results obtained from pansteatitis-affected crocodiles, in which fat tissue was found to have a higher moisture content and contain lower levels of 18:0 and 18:2c9, 12(n-6) than fat tissue of healthy crocodiles (Osthoft *et al.* 2010). High moisture content of pansteatitis-affected fat in crocodiles was thought to be associated with the extensive inflammatory reaction in the adipose tissues accompanying advanced pansteatitis. Although the mesenteric adipose tissue of pansteatitis-affected LK fish took on a rubbery consistency, an equivalent degree of inflammation and hardening of the adipose tissues to that observed in crocodiles was not present. According to Farwer *et al.* (1994), Scott *et al.* (1995) and

Fytianou *et al.* (2006) a decrease in unsaturated fatty acids may be due to oxidation, either by ingestion of oxidants or low levels of dietary vitamin E. In the case of the LK fish, the natural antioxidant capability of the catfish may have been overwhelmed by the excessively high unsaturated fat content in the trout slaughterhouse waste on which these fish had been fed over long periods of time.

Due to limited representatives of all pansteatitis scores of fish from OG, the data of scores 1 and 2 were pooled in one score group, whilst 3 and 4 were grouped together, and the fat composition of these are shown in Table 4. Similarly to the finding in crocodiles (Osthoft *et al.* 2010), the moisture content of fat in the higher pansteatitis score fish from OG appeared to be higher than that observed in fat with the lower score, 20.87% ± 14.49 vs. 7.33% ± 2.74.



**Table 3** Analysis of variance (ANOVA) on the effect of steatitis score of mesenteric fat on chemical composition, fatty acid composition and fatty acid ratios of fish from locality LK

Steatitis score		1 (n = 3)	2 (n = 5)	3 (n = 3)	4 (n = 10)	Significance level
Proximate analysis (%)						
	% Fat	78.46 ± 6.92	85.79 ± 2.87	83.70 ± 0.64	81.20 ± 4.80	P = 0.142
	% Fat-free dry matter	5.53 ± 4.14	4.07 ± 1.09	3.42 ± 1.48	5.03 ± 1.87	P = 0.537
	% Moisture	16.01 ± 3.21	10.13 ± 3.18	12.88 ± 1.23	13.77 ± 3.71	P = 0.122
FAME (% of total fatty acids)						
Common name	Abbreviation					
Myristic	C14:0	3.41 ± 0.59	3.63 ± 0.41	3.26 ± 0.13	3.68 ± 0.53	P = 0.546
Pentadecylic	C15:0	0.43 ± 0.12	0.35 ± 0.04	0.31 ± 0.02	0.34 ± 0.05	P = 0.077
Palmitic	C16:0	27.05 ± 3.49 <sup>b</sup>	23.75 ± 1.20 <sup>a</sup>	23.66 ± 1.02 <sup>a</sup>	23.57 ± 0.70 <sup>a</sup>	P = 0.015
Palmitoleic	C16:1c9	8.17 ± 0.64	8.54 ± 0.38	8.37 ± 0.35	8.65 ± 0.61	P = 0.579
Margaric	C17:0	0.40 ± 0.1 <sup>b</sup>	0.31 ± 0.04 <sup>ab</sup>	0.30 ± 0.02 <sup>ab</sup>	0.29 ± 0.02 <sup>a</sup>	P = 0.031
Heptadecenoic	C17:1c10	0.38 ± 0.10	0.51 ± 0.06	0.48 ± 0.03	0.47 ± 0.20	P = 0.729
Stearic acid	C18:0	4.33 ± 0.48	4.04 ± 0.28	4.17 ± 0.47	3.81 ± 0.51	P = 0.340
Elaidic	C18:1t9	0.31 ± 0.13	0.39 ± 0.11	0.31 ± 0.07	0.37 ± 0.15	P = 0.750
Oleic	C18:1c9	23.71 ± 0.48	24.28 ± 0.89	24.13 ± 0.69	23.53 ± 1.73	P = 0.753
Vaccenic	C18:1c7	4.25 ± 0.27	4.04 ± 0.34	3.99 ± 0.37	3.93 ± 0.21	P = 0.406
Linoleic	C18:2c9,12 (n-6)	13.14 ± 1.80 <sup>a</sup>	16.66 ± 0.91 <sup>b</sup>	15.66 ± 0.49 <sup>ab</sup>	16.32 ± 1.44 <sup>b</sup>	P = 0.008
Arachidic	C20:0	0.18 ± 0.02	0.15 ± 0.03	0.16 ± 0.04	0.15 ± 0.02	P = 0.208
γ-Linolenic	C18:3c6,9,12 (n-6)	0.35 ± 0.11	0.32 ± 0.07	0.30 ± 0.09	0.30 ± 0.04	P = 0.650
α-Linolenic	C18:3c9,12,15 (n-3)	1.75 ± 0.68	0.77 ± 0.24	1.14 ± 0.86	1.19 ± 0.59	P = 0.183
Heneicosanoic	C21:0	0.49 ± 0.11	0.64 ± 0.10	0.57 ± 0.07	0.59 ± 0.25	P = 0.775
Eicosadienoic	C20:2c11,14 (n-6)	0.77 ± 0.03	0.73 ± 0.05	0.75 ± 0.06	0.69 ± 0.06	P = 0.087
Behenic	C22:0	0.08 ± 0.01 <sup>b</sup>	0.04 ± 0.02 <sup>a</sup>	0.06 ± 0.01 <sup>ab</sup>	0.05 ± 0.01 <sup>ab</sup>	P = 0.022
Eicosatrienoic	C20:3c11,14,17 (n-3)	0.47 ± 0.10	0.40 ± 0.07	0.43 ± 0.06	0.38 ± 0.04	P = 0.097
Eicosatrienoic	C20:3c8,11,14 (n-6)	0.05 ± 0.02	0.02 ± 0.01	0.03 ± 0.03	0.02 ± 0.02	P = 0.224
Arachidonic	C20:4c5,8,11,14 (n-6)	0.54 ± 0.02	0.48 ± 0.06	0.47 ± 0.05	0.48 ± 0.04	P = 0.134
Eicosapentaenoic	C20:5c5,8,11,14,17 (n-3)	2.12 ± 1.29	2.70 ± 0.46	2.67 ± 0.16	2.90 ± 0.54	P = 0.349
Nervonic	C24:1c15	0.11 ± 0.02	0.09 ± 0.01	0.11 ± 0.02	0.11 ± 0.03	P = 0.461
Docosapentaenoic	C22:5c7,10,13,16,19 (n-3)	1.81 ± 0.22	1.58 ± 0.19	1.90 ± 0.18	1.71 ± 0.33	P = 0.414
Docosahexaenoic	C22:6c4,7,10,13,16,19 (n-3)	5.70 ± 1.39	5.60 ± 0.59	6.81 ± 0.90	6.46 ± 1.42	P = 0.424
Fatty acid ratios						
	Total Saturated Fatty Acids (SFA)	36.37 ± 3.89 <sup>b</sup>	32.90 ± 1.20 <sup>ab</sup>	32.47 ± 1.60 <sup>ab</sup>	32.49 ± 1.05 <sup>a</sup>	P = 0.023
	Total Mono-Unsaturated Fatty Acids (MUFA)	36.93 ± 0.50	37.85 ± 0.98	37.39 ± 1.13	37.06 ± 1.37	P = 0.628
	Total Polyunsaturated Fatty Acids (PUFA)	26.70 ± 3.80	29.26 ± 1.86	30.15 ± 2.34	30.45 ± 1.99	P = 0.131
	Total Omega- 6 fatty acids (n-6)	14.85 ± 1.67 <sup>a</sup>	18.21 ± 0.86 <sup>b</sup>	17.21 ± 0.51 <sup>ab</sup>	17.81 ± 1.42 <sup>b</sup>	P = 0.010
	Total Omega- 3 fatty acids (n-3)	11.86 ± 2.13	11.04 ± 1.11	12.94 ± 1.84	12.64 ± 1.65	P = 0.299

Means with different superscripts in the same row differ significantly. Steatitis score: 1 = 0–25%; 2 = 25–50%; 3 = 50–75%; 4 = 75–100%.

The fat content of fish from OG was found to be lower in fish with higher pansteatitis score than in those with lower score, 69.04% ± 18.49 vs. 85.71% ± 2.86, however, only at a significance value of  $P = 0.026$ . Relative to pansteatitis severity, the greatest differences in fatty acid composition of OG fish were noted amongst the respective levels of 22:5c7, 10, 13, 16, 19(n-3), 22:6c4, 7, 10, 13, 16, 19(n-3) and 18:2c9, 12(n-6). The omega-3 polyunsaturated fatty acids made up 9.28% ± 2.70 of total fatty acids in the lower pansteatitis score group compared with 16.79% ± 5.51 ( $P = 0.009$ ) in the higher pansteatitis score group. The opposite trend was observed for the omega-6 acids, with 10.4% ± 2.75 and 5.85% ± 1.08 ( $P = 0.017$ ) in the low and high pansteatitis groups, respectively. A significant difference between the two groups was

also noted in the content of 18:0 with 6.95% ± 0.67 vs. 4.06% ± 0.84, respectively. The lower fat and higher moisture content of the adipose tissue and the lower 18:0 and 18:2c9, 12(n-6) levels in the catfish with the high pansteatitis score is similar to that observed for the Nile crocodiles from the same waters reported by Osthoff *et al.* (2010). The increased firmness of the fat tissue observed in crocodiles (Osthoff *et al.* 2010) and catfish with advanced pansteatitis appears to be unrelated to fatty acid composition and is more likely a reflection of physiological changes associated with interstitial inflammation, as has also been observed in cats with pansteatitis (Niza *et al.* 2003). In catfish, however, the hardening of affected fat tissue was not as severe as that observed in crocodiles.

**Table 4** Analysis of variance (ANOVA) on the effect of steatitis score of mesenteric fat on chemical composition, fatty acid composition and fatty acid ratios of fish from locality OG

Steatitis score		1 + 2 ( <i>n</i> = 8)	3 + 4 ( <i>n</i> = 4)	Significance level
Proximate analysis (%)				
% Fat		85.71 ± 2.86	69.04 ± 18.49	<i>P</i> = 0.026
% Fat-free dry matter		6.96 ± 0.80	10.09 ± 4.23	<i>P</i> = 0.060
% Moisture		7.33 ± 2.74	20.87 ± 14.49	<i>P</i> = 0.023
FAME (% of total fatty acids)				
Common name	Abbreviation			
Myristic	C14:0	2.44 ± 0.50	2.04 ± 0.88	<i>P</i> = 0.338
Pentadecylic	C15:0	0.44 ± 0.08	0.36 ± 0.02	<i>P</i> = 0.085
Palmitic	C16:0	28.5 ± 83.89	30.67 ± 2.32	<i>P</i> = 0.350
Palmitoleic	C16:1c9	5.87 ± 0.52	7.43 ± 1.55	<i>P</i> = 0.024
Margaric	C17:0	0.63 ± 0.09	0.61 ± 0.17	<i>P</i> = 0.846
Heptadecenoic	C17:1c10	0.07 ± 0.02	0.15 ± 0.07	<i>P</i> = 0.018
Stearic acid	C18:0	6.95 ± 0.67	4.06 ± 0.84	<i>P</i> < 0.001
Elaidic	C18:1t9	0.03 ± 0.01	0.06 ± 0.04	<i>P</i> = 0.133
Oleic	C18:1c9	31.18 ± 4.32	26.48 ± 4.33	<i>P</i> = 0.106
Vaccenic	C18:1c7	3.45 ± 0.12	3.32 ± 1.05	<i>P</i> = 0.725
Linoleic	C18:2c9,12 (n-6)	8.29 ± 2.79	4.42 ± 1.05	<i>P</i> = 0.025
Arachidic	C20:0	0.26 ± 0.05	0.32 ± 0.09	<i>P</i> = 0.137
γ-Linolenic	C18:3c6,9,12 (n-6)	0.19 ± 0.07	0.32 ± 0.07	<i>P</i> = 0.013
α-Linolenic	C18:3c9,12,15 (n-3)	1.13 ± 0.27	1.10 ± 0.25	<i>P</i> = 0.853
Heinicosenoic	C21:0	0.68 ± 0.52	1.70 ± 0.75	<i>P</i> = 0.020
Eicosadienoic	C20:2c11,14 (n-6)	0.42 ± 0.12	0.26 ± 0.07	<i>P</i> = 0.037
Behenic	C22:0	0.10 ± 0.03	0.14 ± 0.10	<i>P</i> = 0.321
Eicosatrienoic	C20:3c11,14,17 (n-3)	0.44 ± 0.07	0.41 ± 0.16	<i>P</i> = 0.616
Eicosatrienoic	C20:3c8,11,14 (n-6)	0.14 ± 0.02	0.23 ± 0.08	<i>P</i> = 0.010
Arachidonic	C20:4c5,8,11,14 (n-6)	1.00 ± 0.17	0.62 ± 0.03	<i>P</i> = 0.002
Eicosapentaenoic	C20:5c5,8,11,14,17 (n-3)	0.72 ± 0.23	0.79 ± 0.26	<i>P</i> = 0.655
Docosapentaenoic	C22:5c7,10,13,16,19 (n-3)	1.90 ± 0.76	3.44 ± 1.35	<i>P</i> = 0.028
Docosahexaenoic	C22:6c4,7,10,13,16,19 (n-3)	5.09 ± 2.27	11.06 ± 4.47	<i>P</i> = 0.010
Fatty acid ratios				
Total Saturated Fatty Acids (SFA)		40.08 ± 3.98	39.92 ± 3.13	<i>P</i> = 0.946
Total Mono-Unsaturated Fatty Acids (MUFA)		40.60 ± 3.84	37.44 ± 6.29	<i>P</i> = 0.298
Total Polyunsaturated Fatty Acids (PUFA)		19.32 ± 0.83	22.65 ± 5.52	<i>P</i> = 0.111
Total Omega- 6 fatty acids (n-6)		10.04 ± 2.75	5.85 ± 1.08	<i>P</i> = 0.017
Total Omega- 3 fatty acids (n-3)		9.28 ± 2.70	16.79 ± 5.51	<i>P</i> = 0.009

Means with different superscripts in the same row differ significantly. Steatitis score: 1 + 2 = 0–50%; 3 + 4 = 50–100%.

The sharptooth catfish is a benthic opportunistic scavenger that is also known to hunt and prey actively on other fish (Skelton 2001). Food source varied distinctly between sampling sites, and prevalence of fish in the diet correlated with the presence of pansteatitis in free-living catfish from OG. Fish remnants observed in the stomach content of catfish from OG, often in an advanced stage of digestion, frequently consisted of bones and scales of noticeably large unidentified fish. Factors associated with a fish diet appeared to be associated with the development of pansteatitis in catfish in OG, but these must be distinct from a natural healthy fish diet as documented elsewhere in the literature (Spataru, Viveen & Gophen 1987).

An increase in dietary polyunsaturated fat intake has been reported to result in pansteatitis in various animals. A change in diet from smelt (6.7% fat) to mackerel (29.9% fat) was thought to be

the precipitating cause of pansteatitis in captive American alligators (Wallach & Hoessle 1968), whereas a change from Baltic and Mediterranean clupeids to Moroccan Atlantic pilchards was suspected to have been the cause of pansteatitis in northern bluefin tuna (Roberts & Agius 2008). Salmonid diets high in fish oils were found to induce steatitis in channel catfish (Goodwin 2006), and in cats, feeding of an oil-rich fish-based diet similarly induced pansteatitis (Fytianou *et al.* 2006). As a consequence of raising the dam wall of Lake Massingir, a habitat change in the OG occurred that may have favoured a change in access to certain species of fish not normally consumed in large numbers by crocodiles and catfish. This may have exposed these animals to levels of polyunsaturated fatty acids in the diet to which they were not adapted. Tiger fish, *Hydrocynus vittatus* Castelnau, sampled from the OG did not to



suffer from pansteatitis (D. Huchzermeyer, unpublished data). As obligate piscivores, tiger fish may have developed antioxidant protective mechanisms better enabling them to cope with the consumption of higher levels of dietary polyunsaturated fats than the omnivorous catfish.

The n-6 and n-3 fatty acids derived from linoleic and  $\alpha$ -linolenic acids, respectively, are essential fatty acids that cannot be synthesized by animals (Steffens 1997). The relative abundance of these fatty acids in the diet of animals is reflected in the composition of their fat tissues (Hoffman & Prinsloo 1995; Steffens 1997). The fatty acid composition of marine fish oils, and in particular the high n-3 to n-6 ratio of polyunsaturated fatty acids contained in these oils, is a reflection of the fatty acid composition of marine phytoplankton (Steffens 1997). Whereas the ratio of total n-3 to n-6 fatty acids in marine fish oils typically lies between 5 and more than 10 that of freshwater fish is much lower ranging from 1 to 4 (Steffens 1997). In freshwater fish, as in marine fish, these fatty acid ratios are influenced by the composition of the diet. In nutrition trials, the n-3 to n-6 fatty acid ratio in muscle lipid of sharp-tooth catfish could be manipulated from 0.1 in fish on a sunflower oil diet to 1.8 in fish on a cod liver oil diet (Hoffman & Prinsloo 1995). The fat of captive-farmed crocodiles, receiving a diet of chicken, beef and horse meat, had an n-3 to n-6 fatty acid ratio of 0.08 (Osthoff *et al.* 2010). By contrast, the n-3 to n-6 ratio of fatty acids in the fat of wild crocodiles suffering from pansteatitis from the Olifants and lower Letaba Rivers was found to be 2 (Osthoff *et al.* 2010). This reflected a much higher intake of n-3 fatty acids by crocodiles in the Olifants Gorge. Mean ratios of n-3 to n-6 fatty acids in catfish with mild or no pansteatitis sampled from LK, RV and the OG in November 2009 were 0.8, 1.32 and 0.96, respectively (Table 1). There appeared to be no significant difference in n-3 to n-6 ratio of mesenteric fat between fish from Lunsklip Fisheries with varying degree of severity of pansteatitis. The fish with severe pansteatitis sampled from the OG, however, had an n-3 to n-6 fatty acid ratio of 2.87 compared to 0.92 in fish with only mild or no pansteatitis (Table 4). From these results, it can be inferred that pansteatitis in OG fish was caused by high intake of polyunsaturated fatty acids whereas rancidity rather than high polyunsaturated fatty acid intake was the cause of the pansteatitis

observed in catfish from LK. In the light of absence of observed fish mortality in the OG, it would seem unlikely that rancidity associated with intake of dead rotting fish could have been the cause of pansteatitis in the OG catfish and crocodiles.

A significant proportion of the essential fatty acids derived from the diet are stored in the adipose tissues of animals and of these, docosahexaenoic acid 22:6n-3 (DHA) is deposited into the adipose tissues preferentially over eicosapentaenoic acid 20:5n-3 (EPA) (Lin & Connor 1990). Although the polyunsaturated fatty acids are mobilized more rapidly from the adipose tissues than saturated fats, DHA, the most polyunsaturated fatty acid, has been shown to be poorly mobilized (Connor, Lin & Colvis 1996). The higher levels of DHA found in the mesenteric fat of catfish from the Olifants Gorge with pansteatitis (11.06%) compared with mesenteric fat of those without pansteatitis (5.09%) strongly points to a higher intake of DHA in the diet of those fish that developed pansteatitis at this site. A similar differentiation was not observed in the mesenteric fat of catfish with mild and severe pansteatitis from LK, supporting the argument for a different dietary aetiology, most likely associated with rancidity of fats in the slaughter house waste fed to these fish.

The inlet of Lake Massingir, which prior to 2007 lay in Mozambique beyond the OG, now extends into the OG in the KNP within the boundaries of South Africa, flooding the gorge where this river previously traversed the Lebombo Mountains as fast flowing rapids. Phytoplankton blooms have been observed near the inlet to Lake Massingir (D. Pienaar, SANParks, Skukuza, personal communication 2009). Phytoplankton naturally contain large quantities of  $\alpha$ -linolenic acid and other n-3 polyunsaturated fatty acids, in particular EPA and DHA (Steffens 1997). It is proposed that by raising the dam of Lake Massingir, the resulting habitat change that occurred in the OG may have seasonally favoured access by crocodiles and catfish to phytoplankton-feeding fish. Of concern in this respect are silver carp, *Hypophthalmichthys molitrix* (Valenciennes), an invasive species outside of East Asia (Kolar *et al.* 2005) that were introduced into Mozambique and have also escaped into the Olifants River from South Africa and are known to occur in Lake Massingir (Skelton 2001). This fish is a specialized

1 plankton feeder that by preference feeds off phyto-  
 2 plankton (Kolar *et al.* 2005) and is known to  
 3 assimilate n-3 fatty acids (Buchtová & Jezek  
 4 2011). It is possible that crocodiles and catfish  
 5 feed on silver carp when these seasonally migrate  
 6 from the still waters of the lake into the Olifants  
 7 River to spawn, and this may provide one expla-  
 8 nation for intense intake of excessive polyunsatu-  
 9 rated fats by catfish and crocodiles.

## 11 Conclusions

12 The results presented describe and compare the  
 13 fatty acid composition and pathology found in  
 14 the adipose tissues of healthy and pansteatitis-  
 15 affected captive and wild sharp-tooth catfish. Data  
 16 indicate possibly differing causes of the pansteatitis  
 17 observed in the wild and captive fish. A classical  
 18 nutritional cause, overfeeding of rancid fish waste,  
 19 adequately explains the pansteatitis found in the  
 20 captive population of LK fish. Observed fish kills  
 21 have not been a consistent feature of the Olifants  
 22 River Gorge, and the results thus strengthen the  
 23 argument that causes other than consumption of  
 24 dead fish may be involved in inciting pansteatitis  
 25 in the OG fish. Similarities in changes in the adi-  
 26 pose tissues of catfish and crocodiles inhabiting  
 27 the same waters were observed. In the OG, the  
 28 higher n-3 to n-6 fatty acid ratios in the fat of  
 29 both catfish and crocodiles suffering from panstea-  
 30 titis, compared with those of healthy catfish and  
 31 crocodiles, point to an increased intake of  
 32 polyunsaturated fats as a cause of the observed  
 33 pansteatitis. The presence of alien invasive, phyto-  
 34 plankton-feeding, silver carp in Lake Massingir  
 35 and the short seasonal upstream spawning migra-  
 36 tion of this species through the OG provide one  
 37 plausible explanation for intense seasonal dietary  
 38 exposure of catfish and crocodiles to levels of  
 39 polyunsaturated fats to which they are not  
 40 adapted. It is proposed that the habitat changes  
 41 brought about by raising the dam wall of Lake  
 42 Massingir in 2007 may have improved access of  
 43 catfish and crocodiles to such fish within the OG,  
 44 thereby precipitating the pansteatitis outbreaks in  
 45 these animals.

## 47 Acknowledgements

48 The following co-workers are acknowledged for  
 49 their contribution to the field data collection: Drs  
 50 J. Myburgh, J. Steyl, A. Deacon, Colonel R Dixon,

51 Prof H. Bouwman and Mr D. Pienaar. Mr D. Pie-  
 52 naar of SANParks is specifically thanked for faci-  
 53 litating the fieldwork and project registration. Dr P.  
 54 A. Colly and Sterkspruit Veterinary Clinic are  
 55 thanked for logistical and financial support. Mr J.  
 56 Venter of SANParks is thanked for capture and  
 57 transportation of fish and the assistance of SAN-  
 58 Parks rangers and various fishermen are gratefully  
 59 acknowledged in this regard. SANParks rangers are  
 60 thanked for provision of security. Mss N. Maseko  
 61 and P. Shikwambana of SANParks are thanked for **3**  
 62 field laboratory technical assistance. Students, Mis-  
 63 ters C., R. and N. Huchzermeyer are acknowledged  
 64 for logistical support and assistance with catching  
 65 and dissecting fish. From the Department of Para-  
 66 clinical Sciences at the Faculty of Veterinary Sci-  
 67 ence, University of Pretoria, Dr J. Steyl is thanked  
 68 for preparation of histological sections and Prof J.  
 69 Lawrence, as promoter of this project, for his edito-  
 70 rial and scientific comments. Prof Lawrence and Dr  
 71 Steyl are thanked for comments on histological  
 72 interpretations. Prof Bouwmann and student help-  
 73 ers, from University of Northwest and Colonel R.  
 74 Dixon and the SAP Forensics Laboratory are  
 75 acknowledged for assistance with sample collection  
 76 and sample transport. Lunsklip Fisheries are grate-  
 77 fully acknowledged for supply of positive control  
 78 fish. Mistresses H. Kgoete and E. Sithole are thanked  
 79 for assisting with the logistics of fish dissections.  
 80 The project was approved by the respective  
 81 Research and Animal Use and Care Committees of  
 82 the Faculty of Veterinary Science, University of  
 83 Pretoria, Protocol V013/10 and South African  
 84 National Parks. The project was funded in part by  
 85 the Water Research Commission of South Africa  
 86 under Consultancy Contract K8/948.

## 87 References

- 88 Anon (2007) *NCSS, 2007. Statistical System for Windows.*  
 89 NCSS Statistical Systems, Kaysville, Utah, USA.
- 90 Anon (2008) Mystery ailment kills crocs. News in perspective,  
 91 2008. *The New Scientist* **199**, 6.
- 92 Bonar C.J. & Wagner R.A. (2003) A third report of 'golf ball  
 93 disease' in Amazon River dolphin (*Inia geoffrensis*) associated  
 94 with *Streptococcus iniae*. *Journal of Wildlife Medicine* **34**, 296  
 95 –301.
- 96 Bricknell I.R., Bruno D.W., Bowden T.J. & Smith P. (1996)  
 97 Fat cell necrosis syndrome in Atlantic halibut, *Hippoglossus*  
 98 *hippoglossus* L. *Aquaculture* **144**, 65–69.
- 99 Buchtová H. & Jezek F. (2011) A new look at the assessment  
 100 of silver carp (*Hypophthalmichthys molitrix* Val.) as a food  
 101 fish. *Czech Journal of Food Science* **29**, 487–497.

- 1 Bus J.S., Aust S.D. & Gibson J.E. (1976) Paraquat toxicity:  
 2 proposed mechanism of action involving lipid peroxidation.  
 3 *Environmental Health Perspectives* **16**, 139–146.
- 4 Case L.P., Carey D.P. & Hirakawa D.A. (1995) Vitamin  
 5 deficiencies and excesses. In: *Canine and Feline Nutrition.*  
 6 *A Resource for Companion Animal Professionals* (ed. by ????,  
 7 [4] ???), pp. 303–308. Mosby-Year Book, St. Louis.
- 8 Connor W.E., Lin D.S. & Colvis C. (1996) Differential  
 9 mobilization of fatty acids from adipose tissue. *Journal of*  
*Lipid Research* **37**, 290–298.
- 10 Farwer S.R., Haddeman E., Kivits G.A.A., Wiersma A.,  
 11 Danse B.H.J.C. & Derboer B.C.J. (1994) The vitamin E  
 12 nutritional status of rats fed on diets high in fish oil or  
 13 sunflower seed oil. *British Journal of Nutrition* **72**, 127–  
 14 145.
- 15 Ferreira S.M. & Pienaar D. (2011) Degradation of the  
 16 crocodile population of Kruger National Park, South Africa.  
 17 *Aquatic Conservation and Marine and Freshwater Ecosystems*  
 18 **21**, 155–164.
- 19 Folch J., Lees M. & Sloane-Stanley G.H. (1957) A simple  
 20 method for the isolation and purification of total lipids  
 21 from animal tissue. *Journal of Biological Chemistry* **226**,  
 22 497–509.
- 23 Fytianou A., Koutinas A.F., Saridomichelakis M.N. &  
 24 Koutinas C.K. (2006) Blood  $\alpha$ -tocopherol, selenium and  
 25 glutathione peroxidase changes and adipose tissue fatty acid  
 26 changes in kittens with experimental steatitis (yellow fat  
 27 disease). *Biological Trace Element Research* **112**, 131–143.
- 28 Goodwin A.E. (2006) Steatitis, fin loss and skin ulcers of  
 29 channel catfish, *Ictalurus punctatus* (Rafinesque), fingerlings  
 30 fed salmonid diets. *Journal of Fish Diseases* **29**, 61–64.
- 31 Guarda F., Bertoja G., Zoccarato I., Tartari E. & Biolatti B.  
 32 (1997) Spontaneous steatitis of epicardial fat in farmed  
 33 white sturgeon (*Acipenser transmontanus*). *Aquaculture* **158**,  
 34 167–177.
- 35 Heath R., Coleman T. & Engelbrecht J. (2010) Water quality  
 36 overview and literature review of the ecology of the Olifants  
 37 River. Water Research Council Report No. TT452/10.
- 38 Herman R.L. & Kircheis F.W. (1985) Steatitis in Sunapee  
 39 trout, *Salvelinus alpinus oquassa* Girard. *Journal of Fish*  
 40 *Diseases* **8**, 237–239.
- 41 Hoffman L.C. & Prinsloo J.F. (1995) Genetic and nutritional  
 42 influence on the total lipid fatty acid profile of *Clarias*  
 43 *gariiepinus* muscle. *Aquatic Living Resources* **8**, 415–421.
- 44 Huchzermeyer F.W. (2003) *Crocodiles. Biology, Husbandry and*  
 45 *Diseases*. CABI Publishing, Wallingford, Cambridge, pp. 337.
- 46 Huchzermeyer K.D.A., Govender D., Pienaar D.J. & Deacon  
 47 A.R. (2011) Steatitis in sharptooth catfish (*Clarias gariiepinus*  
 48 Burchell), in the Olifants and Lower Letaba Rivers in the  
 49 Kruger National Park, South Africa. *Journal of Fish Diseases*  
 50 **34**, 489–498.
- 51 Jones D., Howard N. & Gresham G.A. (1969) Aetiology of  
 52 'yellow fat' disease (pansteatitis) in the wild rabbit. *Journal*  
*of Comparative Pathology* **79**, 329–334.
- Juan-Sallés E., Prats N., Resendes A., Domingo M., Hilton  
 D., Ruiz J.M., Garner M.M., Valls X., Marco A.J. (2003)  
 Anemia, myopathy, and pansteatitis in vitamin E-deficient  
 captive marmosets (*Callithrix* spp.). *Veterinary Pathology* **40**,  
 540–547.
- Kolar C.S., Chapman D.C., Courtenay W.R. Jr, Housel C.M.,  
 Williams J.D. & Jennings D.P. (2005) Asian carps of the  
 genus *Hypophthalmichthys* (Pisces, Cyprinidae) – A  
 biological synopsis and environmental risk assessment.  
 Report to US Fish and Wildlife Service per Interagency  
 Agreement 94400-3-0128 pp. 175.
- Kwetegeyeka J., Masa J., Kiremire B.T., Mpango G.B. &  
 Grahl-Nielsen O. (2011) Fatty acids of polar lipids in heart  
 tissue are good taxonomic markers for tropical African  
 freshwater fish. *African Journal of Aquatic Science* **36**, 115–  
 127.
- Lin D.S. & Connor W.E. (1990) Are the n-3 fatty acids  
 from dietary fish oil deposited in the triglyceride stores of  
 adipose tissue? *American Journal of Clinical Nutrition* **51**,  
 535–539.
- Niza N.M.R.E., Vilela C.L. & Ferreira L.M.A. (2003)  
 Feline pansteatitis revisited: hazards of unbalanced home-  
 made diets. *Journal of Feline Medicine and Surgery* **5**, 271  
 –277.
- Osthoff G., Hugo A., Bouwman H., Buss P., Govender D.,  
 Joubert C.C. & Swarts J.C. (2010) Comparison of the  
 lipid properties of captive, healthy wild, and pansteatitis  
 affected wild Nile crocodiles (*Crocodylus niloticus*).  
*Comparative Biochemistry and Physiology A* **155**, 64–69.  
 (Imp 1.56)
- Park P.W. & Goins R.E. (1994) *In situ* preparation of fatty  
 acid methyl esters for analysis of fatty acid composition in  
 foods. *Journal of Food Science* **59**, 1262–1266.
- Pollock C.G., Sleeman J.M., Houle C.D. & Ramsay E.C.  
 (1999) Vitamin E deficiency and pansteatitis in juvenile  
 boat-billed herons (*Cochlearius cochlearius*). *Journal of Zoo*  
*and Wildlife Medicine* **30**, 297–300.
- Roberts R.J. & Agius C. (2008) Pansteatitis in farmed  
 northern bluefin tuna, *Thunnus thynnus* (L.), in the eastern  
 Adriatic. *Journal of Fish Diseases* **31**, 83–88.
- Roberts R.J., Richards R.H. & Bullock A.M. (2006)  
 Pansteatitis in rainbow trout *Salmo gairdneri* Richardson: a  
 clinical and histopathological study. *Journal of Fish Diseases*  
**2**, 85–92.
- Scott D.W., Miller W.H. Jr & Griffin C.E. (1995) Nutritional  
 skin diseases. In: *Muller and Kirk's Small Animal*  
*Dermatology*, 8th edn (ed. by ????. ???), pp. 890–901. W.B.  
 Saunders, Philadelphia. [5]
- Sinclair A.J. & O'Dea K. (1987) The lipid levels and fatty  
 acid compositions of the lean portions of Australian beef  
 and lamb. *Food Technology in Australia* **39**, 228–231.
- Skelton P. (2001) *A Complete Guide to the Freshwater Fishes of*  
*Southern Africa*. Struik Publishers, Cape Town, pp. 395.
- Spataru P., Viveen W.J.A.R. & Gophen M. (1987) Food  
 composition of *Clarias gariiepinus* (= *C. lazera*)  
 (Cypriniformes, Clariidae) in Lake Kinneret (Israel).  
*Hydrobiologica* **144**, 77–82.
- Steffens W. (1997) Effects of variation in essential fatty acids  
 in fish feeds on nutritive value of freshwater fish for  
 humans. *Aquaculture* **151**, 97–119.

1 Wallach J.D. & Hoessle C. (1968) Steatitis in captive  
2 crocodilians. *Journal of the American Veterinary Medical*  
3 *Association* **153**, 845–847.  
4  
5 Weyl O.L.F. & Booth A.J. (2008) Validation of annulus  
6 formation in otoliths of a temperate population of adult  
7 African sharpnose catfish *Clarias gariepinus* using  
8 fluorochrome marking of wild fish. *Journal of Fish Biology*  
9 **73**, 1033–1038.

10  
11  
12  
13  
14  
15  
16  
17  
18  
19  
20  
21  
22  
23  
24  
25  
26  
27  
28  
29  
30  
31  
32  
33  
34  
35  
36  
37  
38  
39  
40  
41  
42  
43  
44  
45  
46  
47  
48  
49  
50  
51  
52  
Wong E., Mikaelian I., Desnoyers M. & Fitzgerald G. (1999)  
Pansteatitis in a free-ranging red-tailed hawk (*Buteo*  
*jamaicensis*). *Journal of Zoo and Wildlife Medicine* **30**, 584–  
586.

Received: 18 July 2012

Revision received: 23 August 2012

Accepted: 24 August 2012

UNCORRECTED PROOF

## Author Query Form

Journal: JFD  
Article: 12010

Dear Author,

During the copy-editing of your paper, the following queries arose. Please respond to these by marking up your proofs with the necessary changes/additions. Please write your answers on the query sheet if there is insufficient space on the page proofs. Please write clearly and follow the conventions shown on the attached corrections sheet. If returning the proof by fax do not write too close to the paper's edge. Please remember that illegible mark-ups may delay publication.

Many thanks for your assistance.

Query reference	Query	Remarks
1	<b>AUTHOR: A running head short title was not supplied; please check if this one is suitable and, if not, please supply a short title of up to 40 characters that can be used instead.</b>	
2	<b>AUTHOR: Please check that authors and their affiliations are correct.</b>	
3	<b>AUTHOR: Please check and approve the abbreviation 'Mss' in the 'Mss N. Maseko' in acknowledgements.</b>	
4	<b>AUTHOR: Please provide the editor name(s) for reference Case et al. (1995).</b>	
5	<b>AUTHOR: Please provide the editor name(s) for reference Scott et al. (1995).</b>	

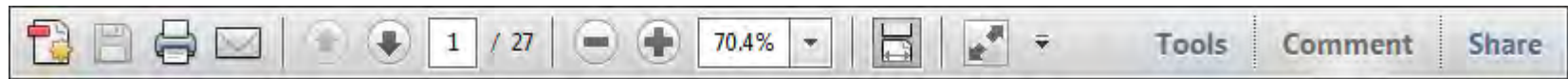


## USING e-ANNOTATION TOOLS FOR ELECTRONIC PROOF CORRECTION

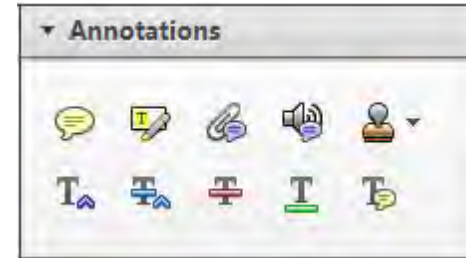
Required software to e-Annotate PDFs: **Adobe Acrobat Professional** or **Adobe Reader** (version 7.0 or above). (Note that this document uses screenshots from **Adobe Reader X**)

The latest version of Acrobat Reader can be downloaded for free at: <http://get.adobe.com/uk/reader/>

Once you have Acrobat Reader open on your computer, click on the **Comment** tab at the right of the toolbar:



This will open up a panel down the right side of the document. The majority of tools you will use for annotating your proof will be in the **Annotations** section, pictured opposite. We've picked out some of these tools below:



### 1. Replace (Ins) Tool – for replacing text.

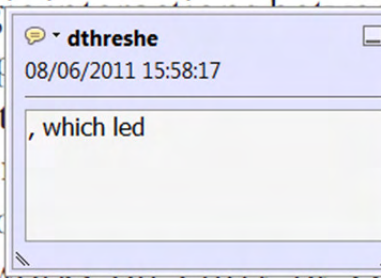


Strikes a line through text and opens up a text box where replacement text can be entered.

#### How to use it

- Highlight a word or sentence.
- Click on the **Replace (Ins)** icon in the Annotations section.
- Type the replacement text into the blue box that appears.

standard framework for the analysis of microeconomics. Nevertheless, it also led to the emergence of strategic behaviour in the number of competitors in the industry. It is that the structure of the industry, which led to the emergence of imperfect competition. The main components of the model, at the industry level, are exogenous variables and important works on this subject by Shirasaka (1987) and henceforth. We open the 'black box'...



### 2. Strikethrough (Del) Tool – for deleting text.



Strikes a red line through text that is to be deleted.

#### How to use it

- Highlight a word or sentence.
- Click on the **Strikethrough (Del)** icon in the Annotations section.

there is no room for extra profits and the number of competitors are zero and the number of firms (net) values are not determined by the number of firms. Blanchard and Kiyotaki (1987), in their paper on perfect competition in general equilibrium, show that the structure of aggregate demand and supply in the classical framework assuming monopoly is determined by an exogenous number of firms.

### 3. Add note to text Tool – for highlighting a section to be changed to bold or italic.



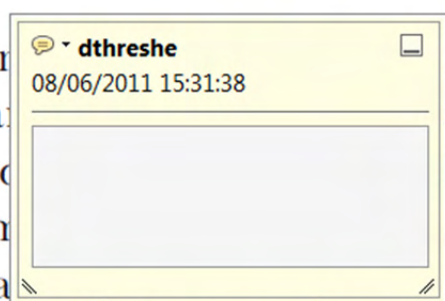Highlights text in yellow and opens up a text box where comments can be entered.

#### How to use it

- Highlight the relevant section of text.
- Click on the **Add note to text** icon in the Annotations section.
- Type instruction on what should be changed regarding the text into the yellow box that appears.

dynamic responses of mark-ups consistent with the VAR evidence.

...with well-labelled... on... to a... on... stent also with the demand...



### 4. Add sticky note Tool – for making notes at specific points in the text.

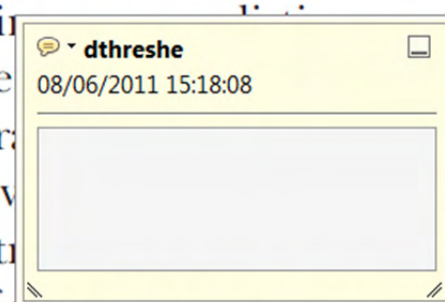

Marks a point in the proof where a comment needs to be highlighted.

#### How to use it

- Click on the **Add sticky note** icon in the Annotations section.
- Click at the point in the proof where the comment should be inserted.
- Type the comment into the yellow box that appears.

...and supply shocks. Most of the... number of... standard framework... cy. Nevertheless, it also led to the emergence of strategic behaviour in the number of competitors and the impact is that the structure of the sector...



USING e-ANNOTATION TOOLS FOR ELECTRONIC PROOF CORRECTION

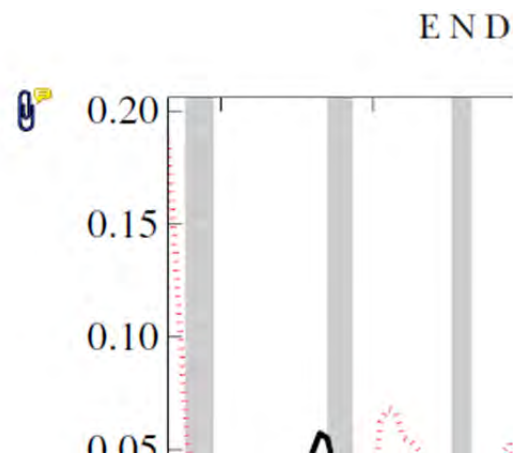
**5. Attach File Tool – for inserting large amounts of text or replacement figures.**



Inserts an icon linking to the attached file in the appropriate place in the text.

**How to use it**

- Click on the [Attach File](#) icon in the Annotations section.
- Click on the proof to where you'd like the attached file to be linked.
- Select the file to be attached from your computer or network.
- Select the colour and type of icon that will appear in the proof. Click OK.



**6. Add stamp Tool – for approving a proof if no corrections are required.**

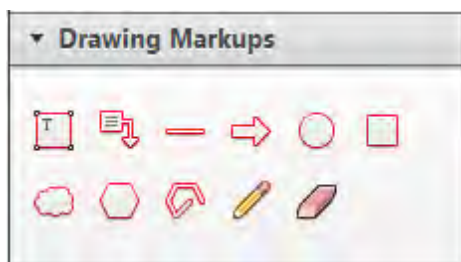

Inserts a selected stamp onto an appropriate place in the proof.

**How to use it**

- Click on the [Add stamp](#) icon in the Annotations section.
- Select the stamp you want to use. (The [Approved](#) stamp is usually available directly in the menu that appears).
- Click on the proof where you'd like the stamp to appear. (Where a proof is to be approved as it is, this would normally be on the first page).

of the business cycle, starting with the  
on perfect competition, constant return  
production. In this environment goods  
extra profits and the market  
he market. The New-Key  
otaki (1987), has introduced product  
general equilibrium models with nomin  
ed and supply shocks. Most of this literat

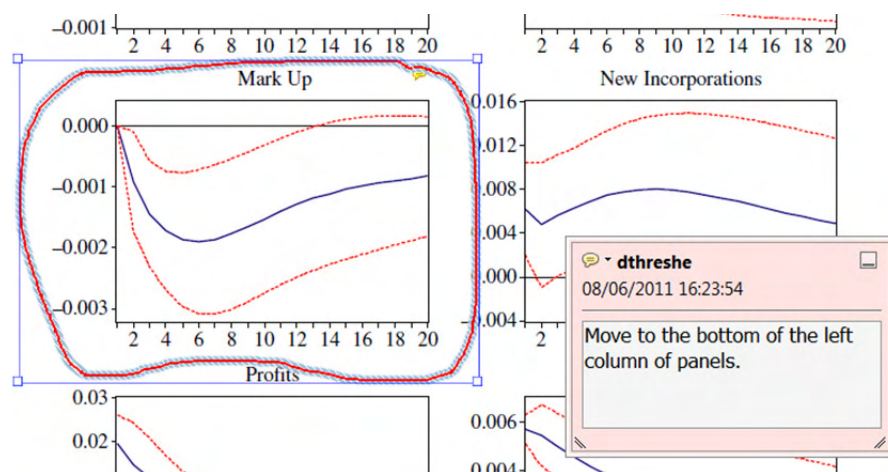


**7. Drawing Markups Tools – for drawing shapes, lines and freeform annotations on proofs and commenting on these marks.**

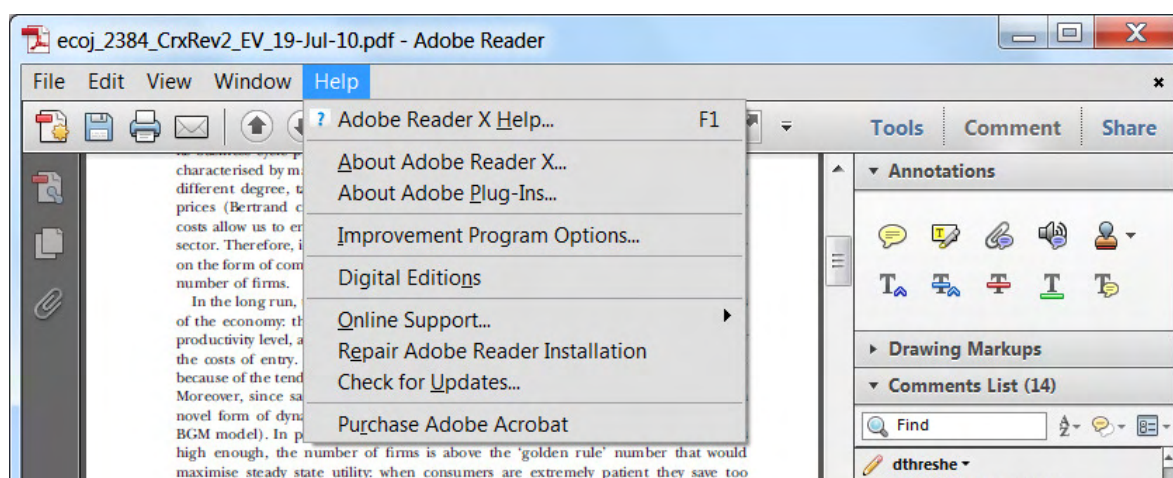
Allows shapes, lines and freeform annotations to be drawn on proofs and for comment to be made on these marks..

**How to use it**

- Click on one of the shapes in the [Drawing Markups](#) section.
- Click on the proof at the relevant point and draw the selected shape with the cursor.
- To add a comment to the drawn shape, move the cursor over the shape until an arrowhead appears.
- Double click on the shape and type any text in the red box that appears.



For further information on how to annotate proofs, click on the [Help](#) menu to reveal a list of further options:



**A PRELIMINARY STUDY TO IDENTIFY  
PATHOLOGY PRESENT IN FISH IN THE LOWER  
OLIFANTS RIVER FOLLOWING A LARGE  
CROCODILE MORTALITY EVENT**

Report to the  
**Water Research Commission**

by

**KDA Huchzermeyer**  
Department of Paraclinical Sciences  
Faculty of Veterinary Science  
University of Pretoria

**WRC Report No. KV 299/12**

**AUGUST 2012**

**Obtainable from**

Water Research Commission  
Private Bag X03  
Gezina, 0031 SOUTH AFRICA

This report emanates from a project titled *Apreliminary study to identify pathology present in fish in the lower Olifants River following a large crocodile mortality event* (WRC Project No K8/948)

**DISCLAIMER**

This report has been reviewed by the Water Research Commission (WRC) and approved for publication. Approval does not signify that the contents necessarily reflect the views and policies of the WRC, nor does mention of trade names or commercial products constitute endorsement or recommendation for use

**ISBN 978-1-4312-0311-6**  
**Printed in the Republic of South Africa**

© WATER RESEARCH COMMISSION



## EXECUTIVE SUMMARY

Pansteatitis is a nutritional disease that follows on consumption of large amounts of polyunsaturated fats. The reduction in tissue vitamin E levels associated with such a diet is exacerbated where dietary fats have become rancid. In the Kruger National Park (KNP), pansteatitis in fish and crocodiles has been shown to be a serious and increasing problem in large man-made lakes fed by rivers arising in polluted catchments. The objective of this study was to identify the range of pathologies present in fish in the lower Olifants and Letaba rivers within the KNP, to determine the significance of these pathologies in terms of pollution and the development of pansteatitis in crocodiles, to differentiate such pathologies from non-pollution related pathology as would be expected in free-living fish in these rivers and to identify improved sacrificial and non-sacrificial methods of monitoring the fish health in KNP rivers.

During the period June 2009 to June 2011, 285 sharptooth catfish (*Clarias gariepinus*, Burchell) specimens were examined during 17 sampling episodes from various localities within and outside of KNP. Tiger fish were sampled from the Olifants Gorge during June 2011. Fish were subjected to detailed autopsies and subsequent histological examination of the organs. Blood samples were collected from all sampled fish. Detailed data sheets were compiled on all macroscopic findings during field data collection and on subsequent histological and laboratory findings.

Significant pathology in catfish was limited to changes associated with necrosis of fat and the resultant inflammatory reaction in the adipose tissues (pansteatitis) of the fish. Pathology secondary to fat necrosis was also identified in certain other organs. These pathologies were differentiated from pathology associated with parasitosis. Pathology indicative of pollution related aetiology could, however, not be demonstrated. An increasing prevalence of fat necrosis and steatitis was recorded in catfish sampled from the Olifants River gorge in the period 2009 to 2011, and over 60% of catfish collected during the most recent sampling from the Olifants Gorge were affected with steatitis. A decline in amount of fat stored by catfish was noted with repeat samplings from the Olifants Gorge between November 2009 and June 2011. Steatitis was also confirmed in catfish collected from the Sabie River in the Sabiepoort at a similar prevalence to that found in the Olifants Gorge. Steatitis was not detected in tiger fish sampled from the Olifants Gorge. Only a low prevalence of steatitis was detected in catfish sampled upstream of the Olifants Gorge within the KNP. No steatitis was observed in catfish sampled from a rain-filled dam unconnected to the Olifants River. Catfish sampled from a dam at a phosphate mine in Phalaborwa showed no sign of steatitis. A high prevalence of nutritionally induced pansteatitis was, however, identified in a farmed population of catfish. This provided the study with valuable comparative pathology. Analysis of stomach content of catfish from the various sampling sites in KNP indicated a higher prevalence of fish in the diet of catfish from the Olifants Gorge and Sabiepoort than in catfish from sites where no steatitis was detected.

With the selected haematological and biochemical parameters it was not possible to differentiate between fish with and without steatitis, reflecting the chronic nature of the condition and possible intermittent exposure to oxidative stress. Whereas haematocrit values proved to be unreliable in detecting presence of oxidative stress in these fish, variation in haemoglobin values between sites pointed to increased erythrocyte turnover, suggestive of oxidative stress in fish from the Olifants Gorge. Determination of serum vitamin E and erythrocyte glutathione peroxidase values, both commercially available tests in South Africa, appeared to indicate that catfish in both the Olifants and lower Letaba rivers within KNP had been exposed to an oxidative stress challenge preceding a sampling during July 2010. These tests require further validation under field conditions before they can be used for non-sacrificial monitoring of catfish in the KNP.

The hypothesis that pansteatitis occurs in sharptooth catfish in the Olifants Gorge has been proven from the results of this project and the findings have been published in the Journal of Fish Diseases. Tissue samples have been stored for toxicological examination from all collected fish. Toxicological analyses fall outside the scope of this contract. Further tissue samples have been collected for co-workers investigating other aspects not covered by this contract. These include analyses of adipose tissue fatty acids and stable isotopes, and manuscripts have been submitted for publication on these topics.

In the absence of observed fish mortality, periodic exposure to an overabundance of certain fish species in the diet of crocodiles and catfish in the Olifants Gorge may have occurred following the raising of the dam wall of Lake Massingir in 2007. Whereas a contributory role of pollution cannot be ruled out, this study points to the likelihood that the increased abundance of phytoplankton feeding fish species, in particular the alien silver carp (*Hypophthalmichthys molitrix*) in the diet of both catfish and crocodiles in the Olifants and Sabie gorges may have led to the pansteatitis observed in these two species. Silver carp are known to occur in Lake Massingir, but their presence has not been confirmed in Lake Corumana. High phosphate levels measured in the Olifants River within KNP prior to 2004, and trapped in Lake Massingir, would have stimulated phytoplankton growth in this lake. A habitat change in the gorge brought about by raising of the sluices of the lake in 2007, and the consequent extension of the lake into the KNP, may have provided both catfish and crocodiles with an excessive intake of silver carp during the short period during peak summer flow when this species migrates into the Olifants River to spawn. The analysis of heavy metals in the fish tissues collected during the course of this study has not been completed. The possibility of bioaccumulation of iron following the consumption of phytoplankton, (as documented in Lake Loskop by Oberholster et al. (2011)), still needs to be investigated in the fish of Lake Massingir and the Olifants River Gorge.

The results of the study emphasize the ecological importance and complexity of oxidative stress in a disturbed aquatic environment and the risk associated with the presence of alien invasive fish species within our national parks. The results suggest that pollution-derived nutrient enrichment of rivers can have far reaching effects where man-made hydrodynamic change has altered the aquatic habitat. Such information is important to guide conservation

policy and decisions regarding use of water and the safety of fish consumed from such waters. In KNP, sharp-tooth catfish and crocodiles appear to show similar sensitivity to pancreatitis within their overlapping habitat. Sharp-tooth catfish are a suitable monitoring species for the condition and can be used by KNP to monitor pancreatitis in crocodiles. It is recommended that the distribution of alien fish species within rivers traversing the KNP is investigated further and that in dams within KNP and elsewhere in South Africa the effects of hydrodynamic change and nutrient entrapment on the aquatic food chain are monitored with particular reference to the health of top aquatic predators such as crocodiles. The study provides South Africa and its authorities with information to insist that environmental controls ensuring the quality of water in our rivers are implemented and provides SANParks with information to insist on prevention of pollution and alien fish species entering KNP, thereby ensuring the biodiversity of the KNP rivers and securing the future of the Nile crocodile in the KNP.

## ACKNOWLEDGEMENTS

The following co-workers are acknowledged for their contribution to the field data collection: Drs D. Govender, J. Myburgh, J. Steyl, A. Deacon, Colonel R. Dixon, Prof H. Bouwman and Messers D. Pienaar and J. Müller. Mr D. Pienaar and Dr D Govender of SANParks are specifically thanked for facilitating the fieldwork and project registration with SAN Parks and Dr D. Govender for epidemiological inputs. Dr P.A. Colly, Sterkspruit Veterinary Clinic is thanked for logistical and financial support, Dr R. Du Plessis, Ampath Pathologists Nelspruit for histological sectioning, Staff of Sterkspruit Veterinary Clinic for logistical support, Mr J. Venter, SANParks for capture and transportation of fish and water quality testing and the SANParks rangers for provision of security. Mss N. Maseko, P. Shikwambana and N. Tyaqana, and Mr K. Deenadayalan of SANParks are thanked for field laboratory technical assistance. The assistance of SANParks rangers and various fishermen with catching and transport of fish is gratefully acknowledged. Students C., R. and N. Huchzermeyer are acknowledged for logistical support and assistance with catching and dissecting fish. From the Department of Paraclinical Sciences at the Faculty of Veterinary Science, University of Pretoria, Dr J. Steyl is thanked for preparation of histological sections and Prof J. Lawrence, as promoter of this project, for his editorial and scientific comments. Prof Lawrence and Dr Steyl are thanked for comments on histological interpretations. Prof H. Bouwman and student helpers, from University of Northwest, are acknowledged for assistance with water quality analyses and toxicological sample collection and sample transport. Colonel R. Dixon and the SAP Forensics Laboratory are thanked for assistance with toxicological sample collection and facilitation of analyses. Prof G. Osthoff from the University of the Free State is thanked for analysis of fatty acid composition and Mr S. Woodborne of the CSIR for radio-isotope mapping of the food web in the Olifants Gorge. Lunsklip Fisheries are gratefully acknowledged for supply of positive control fish. Mr J. Müller and IDEXX Laboratories are thanked for their generous help with field laboratory services and blood chemistry determinations and Ampath Laboratories for  $\alpha$ -tocopherol determinations. Mr M. Lotter is thanked for preparing the map of the sampling sites. Mr H. Kgoete and E. Sithole are thanked for assisting with the logistics of fish dissections.

The project was approved by the respective Research and Animal Use and Care Committees of the Faculty of Veterinary Science, University of Pretoria, Protocol V013/10 and SANParks and forms the basis for a PhD thesis by the author. Funding received from the WRC (Consultancy Contract K8/948) covered the period 1 June 2010 to 31 July 2011. The remainder of the project was funded through the author's private means with assistance from the Veterinary Foundation and IDEXX Laboratories.

## TABLE OF CONTENTS

	EXECUTIVE SUMMARY	iii
	ACKNOWLEDGEMENTS	vi
1	HISTORY AND BACKGROUND OF STUDY	1
1.1	The Crocodile Mortality Events	1
1.2	Organisational Response to the Crocodile Mortality	1
2	OBJECTIVE	2
3	LITERATURE REVIEW	2
4	MATERIALS AND METHOD	6
4.1	Fieldwork	6
4.2	Description of Study Area	6
4.3	Specimen Collection	7
4.4	Laboratory Work	8
4.5	Statistical Analysis	8
5	RESULTS	9
5.1	Steatitis Prevalence	9
5.2	Macroscopic Pathology	14
5.3	Stomach Contents	23
5.4	Histopathology	25
5.4.1	Histopathology of the adipose tissues	25
5.4.2	Histopathology of other organs	29
5.5	Pathology in Other Species	34
5.6	Blood Chemistry and Haematology	34
5.6.1	Blood smear examinations	34
5.6.2	Haematocrit	35
5.6.3	Haemoglobin	35
5.6.4	Serum vitamin E	37
5.6.5	Blood glutathione peroxidase	40
6	DISCUSSION	42
6.1	Prevalence of Steatitis	42
6.2	Pathology	43
6.3	Steatitis and the Crocodile Mortality	44
6.4	Haematology and Blood Chemistry	45
6.5	Xenobiotics as Possible Cause of Steatitis	48
6.6	Dietary Change and Steatitis in the KNP	48
7	CONCLUSION AND RECOMMENDATIONS	52
8	BENEFITS	53
9	REFERENCES	54



## LIST OF FIGURES

	<b>Page</b>
<b>Figure 1:</b> Macroscopic steatitis prevalence as percentage of sampled catfish from various sampling sites in Kruger National Park during the period2009-2011	10
<b>Figure 2:</b> Prevalence of steatitis in catfishsampled from various localities along the Olifants and lower Letaba rivers in the Kruger National Park from 2009 to 2011	11
<b>Figure 3A:</b> Growth rings in the otolith of a 19 year old catfish specimen from the Olifants Gorge	13
<b>Figure 3B:</b> Growth rings in the otolith of a 4 year old catfishspecimen from the Olifants Gorge.	13
<b>Figure 4A:</b> Early steatitis lesion in catfish sampled from the Olifants Gorge during July 2010. Note the small sharply circumscribed foci of fat cell necrosis and associated ceroid deposition imparting the characteristic brown colour (arrow)	14
<b>Figure 4B:</b> Advanced steatitis of mesenteric fat of a catfish specimen sampled from the Olifants Gorge during November 2009. Note the diffuse brown granular appearance of the fat, the rough surface and virtually total absence of normal appearing fat	15
<b>Figure 4C:</b> Cross section of mesenteric adipose tissue from a catfish specimen collected from the Olifants Gorge in November 2009 showing typical severe steatitis. Note brown granuloma formation within the adipose tissue	15
<b>Figure 5:</b> Steatitis of the mesenteric adipose tissues in a catfish sampled from the Olifants Gorge during June 2011. Note that the caudal portion of the mesenteric fat body appears more severely affected	16
<b>Figure 6A:</b> Focal fat necrosis (arrows) in the pectoral fat of a catfish sampled from the Olifants Gorge during July 2010	16
<b>Figure 6B:</b> Focal steatitis (arrows) in the intramuscular fat of a catfish sampled from the Olifants Gorge during July 2010	17
<b>Figure 6C:</b> Generalised steatitis in the fat surrounding the brain of a catfish sampled from the Olifants Gorge during July 2010. Note brown discolouration of fat (arrow) adhering to the opened cranium	17
<b>Figure 7:</b> Melanin deposition (black arrow) associated with digenean trematodes cysts (block arrows) in the caudal mesenteric fat between the male accessory sexual glands of a catfish sampled from Reënvoël Dam in KNP	19
<b>Figure 8:</b> Melanin deposition (arrows) in vicinity of larval nematodes in the mesentery overlying the mesenteric fat in a catfish sampled from van Ryssen Dam at the FOSKOR mine in Phalaborwa	19

<b>Figure 9A:</b> Swollen fatty appearing liver typical of a catfish suffering from steatitis, sampled from the Olifants Gorge during June 2011	20
<b>Figure 9B:</b> Focal fat deposits beneath the liver capsule from a catfish with steatitis sampled from Lunsklip Fisheries during November 2009	21
<b>Figure 9C:</b> Liver from a catfish sampled from Reënvoël Dam during November 2009. Arrows show damage associated with parasitic cysts in the liver parenchyma. Note the dark colour and sharp liver borders of an otherwise healthy liver	21
<b>Figure 9D:</b> Outgrowth of regenerating hepatic tissue (arrow), probably associated with parasitism, in a liver from a catfish sampled from Reënvoël Dam during November 2009. Note the normal brown colour of the liver	22
<b>Figure 10A:</b> Typically enlarged spleen of <i>C. gariepinus</i> , from the Olifants Gorge, suffering from fat necrosis and steatitis	22
<b>Figure 10B:</b> Spleen of a catfish from Lunsklip Fisheries suffering from severe chronic steatitis showing prominent capsular thickening and splenomegaly. Note the rounded nature of the normally flat spleen	23
<b>Figure 11:</b> Stomach content analysis of sharptooth catfish showing that the population with pansteatitis (Pan++) at a site where pansteatitis was prevalent had stomach contents with a higher proportion of fish than vegetation, or invertebrates and detritus (mixed) when compared with the population of fish that did not have pansteatitis (Pan+-) from areas that had pansteatitis prevalence, and the population from areas without pansteatitis prevalence (Pan-). (Triplot preparation courtesy of S. Woodborne, Centre for Scientific and Industrial Research, Pretoria)	25
<b>Figure 12A:</b> Giant cell formation (arrows) in a typical steatitis lesion in adipose tissue from a catfish sampled from the Olifants Gorge in July 2009. HE X100	26
<b>Figure 12B:</b> Positive staining ceroid pigment (purple) within the lipopigment remnants (lp) of ruptured adipocytes and macrophages (m) in mesenteric fat of a catfish sampled from the Olifants Gorge during November 2009. Adipocytes (fc). (GAF)	26
<b>Figure 13:</b> Atrophied mesenteric adipose tissue showing inflammation typical of steatitis in a catfish sampled from the Olifants Gorge during June 2011. Note small size of adipocytes (fc) and aggregates of macrophages (m) containing ceroid, surrounding areas of fat necrosis containing lipopigment (lp). (HE)	27
<b>Figure 14:</b> Advanced stage of fat necrosis and steatitis in mesenteric fat of a catfish sampled from the Olifants Gorge during June 2011. Note the apparently empty lacunae (l) where necrotic remnants of oxidised fat (lp) have been lost during processing, surrounded by an epithelioid sheath. Adipocytes (a), foreign body giant cells (arrow). (HE)	28
<b>Figure 15A:</b> Liver section of a catfish sampled from the Olifants Gorge during November 2009. Note distinct focus of fat vacuoles (f). (HE X200)	30

<b>Figure 15B:</b> Liver section of a catfish sampled from the Olifants Gorge during November 2009. Note distinct focus of fat vacuoles (f) and clustering of haemosiderin (arrows) on the perimeter of this focus. (Perl's Prussian blue, X200)	30
<b>Figure 16:</b> Pancreatic atrophy in a catfish suffering from steatitis, sampled from the Olifants Gorge during June 2011. Note prominence of connective tissue (ct) extending between groups of acinar cells (a). Islet of Langerhans (iL). (HE)	31
<b>Figure 17:</b> Digenean trematode larva encysted within the cartilage of the primary lamellae of a catfish sampled from the Olifants Gorge during June 2011. Note hyperplastic changes in the cartilage (arrows). (HE)	32
<b>Figure 18:</b> Digenean trematodes of the family Diplostomidae (arrows) within the cerebrospinal space adjacent to fat lining the cranium of a catfish sampled from Engelhard Dam during July 2010. Note the cellular reaction associated with presence of these parasites. (HE)	33
<b>Figure 19:</b> Comparison of mean haematocrit (PCV%) from all catfish sampled from the Olifants Gorge sites (n=111) as compared to mean haematocrit (PCV%) of catfish sampled from Lunsklip Fisheries (n=21) and Reënvoël Dam (n=13). (p=0.00002, vertical bars denote +/- standard errors)	36
<b>Figure 20:</b> Comparison of mean haemoglobin values (g/dl) of catfish sampled during November 2009. OG=Olifants Gorge (n 20), LK=Lunsklip Fisheries (n 21) and RV=Reënvoël Dam (n 14). (p=0.02136, vertical bars denote +/- standard errors)	38
<b>Figure 21:</b> Comparison of mean serum vitamin E values (mg/l) of catfish sampled during November 2009. OG=Olifants Gorge (n 15), LK=Lunsklip Fisheries (n 20) and RV=Reënvoël Dam (n 15). (p=0.00000, vertical bars denote +/- standard errors)	39
<b>Figure 22A:</b> Average glutathione peroxidase (GSH-Px) values ( $\mu$ U/mgHb) of catfish with and without steatitis sampled from all sampling sites	41
<b>Figure 22B:</b> Comparison of average erythrocyte glutathione peroxidase (G-Ps) values ( $\mu$ U/mgHb) of all catfish sampled from the Olifants Gorge sites (n=101) , Lunsklip Fisheries (n=21) and Reënvoël Dam (n=27). (p=0.01185, vertical bars denote +/- standard errors)	41

## LIST OF TABLES

<b>Table 1:</b> Prevalence of macroscopically detectable steatitis lesions in the Olifants Gorge and other reference populations of catfish	11
<b>Table 2:</b> Mesenteric adipose tissue mass relative to body mass of catfish sampled from the Olifants Gorge and other sites on various dates.Olifants Gorge (OG), Engelhard Dam (EH), Mamba Weir (M), Lunsklip Fisheries (LK), Reënvoël Dam (RV), Van Ryssen Dam (FK), Levuvhu River (LUV) and Crocodile River (CR)	12
<b>Table 3:</b> Comparison of percentage polychromatocytes in blood smears collected from catfish at three sampling sites during November 2009	35
<b>Table 4:</b> Mean haematocrit values (packed cell volume=PCV) of blood collected from <i>C. gariepinus</i> from all sites (Olifants Gorge=GL, OGM, OG, OL, LOG, LOC; Lunsklip Fisheries=LK; Reënvoël Dam=RVB; Engelhard Dam=EH; Van Ryssen Dam=FK; Mamba Weir=M; Levuvhu River=LUV; Crocodile River=CR)	36
<b>Table 5:</b> Mean haemoglobin values (g/dl) of blood collected from <i>C. gariepinus</i> from all sites (Olifants Gorge=GL, OGM, OG, OL, LOG, LOC; Lunsklip Fisheries=LK; Reënvoël Dam=RV, RVB; Engelhard Dam=EH; Van Ryssen Dam=FK; Mamba Weir=M; Levuvhu River=LUV; Crocodile River=CR)	37
<b>Table 6:</b> Average serum vitamin E values of catfish from all sites (Olifants Gorge=OGM, OG, OL; Lunsklip Fisheries=LK; Reënvoël Dam=RV; Engelhard Dam=EH; Mamba Weir=M)	38
<b>Table 7:</b> Percentage of catfish from the Olifants Gorge and other sites with serum vitamin E levels below the lower fifth percentile of values of healthy fish sampled from Reënvoël Dam. (Olifants Gorge=OGM, OG, OL; Lunsklip Fisheries=LK; Reënvoël Dam=RV; Engelhard Dam=EH; Mamba Weir=M)	39
<b>Table 8:</b> Average erythrocyte glutathione peroxidase (GSH-Px) values of catfish from all sites (Olifants Gorge=GL, OGM, OG, OL, LOG, LOC; Lunsklip Fisheries=LK; Reënvoël Dam=RV, RVB; Engelhard Dam=EH; Van Ryssen Dam=FK; Mamba Weir=M; Levuvhu River=LUV; Crocodile River=CR)	40





# 1 HISTORY AND BACKGROUND OF STUDY

## 1.1 The Crocodile Mortality Events

The Olifants River Gorge and Lower Letaba River, at the confluence with the Olifants River, in the Kruger National Park (KNP) are home to one of the densest populations of large Nile crocodile (*Crocodylus niloticus*) in South Africa. The raising of the Massingir Dam sluices just inside Mozambique in 2007 has flooded many of the rapids and pools in the gorge. Altered hydrodynamics have resulted in the deposition of clay rich sediments within the aquatic habitat of the area. During the autumn and winter of 2008 and 2009, large numbers of adult crocodiles were found dead in this area, coinciding with flooding of the gorge. Some 180 specimens out of a known population of at least 600 were found dead in 2008 alone. Autopsies performed by KNP veterinarians revealed exceptionally fat carcasses with an abnormal hardening of the fat. Histological examination of tissue specimens by Drs Emily Lane, Johan Steyl and Fritz Huchzermeyer confirmed an inflammation of the fat typical of pansteatitis. On 8 July 2009, for the first time, a large fish mortality event was observed within the Olifants Gorge. Affected fish were almost exclusively large *Clarias gariepinus* specimens and were found in the area overlying the clay rich deposits at the point where the gorge widens into the dam. Fish carcasses were observed to be very fat. The fish kill remained localized in space and time and no mortalities were observed in either the Olifants or Letaba rivers up stream of the gorge, and fish in Lake Massingir appeared unaffected.

## 1.2 Organisational Response to the Crocodile Mortality

In response to the crocodile deaths in 2008, the Consortium for the Restoration of the Olifants Catchment (CROC) was founded as a multidisciplinary initiative. CROC provides the following preamble: "*Crocodile catastrophe – implications for mankind*

- *It is increasingly clear that the crocodile deaths in the Olifants Basin are symptomatic of a serious and growing environmental problem in which a tipping point has been reached / crossed with dramatic unexpected effects*
- *Such a top predator collapse indicates prolonged and cumulative ecosystem stress caused by human activities in which the implementation of our legislated environmental controls and monitoring response proved inadequate.*
- *There are serious implications for human health and well-being if the situation continues and river health is not restored."*

As a result, a collaborative team effort was initiated, including KNP researchers, various universities, government departments and private sector consultants, to investigate various aspects that may have played a role leading to the development of pansteatitis in the crocodiles. This study was based on the assumption that pollution-associated pathology in fish in the Olifants River in the KNP preceded the pansteatitis syndrome that caused the deaths of 180 crocodiles during the winter of 2008 and that certain pathological indicators may be used to monitor the situation along the river.

This report presents the results of the pathology data as collected up until 31 July 2011 for the Consultancy Project K8-948 and discusses the causes of the observed pathology.

## 2 OBJECTIVE

The objective of this project was to identify the range of pathologies present in fish in the lower Olifants and Letaba rivers within the KNP, to determine the significance of these pathologies in terms of pollution and the development of pansteatitis in crocodiles, to differentiate such pathologies from non-pollution related pathology as would be expected in free-living fish in these rivers and to identify improved sacrificial and non-sacrificial methods of monitoring fish health in KNP rivers.

## 3 LITERATURE REVIEW

The Olifants River is regarded as one of the most threatened aquatic ecosystems in Mpumalanga Province of South Africa (Ashton, 2010; de Villiers and Mkwelo, 2009; Heath et al., 2010). Since large numbers of Nile crocodiles (*Crocodylus niloticus*, Laurenti) died from pansteatitis in the Olifants Gorge during 2008 (Ferreira and Pienaar, 2011), a link has been sought to the consequences of human activity in the catchment of the Olifants and Letaba Rivers. The Olifants River originates on the Highveld plateau of Mpumalanga then flows eastwards down the escarpment and traverses the Kruger National Park (KNP) where it is joined by the Letaba River at the entrance to the Olifants Gorge. The gorge extends through the Lebombo Mountains for approximately 9 km, exiting into Lake Massingir in Mozambique. From here the Olifants River continues through Mozambique before discharging into the Indian Ocean. The Olifants catchment has been heavily impacted by human activity including; mining, coal fired electricity generation, industrial and urban wastewater discharges, agricultural practices and water impoundments (Heath et al., 2010), whereas the Letaba catchment has been impacted by agriculture and human settlements. Lake Massingir sustains a considerable freshwater fishery to which has been introduced an aggressively invasive planktivorous species, the silver carp (*Hypophthalmichthys molitrix*, Valenciennes) (Skelton, 2001).

Within the upper Olifants catchment lies Lake Loskop. Nile crocodile mortalities in this lake have coincided with periodic mass die-offs of fish since 2003 (Botha et al., 2011). In the KNP, an estimated 180 large crocodiles died in the Olifants River Gorge during the winter of 2008 following the raising of the sluices of Lake Massingir in Mozambique in 2007 (Ferreira and Pienaar, 2011; Huchzermeyer et al., 2011). However no coincidental fish die-off was observed. The number of deaths has declined during the subsequent winters. Crocodile deaths in the Olifants Gorge continue to be restricted to the winter months and as with the 2008 crocodile mortalities, South African National Parks (SANParks) veterinarians established the cause of death as pansteatitis.

Pansteatitis, resulting from peroxidation of body fat and resultant inflammation of the adipose tissues, has been described from many species of both warm and cold blooded animals. The disease is regarded as a nutritionally mediated condition arising from feeding of diets with low vitamin E content particularly where such diets contain high levels of long chain polyunsaturated fatty acids or rancid fish oils (Wallach and Hoessle, 1968, Smith 1979).

As vitamin E protects against lipid peroxidation, tissue vitamin E levels tend to increase with increase in unsaturated fat intake (Raynard et al., 1991). Where vitamin E intake is insufficient to provide adequate protection against the peroxidation of dietary unsaturated or rancid fats, necrosis and inflammation of the fatty tissues ensues giving rise to the clinical picture of pansteatitis. Fats of fish origin, particularly in the absence of sufficient vitamin E, have most commonly been implicated (Goodwin, 2006; Herman and Kircheis, 1985; Murai and Andrews, 1974; Roberts et al., 1979; Roberts and Agius, 2008, Wallach and Hoessle, 1968).

In crocodiles pansteatitis has been associated with consumption of large numbers of dead and rancid fish following large scale fish mortality (Huchzermeyer, 2003) and with a change in type of fish fed (Wallach and Hoessle, 1968). In Lake Loskop, acid mine seepage was found to be the most likely cause of a mass fish mortality that in 2007 led to the deaths of significant numbers of crocodiles and terrapins as a result of pansteatitis (Myburgh and co-workers, University of Pretoria, pers. comm. 2009). The 2008 episode of crocodile pansteatitis in the KNP differed in that no mass mortality of fish was observed in the affected region. Circumstantial evidence pointed to illegal fishing activity with gill nets as a possible source of dead fish. A link between pollution-induced *in vivo* lipid autoxidation in fish and the subsequent development of pansteatitis in crocodiles has not been elucidated previously.

The pathology of pansteatitis has been reported in the literature for various species of fish (Herman and Kircheis, 1985; Huchzermeyer et al., 2011; Murai and Andrews, 1974; Roberts et al., 1979; Roberts and Agius, 2008). In fish, pansteatitis has been reported as an incidental finding from apparently healthy slaughter fish (Goodwin, 2006). Similar findings of subclinical pansteatitis found at slaughter have been reported from American alligators (*Alligator mississippiensis*) fed over a period of 14 years on predominantly freshwater fish in the form of whole fish, fish heads, skins and entrails (Larsen et al., 1983). Oxidative deterioration of polyunsaturated lipids, leading to lipid peroxidation through the release of free radicals, initiates a sequence of events leading to molecular damage of subcellular membranes and eventually to cell membrane damage (Tappel, 1973). Fish fats are more susceptible to autoxidation than other polyunsaturated fats due to their high content of long-chain polyunsaturated fatty acids, particularly eicosapentaenoic acid [20:5(n-3)] and docosahexaenoic acid [22:6(n-3)] (Gonzalez et al., 1992).

Dependency on lipoprotein polyunsaturated fats for normal metabolic function is more pronounced in poikilothermic animals (cold blooded) such as fish and crocodiles than in homothermic (warm blooded) animals. The elongated and desaturated derivatives of linoleic acid (n-6) and  $\alpha$ -linoleic acid (n-3) are essential fatty acids that affect the fluidity, flexibility and permeability of membranes (Steffens, 1997). Poikilothermic animals such as fish and crocodiles depend on these dietary polyunsaturated fats to maintain membrane fluidity and normal metabolic function especially at colder ambient temperatures. They are thus more sensitive to the effects of lipid autoxidation than warm-blooded animals (Stoskopf, 1993).

There is evidence in the literature linking pro-oxidant or oxyradical production in aquatic organisms to anthropogenic activity resulting in pollution of the aquatic environment (Bainy et al., 1996, Winston and DiGiulio, 1991). Histopathological tissue changes in fish have been proposed as a sensitive tool for assessing such exposure to pollution in the aquatic environment (Adams et al., 1993; Bernet et al., 1999; Heath et al., 2004, Roberts and Agius, 2003). The useful role of fish in sediment toxicity assessments has been reviewed by Halare et al., 2011, who stress the importance of benthic rather than pelagic fish species in such studies. Histology used to monitor health status of *Hydrocynus vittatus*, *Labeobarbus marequensis*, *Labeo rosae* and *L. cylindricus*, fish representing different trophic levels in the Olifants River in the KNP, showed that these species were in a healthy state (Wagenaar et al., 2012a, Wagenaar et al., 2012b).

It is known that vitamin E plays an important role in nature as an *in vivo* antioxidant preventing the oxidative conversion of polyunsaturated fats into lipid hydroperoxides (Burton, 1994; Bus et al., 1976; Hove 1955; Niza et al., 2003; Stoskopf, 1993). Such lipid peroxides are held responsible for the various changes observed in animals deprived of vitamin E (Hove, 1955). Several exogenous substances have been reported in the literature to promote the peroxidation of fats, including consumption of unsaturated fat (Burton, 1994). These reactions can be mitigated by the presence of adequate dietary vitamin E (Stoskopf, 1993). Under conditions of dietary oxidant overload, depletion of hepatic vitamin E has been shown to occur in sharp-toothed catfish (Baker et al., 1997).

Basic biological processes such as cellular respiration and the action of certain enzymes lead to production of reactive oxygen species within the body. Imbalances in generation and removal of radical species result in the oxidative stress that has the potential to cause biological injury. Certain xenobiotics capable of redox cycling have the ability to enhance the production of such oxyradicals within cells (Kelly et al., 1998). Xenobiotics capable of redox cycling include quinones, some dyes, bipyridyl herbicides, some transition metals and aromatic nitro compounds (Kelly et al., 1998). The herbicide, paraquat, has been used as an oxidant model causing lipid peroxidation of cell membranes in both humans and animals (Åkerman et al., 2002; Bus et al., 1976; Parvez and Raisuddin, 2005). The cyclical reduction-oxidation of paraquat results in generation of superoxide radicals which dismutate to singlet oxygen. Singlet oxygen reacts with unsaturated lipids in cell membranes to form lipid hydroperoxides. The chain reaction leading to the membrane destructive process of lipid peroxidation results from the spontaneous decomposition of lipid hydroperoxides to lipid free radicals (Bus et al., 1976). The toxic manifestations of other xenobiotics have also been ascribed to oxidative damage. Bachowski et al. (1998) observed a reduction in hepatic and serum  $\alpha$ -tocopherol level in mice and rats exposed to dietary dieldrin. It has similarly been proposed that the hepatic lipid peroxidation and DNA damage in rats exposed to the polyhalogenated hydrocarbons, lindane, DDT, chlordane and endrin was a result of oxidative tissue damage that may contribute to the toxic manifestations of these xenobiotics (Hassoun et al., 1993).

Mammalian organisms use three defence mechanisms to counter the destructive process caused by oxidative stress. Super oxide dismutase scavenges toxic superoxide radicals, endogenous anti-oxidants such as vitamin E terminate the free radical chain reaction of lipid peroxidation and glutathione peroxidase enzymatically reduces the unstable lipid hydroperoxides to stable lipid alcohols thus preventing further formation of free radicals (Bus et al., 1976). Vitamin E acts as hydrogen atom donor thereby preventing the reactive lipid peroxy radicals from abstracting hydrogen atoms from *in vivo* sources such as DNA and proteins (Kelly et al., 1998). These defence mechanisms and related biomarkers have been used in mammalian and fish tissues to measure the effects of pro-oxidant exposure (Awad et al., 1994; Parvez and Raisuddin, 2006) and measurement of thiobarbituric acid reactive substances (TBARS) has been used to determine levels of malondialdehyde, one of the end products of lipid peroxidation, in plasma (Hinchcliff and Piercy, 2000).

Vitamin E is the generic name used to describe the four tocopherols and four tocotrienols that make up this group of lipid soluble substances (Burton, 1994). Of these,  $\alpha$ -tocopherol is the most biologically active. For reasons of consistency the term vitamin E will be used with reference to  $\alpha$ -tocopherol in the further text of this manuscript. Amongst mammals, cats are known to be particularly sensitive to ingestion of polyunsaturated fats. Fytianou et al. (2006) reported measurable changes in the levels of vitamin E and the enzyme glutathione peroxidase in the blood of kittens exposed to experimental diets rich in rancid fats. In rainbow trout, Bell et al. (1985) demonstrated reduced glutathione peroxidase activity with dietary selenium deficiency whereas serum glutathione peroxidase activity appeared independent of vitamin E intake. Tissue and plasma vitamin E has been shown to increase significantly in response to dietary vitamin E intake in sharptooth catfish but was rapidly utilised in tissues challenged by the oxidative stress caused by ingestion of oxidised dietary fats, leading to appearance of vitamin E deficiency signs and increased free radical tissue damage (Baker and Davies, 1997).

## 4 MATERIALS AND METHOD

### 4.1 Fieldwork

The focus of the fieldwork has been on the Sharptooth catfish (*C. gariepinus*, Burchell), as this is a possible major food source for crocodiles along the Olifants River gorge and lower Letaba River. Being an omnivorous benthic scavenger it is likely that this species would be preying on other weakened fish species in the system. Samples were collected and processed over a 2 year period between November 2009 and November 2011. Data from fish sampled prior to this period have been included in the study. Collection of fish samples from the Olifants Gorge has taken place every six months, once during mid to late winter (June-September) when river flow had subsided, most of the rainfall related sediment load had been dropped and water temperatures had reached their winter minimum and once during mid-summer (January to April) when river flow and sediment load were high. A minimum of 20 fish were collected during each of the sampling episodes. Fish were caught by baited hook and line and by netting. A range of fish species, including Mozambique tilapia (*Oreochromis mossambicus*, Peters) were included in samplings done prior to November 2009. During the June 2011 sampling in the Olifants Gorge, tiger fish (*Hydrocynus vittatus*, Castelnau) were also sampled from the confluence of the Olifants and Letaba rivers.

### 4.2 Description of Study Area

Samplings took place from the confluence of the Olifants and Letaba rivers (23°59'21.8"S 31°49'35.6"E), where the Olifants River enters a 9 km long gorge through the Lebombo Mountains, to where it enters Lake Massingir on the Mozambique border (23°57'48"S 31°52'97"E). Catfish specimens were also collected from various other localities within and outside the KNP. Subject to catch success, up to 20 fish were collected on each sampling occasion. These included a negative reference population in Reënvoël Dam (23°58'37.2"S 31°19'38.4"E) that has its entire catchment within the KNP, and a wild population in Van Ryssen Dam (24°00'13.6"S 31°05'36.9"E) at the FOSKOR phosphate mine in Phalaborwa just west of the KNP. Upstream of the gorge fish were sampled at Mamba Weir (24°03'32"S 31°14'14"E), where the Olifants River enters the western boundary of the KNP. On the Letaba River fish were sampled from Engelhard Dam (23°50'19"S 31°28'28"E). Further south in the KNP samplings took place from the Sabiepoort (25°10'25.41"S 32°02'23.42"E), where the Sabie River enters Lake Corumana on the Mozambique border and from the Crocodile River (25°23'57.1"S 31°57'29.9"E) on the southern boundary of the Park. In the north of the KNP, fish were sampled from the Levuvhu River (22°25'51.0"S 31°18'04.4"E). Catfish were also sampled from a farmed population at Lunsclip Fisheries (25°23'08,9"S 30°15'35"E) near Lydenburg, Mpumalanga. These fish were fed almost exclusively an excess of trout slaughterhouse waste, rich in polyunsaturated fat. Slaughterhouse waste, consisting largely of fat rich innards, was dumped into the catfish pond where it was left to be consumed by the fish. Trout farmed at Lunsclip fisheries were fed a commercial trout ration which was top-dressed with additional marine fish oil.



### 4.3 Specimen Collection

All fish were kept alive until they could be examined. Depending on sampling episode catfish were either processed at the sampling site or transported live in fish transport tanks to various laboratory facilities. All fish sampled prior to November 2009 were examined in a field laboratory set up at the confluence of the Olifants and Letabarivers. During November 2009, catfish sampled from the Olifants Gorge and from Reënvoël Dam were transported live to Lydenburg where the author's autopsy facility was used. Catfish from Lunsklip Fisheries were examined and processed on site at Lunsklip Fisheries. All catfish specimens collected during the July 2010 sampling, with the exception of those sampled from the Sabiepoort were transported live to Skukuza where the large autopsy facility was used. A limited field laboratory set up in the Sabiepoort was used to examine fish from this site. Catfish sampled from the Olifants Gorge during January and June 2011 as well as tiger fish sampled during June 2011 were examined at a field laboratory set up near the confluence of the Letaba and Olifants Rivers. Catfish sampled from Reënvoël Dam during January 2011 were sampled at a field laboratory set up at this site. Catfish from van Ryssen Dam were transported live to the field laboratory at Reënvoël Dam. Catfish collected from the Levuvhu and Crocodile Rivers during June 2011 were transported live to the field laboratory at the confluence of the Olifants and Letaba rivers. Sampling from the Sabiepoort and from Van Ryssen Dam had not been included in the original protocol and as result of time constraints and limited facilities at the respective sampling sites no blood samples or weights of fat tissues were collected from these fish.

Four examination fish were placed into a water bath containing benzocaine hydrochloride as anaesthetic at approximately 30 ppm. Anaesthetised fish were subjected to weight and length measurements, body condition scoring and blood collection. Detailed data sheets were completed for all gross observations and measurements. Blood was collected through a 20 gauge hypodermic needle into a 5 ml syringe from the large vessels just ventral to the vertebral canal in the tail area caudal to the abdominal cavity or from the large blood vessels running through the kidney. Collected blood was directly transferred to both EDTA and serum tubes. EDTA tubes were gently shaken to avoid clotting and were wrapped immediately in aluminium foil to prevent exposure to sunlight. Samples for serum were centrifuged to separate the blood from the serum after clotting had occurred. Fresh blood smears were made from all fish. Fish were then humanely euthanized through an over-dose of benzocaine hydrochloride. The collected fish were examined by autopsy for gross pathological changes. Samples from a range of suitable organs and tissues were fixed in 10% buffered formalin.

The major part of the visceral fat of sharptooth catfish is stored within the mesenteries forming a discrete body towards the caudal portion of the abdominal cavity. A further discrete body of fat originating from the hypodermal fat layer is situated behind the pectoral fin. This fat cushion overlies an extension of the anterior kidney and liver into the hypodermal space, a feature unique to this species. For the purposes of this manuscript these two discrete fat depots will be referred to as mesenteric and pectoral fat respectively. Samples

of liver, mesenteric fat, pectoral fat and eyes were collected on ice for toxicological examination. Pectoral and mesenteric fat were collected for determination of fatty acid composition. Otoliths were collected from all specimens for age determinations.

#### **4.4 Laboratory Work**

Tissue specimens fixed in 10% formalin were processed using standard histological technique. Paraffin wax sections were cut at 5µm. All specimens were stained with haematoxylin eosin (HE). Selected specimens were stained in addition with Gomori's aldehyde fuchsin (GAF), periodic acid Schiff's (PAS) and Perl's Prussian blue stain. Sections were prepared from the following organs and tissues of all sampled fish: mesenteric fat, pectoral fat, hypodermal and intramuscular fat, brain fat, liver, spleen, kidney, pancreas, heart, gonad, muscle, skin, gills and brain. Blood smears were fixed and stained with a CAM's quick stain (Kyro-Quick stain, Kyron Laboratories). Histological sections and blood smears were examined by standard light microscopy for presence of pathology. Microtome sections of all otoliths were examined under the light microscope. Growth rings were counted to determine the age of the fish. To determine the haematocrit of the fish, capillary tubes were filled and sealed before centrifugation on a field micro-centrifuge. Packed cell volume (PCV) was expressed as percentage of the height of the red cell column compared to the total column height. All changes were recorded in detail and the relevant information added to the fish data sheets.

Based on the use of blood glutathione peroxidase and vitamin E measurements in studies of the acute effects of steatitis in kittens (Fytianou et al, 2006) and dietary vitamin E and selenium deficiency in rainbow trout (Bell et al., 1985), and the ready availability of these tests from commercial laboratories in South Africa, it was decided to include measurement of these blood parameters in this study in an attempt to identify tests suitable for non-lethal monitoring of steatitis in catfish of the KNP. Blood and serum samples were submitted to IDEXX Laboratories for determination of haemoglobin, erythrocyte glutathione peroxidase and serum vitamin E values.

#### **4.5 Statistical Analysis**

Data obtained from the blood chemistry and haematological examinations were grouped into two categories: those collected from fish with steatitis (category 1) and those collected from fish where steatitis could not be demonstrated either macroscopically or histologically (category 2). T-tests were used to compare mean haematocrits (PCV), mean serum vitamin E and mean haemoglobin values between steatitis positive and steatitis negative fish sampled from the Olifants Gorge and from Lunsklip Fisheries. Type 1 error levels below 0.05 (5%) were accepted as significant. A second set of data was arranged to compare means of all data for a particular dependent variable between sampling sites without differentiating whether the samples were obtained from fish with or without steatitis. The data were statistically analysed using analysis of variance followed by the post-hoc Tukey HSD Test (Agresti and Franklin, 2007). The non-parametric Kruskal-Wallis test was used as an additional approach to the data analysis (Agresti and Franklin, 2007). For comparison of the percentage of fish with

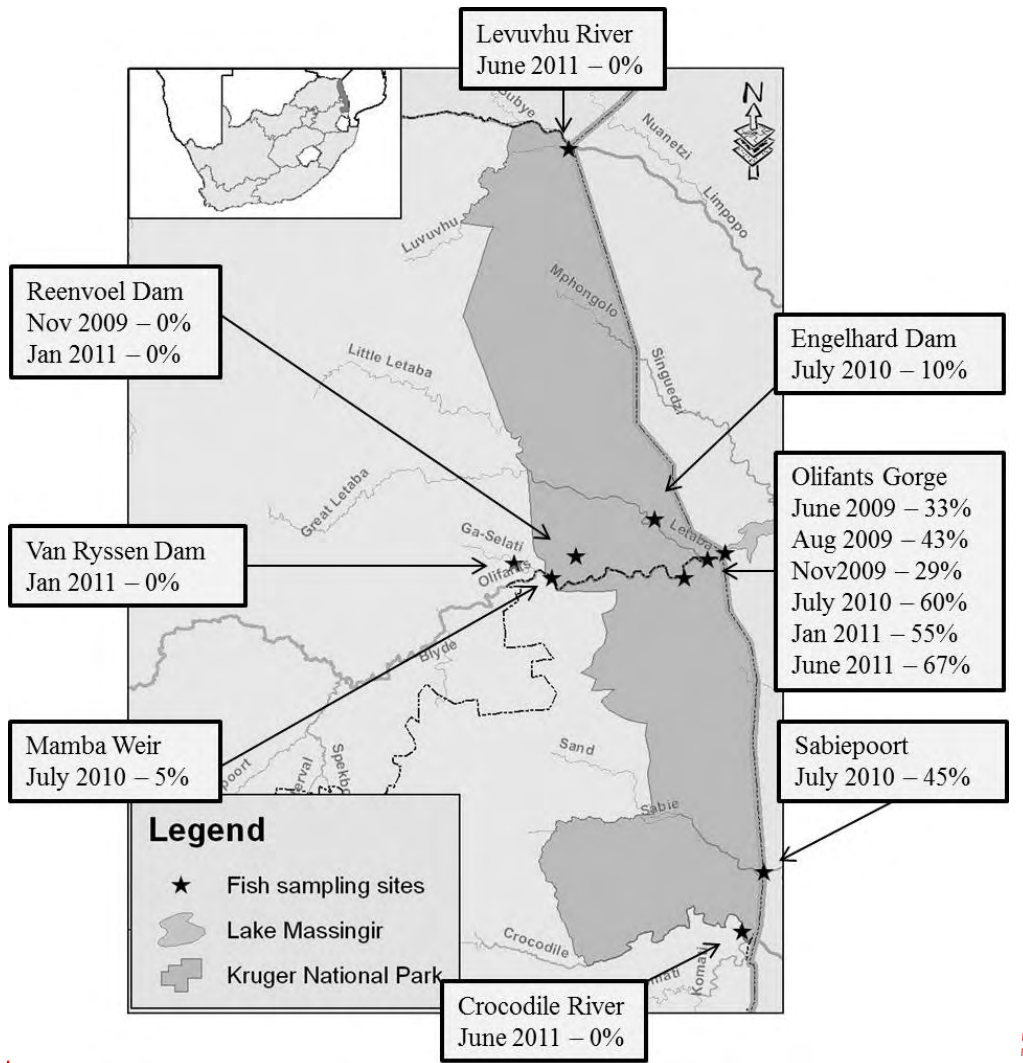
suppressed serum vitamin E values between sites the chi-squared test was used. All statistical analyses were done using Statistica 10 (Statsoft).

## 5 RESULTS

### 5.1 Steatitis Prevalence

The most distinctive pathology observed in catfish from the Olifants Gorge was centred in the adipose tissues of the fish. Presence of macroscopic lesions of fat necrosis and associated inflammation of the adipose tissues was used to determine steatitis prevalence in the KNP rivers (Figure 1). A high prevalence of steatitis was repeatedly identified in catfish sampled from the Olifants Gorge between August 2009 and July 2011. Steatitis prevalence similar to that found in fish from the Olifants Gorge was detected in catfish sampled from the Sabiepoort during a single sampling in July 2010. Lesions in the adipose tissues were identical to those observed in fish from the Olifants Gorge and splenomegaly and pancreatic atrophy were similarly observed. Lower steatitis prevalence was observed in fish sampled from Engelhard Dam. However, the severity of steatitis lesions in one fish from this site was comparable to that of severely affected fish from the Olifants Gorge and Lunsklip Fisheries. In catfish sampled from Mamba Weir a low prevalence of steatitis was noted. Macroscopically no steatitis could be identified in fish sampled from Reënvoël Dam during November 2009 and again during a repeat sampling in January 2011. Similarly, steatitis could not be detected in fish sampled from van Ryssen Dam (Figure 1). These fish carried exceptionally heavy burdens of *Contracaecum* spp. larvae in the peritoneal cavity. Steatitis could also not be demonstrated in catfish sampled from the Levuvhu and Crocodile rivers. Fish from both sites carried relatively low parasite burdens. Fish from the Levuvhu River carried more fat in their adipose tissues than fish sampled from the Olifants Gorge during the same period whilst fish from the Crocodile River were notably leaner than fish from the Olifants Gorge (Table 2).

Lesions identical to those found in the adipose tissues of catfish from the Olifants Gorge, the Sabiepoort and Engelhard Dam were observed in a captive population of catfish at Lunsklip Fisheries. The majority of these fish had severe visible changes in the fat associated with pansteatitis (Table 1) and provided the study with an identified positive control for evaluation of gross pathology and histology. Although steatitis was observed macroscopically in 66% of fish sampled from Lunsklip Fisheries, 95% of these fish showed steatitis on histological examination. The majority of these fish had very large mesenteric fat reserves (Table 2, Figure 3).

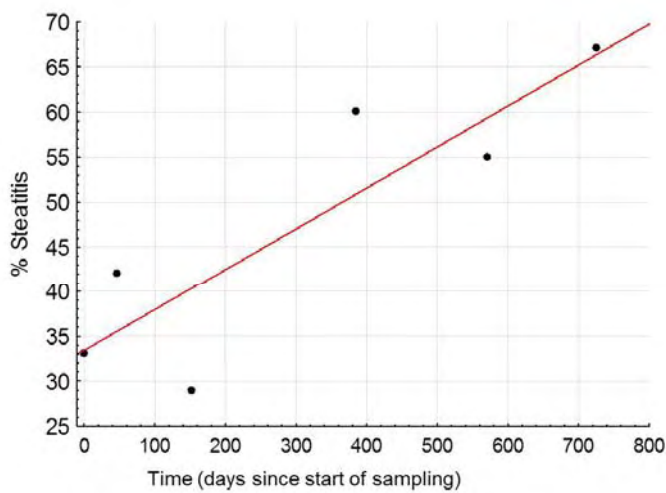


Formatted: English (U.S.), Do not check spelling or grammar

**Figure 1:** Macroscopic steatitis prevalence as percentage of sampled catfish from various sampling sites in Kruger National Park during the period 2009-2011

**Table 1:** Prevalence of macroscopically detectable steatitis lesions in the Olifants Gorge and other reference populations of catfish

Date	Sampling site	% fish with steatitis	Total fish sampled
June 2009	Olifants Gorge	33	9
August 2009	Olifants Gorge	43	14
November 2009	Olifants Gorge	29	21
November 2009	Reënvoël Dam	0	28
November 2009	Lunsklip Fisheries	66	21
July 2010	Olifants Gorge	60	25
July 2010	Mamba weir	5	20
July 2010	Engelhard Dam	10	21
July 2010	Sabiepoort	45	11
January 2011	Olifants Gorge	55	22
January 2011	Reënvoël Dam	0	13
January 2011	Van Ryssen Dam	0	10
June 2011	Olifants Gorge	67	21
June 2011	Levuvhu River	0	14
June 2011	Crocodile River	0	20



Correlation coefficient:  $r = 0.87$  Significance of model:  $p = 0.02$

**Formatted:** Font: (Default) Times New Roman, 12 pt, English (U.S.), Do not check spelling or grammar

**Figure 2:** Prevalence of steatitis in catfish sampled from various localities along the Olifants and lower Letaba rivers in the Kruger National Park from 2009 to 2011


In the Olifants River Gorge, where repeated samplings have taken place since 2009, an increase in prevalence of steatitis in sampled catfish was detected (Figure 2). Most catfish from the Olifants Gorge, as well as from the Sabiepoort, were found to store relatively larger amounts of fat compared to catfish sampled from other localities in KNP. However the amount of fat carried was considerably less than that carried by the fish from Lunsklip Fisheries. A decline over time in amount of stored fat in catfish sampled from the Olifants Gorge was noted during repeat samplings between November 2009 and June 2011. Mesenteric fat made up 4.59% of body mass in the most obese specimen from the Olifants Gorge sampled during November 2009, whereas it only constituted 0.88% of body mass in the most obese specimen sampled during June 2011. By contrast, the most obese fish sampled from Lunsklip Fisheries carried more than 12% of body mass as mesenteric fat. Fish sampled from the Olifants Gorge during June 2011 were distinctly leaner than fish sampled during July 2010 and several wasted fish were caught from the Olifants Gorge during the 2011 samplings. One of these fish was extremely emaciated but nevertheless had a reasonable amount of fat stored in the mesenteric adipose tissue. Steatitis was evident in the adipose tissue of this fish. Most catfish sampled from Engelhard Dam, Mamba Weir, Reënvoël Dam and van Ryssen Dam were lean (Table 2).

**Table 2:** Mesenteric adipose tissue mass relative to body mass of catfish sampled from the Olifants Gorge and other sites on various dates. Olifants Gorge (OG), Engelhard Dam (EH), Mamba Weir (M), Lunsklip Fisheries (LK), Reënvoël Dam (RV), Van Ryssen Dam (FK), Levuvhu River (LUV) and Crocodile River (CR)

Sampling site	Date	Fat % of body mass				
		Mean	Standard Deviation	Sample variance	Range	n
OG	Nov-09	1.17	1.36	1.86	0.08-4.59	20
OG	Jul-10	1.12	1.02	1.05	0-3.68	25
OG	Jan-11	0.4	0.8	0.64	0.02-3.8	22
OG	Jun-11	0.18	0.2	0.04	0.02-0.88	21
EH	Jul-10	0.19	0.4	0.16	0-1.57	21
M	Jul-10	0.16	0.24	0.06	0-0.74	20
LK	Nov-09	4.61	3.45	11.89	1.01-12.07	21
RV	Jul-10	0.32	0.29	0.08	0-0.88	13
FK	Jul-10	0.05	0.08	0.01	0-0.26	10
LUV	Jun-11	0.96	0.78	0.61	0.03-2.2	14
CR	Jun-11	0.14	0.16	0.03	0-0.53	20

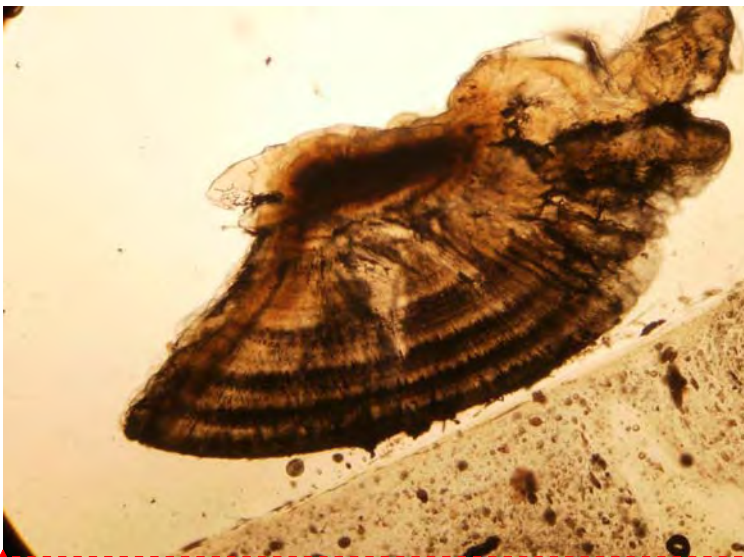
Ages of fish sampled from the Olifants Gorge ranged from 1 to 19 years with steatitis being observed in both male and female fish from 3 to 19 years of age (Figure 3). No correlation was observed between age and severity of steatitis. Ages of fish sampled from Reënvoël Dam similarly ranged from 1 to 19 years with both male and female fish represented.





**Formatted:** Font: (Default) Times New Roman, 12 pt, English (U.S.), Do not check spelling or grammar

**Figure 3A:** Growth rings in the otolith of a 19 year old catfish specimen from the Olifants Gorge



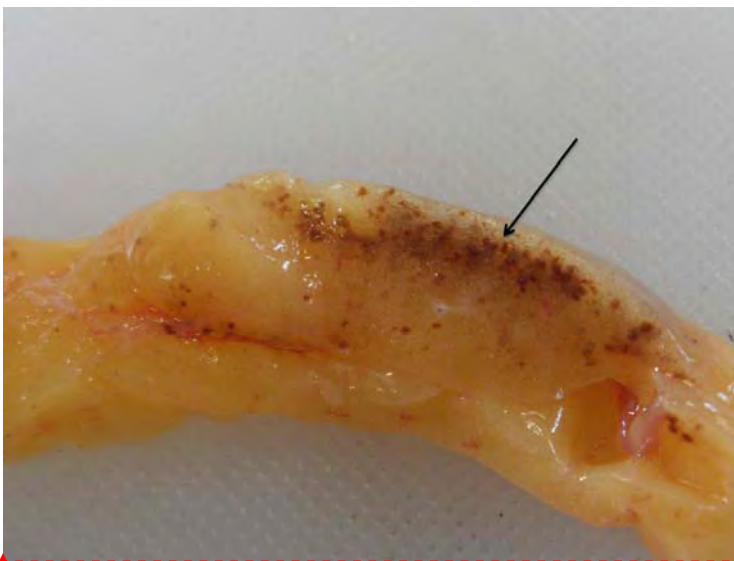**Formatted:** Font: (Default) Times New Roman, 12 pt, English (U.S.), Do not check spelling or grammar

**Figure 3B:** Growth rings in the otolith of a 4 year old catfish specimen from the Olifants Gorge

## 5.2 Macroscopic Pathology

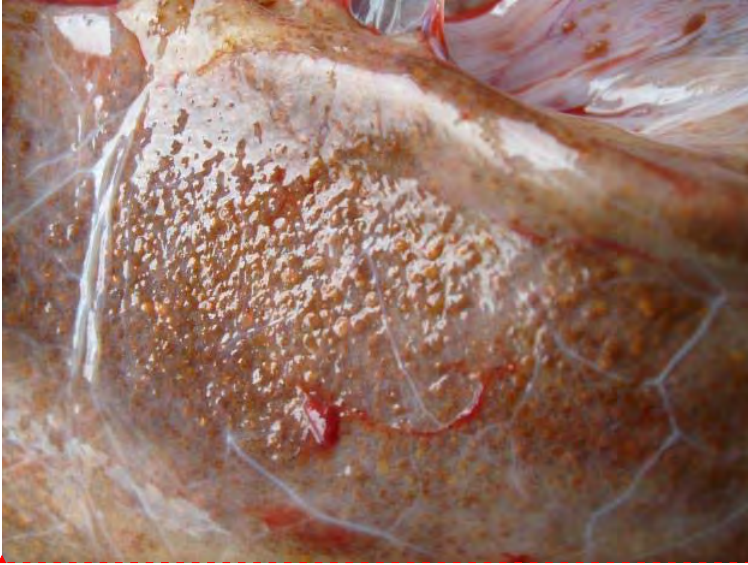Necrosis and associated steatitis was observed repeatedly in the adipose tissues and, other than severity, there was no distinction between the lesions observed in catfish sampled from the Olifants Gorge, Engelhard Dam, Sabiepoort and the positive reference population at Lunsklip Fisheries. Steatitis lesions presented as distinct white and brown spots (Figure 4A), consisting of small focally disseminated to coalescing granulomata up to 5 mm in diameter. In more advanced cases lesions were characterized by a brown colour, sometimes with an orange coloured centre. Affected mesenteric fat, in severe cases, had a rubbery consistency and brown granulomata were confluent throughout the fat (Figures 4B and 4C).

In catfish with steatitis from both the Olifants Gorge and Lunsklip Fisheries, lesions were mostly restricted to the mesenteric fat tissue. In severely affected fish the caudal section of the mesenteric fat body was often adhered to the hind gut and the caudal section of the gonads (Figure 5). In milder cases granulomata were more densely concentrated on the parietal aspect of the fat body closest to the mesenteric insertion (Figure 4A). Layers of fat with differing severity of steatitis were observed in some fish. Presence of both coalescing granulomata and scarring of the adipose tissues and earlier lesions characterized by focal brown spots in the fat appeared to indicate an on-going incitement of fat necrosis in catfish of the Olifants Gorge. Only occasional fish showed steatitis in the pectoral fat cushion (Figure 6A) and the intramuscular fat (Figure 6B). Steatitis could not be demonstrated in the epicardial fat. In fish with generalised pansteatitis, lesions could however be demonstrated in the brain fat (Figure 6C).



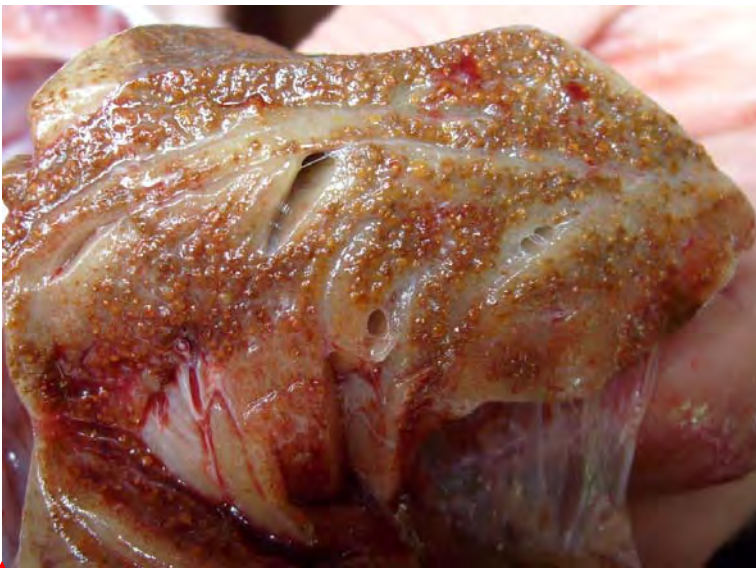Formatted: Font: (Default) Times New Roman, 12 pt, English (U.S.), Do not check spelling or grammar

**Figure 4A:** Early steatitis lesion in catfish sampled from the Olifants Gorge during July 2010. Note the small sharply circumscribed foci of fat cell necrosis and associated ceroid deposition imparting the characteristic brown colour (arrow)



**Formatted:** Font: (Default) Arial, 10 pt, English (U.S.), Do not check spelling or grammar

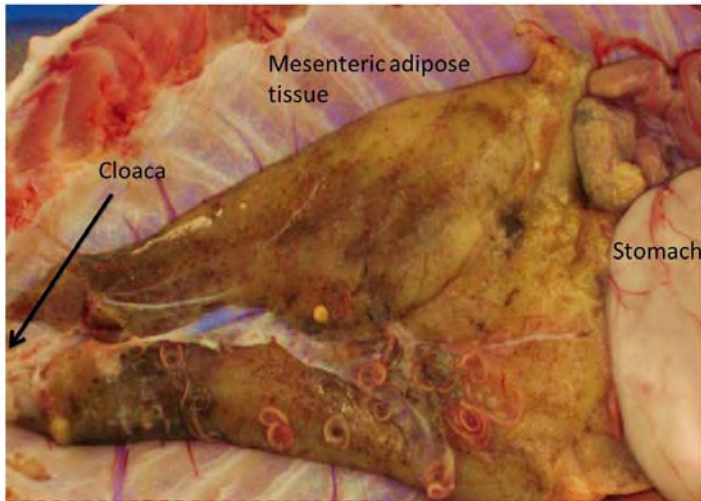
**Figure 4B:** Advanced steatitis of mesenteric fat of a catfish specimen sampled from the Olifants Gorge during November 2009. Note the diffuse brown granular appearance of the fat, the rough surface and virtually total absence of normal appearing fat



**Formatted:** Font: (Default) Times New Roman, 12 pt, Bold, English (U.S.), Do not check spelling or grammar

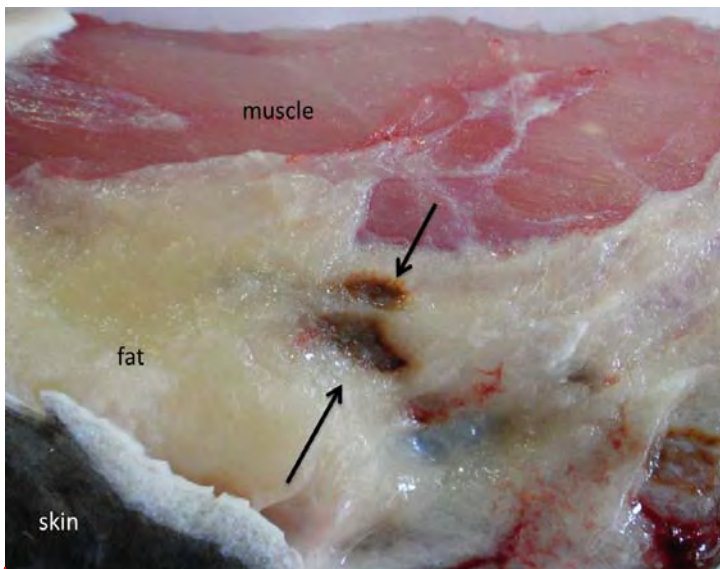
**Figure 4C:** Cross section of mesenteric adipose tissue from a catfish specimen collected from the Olifants Gorge in November 2009 showing typical severe steatitis. Note brown granuloma formation within the adipose tissue





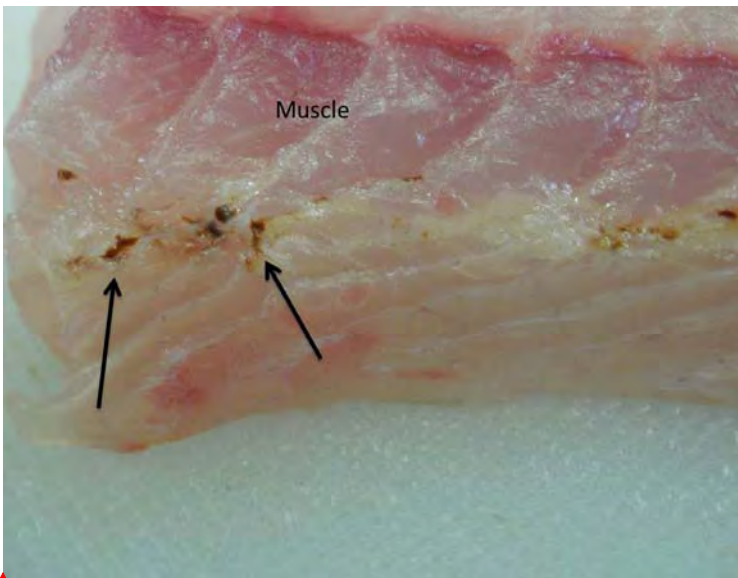
**Formatted:** Font: (Default) Times New Roman, 12 pt, English (U.S.), Do not check spelling or grammar

**Figure 5:** Steatitis of the mesenteric adipose tissues in a catfish sampled from the Olifants Gorge during June 2011. Note that the caudal portion of the mesenteric fat body appears more severely affected



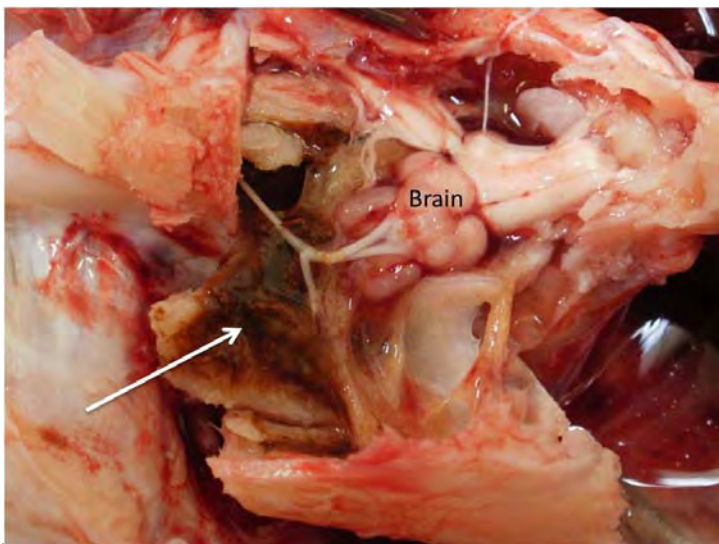
**Formatted:** Font: (Default) Times New Roman, 12 pt, Bold, English (U.S.), Do not check spelling or grammar, Kern at 18 pt

**Figure 6A:** Focal fat necrosis (arrows) in the pectoral fat of a catfish sampled from the Olifants Gorge during July 2010



**Formatted:** Font: (Default) Times New Roman, 12 pt, Bold, English (U.S.), Do not check spelling or grammar, Kern at 18 pt

**Figure 6B:** Focal steatitis (arrows) in the intramuscular fat of a catfish sampled from the Olifants Gorge during July 2010



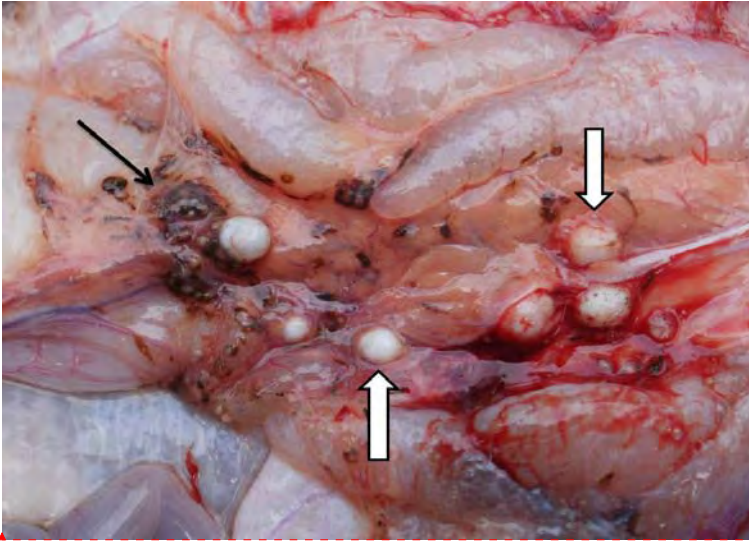
**Formatted:** Font: (Default) Times New Roman, 12 pt, English (U.S.), Do not check spelling or grammar

**Figure 6C:** Generalised steatitis in the fat surrounding the brain of a catfish sampled from the Olifants Gorge during July 2010. Note brown discolouration of fat (arrow) adhering to the opened cranium

Catfish specimens collected from the Olifants Gorge and lower Letaba River during the samplings prior to November 2009 presented with large amounts of variably coloured fat in the body cavity and between the muscles of the tail. The variation in colour, from a cream white to dark yellow, continued to characterize the mesenteric fat of catfish from all samplings in the Olifants Gorge, despite the reduction in quantity of mesenteric fat noted during subsequent samplings (Table 2). There was no correlation between fat colour and steatitis. Microscopic examination of histological sections of fat from sampled fish confirmed the macroscopic diagnosis of steatitis (Figures 12A and 12B). The detailed pathology and histopathology of the organs and the specific lesions associated with fat necrosis in fish from the Olifants Gorge have been published (Huchzermeyer et al., 2011).

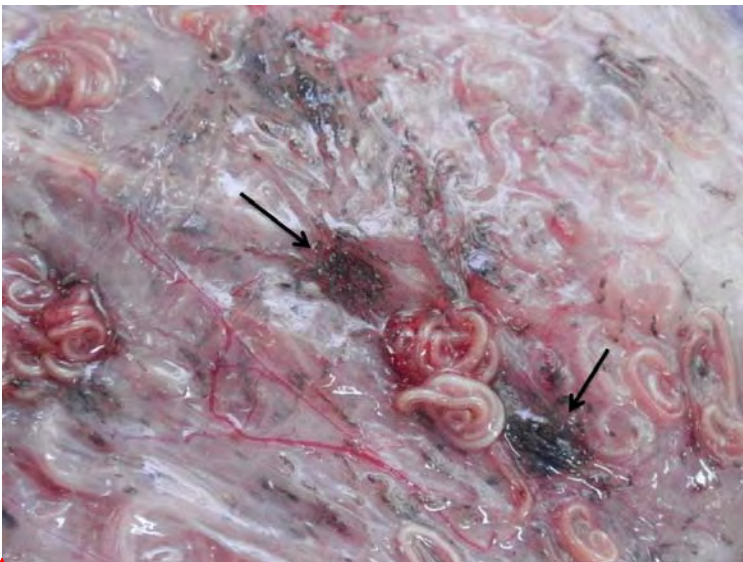Incidental pathology in adipose tissue associated with presence of parasites was noted in many fish and could be differentiated from changes associated with steatitis in the fat tissues. Cysts of digenean parasites, varying in size from 2 to 15 mm in diameter, were occasionally noted in the mesenteric adipose tissues of fish sampled from the Olifants Gorge. Cysts mostly appeared as well circumscribed, hard, white nodules sometimes focally disseminated throughout the mesenteric fat (Figure 7). On incision these consisted of a dense connective tissue capsule surrounding a central parasitic larva. In some cases an irregular brown discolouration as a result of melanin deposition was noted in the adjoining tissue. Such granulomata were distinct from those caused by fat necrosis. *Contracaecum* spp. larval nematodes were present in variable numbers within the peritoneal cavity of most fish sampled from the Olifants Gorge. Brown melanisation of focal areas of the mesenteries overlying the mesenteric fat was occasionally noted in the presence of severe infestation with *Contracaecum* spp. larvae. This was particularly evident in catfish sampled from van Ryssen Dam (Figure 8). As in the case of larval digenean trematode cysts, such discolouration differed distinctly from the discolouration associated with steatitis. There was no correlation between severity of infestation with nematode larvae or digenean trematodes and steatitis. The brown discolouration of the fat and mesenteries associated with parasites was shown histologically to be caused by melanin. Both lipopigment and ceroid were absent from such lesions.





**Formatted:** Font: (Default) Times New Roman, 12 pt, Bold, English (U.S.), Do not check spelling or grammar

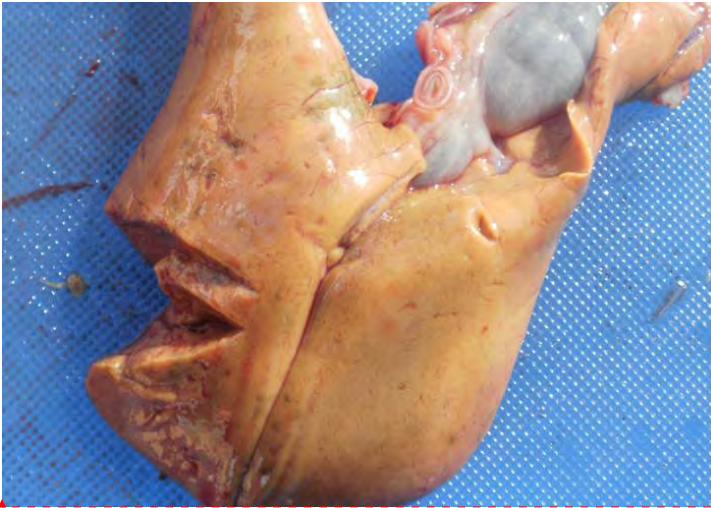**Figure 7:** Melanin deposition (black arrow) associated with digenean trematodes cysts (block arrows) in the caudal mesenteric fat between the male accessory sexual glands of a catfish sampled from Reënvoël Dam in KNP



**Formatted:** Font: (Default) Times New Roman, 12 pt, English (U.S.), Do not check spelling or grammar

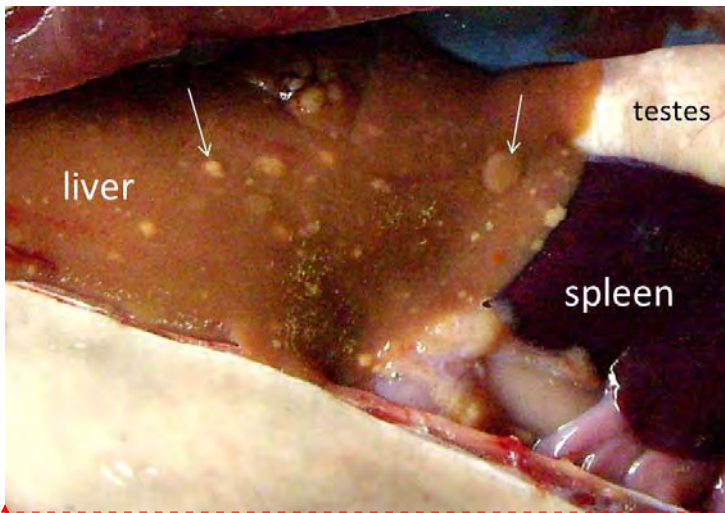
**Figure 8:** Melanin deposition (arrows) in vicinity of larval nematodes in the mesentery overlying the mesenteric fat in a catfish sampled from van Ryssen Dam at the FOSKOR mine in Phalaborwa

Livers of fish sampled from the Olifants Gorge varied in colour but appeared more orange, fatty and swollen in appearance than in fish sampled elsewhere (Figure 9A). Livers of fish with good fat reserves often showed small focal deposits of fat visible on the surface of the livers (Figure 9B). Pale zones were sometimes observed in parts of the liver, occasionally extending into the hypodermal lobe of the organ. Most of the pansteatitis-affected fish from the Olifants Gorge and Lunsklip Fisheries showed severely enlarged and rounded spleens with a rough surface (Figure 10A). The healthy spleen of *C. gariepinus* is an oval flat structure with sharp edges and a smooth surface. Atrophy of the pancreas was evident macroscopically in fish suffering from pansteatitis, however the histological picture revealed normal appearing acinar cells and Langerhans islets indicating that the reduction in pancreatic prominence was a result of reduced pancreatic activity in fish with steatitis rather than of specific pathology. During the early samplings in the Olifants Gorge during 2008 and 2009, gills of many catfish appeared paler than normal and mildly hyperplastic. During later samplings this was no longer evident. Furthermore gill pallor appeared to be affected by temperature of the holding water and length of time that fish were kept in the holding tanks. With warmer water temperature and longer holding periods gills appeared paler.



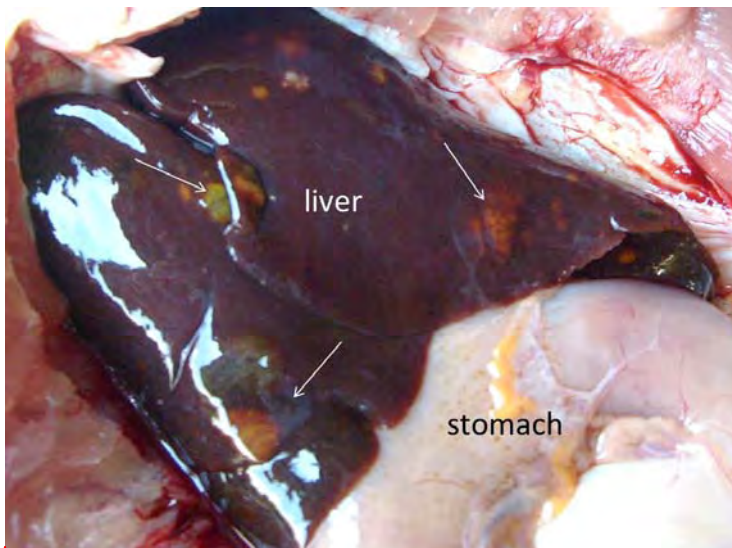
**Formatted:** Font: (Default) Times New Roman, 12 pt, English (U.S.), Do not check spelling or grammar

**Figure 9A:** Swollen fatty appearing liver typical of a catfish suffering from steatitis, sampled from the Olifants Gorge during June 2011



Formatted: Font: (Default) Times New Roman, 12 pt, English (U.S.), Do not check spelling or grammar

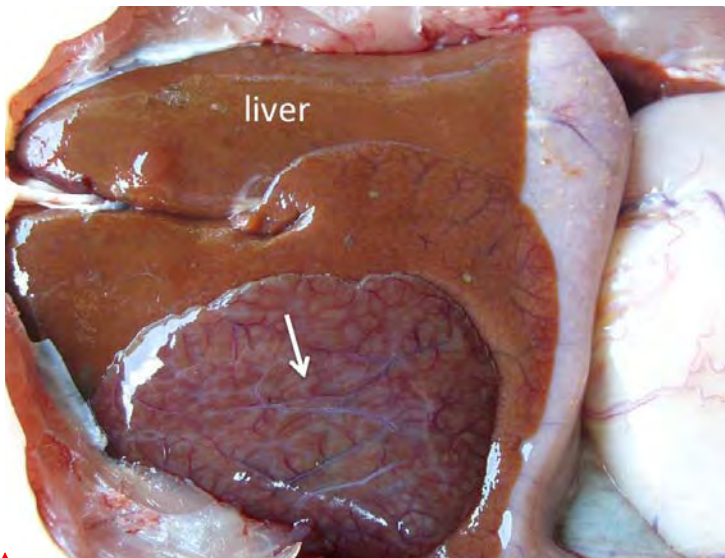
**Figure 9B:** Focal fat deposits beneath the liver capsule from a catfish with steatitis sampled from Lunsklip Fisheries during November 2009



Formatted: Font: (Default) Times New Roman, 12 pt, English (U.S.), Do not check spelling or grammar

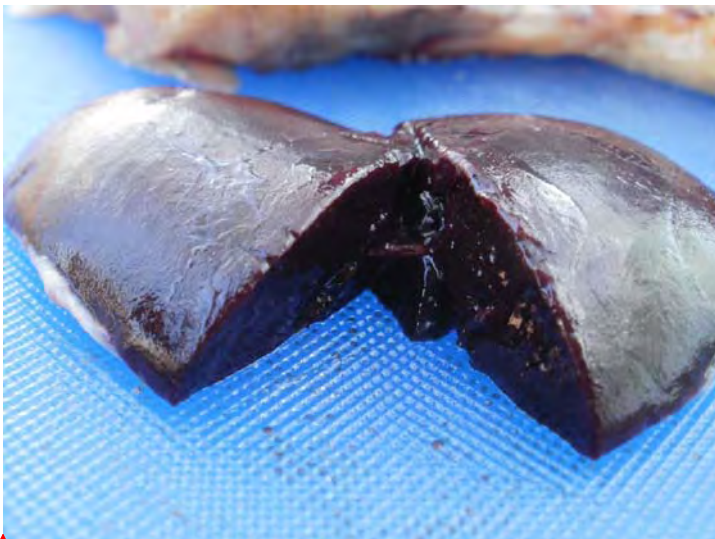
**Figure 9C:** Liver from a catfish sampled from Reënvoël Dam during November 2009. Arrows show damage associated with parasitic cysts in the liver parenchyma. Note the dark colour and sharp liver borders of an otherwise healthy liver





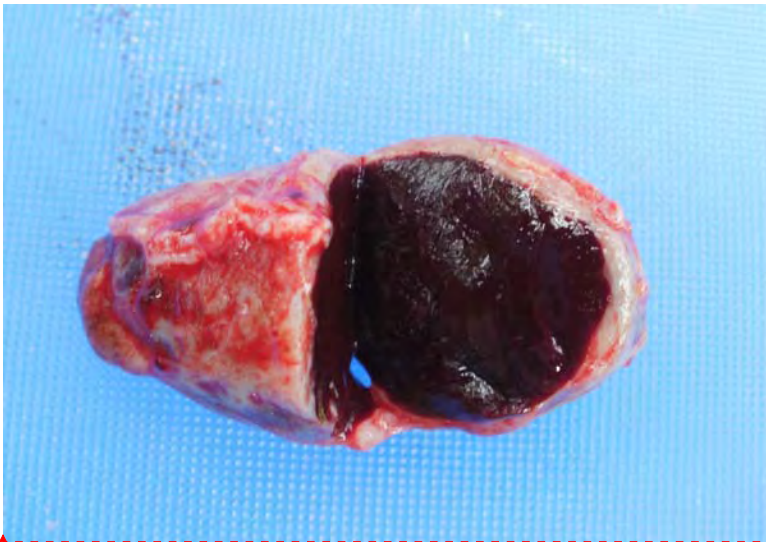
Formatted: Font: (Default) Times New Roman, 12 pt, English (U.S.), Do not check spelling or grammar

**Figure 9D:** Outgrowth of regenerating hepatic tissue (arrow), probably associated with parasitism, in a liver from a catfish sampled from Reënvoël Dam during November 2009. Note the normal brown colour of the liver



Formatted: Font: (Default) Times New Roman, 12 pt, English (U.S.), Do not check spelling or grammar

**Figure 10A:** Typically enlarged spleen of *C. gariepinus*, from the Olifants Gorge, suffering from fat necrosis and steatitis



**Formatted:** Font: (Default) Times New Roman, 12 pt, Bold, English (U.S.), Do not check spelling or grammar

**Figure 10B:** Spleen of a catfish from Lunsklip Fisheries suffering from severe chronic steatitis showing prominent capsular thickening and splenomegaly. Note the rounded nature of the normally flat spleen

Catfish sampled from Reënvoël Dam showed no steatitis and were used as a negative control population (Table 1). The gills of catfish sampled from Reënvoël Dam during November 2009 appeared normal and in good condition despite heavy parasite burdens.

Livers showed no fatty change but varying pathology was observed, associated with high levels of parasitosis. Extensive changes resulting from heavy parasitosis of the liver (Figure 9C), including outgrowths of regenerating liver tissue, were occasionally observed on the dorsal and ventral surface of some livers (Figure 9D). A further 13 fish were sampled from this site in January 2011 and again no steatitis could be demonstrated despite heavy parasite burdens. *Contracaecum* spp. larval nematodes were present in variable numbers within the peritoneal cavity of most catfish sampled from Reënvoël Dam and parasitic granulomata were frequently present in large numbers in the mesenteric adipose tissue. Brown melanisation of focal areas of the mesenteries overlying the mesenteric fat in the presence of *Contracaecum* spp. larvae and in the vicinity of larval digenean trematode cysts was occasionally noted (Figure 9). Compared to other sampling sites fish from Reënvoël Dam carried the heaviest burdens of digenean trematode cysts in the organs and musculature. Similar deposits of melanin were observed in association with heavy *Contracaecum* spp. larval burdens in catfish from Van Ryssen Dam (Figure 10). Such discolouration differed distinctly from the discolouration associated with steatitis and histologically no steatitis could be demonstrated in these fish.

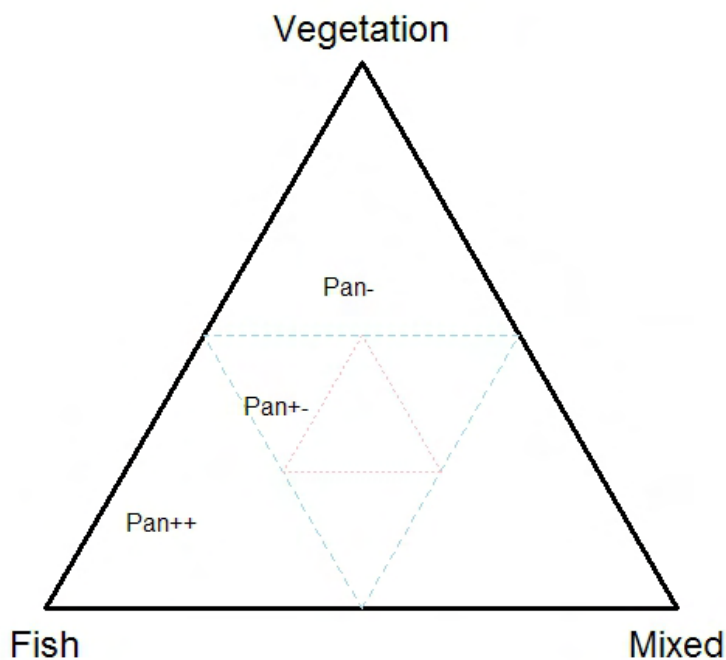
### 5.3 Stomach Contents

The sharp-toothed catfish is an omnivorous benthic scavenger and an active hunter. In the Olifants Gorge there are no trees on the steep riverbanks and catfish stomach contents

consisted predominantly of fish. On the Mozambique border where the Olifants River flows into Lake Massingir and where the sand bottomed pools and rapids have been inundated with clay deposits, stomach and intestinal content of sampled catfish consisted of algal detritus and clay. At those sampling sites where pancreatitis was prevalent in catfish, this was repeatedly linked to presence of fish remnants in the stomach contents. Although stomach content only revealed what had been ingested prior to sampling, a relative relationship between diet and presence of pancreatitis appeared to exist as illustrated in the triplot in Figure 11. Fish remnants in stomach content were often in an advanced stage of digestion and consisted of bones and scales from noticeably large fish as well as occasional pectoral spines of *Cynodontis* spp. fish. In a few cases these spines had migrated through the stomach wall and were found lying within the mesenteric cavity with only a mild associated inflammatory reaction. Intestinal content was often considerable and appeared whitish grey and pasty in fish where bones and scales were present in the stomach content. This was distinct from the black brown intestinal content associated with invertebrate and plant stomach content. Almost all catfish sampled in the Olifants Gorge during the peak flow of January 2011 had full stomachs, the ingesta consisting of fish as well as insects and small reptiles that had been washed into the river during the flood conditions. Despite the murky turbulent water catfish appeared to feed with ease under these conditions. During the winter samplings when the water in the Olifants River is relatively clear far fewer sampled catfish had significant amounts of ingesta in the stomach.

Stomach content of catfish sampled from the Sabiepoort consisted predominantly of fish remnants although stomachs of several of these fish contained recently ingested crocodile fat with visible signs of steatitis still present. The stomachs of catfish sampled from Mamba Weir contained predominantly the fruit of Sycamore fig trees (*Ficus sycomorus*) that overhang the embankment of this stretch of the river. Although more than half of sampled catfish from Reënvoël Dam had empty stomachs, invertebrate and mixed detritus, vegetation and fish were represented in the ingesta of the remaining fish. Recognizable remnants of Mozambique tilapia were found in the stomach content of most catfish sampled from Van Ryssen Dam. The majority of catfish sampled from the Crocodile River during June 2011 had stomachs distended with filamentous algae. Microscopic examination of fluid expressed from the stomach contents revealed that large numbers of diatoms had been ingested together with the filamentous algae. Stomach content of catfish sampled from the Levuvhu River, during June 2011, consisted of algae and sycamore figs.



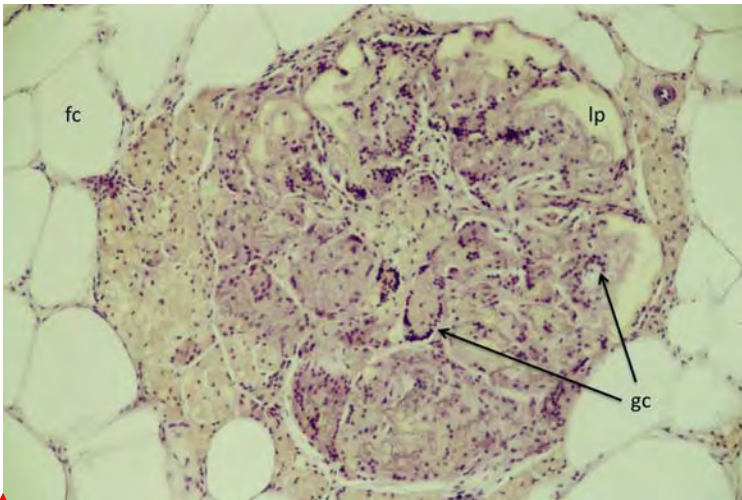


**Figure 11:** Stomach content analysis of sharp-toothed catfish showing that the population with pansteatitis (Pan++) at a site where pansteatitis was prevalent had stomach contents with a higher proportion of fish than vegetation, or invertebrates and detritus (mixed) when compared with the population of fish that did not have pansteatitis (Pan+-) from areas that had pansteatitis prevalence, and the population from areas without pansteatitis prevalence (Pan-). (Triplot preparation courtesy of S. Woodborne, Centre for Scientific and Industrial Research, Pretoria)

## 5.4 Histopathology

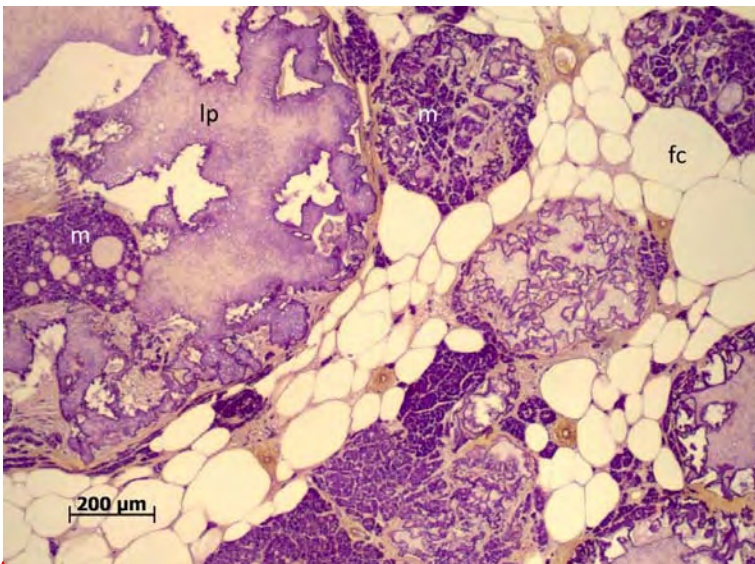
### 5.4.1 Histopathology of the adipose tissues

Various granulomatous reactions were observed in the fat tissues of catfish specimens. Parasitic granulomata were distinguishable from foci of inflammation and granuloma formation associated with non-parasitic causes. The histological appearance of non-parasitic granulomata in the adipose tissues was typical of lesions expected with steatitis (Figures 12A and 12B). These lesions were similar in appearance in all fish sampled with macroscopic steatitis, including the fish suffering from nutritional steatitis at Lunsklip Fisheries.



**Formatted:** Font: (Default) Times New Roman, 12 pt, Bold, English (U.S.), Do not check spelling or grammar

**Figure 12A:** Giant cell formation (arrows) in a typical steatitis lesion in adipose tissue from a catfish sampled from the Olifants Gorge in July 2009. HE X100

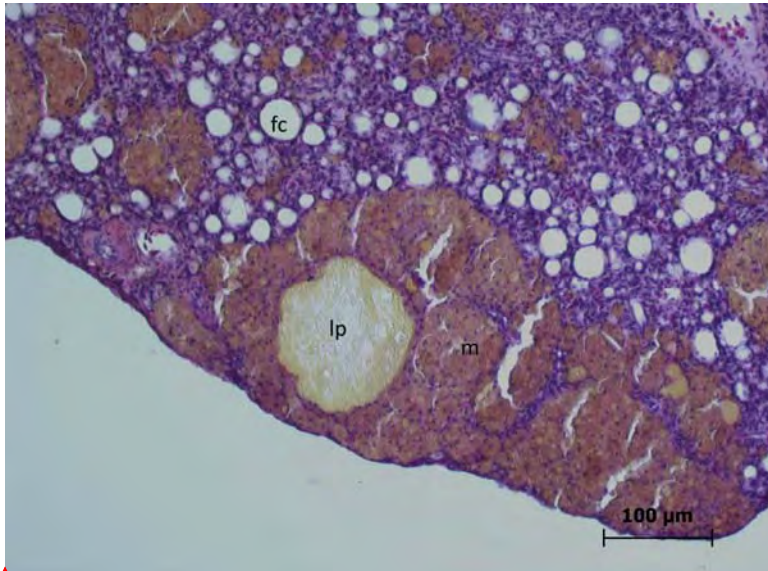


**Formatted:** Font: (Default) Times New Roman, 12 pt, English (U.S.), Do not check spelling or grammar

**Figure 12B:** Positive staining ceroid pigment (purple) within the lipopigment remnants (lp) of ruptured adipocytes and macrophages (m) in mesenteric fat of a catfish sampled from the Olifants Gorge during November 2009. Adipocytes (fc). (GAF)

Lesions in the adipose tissues were focal and often roughly circular in shape in mild cases and disseminated and coalescing throughout the adipose tissue in severe cases. Surrounding adipocytes often appeared normal although they were reduced in number and displaced by the associated inflammatory reaction in severe cases.

Steatitis was observed in both atrophied adipose tissue (Figure 13) and in adipose tissue where adipocytes were replete with fat. The focal distribution of granulomata in mildly affected fish resulted in lesions sometimes being missed during the sectioning process. Such cases, although positive for steatitis on macroscopic evaluation could not be identified on histological evaluation alone.



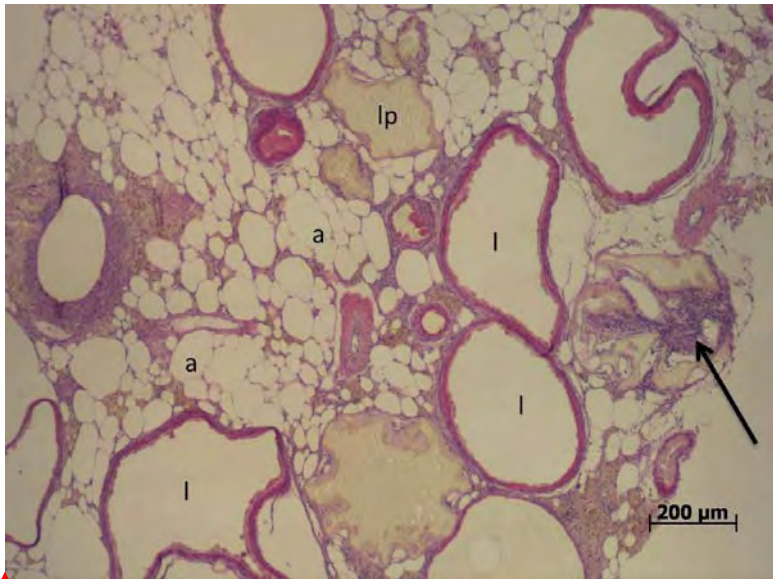
**Formatted:** Font: (Default) Times  
 New Roman, 12 pt, Bold, English  
 (U.S.), Do not check spelling or  
 grammar, Kern at 18 pt

**Figure 13:** Atrophied mesenteric adipose tissue showing inflammation typical of steatitis in a catfish sampled from the Olifants Gorge during June 2011. Note small size of adipocytes (fc) and aggregates of macrophages (m) containing ceroid, surrounding areas of fat necrosis containing lipopigment (lp). (HE)

In haematoxylin eosin stained sections of affected fat, varying sized foci consisting of ruptured adipocytes contained a characteristic pigment typical of extracellular ceroid-type (ECC) lipopigment (Elleder, 1991), also called preceroid (Jolly and Dalefield, 1990). This pigment, typical of oxidative damage to fat cells, appeared as yellow, granular and refractive inclusions of varying size. ECC lipopigment was also observed to be phagocytised by the macrophages surrounding steatitis lesions. Necrotic adipocytes and associated cell breakdown debris were surrounded by a dense mass of macrophages containing intracellular ceroid (Fig. 12B), pigment also derived from degeneration and peroxidation of unsaturated lipid (Jolly and Dalefield, 1990; Elleder, M, 1991). Such lesions were associated with presence of variable numbers of fibroblasts and connective tissue deposition. These lesions were focally disseminated throughout the affected mesenteric adipose tissue and represented the brown granulomata noted macroscopically. Lipopigment and ceroid-containing macrophage aggregations within the interstitium of the fat tissues in the absence of adipocyte necrosis were noted in a few fish, and were indicative of mild or early oxidative damage to the fat.

In the absence of frank necrosis in the adipose tissues, the presence of phagocytosed lipopigment within macrophages containing ceroid was used to interpret such lesions as steatitis. Presence of ceroid in the macrophages was confirmed by staining with GAF (Fig. 12B) and PAS stains. Multinucleate Langhans giant cells were invariably associated with the inflammatory response surrounding necrotic areas of fat (Fig. 12A).

In some lesions, more compact macrophages were arranged in the form of an epithelioid type sheath surrounding the ruptured fat cells. Advanced cases presented with a clear or lipopigment containing central lacuna surrounded by organised layers of epithelioid cells that in places coalesced and became embedded in fibrous connective tissue (Figure 14). Clear lacunae were an artefact of sectioning where the central pigmented area of fat breakdown products had been lost during sectioning.



**Formatted:** Font: (Default) Times New Roman, 12 pt, Bold, English (U.S.), Do not check spelling or grammar, Kern at 18 pt

**Figure 14:** Advanced stage of fat necrosis and steatitis in mesenteric fat of a catfish sampled from the Olifants Gorge during June 2011. Note the apparently empty lacunae (l) where necrotic remnants of oxidised fat (lp) have been lost during processing, surrounded by an epithelioid sheath. Adipocytes (a), foreign body giant cells (arrow). (HE)

Parasitic granulomata of varying sizes were common in the mesenteric, hypodermal and intramuscular fat but were not observed in the pectoral fat. These granulomata were distinct from granulomata caused by steatitis. Parasitic granulomata showed a greater infiltration of fibroblasts and greater collagen deposition in the capsule than observed with granulomata associated with steatitis. Macrophage clusters on the periphery of parasitic granulomata were less intense and usually in the form of melanomacrophage centres. On haematoxylin eosin stained sections these appeared mildly basophilic in colour with variable amounts of brown melanin pigment. Ceroid- and lipopigment-containing macrophages were not generally

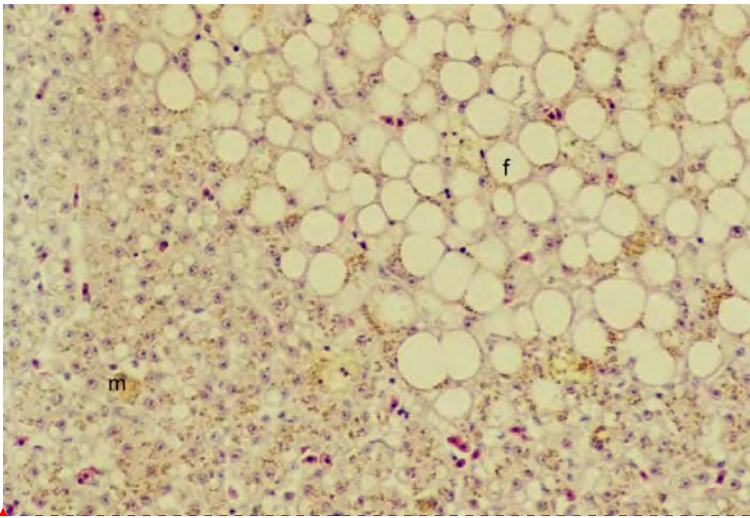


associated with parasitic granulomas, and were infrequently observed in the vicinity of parasites in the mesenteric adipose tissues.

#### **5.4.2 Histopathology of other organs**

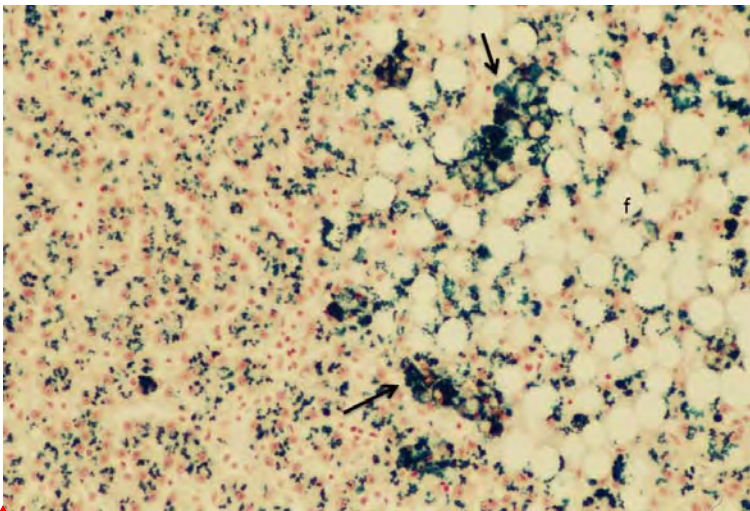
Varying degrees of hepatic lipidosis, often within distinct foci, were observed in the livers of fish suffering from steatitis. Special stains established presence of ceroid, in the hepatocytes of these fish as well as large amounts of haemosiderin (Figures 15A and 15B). Presence of haemosiderin was confirmed by use of Perl's Prussian blue stain. However, similar changes were observed in livers from some Reënvoël Dam fish in the absence of associated steatitis. Well-encapsulated parasitic granulomata of varying sizes were a common histological finding in many liversections of fish from both the Olifants Gorge and Reënvoël Dam but were not observed in livers of catfish from Lunsklip Fisheries. A large focus of hepatocellular disorganization was observed in the liver of one fish from Lunsklip Fisheries suffering from severe steatitis. The affected area showed eosinophilia of hepatocytes and tracts of fibroblasts and associated inflammatory round cells infiltrating the liver parenchyma. The periphery of the focus was demarcated by a zone of melanomacrophage aggregations. The central area of the lesion appeared partitioned by fibrous tracts with islands of hepatocytes undergoing degeneration and necrosis. A clearly demarcated zone of disorganization with enlarged hepatocytes, devoid of pigment, arranged in loose whorls with mild fibroplasia surrounding dilated vascular spaces was observed occasionally in fish from Reënvoël Dam and from the Olifants Gorge. Melanomacrophages in all organs of older fish were replete with melanin. Variable numbers of inflammatory cells associated with ducts and blood vessels were observed in the livers of older fish particularly. Pancreatic acinar and islet cells appeared normal in all of the fish, although the variable prominence of pancreatic tissues noted macroscopically was reflected in atrophy of the organ, which was most prominent in fish affected by steatitis (Figure 16). No specific pathology was observed in the intestines of sampled fish.





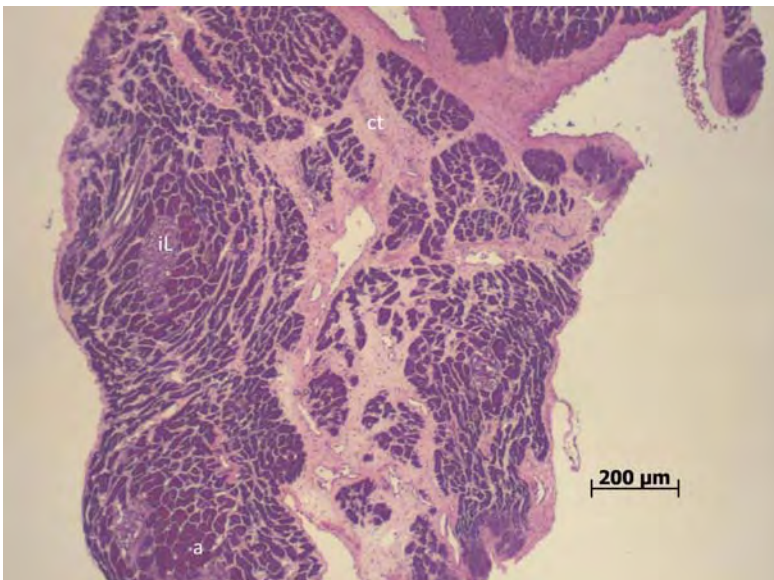
**Formatted:** Font: (Default) Times New Roman, 12 pt, Bold, English (U.S.), Do not check spelling or grammar

**Figure 15A:** Liver section of a catfish sampled from the Olifants Gorge during November 2009. Note distinct focus of fat vacuoles (f). (HE X200)



**Formatted:** Font: (Default) Times New Roman, 12 pt, English (U.S.), Do not check spelling or grammar

**Figure 15B:** Liver section of a catfish sampled from the Olifants Gorge during November 2009. Note distinct focus of fat vacuoles (f) and clustering of haemosiderin (arrows) on the perimeter of this focus. (Perl's Prussian blue, X200)



**Figure 16:** Pancreatic atrophy in a catfish suffering from steatitis, sampled from the Olifants Gorge during June 2011. Note prominence of connective tissue (ct) extending between groups of acinar cells (a). Islet of Langerhans (iL). (HE)

In fish from all sites, variable numbers of focally disseminated clusters of dense basophilic lymphocytes were noted in the cranial and caudal kidney representing variation in the normal lymphocytic tissue within this organ.

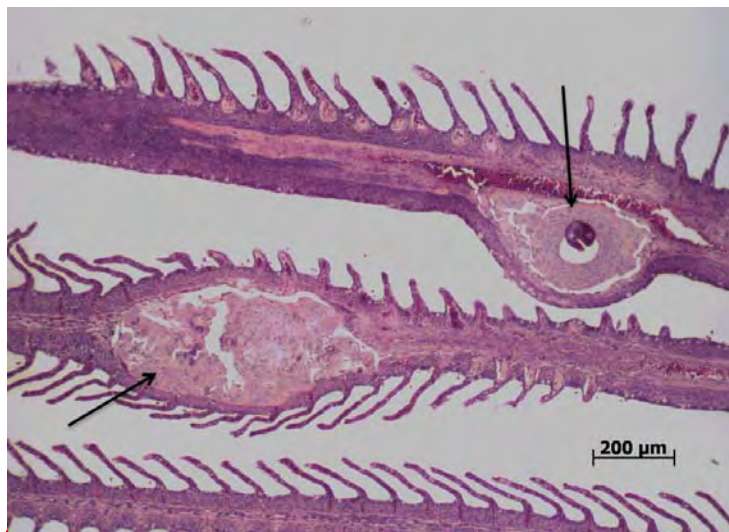
Apparent necrotic changes observed in the haemopoietic tissues of some catfish specimens collected from the Olifants Gorge during 2008 were not evident in the specimens collected subsequently, but were again noted in fish collected at the time of the fish kill in July 2009. Sampling of these respective fish was done in the absence of the author and autolytic changes had complicated the histological picture. Necrosis of haematopoietic tissues was not observed in fish sampled from any sites between November 2009 and June 2011.

The spleens of fish from various sites were variable in appearance depending on the numbers of erythrocytes held in the splenic sinusoids. Encapsulated necrotic foci, from degenerating parasites within the spleen, were observed in two fish from the Olifants Gorge. Multiple cyst-like mineralized foci were observed in the spleen of one fish that was not suffering from steatitis. Small coccidian type intracellular parasites were observed in macrophages within melanomacrophage centres of both the spleen and kidney of fish from the Olifants River and from Reënvoël Dam. These parasites were not observed in fish from Lunsklip Fisheries. There appeared to be no pathology associated with presence of this parasite.

Multiple focal cyst-like structures that appeared to be of thyroid origin were observed in the hearts of two fish with steatitis from Lunsklip Fisheries. The structures appeared to be

lined by an epithelium and were filled with homogenous eosinophilic material. Myocardial lesions were not observed in fish from other sampling sites. No signs of fat necrosis could be detected in epicardial fat cells where these were present on the hearts of sampled fish.

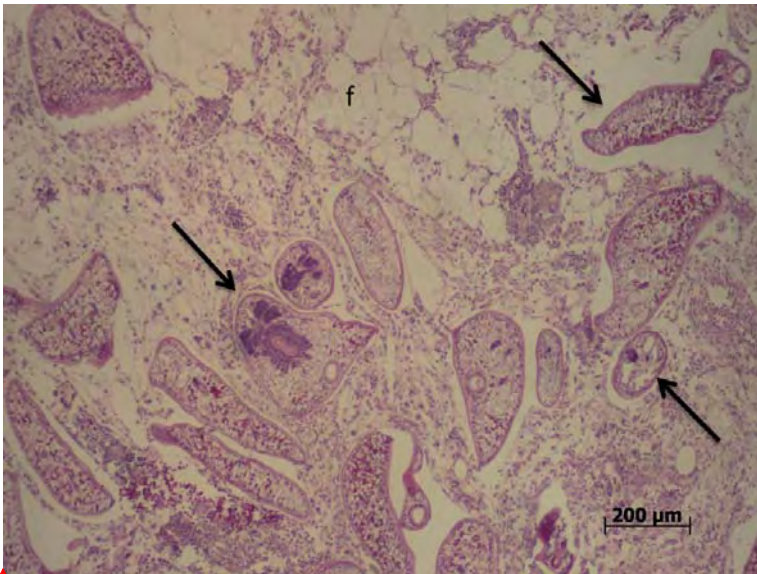
Gills in the catfish specimens collected in the Olifants Gorge during January 2009 presented with a two to three-fold increase in the thickness of the epithelium of the secondary lamellae. In many of these specimens the epithelial hyperplasia increased towards the base of the secondary lamellae imparting a wedge shaped appearance. Such changes were less evident in fish sampled from the Olifants Gorge in November 2009, and during later samplings gills showed minimal signs of hyperplasia. Monogenean trematodes were occasionally visible between the secondary lamellae of the gills. Some fish showed deformity of the cartilage of the primary gill lamellae as a result of infection with a digenean trematode, possibly *Centrocestus formosanus* (Figure 17). These parasites could be observed lying within cysts in the gill cartilage where they appeared to feed off chondrocytes causing considerable damage to the gill cartilage. Infection with this parasite and resultant gill cartilage deformity was also a common finding in fish sampled from Reënvoël Dam. Only mild hyperplasia of the gill epithelium was evident in some fish from Lunsklip Fisheries; however the absence of digenean gill parasites from these fish was notable.



**Formatted:** Font: (Default) Times  
 New Roman, 12 pt, Bold, English  
 (U.S.), Do not check spelling or  
 grammar, Kern at 18 pt

**Figure 17:** Digenean trematode larva encysted within the cartilage of the primary lamellae of a catfish sampled from the Olifants Gorge during June 2011. Note hyperplastic changes in the cartilage (arrows). (HE)





**Formatted:** Font: (Default) Times New Roman, 12 pt, Bold, English (U.S.), Do not check spelling or grammar

**Figure 18:** Digenean trematodes of the family Diplostomidae (arrows) within the cerebrospinal space adjacent to fat lining the cranium of a catfish sampled from Engelhard Dam during July 2010. Note the cellular reaction associated with presence of these parasites. (HE)

No lesions were observed in the brains of fish from any of the sampling sites. At some sampling sites large numbers of digenean trematodes (Fam. Diplostomidae) were observed surrounding the brain and within the brain fat (Figure 18). Histologically an inflammatory reaction with presence of macrophages could be observed in association with these parasites, but the parasites were never observed penetrating the brain tissues. There was no correlation between parasite presence and steatitis in the brain fat.

Maturity of gonads observed in sampled fish depended on age and sampling season. Older female fish showed large numbers of melanomacrophages within the ovaries. In testicular tissue, melanomacrophages were seldom noted. Gonadal development in all cases appeared to be normal and no pathology was noted within the gonads. Development of intersex was not observed in sampled fish.

Muscle atrophy was observed in some fish suffering from steatitis. Other than presence of parasitic cysts, no other pathology was observed in muscle tissue. The fibrous and round cell inflammatory reaction associated with parasites depended on type and stage of parasite but was not correlated with presence of steatitis in the intramuscular fat. No specific pathology was observed in the skin of sampled fish.

## 5.5 Pathology in Other Species

Mozambique tilapias were difficult to catch in the Olifants Gorge. However a few specimens caught from the Letaba River at the confluence with the Olifants River at the entrance to the gorge appeared thin, despite presence of moderate mesenteric fat reserves. Distinctly demarcated pale areas of discolouration were noted in the livers of some of these fish. These were confirmed by histology to be zones of fat accumulation within hepatocytes. Such zones are not uncommon in farmed tilapias. Gills of Mozambique tilapiaspecimens appeared normal. Mesenteric fat showed no evidence of steatitis. However on histology one fish showed small amounts of lipopigment within macrophages associated with mesenteric adipose tissue. Distinct from catfish, Mozambique tilapiaspecimens showed no ceroid or haemosiderin deposition in the livers. All other organs appeared histologically normal. Only one large specimen of the purple labeo (*Labeo congoro*Peters)was collected in the gorge. The gills of this fish manifested with an unusual severe fusion of the distal ends of the primary lamellae, a change that was not observed in either catfish or Mozambique tilapia. A few purple labeo specimens caught at other sampling sites did not show this same gill fusion.

Steatitis could not be demonstrated in 5 tiger fish collected from the Olifants Gorge during September 2008 or in 21 tiger fish collected from the Olifants Gorge during June 2011. The fish were all in good condition with distinctly white mesenteric fat reserves. Fish sampled during June 2011 ranged in age from 1 to 10 years and both male and female fish were represented. All fish carried low numbers of larval nematodes in the peritoneal cavity however digenean trematode cysts were absent in all but one fish.

## 5.6 Blood Chemistry and Haematology

### 5.6.1 Blood smear examinations

Examination of blood smears taken from catfish collected from the Olifants Gorge soon after the mass crocodile mortality in the winter of 2008indicated an increase in numbers of immature erythrocytes in many of the fish as well as erythrocytes with irregular cell shapes and crenated cell membranes. Nuclear shapes were similarly irregular with a high prevalence of chromatin clumping visible within the nuclei in some blood smears. As the changes were not restricted to immature erythrocytes, these may have been an artefact of smear preparation. An increase in polychromatocytes was,however, still evident in blood smears taken during the November 2009 sampling (Table 3). Sharptooth catfishnormally have round nucleated erythrocytes which are distinct from the oval erythrocytes of many other fish species. Compared to mature erythrocytes, polychromatocytes were characterised by a more basophilic cytoplasm and a larger, granular appearing nucleus. Crenation of erythrocyte cell membranes was still present in some blood smears of fish sampled from the Olifants Gorge during November 2009. The finding was more frequent in blood smears taken from catfish at Lunsklip Fisheries at the same time but was rare in blood smears of fish sampled from Reënvoël Dam.



**Table 3:** Comparison of percentage polychromatocytes in blood smears collected from catfish at three sampling sites during November 2009

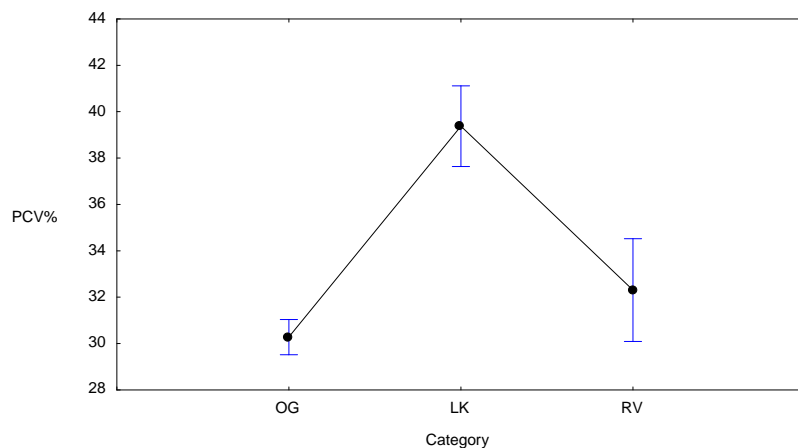
Sampling site	% polychromatocytes		
	mean $\pm$ SD*	range	n
Lunsklip Fisheries	0.75 $\pm$ 0.60	0-2.33	21
Olifants Gorge	3.26 $\pm$ 2.73	0.67-12.33	19
Reënvoël Dam	1.95 $\pm$ 1.65	0.33-5.33	20

### 5.6.2 Haematocrit

Average haematocrit values are presented in Table 4. There were no significant differences in haematocrit values between fish with and without steatitis at various sampling sites where steatitis was found to occur. In the Olifants Gorge, mean PCV values of fish ranged between 25 and 41% in apparently healthy fish and between 24 and 37% in fish with steatitis. The mean PCV value for fish sampled from Reënvoël Dam was 32.3% (n=13, standard deviation=6.1). Comparison of mean PCV values from fish sampled from the Olifants Gorge (32.6%) with Lunsklip Fisheries (39.4%) during November 2009 indicated significantly lower haematocrit values in the Olifants Gorge fish ( $p < 0.05$ ). Haematocrit values were only available from fish sampled from Reënvoël Dam during January 2011; during the November 2009 sampling of catfish from Reënvoël Dam a field micro-centrifuge was not available. Analysis of variance ( $p = 0.00002$ ) followed by post-hoc Tukey's HSD test showed significant differences between mean PCV values (39.4%) for fish from Lunsklip Fisheries (positive reference population, n=21) when compared to mean PCV values (30.3%) for all fish sampled from the Olifants Gorge (n=111), and to mean PCV values (32.3%) for fish from Reënvoël Dam (negative reference population, n=13) (Figure 19).

### 5.6.3 Haemoglobin

Average haemoglobin values for fish sampled from all sites are shown in Table 5 and were noticeably variable. Haemoglobin values (g/dl) did not differ significantly between fish with and without steatitis sampled from the Olifants Gorge, with mean values of 10.1 and 9.7 for fish with and without steatitis, respectively. Analysis of variance showed significant difference ( $p < 0.05$ ) in mean haemoglobin values of fish sampled during November 2009 from the Olifants Gorge, Lunsklip Fisheries and Reënvoël Dam (post-hoc Tukey's test) (Figure 20). The average haemoglobin value of fish sampled from Reënvoël Dam during January 2011 was however, much lower than that of fish sampled from the same site during November 2009, with average values being similar to those of catfish sampled from the Levuvhu and Crocodile rivers. The significance of the differences observed in the November results thus remains uncertain.



**Figure 19:** Comparison of mean haematocrit (PCV%) from all catfish sampled from the Olifants Gorge sites (n=111) as compared to mean haematocrit (PCV%) of catfish sampled from Lunsklip Fisheries (n=21) and Reënvoël Dam (n=13). ( $p=0.00002$ , vertical bars denote +/- standard errors)

**Table 4:** Mean haematocrit values (packed cell volume=PCV) of blood collected from *C. gariepinus* from all sites (Olifants Gorge=GL, OGM, OG, OL, LOG, LOC; Lunsklip Fisheries=LK; Reënvoël Dam=RVB; Engelhard Dam=EH; Van Ryssen Dam=FK; Mamba Weir=M; Levuvhu River=LUV; Crocodile River=CR)

Sample site	Date	Packed cell volume (%)		
		mean $\pm$ SD*	range	number
GL	Jun-09	26.33 $\pm$ 4.97	15-31	9
OGM	Aug-09	39.07 $\pm$ 6.75	30-50	14
LK	Nov-09	39.38 $\pm$ 7.6	22-50	21
OG	Nov-09	32.55 $\pm$ 9.71	10-50	20
EH	Jul-10	29.95 $\pm$ 5.96	19-40	19
OL	Jul-10	28.56 $\pm$ 6.92	15-38	25
M	Jul-10	27.75 $\pm$ 8.34	12-45	20
LOG	Jan-11	30.59 $\pm$ 6.04	14-39	22
RVB	Jan-11	32.31 $\pm$ 6.06	20-44	13
FK	Jan-11	32.2 $\pm$ 4.69	22-38	10
LUV	Jun-11	30.79 $\pm$ 5.82	21-40	14
LOC	Jun-11	25.67 $\pm$ 7.43	11-40	21

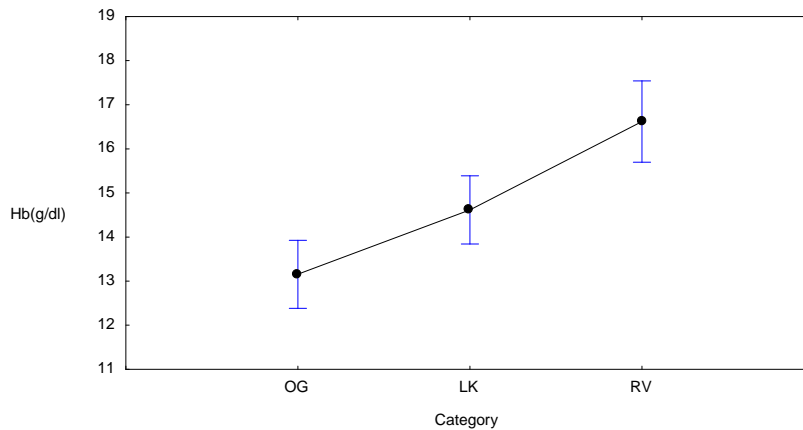
#### 5.6.4 Serum vitamin E

Average serum vitamin E values for catfish sampled from all sites are presented in Table 6. Vitamin E values did not differ significantly between fish with and without steatitis. Although some fish from the Olifants Gorge had very low serum vitamin E values, analysis of variance showed that there was no significant difference in mean serum vitamin E values between fish sampled from the Olifants Gorge and Reënvoël Dam during November 2009 whereas the values in fish sampled from Lunsklip Fisheries were significantly higher at this time (Figure 21).

**Table 5:** Mean haemoglobin values (g/dl) of blood collected from *C. gariepinus* from all sites (Olifants Gorge=GL, OGM, OG, OL, LOG, LOC; Lunsklip Fisheries=LK; Reënvoël Dam=RV, RVB; Engelhard Dam=EH; Van Ryssen Dam=FK; Mamba Weir=M; Levuvhu River=LUV; Crocodile River=CR)

Sample site	Date	Haemoglobin		
		mean $\pm$ SD*	range	number
GL	Jun-09	12.32 $\pm$ 1.07	10.7-13.8	9
OGM	Aug-09	11 $\pm$ 1.11	8.93-13	14
LK	Nov-09	14.47 $\pm$ 3.06	9.53-23	21
OG	Nov-09	13.16 $\pm$ 3.84	6.65-21	20
RV	Nov-09	16.62 $\pm$ 3.39	10.8-21.3	14
EH	Jul-10	9.39 $\pm$ 3.57	3.82-16.9	20
OL	Jul-10	9.66 $\pm$ 4.29	3.24-21.3	25
M	Jul-10	8.04 $\pm$ 4.52	2.33-17.1	20
LOG	Jan-11	7.69 $\pm$ 3.05	0.1-13.7	22
RVB	Jan-11	8.05 $\pm$ 2.45	3.5-13.1	13
FK	Jan-11	13.83 $\pm$ 6.39	8.15-29.93	10
LUV	Jun-11	9.25 $\pm$ 1.68	6.4-12.2	14
LOC	Jun-11	7.9 $\pm$ 2.12	4.2-12	16
CR	Jun-11	7.89 $\pm$ 1.34	4.2-10.2	20

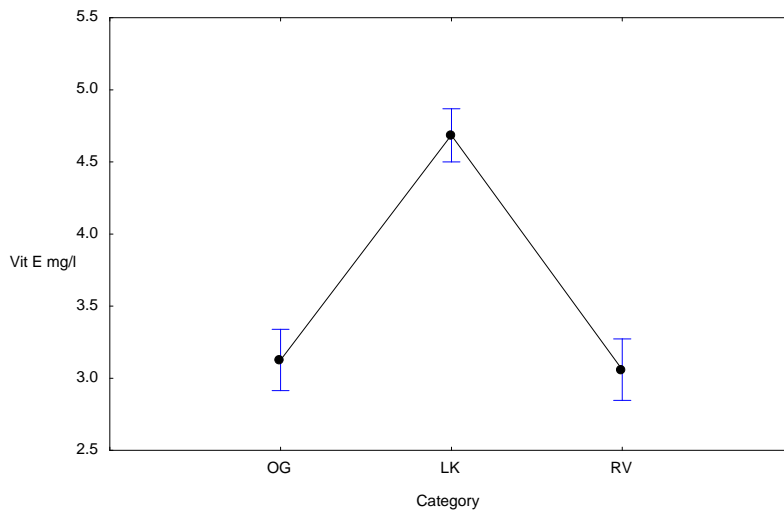
**Formatted:** Font: (Default) Times New Roman, 12 pt, Bold, Do not check spelling or grammar



**Figure 20:** Comparison of mean haemoglobin values (g/dl) of catfish sampled during November 2009. OG=Olifants Gorge (n 20), LK=Lunsklip Fisheries (n 21) and RV=Reënvoël Dam (n 14). (p=0.02136, vertical bars denote +/- standard errors)

**Table 6:** Average serum vitamin E values of catfish from all sites (Olifants Gorge=OGM, OG, OL; Lunsklip Fisheries=LK; Reënvoël Dam=RV; Engelhard Dam=EH; Mamba Weir=M)

Sample site	Date	Vitamin E (mg/l)		
		mean ± SD*	range	number
OGM	Aug-09	4.67 ± 2.99	1.0-8.9	14
LK	Nov-09	4.6 ± 1.26	2.7-6.7	21
OG	Nov-09	3.13 ± 0.34	2.7-3.9	15
RV	Nov-09	3.06 ± 0.33	2.4-3.7	15
EH	Jul-10	3.33 ± 1.49	1.4-7.8	18
OL	Jul-10	2.75 ± 1.18	1.1-5.4	17
M	Jul-10	2.88 ± 1.4	0.8-5.7	16



**Figure 21:** Comparison of mean serum vitamin E values (mg/l) of catfish sampled during November 2009. OG=Olifants Gorge (n 15), LK=Lunsklip Fisheries (n 20) and RV=Reënvoël Dam (n 15). (p=0.00000, vertical bars denote +/- standard errors)

The lower fifth percentile of serum vitamin E values (2.7 mg/l) in healthy fish from Reënvoël Dam was used to identify fish with depressed vitamin E values and subjected to chi-squared analysis ( $p < 0.05$ ). Whereas the percentage of fish with depressed serum vitamin E values during the November 2009 sampling from the Olifants Gorge was similar to that of fish sampled from Reënvoël Dam and Lunsklip Fisheries in the same period, significantly higher percentages of fish with depressed serum vitamin E values were sampled from the Olifants Gorge and Mamba Weir during July 2010. Although at p values slightly above 0.05, numbers of fish with low serum vitamin E values sampled from the Olifants Gorge during August 2009 and from Engelhard Dam during July 2010 were indicative of a similar pattern of depression during these sampling episodes (Table 7).

**Table 7:** Percentage of catfish from the Olifants Gorge and other sites with serum vitamin E levels below the lower fifth percentile of values of healthy fish sampled from Reënvoël Dam. (Olifants Gorge=OGM, OG, OL; Lunsklip Fisheries=LK; Reënvoël Dam=RV; Engelhard Dam=EH; Mamba Weir=M)

Sampling site	Sampling date	% fish with vitamin <2.7 mg/l	n
OGM	Aug-09	36	14
OG	Nov-09	7	15
RV	Nov-09	7	15
LK	Nov-09	10	21
OL	Jul-10	65	17
EH	Jul-10	33	18
M	Jul-10	50	16



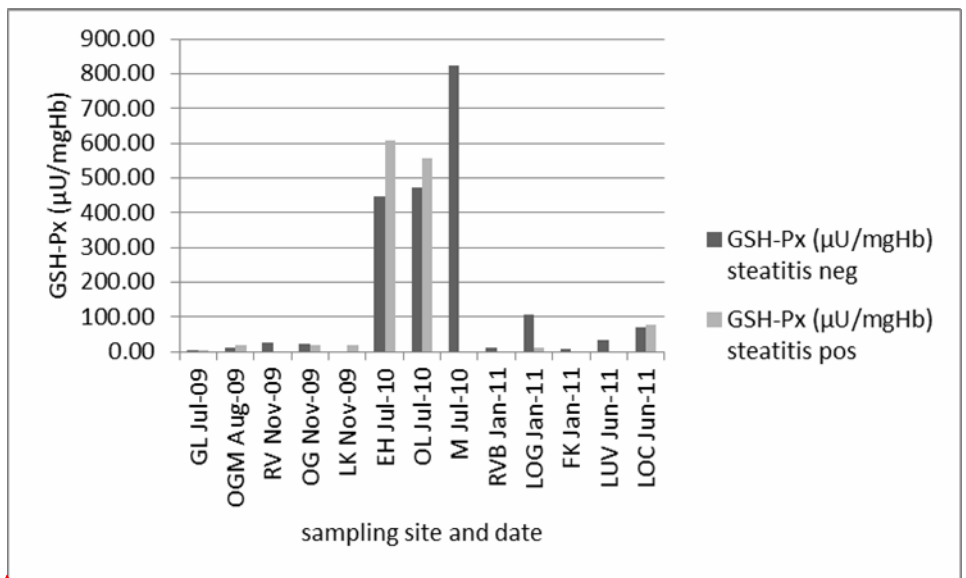
### 5.6.5 Blood glutathione peroxidase

Exceptionally high erythrocyte glutathione peroxidase values were measured in catfish from three sampling sites during July 2010 (Table 8). Fish with steatitis were found at all three of these sites (Figure 22A). A comparison of erythrocyte glutathione peroxidase values measured in blood of catfish from the same sites in the Olifants Gorge on different sampling dates lets these high values appear suspicious. No significant difference in erythrocyte glutathione peroxidase values could be demonstrated in fish sampled during November 2009 from the Olifants Gorge, Lunsklip Fisheries and Reënvoël Dam and there was no significant difference in erythrocyte glutathione peroxidase values in fish with and without steatitis.

After combining data from all sampling sites, including the suspicious data from July 2010, analysis of variance showed that sampling site and date did have a significant effect on blood glutathione peroxidase values ( $F=4.57$ ,  $p=0.0012$ ). According to Tukey's post-hoc test, there was a significant difference in average values between fish sampled from the Olifants Gorge (159.5) and fish sampled from Reënvoël Dam (18.8). Levene's test for homogeneity of variances showed that there was significant inequality in variances between treatments and this could not be eliminated after data had been log-transformed. It was therefore decided to use the non-parametric Kruskal-Wallis test as an additional approach to the data analysis. This confirmed the significant effect of sampling site on blood glutathione peroxidase values at  $p=0.0135$  (Figure 22B). The comparison would, however, appear unjustified.

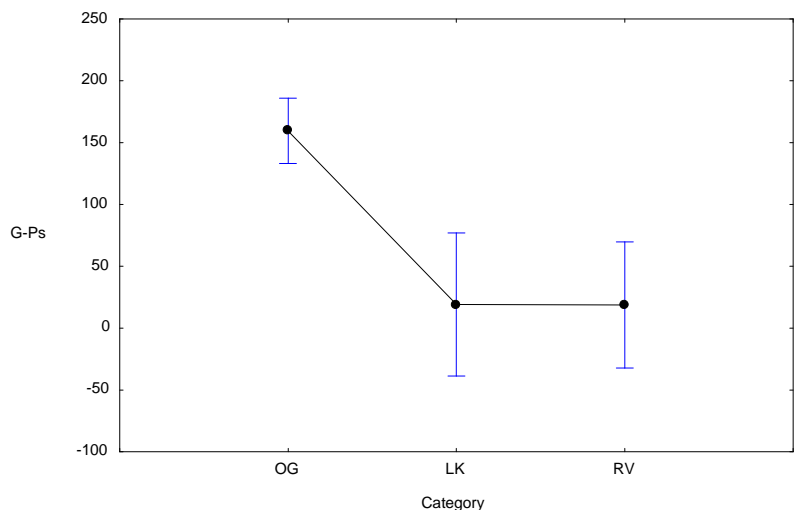
**Table 8:** Average erythrocyte glutathione peroxidase (GSH-Px) values of catfish from all sites (Olifants Gorge=GL, OGM, OG, OL, LOG, LOC; Lunsklip Fisheries=LK; Reënvoël Dam=RV, RVB; Engelhard Dam=EH; Van Ryssen Dam=FK; Mamba Weir=M; Levuvhu River=LUV; Crocodile River=CR)

Sample site	Date	Glutathione peroxidase ( $\mu\text{U}/\text{mgHb}$ )		
		mean $\pm$ SD*	range	number
GL	Jun-09	2.41 $\pm$ 0.22	2.16-2.79	9
OGM	Aug-09	14.13 $\pm$ 7.87	6.57-33.72	14
LK	Nov-09	19.13 $\pm$ 6.21	11.77-35.93	21
OG	Nov-09	20.3 $\pm$ 8.55	10.32-48.08	20
RV	Nov-09	25.41 $\pm$ 10.02	4.66-45.34	14
EH	Jul-10	470.24 $\pm$ 366.55	76.56-1203.29	20
OL	Jul-10	526.57 $\pm$ 464.42	60.87-1664.36	25
M	Jul-10	807.65 $\pm$ 712.28	0-2664.48	20
LOG	Jan-11	38.93 $\pm$ 119.79	6.29-574.6	22
RVB	Jan-11	11.59 $\pm$ 6.14	5.11-30.1	13
FK	Jan-11	7.81 $\pm$ 2.14	2.4-9.5	10
LUV	Jun-11	34.64 $\pm$ 8.55	24.22-50.7	14
LOC	Jun-11	74.43 $\pm$ 118.94	13.68-536.28	20
CR	Jun-11	34.35 $\pm$ 12.57	5.8-58.1	20



Formatted: Font: (Default) Times New Roman, 12 pt, English (U.S.), Do not check spelling or grammar

**Figure 22A:** Average glutathione peroxidase (GSH-Px) values (µU/mgHb) of catfish with and without steatitis sampled from all sampling sites



Formatted: Font: (Default) Times New Roman, 12 pt, Do not check spelling or grammar

**Figure 22B:** Comparison of average erythrocyte glutathione peroxidase (G-Ps) values (µU/mgHb) of all catfish sampled from the Olifants Gorge sites (n=101), Lunsklip Fisheries (n=21) and Reënvoël Dam (n=27). (p=0.01185, vertical bars denote +/- standard errors)

## DISCUSSION

### 6.1 Prevalence of Steatitis

Steatitis was identified in catfish sampled from the Olifants River at the confluence with the Letaba River where the Olifants River enters the 9 km long gorge that opens into Lake Massingir in Mozambique. This same area has been the epicentre of the recent crocodile mortalities. During repeat samplings, an increasing prevalence of steatitis affecting up to 67% of catfish in this section of river was identified. A lower prevalence of steatitis was found in catfish sampled from Engelhard Dam on the Letaba River a few kilometres upstream of the confluence with the Olifants River and in catfish sampled from Mamba Weir where the Olifants River enters the western boundary of the KNP. In the Sabiepoort of the KNP, where the Sabie River flows through a gorge before entering Lake Corumana in Mozambique, a similar situation was identified with steatitis prevalence similar to that in fish from the Olifants Gorge. Crocodile deaths from pansteatitis have also been observed in the Sabiepoort (D Govender, SANParks, Skukuza, pers. comm. 2010). It is well documented that the Olifants River, draining the eastern side of the Mpumalanga Highveld, has been extensively affected by anthropogenic activity (Ashton, 2010; de Villiers and Mkwelo, 2009; Heath et al., 2010), and this was reflected in a preliminary assessment of metals found in the livers of catfish sampled from the Olifants Gorge (Dixon et al., 2011). There is, however, little commonality between pollution impacts in the respective catchments of the Sabie, Letaba and Olifants rivers. Steatitis could not be detected in fish from the Levuvhu and Crocodile rivers, both of which drain catchment areas subject to divergent anthropogenic impact and neither of which are dammed in or near the KNP. Neither could steatitis be demonstrated in fish from Reënvoël Dam, which is an entirely rain fed water body within KNP and distant from potential pollution sources affecting the Olifants River. It is possible that steatitis in catfish in Engelhard Dam was associated with upstream movement of fish from the Olifants Letaba confluence.

The sediment rich burden of the Olifants River is deposited annually in the Olifants Gorge where the flow of the river has been slowed by damming from Lake Massingir, a situation that arose after the sluices of the Massingir dam wall were raised in 2007 (Ferreira and Pienaar 2011). This brought about a drastic alteration of the aquatic habitat in the Gorge. Mamba Weir differs from the Olifants Gorge in that regular scouring, when the Phalaborwa barrage is opened, removes sediment build-up from the weir. Riparian vegetation along this section of the Olifants River includes Sycamore fig trees. Compared to the predominantly piscivorous diet of catfish from the Olifants Gorge, fruit of the Sycamore fig trees were the most common constituent of the stomach content of catfish sampled from Mamba Weir.

A large phosphate mine is situated near the town of Phalaborwa just east of the KNP near the western entry point of the Olifants River into the KNP. For a number of years prior to 2004, and once in 2008, abnormally high phosphate levels were recorded in the Olifants River within the KNP (J Venter, SANParks, Skukuza, pers. comm. 2012). These were ascribed to the discharge of tailings from the phosphate mine in Phalaborwa into the Selati River, a

tributary of the Olifants River and to municipal sewerage discharges from the town of Phalaborwa.

This discharge was apparently discontinued after 2004 and, except during the winter of 2008, the measurement of phosphate levels in the Olifants River downstream in the KNP has shown acceptable limits (J Venter, SANParks, Skukuza, pers. comm. 2012). Dissolved phosphate is often the limiting nutrient governing phytoplankton growth in fresh water. The high levels of phosphate reaching Lake Massingir may have been a significant stimulus for phytoplankton growth resulting in the blooms observed in 2008 (J Myburgh, Faculty of Veterinary Science, University of Pretoria, pers. comm. 2008).

During periods of flooding the Olifants River carries large loads of silt. From time to time this is exacerbated when the Phalaborwa Barrage, on the Olifants River just west of the KNP, releases water to prevent debris build-up from damaging the sluice gates and to create space to accommodate the increased flow. Downstream, occasional fish kills have resulted from the oxygen depletion in the Olifants River caused by this high silt burden. During such episodes in February 1999 and January 2004 large biomasses of silver carp were identified amongst the dead fish in the Olifants River within KNP, confirming the presence of large numbers of this species during these months (J Venter, SANParks, Skukuza, pers. comm. 2012).

The high prevalence of steatitis in captive catfish at Lunsklip Fisheries could be ascribed to the excessive intake of trout slaughterhouse waste that was observed rotting in the catfish pond and hence was likely to contain rancid fats.

## 6.2 Pathology

Necrosis of the adipose tissue resulting in steatitis was the main pathological change repeatedly observed in sharptooth catfish from the Olifants Gorge and was a consistent indicator of oxidative stress. The fat of *C. gariepinus* is distinct from that of other fish species in that a variation in colour of the mesenteric adipose tissues appears to be normal and fat colour can thus not be used as an indication of lipid peroxidation as in other species. During the study, specific pathology relating to lipid autoxidation and pansteatitis was also observed in a captive population of sharptooth catfish suffering from known nutritionally induced pansteatitis. Observation of these fish indicated that even in severely affected fish, the condition was not rapidly fatal. Results of an unpublished trial done by the author, and not included in this study, confirmed persistence of steatitis in fish from Lunsklip Fisheries after an 11 month period during which these fish were kept in a recirculated facility on a combination of live natural as well as commercial trout food. Despite a 6 month period through the winter during which the fish refused to feed and lost body condition, there was no reduction in the amount of stored mesenteric fat nor in the degree of steatitis in the fat. Similar observations were made in channel catfish (Goodwin, 2006) and in captive alligators (Larsen et al., 1983). Catch methods imposed by the environment in the Olifants Gorge (presence of hippos and crocodiles) have limited most samplings to catching by baited hook and line. The most severely affected fish may not have taken bait and would have been easy prey for crocodiles. This heavily favoured sampling of relatively healthy fish whereas the worst affected fish remained under-represented. Despite this, significant numbers of fish with

pansteatitis were caught repeatedly in the Olifants Gorge and on a single occasion in the Sabiepoort.

Compared to control fish, catfish from most sampling sites carried heavy burdens of parasites. Frequent and varied pathology associated with parasites was observed in most of the wild caught fish and varied between sampling sites depending on parasite burdens and prevalence of specific parasites. Despite the associated pathology, presence of parasites appeared to be well tolerated by the fish. Fish from Reënvoël Dam, a population where steatitis could not be demonstrated, showed the heaviest parasite burdens. Focal steatitis with minimal lipopigment formation was observed only infrequently in association with parasites and no correlation could be demonstrated between parasite burden and steatitis. The steatitis described in association with lipoidosis and streptococcosis in cultured silver perch (*Bidyanus bidyanus*) (Deng et al., 2012) was similarly characterised by an absence of ceroid within the necrotic lesions in fat deposits observed in various organs. It is interesting to note the presence of metacercariae of *Centrocestus formosanus* in gills of catfish from KNP, as spread of this zoonotic parasite has been associated with introduction of carp from Asia elsewhere (Velez-Hernandez et al, 1998).

Various degrees of hepatic lipidosis and ceroidosis were observed in fish with severe steatitis. The clustering of haemosiderin around the perimeter of fat accumulation in livers of fish with steatitis is interesting in that redox cycling of iron has been implicated as a cause of iron catalysed lipid peroxidation (Minotti and Aust, 1992), however, such ferric iron compounds may be derived predominantly from haemoglobin catabolism (Mocca et al., 1984) in which case, bound to transferrin or sequestered as haemosiderin, the iron is well tolerated by the liver (Hayes, 2004). Splenomegaly was a consistent finding in fish with steatitis, as was splenic haemosiderosis, indicative of increased haemoglobin catabolism. Reduced feed intake by these fish appeared to result in the observed atrophy of the pancreatic acinar tissues. Muscular dystrophy as described in association with pansteatitis and vitamin E deficiency in other species of fish (Murai and Andrews, 1974, Roberts et al., 1979; Smith et al., 1972) was not observed in fish with pansteatitis from either the Olifants Gorge or Lunsklip Fisheries. This may reflect adequate dietary intake of vitamin E in these fish. Although vitamin E levels are known to deplete with acute pro-oxidant exposure, dietary vitamin E deficiency, rather than lipid peroxidation, has been implicated as the cause of muscular dystrophy observed in various species (Smith et. al., 1972). Although an integral part of the aetiology of pansteatitis, from the results of this study a primary vitamin E deficiency appears unlikely.

### **6.3 Steatitis and the Crocodile Mortality**

During the sampling period from 2009 to 2011 a rising prevalence of steatitis was detected in fish sampled from the Olifants Gorge. However the level of obesity declined in the fish during this period. In the same period there has been a decline in crocodile mortality. The crocodile mortality in the Olifants Gorge began in the winter of 2008 after the sluices of Lake Massingir were raised in 2007 (Ferreira and Pienaar 2011). As the waters of the lake dammed back and flooded a large part of the gorge, the aquatic environment of the gorge was



drastically altered with likely changes in the amount of fish available for crocodiles and catfish to feed off. Large crocodiles dying of steatitis in 2008 were found to be extremely fat. By 2009 emaciated crocodiles were also observed in the Olifants Gorge. Recent surveys by SANParks have indicated that younger crocodiles have moved into the gorge (D Pienaar, SANParks, Skukuza, pers. comm. 2012). Some of the surviving large crocodiles have become leaner, and wasted animals have been observed. On autopsy, such animals were found to be suffering from pansteatitis (D. Govender, SANParks, Skukuza, pers. comm. 2011). Similar wasting of catfish, suffering from steatitis, has been observed in the Olifants Gorge. An unpublished trial done by the author, and not included in this study, has confirmed that lesions of nutritionally induced steatitis in the fat of sharptooth catfish remain unchanged over time once the diet has been corrected. These fish are unable to fully access fat reserves damaged by steatitis. If unable to find or catch food, such fish will show wasting of body musculature despite retention of fat in the adipose depots. Danse and Verschuren (1978) have shown that stimulated lipolysis in rats was reduced in adipose tissues affected by steatitis.

As poikilothermic animals do not need energy to maintain homeothermy, starvation leading to death can be protracted over many months during which the starving animal will first utilize available fat reserves. Once fat reserves have become depleted or are no longer accessible, as in the case of pansteatitis, the animal will metabolize amino-acids from the body musculature as a source of energy. Such catabolic processes explain the wasting observed in both crocodiles and catfish chronically affected by pansteatitis in the Olifants Gorge. Poikilothermic animals that are unable to access damaged fat depots need to keep feeding to avoid muscular wasting and starvation. The captive fish at Lunsklip Fisheries were fed throughout the year. At the latitude of the Olifants River, wild crocodiles reduce feeding during the cooler winter months. The accelerated effects of starvation in those individuals affected by pansteatitis may partially explain why crocodile mortalities were restricted to the winter months.

#### **6.4 Haematology and Blood Chemistry**

In catfish with steatitis from both the Olifants Gorge and Lunsklip Fisheries the oxidative stress resulting in steatitis appears to have remained specifically limited in location to the adipose tissues as reflected in the pathology. For the selected haematology and blood chemistry parameters no significant differences could be detected between fish with and without steatitis from both the Olifants Gorge and Lunsklip Fisheries and may have been a reflection of the chronic nature of the condition in these fish. Significant numbers of catfish with depressed serum vitamin E values correlated to sites with high steatitis prevalence in the Olifants Gorge yet catfish from Lunsklip Fisheries with severe chronic steatitis showed normal serum vitamin E values.

Vitamin E plays an integral role in cell membrane integrity and growth, and in the case of rainbow trout, feeding of diets deficient in vitamin E or containing rancid oxidised fish oils has been held accountable for an increase in the number of polychromatocytes and crenation of immature erythrocytes (Moccia et al., 1984), both changes observed in blood smears from catfish from the Olifants Gorge and Lunsklip Fisheries but not from fish from Reënvoël Dam.

Under similar feeding conditions an increase in polychromatocytes with large rounded granular nuclei has also been reported from channel catfish (Murai and Andrews, 1974). In farmed channel catfish and rainbow trout, microcytic anaemia has been associated with feeding of rancid diets deficient in vitamin E (Smith, 1979; Murai and Andrews, 1974). Where oxidised fish oils were fed to farmed rainbow trout, development of anaemia could be prevented by dietary vitamin E supplementation (Moccia et al., 1984). The fact that fish from Lunsklip Fisheries did not develop anaemia despite developing severe steatitis may be a reflection of the consistently higher serum vitamin E levels found in these fish when compared to those of fish from the Olifants Gorge. The increased haemoglobin catabolism observed in vitamin E deficient rainbow trout, resulting from the degeneration and failure of polychromatocytes to fully mature, has been associated with resultant splenic haemosiderosis (Moccia et al., 1984). Intermittent increased erythrocyte fragility leading to haemolysis and increased erythrocyte turnover at times of oxidative stress challenge may have been responsible for the sometimes high levels of haemosiderin observed histologically in the splenic and hepatic macrophages of catfish from the Olifants Gorge (Huchzermeyer et al., 2011).

Changes in fluid partitioning between blood and lymph are likely to be rapid, variable and pronounced during stressful episodes, such as occur during sampling of wild fish. This is a reflection of the close association of blood and lymph in fish (Branson, 1993). Haematocrits in fish from all sampling sites were very variable, and no significant variation could be demonstrated in haematocrit values between fish with and without steatitis. Comparison of mean haematocrit values however, showed significant variation between fish sampled from the Olifants Gorge and fish sampled from Lunsklip Fisheries and Reënvoël Dam. The mean PCV value from the Lunsklip Fisheries fish was higher than for fish from the Olifants Gorge. This is interesting as the majority of fish from Lunsklip Fisheries were obese and suffering from chronic and protracted steatitis. Fish from Reënvoël Dam showed the lowest mean haematocrit values, but did not show the individual low values found in fish from the Olifants Gorge. Whereas all attempts were made to minimise sampling associated stress, osmotic disruption is impossible to avoid when catching fish. The variability of factors resulting in stress during sampling was likely to have impacted on haematocrit values of the fish limiting the usefulness of this parameter in wild fish.

The haemoglobin values of fish sampled from Lunsklip Fisheries, despite the high prevalence of steatitis, were significantly higher than haemoglobin values in fish from both the Olifants Gorge and Reënvoël Dam. Significantly, the haemoglobin values of fish from the Olifants Gorge were lower than those of fish from Reënvoël Dam, possibly indicating a higher erythrocyte turnover in these fish at the time of sampling, a change consistent with oxidative stress and low vitamin E levels and reflected in the observed haemosiderin deposits within hepatocytes and splenic and hepatic macrophages.

In aquatic systems oxidative stress studies have centred on depletion and induction of various antioxidant defences. In fish the antioxidant protective enzyme glutathione peroxidase shows higher basal activity than the enzymes superoxide dismutase and catalase when compared to

other vertebrate systems, making glutathione peroxidase a suitable biomarker of oxidative damage in fish (Kelly et al., 1998). Measurement of blood values of the *in vivo* antioxidants vitamin E and glutathione peroxidase showed no statistical difference between catfish with and without steatitis from the Olifants Gorge. Apparent differences in erythrocyte glutathione peroxidase values were detected between sampling sites with the highest values detected in fish sampled from the Olifants Gorge during July 2010. Similarly high values were also measured in fish sampled from Mamba Weir and Engelhard Dam at the same time. Different prevalence of steatitis was identified at these three sites. As there were no significant differences in the glutathione peroxidase values of fish with and without steatitis, the significance of these high erythrocyte glutathione peroxidase values should be viewed with suspicion. There was also no significant difference in mean erythrocyte glutathione peroxidase values between fish sampled from Lunsklip Fisheries and Reënvoël Dam, possibly as a result of the higher serum vitamin E values measured in these fish but also a reflection of the chronic nature of the condition in the catfish from Lunsklip Fisheries.

Mean serum vitamin E values in fish from the Olifants Gorge were significantly lower than mean values for fish sampled from Lunsklip Fisheries, but only slightly higher than mean values from fish sampled from Reënvoël Dam. These differences may reflect differences in dietary intake rather than being an expression of oxidative stress. It is interesting to note that a high percentage of individual fish with significantly reduced serum vitamin E values were sampled only from sites in the KNP where steatitis occurred in the fish.

From the pathology observed in catfish from Lunsklip Fisheries it is evident that steatitis observed in these fish was a chronic manifestation of prolonged continuous exposure. The adaptation of antioxidant protective mechanisms to chronic exposure to pro-oxidants, resulting in the chain reaction of lipid peroxidation (Kelly et al., 1998), may explain the similarity in erythrocyte glutathione peroxidase values found in these fish when compared to those of healthy fish from Reënvoël Dam. In the Olifants Gorge, the initiating cause of steatitis may have no longer been present at the time when lesions in the adipose tissues were noted, explaining why only some fish from the Olifants Gorge showed depleted serum vitamin E levels and why these did not necessarily correspond to presence of steatitis in these fish. During this study, only serum vitamin E levels were measured. Kelly et al., (1998) also ascribe a lipid protective role to ascorbic acid which acts through regeneration of tocopherol. Catfish from Lunsklip Fisheries were fed exclusively on trout slaughter house waste that would have reflected the high vitamin E and ascorbic acid inclusion in the commercial diet being fed to the trout. The slightly higher average serum vitamin E values from fish from Lunsklip Fisheries and the absence of fish with depleted serum vitamin E values are a likely reflection of continuous high vitamin E and ascorbic acid intake by these fish, despite the apparent rancidity of the diet which they were fed. It is interesting to note that peroxidation of lipids in the adipose tissues resulting in the observed pansteatitis in these fish took place despite the consistently high serum vitamin E values that were measured.

Serum vitamin E and erythrocyte glutathione peroxidase determinations, shown to be useful in studying the acute manifestations of pansteatitis in cats (Fytianou et al., 2006), appeared to

be of limited use as a monitoring tool for oxidative stress exposure of catfish in the lower Olifants and Letaba rivers. The diagnosis of oxidative stress in live fish from the Olifants Gorge is further complicated by the possible intermittent exposure and the resultant protracted chronic nature of the observed lesions. More work needs to be done before these or similar tests can be used to monitor the status of fish in these rivers. Determining malondialdehyde levels in the lipid fraction of serum by use of the thiobarbituric acid reactive substances test still needs to be evaluated as a monitoring tool.

### **6.5 Xenobiotics as Possible Cause of Steatitis**

Coetzee et al. (2002) have demonstrated site specific bioaccumulation of metals in sharptooth catfish in the upper catchment of the Olifants River, an area heavily impacted by afforestation, mining, power generation, irrigation and industrial activities. Oberholster et al. (2011) have proposed that aluminium and iron bio-accumulation by fish in Lake Loskop may have induced the yellow fat observed in fish from that site. Baker et al. (1997) have however proposed that African catfish efficiently regulate iron status and are able to prevent tissue assimilation of dietary iron intake. This is an important adaptation to their benthic habitat, in which they are likely to consume sediment burrowing organisms with inadvertent ingestion of sediment. Deposition of sediments in the Olifants Gorge has been of concern regarding release of pollutants at this site and the ingestion of sediment-rich detritus was observed in fish sampled from the Olifants Gorge on the Mozambique border. Hepatic iron levels in fish from the Olifants Gorge were lower than in fish from Lunsklip Fisheries (Dixon et al., 2011), supporting the argument for increased haemoglobin catabolism in pancreatitis affected fish as the cause of these higher iron levels when compared to those in fish from Reënvoël Dam.

It is a well-established fact that many xenobiotics exert their harmful effects through oxidative damage to phospholipid structures in various organs and tissues. Exposure to such pollutants would be expected to result in detectable pathology in various organs. In catfish from the Olifants Gorge, significant pathology was restricted to the adipose tissues with the most intense and frequent lesions being present in the mesenteric fat reserves. Further pathology observed in the livers, spleen and pancreas was probably secondary to fat necrosis observed in the adipose tissues. Water-borne pollutants or bio-accumulated xenobiotics moving up the food chain would be expected to exert similar pathology in fish feeding at the same trophic level. Isotopic studies of the lotic food web in the Olifants Gorge have indicated that catfish from this locality had changed their dietary niche to a trophic level similar to that of tiger fish, an obligate piscivore, and that both tiger fish and catfish occupy a higher trophic level in the Olifants Gorge than in other river systems in the KNP (Woodborne et al., 2012), yet tiger fish in the Olifants Gorge do not develop steatitis. Use of metallothionins, acetylcholinesterase and ethoxyresorufin-O-deethylase, biomarkers respectively of metal, organophosphate and carbamate, and organochlorine exposure, have been proposed for monitoring the state of tiger fish in the KNP (Van Vuuren, Wepener, Smit and Vlok, 2012) and may be found suitable for future monitoring of catfish.

### **6.6 Dietary Change and Steatitis in the KNP**

The sharptooth catfish is a benthic opportunistic scavenger that is also known to actively hunt and prey on other fish (Skelton, 2001). Food source varied distinctly between sampling sites and prevalence of fish in the diet correlated with presence of steatitis in catfish from the Olifants Gorge and the Sabiepoort. Fish remnants observed in the stomach content of catfish from the Olifants Gorge, often in an advanced stage of digestion, frequently consisted of bones and scales of noticeably large unidentified fish. In the Olifants Gorge both crocodiles and catfish have been observed incidentally feeding off the carcasses of dead crocodiles (D Pienaar, SANParks, Skukuza, pers. comm. 2009) and crocodile fat afflicted with steatitis was found in the stomach contents of some catfish sampled from the Sabiepoort. In contrast, stomach content of catfish from Van Ryssen Dam contained only Mozambique tilapia. These fish showed no signs of steatitis. Although factors associated with a fish diet appear to be associated with development of steatitis in catfish in the Olifants Gorge, these must be distinct from a natural healthy fish diet as observed in fish from Van Ryssen Dam and documented elsewhere in the literature (Spataru et al., 1987).

As a consequence of raising the sluices of Lake Massingir, the waters of the lake have extended into the KNP causing a habitat change in the Olifants Gorge that may have favoured a change in access to certain species of fish not normally consumed in large numbers by crocodiles and catfish. This could have exposed these animals to levels of polyunsaturated fatty acids in the diet to which they are not adapted. An increase in dietary polyunsaturated fat intake has been reported to result in pansteatitis in various animals. Wallach and Hoessle (1968) concluded that a change in diet from smelt (6.7% fat) to mackerel (29.9% fat) was the precipitating cause of pansteatitis in captive American alligators. Goodwin (2006) stressed the dangers of using diets high in fish oils for inappropriate species, and a change from Baltic and Mediterranean clupeids to Moroccan Atlantic pilchards was suspected to have been the cause of pansteatitis in northern bluefin tuna reported by Roberts and Agius (2008). Similarly pansteatitis could be induced in cats by feeding an oil rich fish-based diet (Fytianou et al., 2006).

The n-6 and n-3 fatty acids derived from linoleic and  $\alpha$ -linolenic acids respectively are essential fatty acids that cannot be synthesized by animals (Steffens, 1997). The relative abundance of these fatty acids in the diet of animals is reflected in the composition of their fat tissues (Hoffman and Prinsloo, 1995; Steffens, 1997). The fatty acid composition of marine fish oils and in particular the high n-3 to n-6 ratio of polyunsaturated fatty acids contained in these oils is a reflection of the fatty acid composition of marine phytoplankton (Steffens, 1997). Whereas the ratio of total n-3 to n-6 fatty acids in marine fish oils typically lies between 5 and more than 10, that of freshwater fish is much lower, ranging from 1 to 4 (Steffens, 1997). In freshwater fish, as in marine fish, these fatty acid ratios are influenced by the composition of the diet. In nutrition trials the n-3 to n-6 fatty acid ratio in muscle lipid of sharptooth catfish could be manipulated from 0.1 in fish on a sunflower oil diet to 1.8 in fish on a cod liver oil diet (Hoffman and Prinsloo, 1995). The fat of captive farmed crocodiles, receiving a diet of chicken, beef and horse meat, had an n-3 to n-6 fatty acid ratio of 0.08 (Osthoff et al., 2010). By contrast the n-3 to n-6 ratio of fatty acids in the fat of wild crocodiles suffering from steatitis from the Olifants and lower Letaba Rivers was found to be



2 (Osthoff et al., 2010). Compared to the fat of farmed crocodiles, this reflected a much higher intake of n-3 fatty acids by crocodiles in the Olifants Gorge. Mean ratios of n-3 to n-6 fatty acids in catfish with mild or no steatitis sampled from Lunsklip Fisheries, Reënvoël Dam and the Olifants Gorge in November 2009 were 0.8, 1.32 and 0.96 respectively (Huchzermeyer et al., 2012). There appeared to be no significant difference in n-3 to n-6 ratio between fish from Lunsklip Fisheries with varying degree of severity of steatitis in fish. The fish with severe steatitis sampled from the Olifants Gorge, however, had an n-3 to n-6 fatty acid ratio of 2.87 compared to 0.92 in fish with only mild or no steatitis (Huchzermeyer et al., 2012). From these results it can be inferred that rancidity rather than high polyunsaturated fatty acid intake was the cause of the steatitis observed in catfish from Lunsklip Fisheries. By extension of this argument it would seem unlikely that rancidity associated with intake of dead rotting fish could have been the cause of pansteatitis in the Olifants Gorge catfish and crocodiles.

Steatitis was confirmed in catfish from primarily three locations within KNP; the Olifants Gorge and lower Letaba River at the confluence with the Olifants River, from Engelhard Dam on the Letaba River upstream of the Olifants-Letaba confluence and from the Sabiepoort. Catfish with steatitis may have migrated from the Olifants Gorge upstream to Engelhard Dam and this may be one explanation for the presence of steatitis affected fish at this site, but the Sabiepoort on the Sabie River is in an entirely separate catchment. The anthropogenic activities resulting in potential pollution of the rivers differ greatly between these two catchments providing further argument against primary pollution related aetiology of the pansteatitis incidence at these two sites. Common to both the Olifants Gorge and the Sabiepoort is the damming of the rivers in Mozambique to form lakes Massingir and Corumana respectively. The inlets of both lakes extend back into the KNP flooding the respective gorges where these rivers previously traversed the Lebombo Mountains as fast flowing rapids.

Silver carp (*Hypophthalmichthys molitrix* Valenciennes), an invasive species outside of its home range in East Asia (Kolar et al., 2005), were introduced into Mozambique from Cuba and are known to occur in Lake Massingir (Skelton, 2001). Silver carp are also known to have escaped into the Olifants River in South Africa and may have spread downstream (P Skelton, South African Institute of Aquatic Biodiversity, Grahamstown, pers. comm. 2012). This fish is a specialized plankton feeder that by preference feeds off phytoplankton and is an important consumer of cyanobacterial blooms, with *Microcystis* constituting 20-98% of the food bolus during some seasons (Kolar et al, 2005). Such blooms have been observed near the inlet to Lake Massingir (D Pienaar, SANParks, Skukuza, pers. comm. 2009). Phytoplankton naturally contain large quantities of  $\alpha$ -linolenic acid and other n-3 polyunsaturated fatty acids in particular eicosapentaenoic acid C20:5n-3(EPA) and docosahexaenoic acid C22:6n-3(DHA) (Steffens, 1997). Intake of these fatty acids is reflected in the adipose tissues of silver carp, with these two fatty acids, in one study, making up to 5.28 and 3.4% of body fat triacylglycerols respectively (Buchtová and Ježek, 2011). As a result of the high levels of C20 and C22 fatty acids, consumption of the fat of silver carp

has been proposed to have health benefits to human consumers equivalent to those of oil-rich marine fish (Buchtová and Ježek, 2011, Steffens, 1997).

A significant proportion of the essential fatty acids derived from the diet are stored in the adipose tissues of animals and of these, DHA is deposited into the adipose tissues preferentially over EPA (Connor et al., 1990). Although the polyunsaturated fatty acids are mobilised more rapidly from the adipose tissues than saturated fats, DHA, the most polyunsaturated fatty acid has been shown to be poorly mobilised (Connor et al., 1996). The higher levels of DHA found in the mesenteric fat of catfish from the Olifants Gorge with steatitis (11.06%) compared to mesenteric fat of those without steatitis (5.09%) strongly points to a higher intake of DHA in the diet of those fish that developed steatitis at this site (Huchzermeyer et al., 2012). A similar differentiation was not observed in the mesenteric fat of catfish with mild and severe pansteatitis from Lunsklip Fisheries, supporting the argument for a different dietary aetiology, most likely associated with rancidity of fats in the slaughter house waste fed to these fish.

Steatitis could not be demonstrated in tiger fish sampled from the Olifants Gorge. Tiger fish, having evolved as obligate piscivores, are likely to have developed anti-oxidant protective mechanisms better enabling them to cope with the consumption of higher levels of dietary polyunsaturated fats than the omnivorous catfish.

Silver carp, a schooling species, seasonally migrate upstream into rivers from the still waters of lakes to spawn (Skelton, 2001). Spawning is associated with an increase in suspended alluvium and a rise in water level of the river and occurs over an 8 to 10 week period (Kolar et al., 2005). The spawning migration takes place during early to midsummer and in the Olifants Gorge this mass migration may account for intense dietary exposure of crocodiles and catfish to this species and the consequential intake of excessive polyunsaturated fats during a short period each year. This may explain the increase in crocodile mortality during the subsequent autumn and winter as observed in 2008 and to a lesser extent in the following years. In the Olifants Gorge fish surveys are conducted by KNP scientists during the winter months when the river can be safely accessed and the waters of the river become clearer (A Deacon, SANParks, Skukuza, pers. comm. 2012). Movement of silver carp into the Olifants Gorge may thus easily have been over looked. It is proposed that by raising the sluices of Lake Massingir, the resulting habitat change that occurred in the Olifants Gorge may have seasonally favoured access by crocodiles and catfish to large schools of silver carp. The situation in the Sabiepoort is less clear as presence of silver carp in this lake has not been confirmed; however, similarity in habitat to the Olifants Gorge also points to consumption of fish rich in polyunsaturated fats as the cause of steatitis at this site.

## 7 CONCLUSION AND RECOMMENDATIONS

This study has shown that sharptooth catfish in the Olifants Gorge develop steatitis and that during the study period there was an increasing prevalence of steatitis in these fish. Co-existence of old and recent lesions indicated an on-going incitement of steatitis. Catfish have been shown to be a suitable monitoring species for pansteatitis in crocodiles as they appear to show similar sensitivity to pansteatitis within their overlapping habitat. Whereas the Nile crocodile is classed as endangered, the sharptooth catfish is an abundant species that in the Olifants Gorge and Sabiepoort is relatively easy to sample.

Several explanations for the cause of pansteatitis in crocodiles and fish in the Olifants Gorge have been proposed. Bio-accumulation of one or more xenobiotics resulting from upstream pollution cannot be ruled out. However, lack of known pollutant related pathology in catfish from the Olifants Gorge and the fact that steatitis was found in catfish in the Sabiepoort, which would have a different pollution profile, makes this aetiology seem unlikely. Consumption of large quantities of dead rotting fish seems unlikely as a cause of the pansteatitis as mass fish mortality has not been a consistent finding at the sites where steatitis was observed and the fatty acid profile of farmed catfish fed rancid fish fats differed from that of catfish suffering from steatitis in the Olifants Gorge. It would also seem unlikely that consumption of catfish suffering from steatitis alone could have precipitated the pansteatitis outbreak in the crocodiles. More convincingly, this study raises the possibility that seasonal abundance of fish species rich in n-3 polyunsaturated fats in the diet of catfish and crocodiles in the Olifants Gorge may have resulted in development of pansteatitis in these two species and that habitat change brought about by damming of rivers extending into KNP influenced access to such fish. However, it is not clear whether the same factors were responsible for the development of pansteatitis in catfish from the Sabiepoort. The situation at this site warrants further study.

The association between nutrient pollution of the aquatic environment, eutrophication and the influence of phytoplankton on fatty acid composition of fish consuming such phytoplankton needs further study. The role of phosphate discharges into the Olifants River, the impact of dam building and subsequent silt and nutrient entrapment on relative fish species abundance, and particularly the presence of alien silver carp within the KNP need to be investigated. Pansteatitis in wild fish is a unique finding and although work is being done on fish from Lake Loskop (J Myburgh, J Steyl, Faculty of Veterinary Science, University of Pretoria, pers. comm. 2009); further work needs to be done to establish the extent to which steatitis may be present in fish in other artificial lakes in polluted catchments.

The analysis of heavy metals in the fish tissues collected during the course of this study has not been completed. The possibility of bioaccumulation of iron following the consumption of phytoplankton, (as documented in Lake Loskop by Oberholster et al. (2011)), still needs to be investigated in the fish of Lake Massingir and the Olifants River Gorge.

Comment [a1]: Inseted full stop

The study emphasizes the ecological importance and complexity of oxidative stress in a disturbed aquatic environment and the risk associated with the presence of alien invasive fish species within our national parks. It is recommended that the distribution of alien fish species within rivers traversing the KNP is investigated and that in dams within KNP and elsewhere in South Africa the long-term effects of hydrodynamic change and nutrient entrapment on the aquatic food chain are monitored with particular reference to the health of top aquatic predators such as crocodiles.

## **8 BENEFITS**

The study provides SANParks with information on the extent of pathology in sharptooth catfish in the Olifants River and other water bodies in KNP and the risks attached to damming of rivers that traverse the Park, particularly where these are nutrient enriched. Such information is important to guide conservation policy and decisions regarding use of water and the safety of fish consumed from such waters. Distinct parallels in the pathology observed in crocodiles and catfish in the Olifants Gorge have been demonstrated. Within KNP the distribution of crocodiles and catfish overlap. Although sharptooth catfish were thought to form a major part of the diet of crocodiles within the river gorges of the Park, this study has provided valuable knowledge suggesting how the deleterious impacts of hydrodynamic change on the fresh water ecosystems within KNP, brought about by damming of rivers, has allowed crocodiles and catfish to access phytoplankton-feeding fish species in their diet at levels to which they are not adapted.

Sharptooth catfish are an abundant and ubiquitous species in southern African rivers. The results of this study confirm that this fish is a suitable monitoring species in the aquatic environment and can be used by SANParks to monitor fish and indirectly crocodile health. Demonstration of a direct causal relationship between pancreatitis and one or more pollutants could not be demonstrated, but cannot be ruled out. Co-workers have received the entire sample set for toxicological analysis. Should results of such analyses show a causal relationship this will provide SANParks with further information to insist on prevention of pollution entering KNP.

The current study illustrates how the complex interaction of nutrient pollution, construction of dams outside of the borders of South Africa and introduction of alien fish species into such lakes can threaten the biodiversity of the KNP rivers and the future of the Nile crocodile in the KNP. The research was undertaken as part of the CROC initiative at the request of SANParks. The study provides South Africa and its authorities with information to insist that environmental controls ensuring the quality of water in our rivers are implemented and provides SANParks with information to insist on prevention of pollution and alien fish species entering KNP, thereby ensuring the biodiversity of the KNP rivers and securing the future of the Nile crocodile in the KNP.

## 9 REFERENCES

- ADAMS SM, BROWN AM, GOEDE RW (1993) A quantitative health assessment index for rapid evaluation of fish condition in the field. *Transactions of the American Fisheries Society* **122** 63-73
- AGRESTI A, FRANKLIN C (2007) *Statistics: The Art of Learning from Data*. Pearson Prentice Hall, Pearson Education, Inc. New Jersey 693pp
- ÅKERMAN G, AMCOFF P, TJÄNLUND U, FOGELBERG K, TORRISSEN O, BALK L (2002) Paraquat and menadione exposure of rainbow trout (*Oncorhynchus mykiss*)-studies of effects on pentose-phosphate shunt and thiamine levels in liver and kidney. *Chemico-Biological Interactions* **142** 269-283
- ASHTON PJ (2010) The demise of the Nile crocodile (*Crocodylus niloticus*) as a keystone species for aquatic ecosystem conservation in South Africa: The case of the Olifants River. *Aquatic Conservation: Marine and Freshwater Ecosystems* **20** 489-493
- AVENANT-OLDEWAGE A (2004) *Freshwater Fish and Human Health*. Appendix A. Fish as bio-monitoring tools: Development of the fish health assessment index (HAI). Water Research Commission WRC Report No TT212/04 pp A1-15
- AVENANT-OLDEWAGE A (2004) *Freshwater Fish and Human Health*. Appendix B. A reference guide for determining the human health risks of consuming freshwater fish in South Africa. Protocol for the assessment of fish health. User's manual. Water Research Commission WRC Report No TT212/04 pp B1-18
- AWAD JA, MORROW JD, HILL KE, ROBERTS LJ, BURK RF (1994) Detection and localization of lipid peroxidation in selenium- and vitamin E-deficient rats using F<sub>2</sub>-isoprostanes. *Journal of Nutrition* **124** 810-816
- BACHOWSKI S, XU Y, STEVENSON DE, WALBORG Jr EF, KLAUNIG JE (1998) Role of oxidative stress in the selective toxicity of dieldrin in the mouse liver. *Toxicology and Applied Pharmacology* **150** 301-309
- BAKER RTM, DAVIES SJ (1997) Modulation of tissue  $\alpha$ -tocopherol in Africa catfish, *Clarias gariepinus* (Burchell), fed oxidized oils, and the compensatory effect of supplemental dietary vitamin E. *Aquaculture Nutrition* **3** 91-97
- BAKER RTM, MARTIN P, DAVIES SJ (1997) Ingestion of sub-lethal levels of iron sulphate by African catfish affects growth and lipid peroxidation. *Aquatic Toxicology* **40** 51-61
- BAINY ACD, SAITO E, CARVALHO PSM, JUNQUEIRA VBC (1996) Oxidative stress in gill, erythrocytes, liver and kidney of Nile tilapia (*Oreochromis niloticus*) from a polluted site. *Aquatic Toxicology* **34** 151-162
- BELL JG, COWEY CB, ADRON JW, SHANKS AM (1985) Some effects of vitamin E and selenium deprivation on tissue enzyme levels and indices of tissue peroxidation in rainbow trout (*Salmo gairdneri*). *British Journal of Nutrition* **53** 149-157

- BOTHA H, VAN HOVEN W, GUILLETTE LJ(2011) The decline of the Nile crocodile population in Loskop Dam, Olifants River, South Africa, *Water SA***37** 103-108
- BRANSON E (1993) Basic anatomy and physiology. In: *Aquaculture for Veterinarians: Fish Husbandry and Medicine* (ed. L. Brown) Pergamon Press, Oxford, New York, Seoul, Tokyo pp 1-30
- BUCHTOVÁ H, JEŽEK F (2011) A new look at the assessment of silver carp (*Hypophthalmichthys molitrix* Val.) as a food fish. *Czech Journal of Food Science***29** 487-497
- BURTON GW (1994) Vitamin E: molecular and biological function. *Proceedings of the Nutrition Society***53** 251-262
- BUS JS, AUST SD, GIBSON JE (1976) Paraquat toxicity: proposed mechanism of action involving lipid peroxidation. *Environmental Health Perspectives***16** 139-146
- COETZEE L, DU PREEZ HH, VAN VUUREN JHJ (2002) Metal concentrations in *Clarias gariepinus* and *Labeo umbratus* from the Olifants and Klein Olifants River, Mpumalanga, South Africa: Zinc, copper, manganese, lead, chromium, nickel, aluminium and iron. *Water SA***28**433-448
- CONNOR WE, LIN DS, COLVIS C (1996) Differential mobilization of fatty acids from adipose tissue. *Journal of Lipid Research***37** 290-298
- DANSE LHJC, VERSCHUREN PM (1978) Fish oil induced yellow fat disease in rats. III. Lypolysis in affected adipose tissue. *Veterinary Pathology***15** 544-548
- DE VILLIERS S, MKWELO ST (2009) Has monitoring failed the Olifants River, Mpumalanga? *Water SA***35** 671-676
- DENG CY, PENG, JH, CHEN MM, CHEN MH, CHANG PH (2012) Lipoidosis, steatitis, and streptococcosis in mariculture of silver perch (*Bidyanus bidyanus*). *Bulletin of the European Association of Fish Pathologists***32** 49-55
- DIXON R, HUCHZERMEYER D, ESPACH H, HUCHZERMEYER F (2011) Baseline metal levels in *Clarias gariepinus* and *Crocodylus niloticus* in the Kruger National Park in relation to pansteatitis. South African National Parks 9<sup>th</sup> Annual Savanna Science Network Meeting. 13-18 March 2011 Skukuza
- ELLEDER M (1991) Primary extracellular ceroid type lipopigment. A histochemical and ultrastructural study. *Histochemical Journal***23** 247-258
- FERREIRA SM, PIENAAR D (2011) Degradation of the crocodile population of Kruger National Park, South Africa. *Aquatic Conservation: Marine and Freshwater Ecosystems* **21**155-164



FYTIANOU A, KOUTINAS AF, SARIDOMICHELAKIS MN, KOUTINAS CK(2006) Blood  $\alpha$ -tocopherol, selenium, and glutathione peroxidase changes and adipose tissue fatty acid changes in kittens with experimental steatitis (yellow fat disease). A comparative study between the domestic shorthaired and siamese breed. *Biological Trace Element Research* **112** 131-143.

GONZALEZ MJ, GRAY JI, SCHEMMEL RA, DUGAN Jr L, WELSCH CW (1992) Lipid peroxidation products are elevated in fish oil diets in the presence of added antioxidants *Journal of Nutrition* **122** 2190-2195

GOODWIN AE (2006) Steatitis, fin loss and skin ulcers of channel catfish, *Ictalurus punctatus* (Rafinesque), fingerlings fed salmon diets. *Journal of Fish Diseases* **29** 61-64

HALARE AV, SEILER T-B, HOLLERT H (2011) The versatile, changing, and advancing roles of fish in sediment toxicity assessment-a review. *Journal of soils and Sediments* **11** 141-173

HASSOUN E, BAGCHI M, BAGCHI D, STOHS SJ (1993) Comparative studies on lipid peroxidation and DNA-single strand breaks induced by lindane, DDT, chlordane and endrin in rats. *Comparative Biochemistry and Physiology* **104C**427-431

HAYES AM (2004) Pathophysiology of the liver. In: Dunlop R. H. and Malbert C-H. (Eds) *Veterinary Pathophysiology*. First edition. Blackwell Publishing Professional, Ames Iowa, USA; Carlton, Victoria, Australia. pp 371-399

HEATH R, DU PREEZ H, GENTHE B, AVENANT-OLDEWAGE A (2004) *Freshwater Fish and Human Health Reference Guide*. A report to the Water Research Commission. WRC Report No TT213/04. 93pp

HEATH R, COLEMAN T, ENGELBRECHT J (2010) Water quality overview and literature review of the ecology of the Olifants River WRC Report No. TT452/10. 51pp

HERMAN RL, KIRCHEIS FW (1985) Steatitis in Sunapee trout, *Salvelinus alpinus oquassa* Girard. *Journal of Fish Diseases* **8** 237-239

HINCHCLIFF KW, PIERCY RJ (2000) Oxidant stress, oxidant damage, and antioxidants: Review and studies in Alaskan sled dogs. *Recent Advances in Canine and Feline Nutrition*. Volume III. 2000 IAMS NUTRITION SYMPOSIUM. *Proceedings* Wilmington, Ohio: Orange Frazer: pp 517-529

HOFFMAN LC, PRINSLOO JF (1995) Genetic and nutritional influence on the total lipid fatty acid profile of *Clarias gariepinus* muscle. *Aquatic Living Resources* **8** 415-421

HOVE EL (1955) Anti-vitamin E stress factors as related to lipid peroxides. *American Journal of Clinical Nutrition* **3** 328-336

HUCHZERMAYER FW (2003) *Crocodiles. Biology, Husbandry and Diseases*. CABI Publishing Wallingford 337pp

HUCHZERMEYER KDA, GOVENDER D, PIENAAR DJ, DEACON AR (2011) Steatitis in wild sharptooth catfish, *Clarias gariepinus* (Burchell) in the Olifants and Lower Letaba Rivers in the Kruger National Park, South Africa. *Journal of Fish Diseases* **34**489-498

HUCHZERMEYER KDA, OSTHOFF G, HUGO A, GOVENDER D (2012) Comparison of the lipid properties of healthy and pansteatitis-affected *Clarias gariepinus* and the role of diet in pansteatitis outbreaks in the Olifants River in the Kruger National Park, South Africa. Submitted for publication to *Journal of Fish Diseases*

JOLLY RD, DALEFIELD RR (1990) Lipopigments in veterinary pathology: pathogenesis and terminology. In: Porta E.A. (ed) 3rd International Symposium on Lipofuscin and Ceroid Pigments 1989 Wailea, Maui, Hawaii. Plenum Press, New York: pp 157-168

KELLY SA, HAVRILLA CM, BRADY TC, ABRAMO KH, LEVIN ED (1998) Oxidative stress in toxicology: established mammalian and emerging piscine model systems. *Environmental Health Perspectives* **106** 375-384

KOLAR CS, CHAPMAN DC, COURTENAY Jr WR, HOUSEL CM, WILLIAMS JD, JENNINGS DP (2005) Asian carps of the genus *Hypophthalmichthys* (Pisces, Cyprinidae) – A biological synopsis and environmental risk assessment. *Report to US Fish and Wildlife Service per Interagency Agreement 94400-3-0128* 175pp

LARSEN RE, BUERGELT C, CARDEILHAC PT, JACOBSON ER (1983) Steatitis and fat necrosis in captive alligators. *Journal of the American Veterinary Medical Association* **11** 1202-1204

LIN DS, CONNOR WE (1990) Are the n-3 fatty acids from dietary fish oil deposited in the triglyceride stores of adipose tissue? *American Journal of Clinical Nutrition* **51** 535-539

MINOTTI G, AUST SD (1992) Redox cycling of iron and lipid peroxidation. *Lipids* **27** 219-226

MOCCIA RD, HUNG SSO, SLINGER SJ, FERGUSON HW (1984) Effect of oxidized fish oil, vitamin E and ethoxyquin on the histopathology and haematology of rainbow trout, *Salmo gairdneri* Richardson. *Journal of Fish Diseases* **7** 269-282

MURAI T, ANDREWS JW (1974) Interactions of dietary  $\alpha$ -tocopherol, oxidized menhaden oil and ethoxyquin on channel catfish (*Ictalurus punctatus*). *Journal of Nutrition* **104** 1416-1431

NIZA MMRE, VILELA CL, FERREIRA LMA (2003) Feline pansteatitis revisited: hazards of unbalanced home-made diets. *Journal of Feline Medicine and Surgery* **5** 271-277

OBERHOLSTER PJ, MYBURGH JG, ASHTON PJ, COETZEE J, BOTHA A-M (2011) Bioaccumulation of aluminium and iron in the food chain of Lake Loskop, South Africa. *Ecotoxicology and Environmental Safety* **75** 134-141

PARVEZ S, RAISUDDIN S (2006) Effects of paraquat on freshwater fish *Channa punctata* (Bloch): Non-enzymatic antioxidants as biomarkers of exposure. *Archives of Environmental Contamination and Toxicology* **50** 392-397

- RAYNARD RS, McVICAR AH, BELL JG, YOUNGSON A, KNOX D, FRASER CO (1991) Nutritional aspects of pancreas disease of Atlantic salmon: the effects of dietary vitamin E and polyunsaturated fatty acids. *Comparative Biochemistry and Physiology***98A**125-131
- ROBERTS RJ, AGIUS C (2008) Pan-steatitis in farmed northern bluefin tuna, *Thunnus thynnus* (L.), in the eastern Adriatic. *Journal of Fish Diseases***31** 83-88
- ROBERTS RJ, RICHARDS RH, BULLOCK AM (1979) Pansteatitis in rainbow trout *Salmo gairdneri* Richardson: a clinical and histological study. *Journal of Fish Diseases***2** 85-92
- SKELTON P (2001) A Complete Guide to the Freshwater Fishes of Southern Africa. Struik Publishers, Cape Town 395pp
- SMITH CE (1979) The prevention of liver lipid degeneration (ceroidosis) and microcytic anemia in rainbow trout *Salmo gairdneri* Richardson fed rancid diets: a preliminary report. *Journal of Fish Diseases***2** 429-437
- SPATARU P, VIVEEN WJAR, GOPHEN M (1987) Food composition of *Clarias gariepinus* (= *C. lazera*) (Cypriniformes, Clariidae) in Lake Kinneret (Israel). *Hydrobiologica***144** 77-82
- STEFFENS W (1997) Effects of variation in essential fatty acids in fish feeds on nutritive value of freshwater fish for humans. *Aquaculture***151** 97-119
- STOSKOPF MK (1993) Fish Medicine. WB Saunders Company. Harcourt Brace Jovanovich, Inc. Philadelphia London Toronto Montreal Sydney Tokyo. pp 355, 463
- TAPPEL AL (1973) Lipid peroxidation damage to cell components. *Federation Proceedings***32** 1870-1874
- VAN VUUREN JHJ, WEPENER V, SMIT NJ, VLOK W (2012) Biomarkers of pollution in tiger fish, *Hydrocynus vittatus*. South African National Parks 10<sup>th</sup> Annual Savanna Science Network Meeting. 5-9 March 2012. Skukuza.
- VÉLEZ-HERNÁNDEZ EM, CONSTANTINO-CASAS F, GARCÍA-MÁRQUEZ LJ, OSORIO-SARABIA D (1998) Gill lesions in common carp, *Cyprinus carpio* L., in Mexico due to the metacercariae of *Centrocestus formosanus*. *Journal of Fish Diseases***21**229-232
- WAGENAAR GM, SMITH WC, SMIT NJ (2012a) The health status of tiger fish, *Hydrocynus vittatus*, in two rivers in the Kruger National Park using histology as a bio-monitoring tool. South African National Parks 10<sup>th</sup> Annual Savanna Science Network Meeting. 5-9 March 2012 Skukuza.
- WAGENAAR GM, SMITH WC, SMIT NJ (2012b) Histology as a bio-monitoring tool to assess the health status of selected fish species in the Levuvhu and Olifants rivers in the Kruger National Park. South African National Parks 10<sup>th</sup> Annual Savanna Science Network Meeting. 5-9 March 2012 Skukuza.

WALLACH JD, HOESSLE C (1968) Steatitis in captive crocodilians. *Journal of the American Veterinary Medical Association* **153** 845-847

WINSTON GW, DI GIULIO RT (1991) Prooxidant and antioxidant mechanisms in aquatic organisms. *Aquatic Toxicology* **19** 137-161

WOODBORNE S, HUCHZERMAYER D, GOVENDER D, PIENAAR D, HALL G, MYBURGH J, DEACON A, VENTER J, LUBCKER N (2012) Ecosystem change and the Olifants River crocodile mass mortality events. South African National Parks 10<sup>th</sup> Annual Savanna Science Network Meeting. 5-9 March 2012 Skukuza.