

Bibliography

- Adewale L, Dearlove O, Wilson B, Hindle K, Robinson DN. The caudal canal in children: a study using magnetic resonance imaging. *Paediatr Anaesth* 2000; **10(2)**:137-141.
- Ajar A, Hoeft M, Alsofrom GF, Mukerji SK, Rathmell JP. Review of brachial plexus anatomy as seen on diagnostic imaging: clinical correlation with computed tomography - guided brachial plexus block. *Reg Anesth Pain Med* 2007; **32**:79-83.
- Alexander C, Wolf S, Ghia JN. Caudal anesthesia for early onset myotonic dystrophy. *Anesthesiology* 1981; **55**:597-598.
- American Association of Clinical Anatomists, Educational Affairs Committee. The Clinical Anatomy of Several Invasive Procedures. *Clin Anat* 1999; **12**:43-54.
- Armitage EN. Caudal block in children. *Anaesthesia* 1979; **34**:396.
- Armitage EN. Regional anaesthesia in paediatrics. *Clin Anaesth* 1985; **3**:553-568.
- Arthur DS, McNicol LR. Local anaesthetic techniques in paediatric surgery. *Br J Anaesth* 1986; **58**:760-777.
- Arthur DS. Caudal anaesthesia in neonates and infants. *Anaesthesia* 1980; **35**:1136-1137.
- Arthurs OJ, Murray M, Zubier M, Tooley J, Kelsall W. Ultrasonographic determination of neonatal spinal canal depth *Arch. Dis. Child. Fetal Neonatal Ed* 2008; **93**:F451-F454.

Aziz A, Farid N, Abdelaal A. Ultrasound-guided regional anaesthesia and paediatric surgery. *Curr Anaesth Crit Care* 2009; **20(2)**:74-79.

Babitzki P. A new way of anesthetizing the brachial plexus. *Zentralbl. Chir* 1918; **45**:215-217 [Abstract in German].

Bailey PW. Median epidural septum and multiple cannulation. *Anaesthesia* 1986; **41**:881-882.

Bainbridge WS. A report of twelve operations on infants and young children during spinal anesthesia. *Arch Pediatr* 1901; **18**:510 [Abstract].

Balacesco J. Considerations sur 1241 applications de la rachianesthésie chez l'enfant. *Le Monde Medical* 1935; **45**:936-941 [Abstract].

Balog A. Leitungsanästhesie an dem infraclavicularen teile des plexus brachialis. *Zentralbl Chir* 1924; **51**:1563–1564 [Abstract in German].

Barson AJ. The vertebral level of termination of the spinal cord during normal and abnormal development. *J Anat* 1970; **106(3)**:489-497.

Bates B. A Guide to Physical Examination. Philadelphia: Lippincott, 1983.

Bazy L. L'Anesthésie du plexus brachial. In: Pauchet V, Sourdat P, Labouré J, (eds). *L'Anesthésie regionale*. Paris: Doin et Cie, 1917 [Abstract in French].

Beerle BJ, Rose RJ. Lower extremity compartment syndrome from prolonged lithotomy position not masked by epidural bupivacaine and fentanyl. *Reg Anesth* 1993; **18(3)**:189-190.

- Beilin Y, Arnold I, Telfeyan C, Bernstein HH, Hossain S. Quality of analgesia where air versus saline is used for identification of the epidural space in parturients. *Reg Anesth Pain Med* 2000; **25**:596-599.
- Berde CB. Paediatric postoperative pain management. *Pediatr Clin North Am* 1989; **36(4)**:921-940.
- Berde CB. Regional anaesthesia in children: What have we learned? *Anesth Analg* 1996; **83**:897-900.
- Berry FR. Analgesia in patients with fractured shaft femur. *Anaesthesia* 1977;**32**:576-577.
- Bier A. Versuche uÈber Cocainisierung des Rückenmarkes. *Deutsche Zeitschrift für Chirurgie* 1899; **51**:361-369 [Abstract].
- Bigeleisen PE. Ultrasound-guided infraclavicular block in an anticoagulated and anesthetized patient. *Anesth Analg* 2007; **104**:1285-1287.
- Binokay F, Akgul E, Bicakci K, Soyupak S, Aksungur E, Sertdemir Y. Determining the level of the dural sac tip: Magnetic resonance imaging in an adult population. *Acta Radiol* 2006; **4**:397-400.
- Birchansky S, Altman N. Imaging the brachial plexus and peripheral nerves in infants and children. *Semin Pediatr Neurol* 2000; **7**:15-25.
- Bloc S, Garnier T, Komly B, Leclerc P, Mercadel L, Morel B, Dhonneur G. Single-stimulation, low volume infraclavicular plexus bloc: influence of evoked distal motor response on success rate. *Reg Anesth Pain Med* 2006; **31**:433-437.

- Bloc S, Garnier T, Komly B, Leclerc P, Mercadel L, Morel B, Dhonneur G. Single-stimulation, low volume infraclavicular plexus bloc: influence of evoked distal motor response on success rate. *Reg Anesth Pain Med* 2006; **31**:433-437.
- Blomberg R. The dorsomedian connective tissue band and the lumbar epidural space in humans: an anatomical study using epiduoscscopy in autopsy cases. *Anesth Analg* 1986; **65**:747-752.
- Blumel J, Evans EB, Eggers GW: Partial and complete agenesis of malformation of the sacrum with associated anomalies. *J Bone Joint Surg Am* 1959; **41**:497-518.
- Bonica JJ. History, current status and future of regional anesthesia. *Ann Chir Gynaecol Fenn* 1984; **73**:108-117.
- Boon JM, Abrahams PH, Meiring JH, Welch T. Lumbar puncture for the generalist. *SAFP* 2004; **46**:38-42.
- Boon JM, Prinsloo E, Raath RP. A paramedian approach for epidural block: An anatomic and radiologic description. *Reg Anesth Pain Med* 2003; **28**:221-227.
- Boonpirak N, Apinhasmit W. Length and caudal level of termination of spinal cord in Thai adults. *Acta Anat* 1994; **149**:74–78.
- Borgeat A, Ekstodramis G, Dumont C. An evaluation of the infraclavicular block via a modified approach of the Raj technique. *Anesth Analg* 2001; **93**:436-441.
- Bosenberg AT, Bland BAR, Schulte-Steinberg OT, Downing JW. Thoracic epidural anesthesia via caudal route in infants. *Anesthesiology* 1988; **69**:265-269.

Bosenberg AT, Gouws E. Skin-epidural distance in children. *Anaesthesia* 1995; **50**:895-897.

Bosenberg AT, Raw R, Boezaart AP. Surface mapping of peripheral nerves in children with a nerve stimulator. *Paediatr Anaesth* 2002; **12(5)**:398-403.

Bosenberg AT. Coiled epidural catheter – a source of frustration (letter). *Anaesthesia* 1994; **49**:832.

Bosenberg AT. Epidural analgesia for major neonatal surgery. *Paediatr Anaesth* 1998; **8**:479-483.

Bosenberg AT. Lower limb blocks in children using unsheathed needles and a nerve stimulator. *Anaesthesia* 1995; **50**:206-210.

Bramwell RGB, Bullen C, Redford P. Caudal block for post-operative analgesia in children. *Anaesthesia* 1982; **5**:1024-1028.

Brian S, Richard B, Vincent C, Brian S, John G, Michael B, *et al*. Artifacts and pitfall errors associated with ultrasound guided regional anaesthesia. Part 1: Understanding the basic principles of ultrasound physics and machine operations. *Reg Anaesth Pain Med* 2007; **23**:412-418.

Broadbent CR, Maxwell WB, Ferrie R *et al*. Ability of Anesthetists to identify a marked lumbar interspace. *Anaesthesia* **55**:1122-6, 2000

Broadman LM, Hannallah RS, Norden RS, McGill WA. 'Kiddie Caudals', experience with 1154 consecutive cases without complications. *Anesth Analg* 1987; **66**:S18.

Broadman LM. Regional anesthesia for the pediatric outpatient. *Anesthesiology* 1987; **5**:53-72.

Bromage PR. Physiology and pharmacology of epidural analgesia. *Anesthesiology* 1967; **28**:592-622.

Brown DL. Brachial plexus anesthesia: An Analysis of options. *Yale J Biol Med* 1993; **66**:415-431.

Brown RA: Unassisted Peripheral Nerve Blocks. *Reg Anesth* 1993; **18**:137-138.

Brown TCK, Schulte-Steinberg O. Neural blockade for pediatric surgery. In: Cousins MJ, Bridenbaugh PO. *Neural blockade in clinical anesthesia and management of pain*. 2nd ed. Philadelphia: JB Lippincott Company, 1988:669-692.

Brown TCK. Local and regional anaesthesia in children. *Anaesthesia* 1985; **40**:407-408.

Buist RJ. A survey of the practice of regional anaesthesia. *J Royal Soc Med* 1990; **83**:709-712.

Busoni P, Andreuccetti T. The spread of caudal analgesia in children: a Mathematical model. *Anaesth Intens Care* 1986; **14**:140-144.

Cahill JL, Talbert JL, Otteson OE, Rowe RD, Haller AJ. Arterial complications following cardiac catheterization in infants and children. *J Pediatr Surg* 1967; **2**:134.

Campbell MF. Caudal anesthesia in children. *Am J Urol* 1933; **30**:245 [Abstract].

Carré P, Mollet J, Le Poutel S, Costey G, Ecoffey C. Ilio-inguinal Ilio-hypogastric nerve block with a single puncture: an alternative for anesthesia in emergency inguinal surgery [Abstract]. *Ann Fr Anesth Reanim* 2001; **20(7)**:643-646.

Carron H, Korbon GA, Rowlingson JC. *Regional Anesthesia: Techniques and Clinical Application*. Orlando: Grune and Stratton, Inc. 1984.

Cathelin F. A new route of spinal injection: a method of epidural injections by way of the sacral canal: application to man. *Current Reports of the Society of Biology* (Paris) 1901; **53**:452-455 [Abstract].

Chatlin BE, Barton ED. Pilonidal Cyst. *Emedicine Journal*; 2001 [cited November 2003]. Available from: URL: <http://www.emedicine.com/aaem/topic350.htm>.

Chayan D, Nathan H, Chayan M. The psoas compartment block. *Anaesthesiology* 1976; **45(1)**:95-99.

Choi JB, Hong JY, Kim JS, Kil HK. Estimating lumbar epidural space depth in infants and children of Korea. *Korean J Anesthesiol* 2009; **56(5)**:531-534 [Abstract]

Claudio R. Infraclavicular brachial plexus nerve block. *NYSORA article* 2009 [cited 26 May 2009] Available from URL: <http://www.nysora.com/peripheral-nerve-blocks/nerve-stimulator-techniques/3099-Infraclavicular-Brachial-Plexus-Nerve-Block.html>.

Clayton ML, Turner DA. Upper arm block anesthesia on children with fracture. *JAMA* 1959; **169**:327-329.

Clergue F, Auroy Y, Pequignot F, Jouglu E, Lienhart A, Laxenaire MC. French survey of anesthesia in 1996. *Anesthesiology* 1999; **91**:1509-1520.

- Cook B, Grubb DJ, Aldridge LA, Doyle E. Comparison of the effects of adrenaline, clonidine and ketamine on the duration of caudal analgesia produced by bupivacaine in children. *Br J Anaesth* 1995; **75**:698-701.
- Cork RC, Kryc JJ, Vaughan RW. Ultrasonic localization of the lumbar epidural space. *Anaesthesiology* **52**:513-16, 1980
- Craven J. Anatomy relevant to epidural and subarachnoid blockade. *Anaesth Intensive Care Med* 2004; **5(5)**:147-149.
- Crews JC, Gerancher JC, Weller RS. Pneumothorax after coracoid infraclavicular brachial plexus block. *Anesth Analg* 2007; **105**:275-277.
- Crighton IM, Barry BP, Hobbs GJ. A study of the anatomy of the caudal space using magnetic resonance imaging. *Br J Anaesth* 1997; **78**:391–395.
- Cross GD, Barrett RF. Comparison of two regional techniques for postoperative analgesia in children following herniotomy and orchidopexy. *Anaesthesia* 1987; **42**:845-849.
- Dadure C, Capdevila X. Continuous peripheral nerve blocks in children. *Best Pract Res Clin Anaesth* 2005; **19(2)**: 309–321.
- Dadure C, Raux O, Troncin R, Rochette A, Capdevila X. Continuous infraclavicular brachial plexus block for acute pain management in children. *Anesth Analg* 2003; **97**:691-693.
- Dahl JB, Christiansen CL, Daugaard JJ, Schultz P, Carlsson P. Continuous blockade of the lumbar plexus after knee surgery--postoperative analgesia and bupivacaine plasma concentrations. A controlled clinical trial. *Anaesthesia* 1988; **43(12)**: 1015-1018.

Dalens B, Hasnaoui A. Caudal anesthesia in pediatric surgery: success rate and adverse effects in 750 consecutive patients. *Anesth Analg* 1989; **68**:83-39.

Dalens B. Lower extremity nerve blocks in pediatric patients. *Tech Reg Anesth Pain Manage* 2003; **7(1)**:32-47.

Dalens B. Regional anesthetic techniques. In: Bissonnette B, Dalens B (eds.). *Pediatric Anesthesia: Principles and Practice*. New York: McGraw-Hill 2002:528-575.

Dalens B. Upper extremity nerve blocks in pediatric patients. *Tech Reg Anesth Pain Manag* 2003; **7(1)**:87-95.

Dalens BJ (ed.). *Regional Anesthesia in Infants, Children, and Adolescents*. London: Williams & Wilkens, 1995.

Dalens BJ, Bazin JE, Haberer JP. Epidural bubbles as a cause of incomplete analgesia during epidural anesthesia. *Anesth Analg* 1987; **66**:679-683.

Dalens BJ, Mansoor O. Safe selection and performance of regional anaesthetic techniques in children. *Curr Opin Anaesth* 1994; **7**:257-261.

Dalens BJ, Vanneuville G, Tanguy A. Comparison of the fascia iliaca compartment block with the 3-in-1 block in children. *Anesth Analg* 1989; **69**:705-713.

Dalens BJ. 'Small blocks' in paediatric patients. *Baillieres Best Pract Res Clin Anaesth* 2000; **14(4)**:745-758.

- Dalens BJ. Caudal anesthesia. In: Dalens BJ (ed.). *Regional Anesthesia in Infants, Children, and Adolescents*. London: Williams & Wilkens, 1995:171-192.
- Dalens BJ. Lumbar epidural anesthesia. In: Dalens BJ (ed.). *Regional Anesthesia in Infants, Children, and Adolescents*. London: Williams & Wilkens, 1995:207-248.
- Dalens BJ. Nerve blocks of the trunk. In: Dalens BJ (ed.). *Regional Anesthesia in Infants, Children, and Adolescents*. London: Williams & Wilkens, 1995:476-479.
- Dalens BJ. Pediatric regional anesthesia: The appropriate materials. *Tech Reg Anesth Pain Manag* 1999; **3(3)**:146-149.
- Dalens BJ. Proximal blocks of the upper extremity. In: Dalens BJ (ed.). *Regional Anesthesia in Infants, Children, and Adolescents*. London: Williams & Wilkens, 1995:275-312.
- De Andrés J, Alonso-Iñigo JM, Sala-Blanch X, Reina MA. Nerve stimulation in regional anesthesia: theory and practice. *Best Pract Res Clin Anaesthesiol* 2005, **19(2)**:153-174.
- De Jose Maria B, Tielens LK. Vertical infraclavicular brachial plexus block in children: a preliminary study. *Paediatr Anaesth* 2004; **14**:931-935.
- Deleuze A, Gentili ME, Marret E, Lamonerie L, Bonnet F. A comparison of a single-stimulation lateral infraclavicular plexus block with triple stimulation axillary block. *Reg Anesth Pain Med* 2003; **28(2)**:89-94.
- Delleur MM. Continuous lumbar epidural block. In: Saint-Maurice C, Schulte Steinberg O (eds.). *Regional Anaesthesia in Children*. Norwalk, Connecticut: Appleton & Lange/Mediglobe, 1990:106-109

Demiryürek D, Aydingöz Ü, Akşit MD, Yener N, Geyik PO. MR imaging determination of the normal level of conus medullaris. *J Clin Imag* 2002; **26**:375-377.

Denton JS, Manning MP. Femoral nerve block for femoral shaft fractures in children: brief report. *J Bone Joint Surg Br* 1988; **70(1)**:84.

Desparment J, Meistelman C, Barre J, Saint-Maurice C. Continuous epidural infusion of bupivacaine for postoperative pain relief in children. *Anesthesiology* 1987; **67**:108-110.

Desparment J. Total spinal anesthesia after caudal anesthesia in an infant. *Anesth Analg* 1990; **70**:665-667.

Desroches J. The infraclavicular brachial plexus block by the coracoid approach is clinically effective: an observational study of 150 patients. *Can J Anesth* 2003; **50(3)**:253-257.

Dias Filho LC, Valenca MM, Guimaraes Filho FA: Lateral femoral cutaneous neuralgia: an anatomical insight. *Clin Anat* 2003 **16**:309-316.

DiGiovanni AJ. Inadvertent intraosseous injection- a hazard of caudal anesthesia. *Anesthesiology* 1971; **34**:92-94.

Dogliotti AM. A new method of block anesthesia: segmental peridural spinal anesthesia. *Am J Surg* 1933; **20**:107-111.

Drake RL, Vogl AW, Mitchell AWM (eds.). *Gray's Anatomy for Students* (2nd ed.). Philadelphia: Churchill Livingstone 2010.

Duffy GP. Lumbar puncture in the presence of raised intracranial pressure. *Br J Anaesth* 1969; **1**:407-409.

Dullenkopf A, Blumenthal S, Theodorou P, Roos J, Perchak H, Borgeat A. Diaphragmatic excursion and respiratory function after the modified raj technique of the infraclavicular plexus block. *Reg Anesth Pain Med* 2004; **29**:110-114.

Dunbar SF, Barnes PD, Tarbell NJ. Radiologic determination of the caudal border of the spinal field in cranial spinal irradiation. *Int J Radiat Oncol Biol Phys* 1993; **26**:669–673.

Eather KF. Regional anesthesia for infants and children. *Int Anesthesiol Clin* 1975; **13**:19-48.

Ecoffey C, Dubousset A-M, Samii K. Lumbar and thoracic epidural anesthesia for urologic and upper abdominal surgery in infants and children. *Anaesthesiology* 1986; **65**:87-90.

Ecoffey C, McIlvaine WB. Technique of Regional Anaesthesia in Children. In: Raj PP (ed.). *Clinical Practice of Regional Anaesthesia*. New York: Churchill Livingstone 1991:365-388.

Edwards ND, Wright EM. Continuous low-dose 3-in-1 nerve blockade for postoperative pain relief after total knee replacement. *Anesth Analg* 1992; **75(2)**: 265-7.

Eichenberger U, Greher M, Kirchmair L, Curatolo M, Moriggl B. Ultrasound-guided blocks of the ilioinguinal and iliohypogastric nerve: accuracy of a selective new technique confirmed by anatomical dissection. *Br J Anaesth* 2006; **97**:238-243.

Electrical nerve stimulation [cited 19 January 2009]: Available from: URL: http://www.nerveblocks.net/tutorium/?lang=en_EN§ion=document&main=1&sub=2.

Eledjam J-J, Viel E, Ripart J. Contraindications for peripheral blocks. In: van Zundert A. (ed). *Highlights in Regional Anaesthesia and Pain Therapy*. IX. Cyprus: Cyprint Ltd. 2000:266-274.

Ellis H, Feldman S. Peripheral nerves. In: Ellis H, Feldman S (eds.). *Anatomy for the Anaesthetists* (6th ed.). Blackwell Scientific Publications 1993:156-202.

Ellis, H. *Clinical Anatomy: A revision and applied anatomy for clinical students* (9th ed.). United Kingdom: Blackwell Science, 1997.

Etherington-Wilson W. Spinal anesthesia in the very young and further observations. *Proc Roy Soc Med* 1944; **38**:109-115.

Farr RE. Local anesthesia in infancy and childhood. *Arch Pediatr* 1920; **37**:381 [Abstract].

Finlayson BJ, Underhill TJ, Femoral nerve block for analgesia in fractures of the femoral neck. *Arch Emerg Med* 1988; **5**:173-176.

Finucane BT. Complications of brachial plexus anaesthesia. In: Finucane BT (ed.). *Complications of Regional Anaesthesia*. New York: Churchill Livingstone. 1999:56-76.

Fisher P, Wilson SE, Brown M, Ditunno T. Continuous infraclavicular brachial plexus block in a child. *Paediatr Anaesth* 2006; **16**:884-886.

Fiutek E, Fiutek Z. Regional femoral nerve block combined with local anaesthesia in day surgery for varicose veins. *Eur J Vasc Endovasc Surg* 2008; **36(6)**: 748-748.

Flandin-Bléty C, Barrier G. Accidents following extradural analgesia in children. The results of a retrospective study. *Paediatr Anaesth* 1995; **5**: 41-46.

Fleischmann E, Marhofer P, Greher M, Walzl B, Sitzwohl C, Kapral S. Brachial plexus anaesthesia in children: lateral infraclavicular vs. axillary approach. *Paediatr Anaesth* 2003; **13**:103-108.

Fortuna A, de Oliveira Fortuna A. The history of paediatric anaesthesia. *Bailliere's Best Pract Res Clin Anaesth* 2000; **14(4)**:625-639.

Fortuna A. Bloqueios anestésicos. *Revista Brasileira de Anestesiologia* 1963; **13**:227-326 [Abstract].

Fortuna A. Caudal analgesia: A simple and safe technique in paediatric surgery. *Br J Anaesth* 1967; **39**:165-170.

Furness G, Reilly MP, Kuchi S. An evaluation of ultrasound imaging for identification of lumbar intervertebral level. *Anaesthesia* 2002; **57**:277-280.

Gaertner E, Estebe J-P, Zamfir A, Cuby C, Macaire P. Infraclavicular plexus block: multiple injection versus single injection. *Reg Anesth Pain Med* 2002; **27(6)**:590-594.

Genteli ME, Deleuze A, Estèbe J-P, Lebourg M, Exoffey C. Severe respiratory failure after infraclavicular block with 0.75% ropivacaine: A case report. *J Clin Anesth* 2002; **14**:459-461.

Ger R. Basic Surgical Training 4: American and British scenes compared. *Clin Anat* 1996; **9**:175-182.

- Giaufre E, Dalens B, Gombert A. Epidemiology and morbidity of regional anesthesia in children: A one-year prospective survey of the French-language society of pediatric anesthesiologists. *Anesth Analg* 1996; **83**:904-912.
- Gingrich TF. Spinal epidural hematoma following continuous epidural anaesthesia. *Anaesthesiology* 1968; **29**:162-163.
- Goranson BD, Lang S, Cassidy JD, Dust WN, McKerrell J. A comparison of three regional anaesthesia techniques for outpatient knee arthroscopy. *Can J Anaesth* 1997; **44(4)**: 371- 376.
- Govender S, Charles RW, Haffeejee MR. Level of termination of the normal and abnormal fetal spinal cord during development *SAMJ* 1989; **75**:484-487.
- Grau T, Leipold RW, Horter J, Conradi R, Martin EO, Motsch J. Paramedian access to the epidural space: The optimum window for ultrasound imaging. *J Clin Anesth* 2001; **13**:213-217.
- Gray AT, Collins AB, Schafhalter-Zoppoth I. An introduction to femoral nerve and associated lumbar plexus nerve blocks under ultrasonic guidance. *Tech Reg Anesth Pain Manage* 2004; **8**:155–163.
- Greher M, Retzl G, Niel P, Kamolz L, Marhofer P, Kapral S. Ultrasonographic assessment of topographic anatomy in volunteers suggests a modification of the infraclavicular vertical brachial plexus block. *Br J Anaesth* 2002; **88**:632-636.
- Grossi P, Coluccia R, Tassi A, Indrizzi VL, Gazzotti F. The infraclavicular brachial plexus block. *Tech Reg Anesth Pain Manag* 1999; **3**:217-221.

Gruber H, Peer S, Kovacs P: The ultrasonographic appearance of the femoral nerve and cases of iatrogenic impairment. *J Ultrasound Med* 2003; **22**:163-172.

Gunter J. Caudal anesthesia in children: a survey. *Anesthesiology* 1991; **75**:936.

Hadzic A, Arliss J, Kerimoglu B, Karaca PE, Yufa M, Claudio RE, Vloka JD, Rosenquist R, Santos AC, Thys DM. A comparison of infraclavicular nerve block versus general anesthesia for hand and wrist day-case surgeries. *Anesthesiology* 2004; **101**:127-132.

Hadzic A, Vloka JD, Claudio RE, Hadzic N, Thys DM, Santos AC. Electrical nerve localization: effects of cutaneous electrode placement and duration of the stimulus on motor response. *Anesthesiology* 2004; **100**:1526-1530.

Hadzic A, Vloka JD: Peripheral nerve stimulator for unassisted nerve blockade. *Anesthesiology* 1996; **84**:1528-1529.

Hannallah RS, Broadman LM, Belman AB, Abramowitz MD, Epstein BS. Comparison of caudal and ilioinguinal/iliohypogastric nerve blocks for control of post-orchiopexy pain in pediatric ambulatory surgery. *Anesthesiology* 1987; **66**:832-834.

Hansasuta A, Tubbs RS, Oakes WJ. Filum terminal fusion and dural sac termination: study in 27 cadavers. *Pediatr Neurosurg* 1999; **30**:176-179.

Haro F, Rodríguez J, De Andres J. Alternatives to the vertical approach for infraclavicular brachial plexus block. *Tech Reg Anesth Pain Manag* 2003; **7**:72-80.

Hasan MA, Howard RF, Lloyd Thomas AR. Depth of epidural space in children. *Anaesthesia* 1994; **49**:1085-1087.

Hassan SZ. Caudal anesthesia in infants. *Anesth Analg* 1977; **56**:686-689.

Hawass ND, El-Badawi MG, Fatani JA, Meshari AA, Abbas FS, Edrees YB, Jabbar FA, Banna M. Myelographic study of the spinal cord ascent during fetal development. *Am J Neuroradiology* 1987; **8**:691-695.

Heckman MM. Whitesides TE Jr. Grewe SR. Rooks MD. Compartment pressure in association with closed tibial fractures. The relationship between tissue pressure, compartment, and the distance from the site of the fracture. *J Bone Joint Surg Am* 1994;**76(9)**:1285-1292.

Heid FM, Jage J, Guth M, Bauwe N, Brambrink AM. Efficacy of vertical infraclavicular plexus bloc vs. modified axillary plexus block: a postoperative, randomized, observer-blind study. *Acta Anaesthesiol Scan* 2005; **49**:677-682.

Helperin SW, Cohen DD. Hematoma following epidural anaesthesia: Report of a case. *Anesthesiology* 1971; **35**:641-644.

Hilt H, Gramm HJ, Link J. Changes in intracranial pressure associated with extradural anaesthesia. *Br J Anaesth* 1986; **58**:676-680.

Hinkle AJ. Percutaneous inguinal block for the outpatient management of post-herniorrhaphy pain in children. *Anesthesiology* 1987; **67(3)**:411-413.

Hirschel G. Anesthesia of the brachial plexus for operations on the upper extremity. *München Med Wochenschr* 1911; **58**:1555–1556 [Abstract].

Hogan QH. Anatomy for the regionalist [cited 18 May 2009]. Available from: URL: http://www.csaol.cn/img/2007asa/RCL_src/306_Hogan.pdf.

Hogan QH. Lumbar epidural anatomy: a new look by cryomicrotome section. *Anaesthesiology* 1991; **75**:767-775.

Ivins FA. Accuracy of placement of extradural needles in the L3/4 interspace: comparison of two methods of identifying L4. *Br J Anaesth* 1991; **66**:381-382.

Illiasch H, Likar R, Stanton-Hicks M. CT use in pain management. *Tech Reg Anesth Pain Manag* 2007; **11**:103-112.

Ivani G, Conio G, Papurel F, Ciliberto F, Vitale P. Central blocks in children. In: van Zundert A. (ed). *Highlights in Regional Anaesthesia and Pain Therapy*. IX.. Cyprus: Cyprint Ltd. 2000: 194-199.

Jagannathan N, Suresh S. Truncal blocks in children. *Tech Reg Anesth Pain Manag* 2007; **11**:260-264.

Jandard C, Gentili ME, Girard F, Ecoffey C, Heck M, Laxenaire MC, Bouaziz H. Infraclavicular block with lateral approach and nerve stimulation: extent of anesthesia and adverse effects. *Reg Anesth Pain Med* 2002; **27(1)**:37-42.

Jankovic D, Wells C (eds.). *Regional Nerve Blocks* (2nd ed.). Vienna: Blackwell Science Berlin, 2001.

Jankovic D, Wells C. Blocking individual nerves in the lumbar plexus. In: Jankovic D, Wells C (eds.). *Regional Nerve Blocks* (2nd ed.). Vienna: Blackwell Science Berlin, 2001:167-169.

Jankovic D, Wells C. Brachial plexus. In: Jankovic D, Wells C (eds.). *Regional Nerve Blocks* (2nd ed.). Vienna: Blackwell Science Berlin, 2001:76-77.

- Johnson CM. Continuous femoral nerve blockade for analgesia in children with femoral fractures. *Anaesth Intens Care* 1994; **22**: 281-283.
- Jöhr M, Sossai R. Colonic puncture during ilioinguinal nerve block in a child. *Anesth Anal* 1999; **88**:1051-1052.
- Jöhr M. A complication of continuous blockade of the femoral nerve. *Reg Anaesth* 1987; **10**:37-38 [Abstract].
- Jones FW (ed.). Buchanan's Manual of Anatomy (7th ed.). London: Baillière, Tindall and Cox, 1946.
- Jones SE, Smith BA. Anesthesia for pediatric day-surgery. *J Pediatr Surg* 1980;**15**:31-34.
- Kapitanyan R, Su M. Toxicity, local anesthetics. *Emedicine Journal*; June 10, 2001 [cited February 2010]. Available from: URL: <http://www.emedicine.com/article/819628-overview>.
- Kapral S, Jandrasits O, Aram L, Weinstabl C, Mayer N. Lateral infraclavicular block: A new technique for regional anaesthesia of the brachial plexus. *Anesthesiology* 1996; **85(3A)**:A738.
- Kapral S, Jandrasits O, Schabernig C, Likar R, Reddy N, Mayer N, Weinstabl C. Lateral infraclavicular plexus block vs. axillary block for hand and forearm surgery. *Acta Anaesthesiol Scan* 1999; **43**:1047-1052.
- Katz J. *Atlas of Regional Anaesthesia*. 2nd ed. London: Prentice-Hall International Inc., 1993.
- Katz J. Brachial plexus block. In: Katz J. (ed.). *Atlas of Regional Anaesthesia*. (2nd ed.). London: Prentice-Hall International Inc., 1993.

Katz J. Femoral nerve block. In: Katz J (ed.). *Atlas of Regional Anaesthesia*. (2nd ed.). London: Prentice-Hall International Inc., 1993:224-225.

Kay B. Caudal block for post-operative pain relief in children. *Anaesthesia* 1974; **29**:610-611.

Keschner MT, Michelsen H, Rosenberg AD, Wambold D, Albert DB, Altman R, Green S, Posner M. Safety and efficacy of the infraclavicular nerve block performed at low current. *Pain Prac* 2006; **6**:107-111. [Abstract]

Kester Brown TC, Schulte-Steinberg O. Neural blockade for pediatric surgery. In: Cousins MJ, Bridenbaugh PO (eds.). *Neural Blockade in Clinical Anesthesia and Management of Pain* (2nd ed.). Philadelphia: JB Lippincott Company 1980:669-692.

Kester Brown TC. Blocks of the lower limb. In: Saint-Maurice C, Schulte Steinberg O. *Regional Anaesthesia in Children*. Norwalk, Connecticut: Appleton & Lange/Mediglobe, 1990:139-148.

Kilka HG, Geiger P, Mehrkens HH. Infraclavicular vertical brachial plexus blockade. A new method for anesthesia of the upper extremity. An anatomical and clinical study. *Anaesthetist* 1995; **44**:339-344 [Abstract].

Kim J, Jung C, Lee J, Min S, Bahk J. Influence of lumbar flexion on the position of the intercrestal line. *Reg Anesth Pain Med* 2003; **28**:509-511.

Kim S. Pediatric epidural and caudal analgesia and anesthesia in Children. *NYSORA article* 2009 [cited 18 May 2009] Available from: URL: http://nysora.com/regional_anesthesia/sub-specialties/pediatric_anesthesia/3087-pediatric_epidural_and_caudal_analgesia_and_anesthesia_in_childr.html.

- Kim S. Ultrasound-guided peripheral nerve blocks in children. *NYSORA article* 2009 [cited 18 May 2009]. Available from: URL: http://nysora.com/regional_anesthesia/sub-specialties/pediatric_anesthesia/3083-ultrasound-guided_pnbs_in_children.html.
- Koch J, Nielsen JU. Rare misplacements of epidural catheters. *Anesthesiology* 1986; **65**:556-557.
- Kopacz DJ, Neal JM, Pollock JE. The regional anaesthesia “learning curve”: What is the minimum number of epidural and spinal blocks to reach consistency? *Reg Anesth* 1996; **21**:182-190.
- Koscielniak-Nielsen ZJ, Nielsen P, Mortensen CR. A comparison of coracoid and axillary approaches to the brachial plexus. *Acta Anaesthesiol Scan* 2000; **44**:274-279.
- Kost-Byerly S, Tobin JR, Greenberg RS, Billett C, Zahurak M, Yaster M. Bacterial colonization and infection rate of continuous epidural infusions in children. *Anesth Analg* 1998; **86**:712-716.
- Kost-Byerly S. Update in acute pain management in children. *Tech Reg Anesth Pain Manag* 2003; **7(3)**:166-171.
- Krane EJ, Dalens BJ, Murat I, Murell D. The safety of epidural placed under general anaesthesia. Editorial. *Regional Anes Pain Med* 1998; **23**:433-438.
- Krane EJ, Dalens BJ, Murat I, Murrell D. The safety of epidurals placed during general anesthesia. *Reg Anesth Pain Med* 1998; **23(5)**:433-438.
- Kulenkampff D, Persky MA. Brachial plexus anaesthesia. *Ann Surg* 1928; **87**:883-891.

- Laman EN, McLeskey CH. Supraclavicular subcutaneous emphysema following lumbar epidural anesthesia. *Anesthesiology* 1978; **48(3)**:219-221.
- Lanz E, Theiss D, Jankovic D. The extent of blockade following various techniques of brachial plexus block. *Anesth Analg* 1983; **62**:55-58.
- Larsen JL, Olsen KO. Radiographic anatomy of the distal dural sac. A myelographic investigation of dimensions and termination. *Acta Radiol* 1991; **32**:214–219.
- Lau ST, Lee Y-H, Caty MG. Current management of hernias and hydroceles. *Semin Pediatr Surg* 2007; **16**:50-57.
- Lennon RL, Linstromberg JW. Brachial plexus anesthesia and axillary sheath elastance. *Anesth Analg* 1983; **62**:215-217.
- Letts RM. Congenital spinal deformity. *Emedicine Journal*; April 16, 2001 [cited June 2004]. Available from: URL: <http://www.emedicine.com/orthoped/topic618.htm>.
- Lewis MPN, Thomas P, Wilson LF, Mulholland RC. The ‘whoosh’ test: a clinical test to confirm correct needle placement in caudal epidural injections. *Anaesthesia* 1992; **47**: 57–58.
- Lim SL, Ng Sb A, Tan GM. Ilioinguinal and iliohypogastric nerve block revisited: single shot versus double shot technique for hernia repair in children. *Paediatr Anaesth* 2002; **12**:255-260.
- Lipp A, Woodcock J, Hensman B, Wilkinson K. What is the incidence of leg weakness after ilio-inguinal block in children? *Paed Anaesth* 2000; **10(6)**: 687-8.

Lloyd-Thomas AR. Pain management in paediatric patients. *Br J Anaesth* 1990; **64**:85-104.

Löfström B, Engleson S. Nerve block of the region of the hip-joint. In: Eriksson E (ed.). *Illustrated Handbook in Local Anesthesia*. Philadelphia: WB Saunders, 1979:101-110.

Lourey CJ, McDonald IM. Caudal anaesthesia in infants and children. *Anaesth Intensive Care* 1973; **1**:547-548.

Lunn JN. Postoperative analgesia after circumcision: a randomised comparison between caudal analgesia and intramuscular buprenorphine. *Anaesthesia* 1979; **34**:552-554.

Luyendijk W. The plica mediana dorsalis of the dura mater and its relation to the lumbar periurography (canalgraphy). *Neuroradiology* 1976; **11**:147-149.

Lynch J, Trojan S, Arhelger S, Krings-Ernst I. Intermittent femoral nerve blockade for anterior cruciate ligament repair. Use of a catheter technique in 208 patients. *Acta Anaesthesiol Belg* 1991; **42(4)**: 207-212.

Maccani RM, Wedel DJ, Melton A, Gronert GA. Femoral and lateral femoral cutaneous nerve block for muscle biopsies in children. *Paediatr Anaesth* 1995; **5(4)**:223-227.

MacDonald A, Chatrath P, Spector T, Ellis H. Level of termination of the spinal cord and dural sac: a magnetic resonance study. *Clin Anat* 1999; **12**:149-152.

Mak PH, Irwin MG, Ooi CG, Chow BF. Incidence of diaphragmatic paralysis following supraclavicular brachial plexus block and its effect on pulmonary function. *Anaesthesia* 2001; **56**:352-356.

Malas MA, Seker M, Salbacak A, Büyükmumcu M, Karabulut AK, Yardımcı C. The relationship between the lumbosacral enlargement and the conus medullaris during the period of fetal development and adulthood. *Surg Radiol Anat* 2000; **22**:163– 168.

Marhofer P, Greher M, Kapral S. Ultrasound guidance in regional anaesthesia. *Br J Anaesth* 2005; **94(1)**:7-17.

Marhofer P, Schrogendorfer K, Koinig H, Kapral S, Weinstabl C, Mayer N. Ultrasonographic guidance improves sensory block and onset time of three-in-one blocks. *Anesth Analg* 1997; **85**:854-857.

Marhofer P, Sitzwohl C, Greher M, Kapral S. Ultrasound guidance for infraclavicular brachial plexus anaesthesia in children. *Anaesthesia* 2004; **59**:642-646.

Marian J. Die Rachianaesthesia im Kindesalter. *Zentralblatt für Chirurgie* 1932; **59**:1852-1857 [Abstract].

Markakis DA. Regional anaesthesia in paediatrics. *Anesth Clin North Am* 2000; **18(2)**:355-381.

Markham SJ, Tomlinson J, Hain WR. Iliioinguinal nerve block in children - a comparison with caudal block for intra and postoperative analgesia. *Anaesthesia* 1986; **41**:1098-1103.

Martin LVH. Postoperative analgesia after circumcision in children. *Br J Anaesth* 1982; **54**:1263-1266.

- Massey Dawkins CJ. An analysis of the complications of extradural and caudal blocks. *Anaesthesia* 1969; **24**:554-563.
- Maxwell LG, Yaster M, Wetzel RC, Niebyl JR. Penile nerve block for newborn circumcision. *Obstet Gyn* 1987; **70(3-1)**:415-418.
- May AE, Wandless J, James RH. Analgesia for circumcision in children: A comparison of caudal bupivacaine and intramuscular buprenorphine. *Acta Anaesth Scand* 1982; **26**:331-333.
- McClain BC, Redd SA: Barrier flaps for continuous caudal anesthesia in pediatric patients. *Anesthesiology* **79**:400-401, 1993
- McCormack JG, Malherbe S. Applications of ultrasound in paediatric anaesthesia, *Curr Anaesth Crit Care* 2008; **19**:302-308.
- McGown RG. Accidental marrow sampling during caudal anaesthesia. *Br J Anaesth* 1972; **44**:613-615.
- McGown RG. Caudal analgesia in children. Five hundred cases for procedures below the diaphragm. *Anaesthesia* 1982; **37**: 806-818.
- McIntyre JWR. Regional anaesthesia safety. In: Finucane BT (ed.). *Complications of Regional Anaesthesia*. New York: Churchill Livingstone, 1999:1-30.
- McNicol LR. Lower limb blocks for children: Lateral cutaneous and femoral nerve blocks for postoperative pain and relief in paediatric practice. *Anaesthesia* 1986; **41**:27-31.
- Meignier M, Souron R, Le Neel JC. Postoperative dorsal epidural analgesia in the child with respiratory disabilities. *Anesthesiology* 1983; **59**:473-475.

Meikeljohn BH. The effect of rotation of an epidural needle. *Anaesthesia* 1987; **42**:1180-1182.

Melman E, Oenuelas J, Marrufo J. Regional anesthesia in children. *Anesth Analg*; 1975 **54**:387-390.

Merguerian PA, Sutters KA, Tang E, Kaji D, Chang B. Efficacy of continuous epidural analgesia versus single dose caudal analgesia in children after intravesical ureteroneocystostomy. *J Urol* 2004; **172**:1621-1625.

Minville V, N'Guyen L, Chassery C, Zetlaoui, Pourrut J-C, Gris C, Eychennes B, Benhamou D, Samii K. A modified coracoid approach to infraclavicular brachial plexus block using a double-stimulation technique in 300 patients. *Anesth Analg* 2005; **100**:263-265.

Montes FR, Zarate E, Grueso R, Giraldo JC, Venegas MP, Gomez A, Rincón JD, Hernandez M, Cabrera M. Comparison of spinal anesthesia with combined sciatic-femoral nerve block for outpatient knee arthroscopy. *J Clin Anesth* 2008; **20**:415–420.

Montgomery SJ, Raj PP, Nettles D, Jenkins MT. The use of the nerve stimulator with standard unsheathed needles in nerve blockade. *Anesth Analg* 1973; **52**: 827-31.

Mukherji SK, Wagle A, Armao DM, Dogra S. Brachial plexus nerve block with CT guidance for regional pain management: Initial results. *Radiology* 2000; **216**:886-890.

Murrell D, Gibson PR, Cohen RC. Continuous epidural analgesia in newborn infants undergoing major surgery. *J Paediatr Surg* 1993; **28**:548-553.

Naguib M, Magboul MM, Samarkandi AH, Attia M. Adverse effects and drug interactions associated with local and regional anaesthesia. *Drug Saf* 1998; **18**:221-250.

Needles JH. The caudal level of termination of the spinal cord in American whites and American Negroes. *Anat Rec* 1935; **63**:417–424 [Abstract].

Nielsen KC, Klein SM, Steele SM. Femoral nerve blocks. *Tech Reg Anesth Pain Manage* 2003; **7(1)**:8-17.

Nolte W. Ilioinguinal nerve block. In: Hoerster W, Kreuzer H, Chr. Niesel H, Zenz M (eds.). *Regional Anaesthesia* (2nd ed.). St. Louis: Mosby-Year Book, Inc. 1990:277-279.

Nunn G, MacKinnon RPG. Two unilateral epidural blocks. *Anaesthesia* 1986; **41**:439-440.

Oberndorfer U, Marhofer P, Boßenberg A, et al. Ultrasonographic guidance for sciatic and femoral nerve blocks in children. *Br J Anaesth* 2007; **98(6)**:797-801.

Office of the prime minister. Human Tissue Act, Act no 65. *Republic of South Africa Government Gazette* 1983; 1-35.

Overdiek N, Grisales DA, Gravenstein D, Bosek V, Nishman R, Modell JH. Subdural air collection: a likely source of radicular pain after lumbar epidural. *J Clin Anesth* 2001; **13(5)**:392-397.

Pages F. Anesthesia metamerica. *Revista Sanidad Militar* 1921; **11**:351-354 [Abstract].

Pait TG, Elias AJ, Tribell R. Thoracic, lumbar, and sacral spine anatomy for endoscopic surgery. *Neurosurgery* 2002; **51(5)**:67-78.

Parkin IG, Harrison GR. The topographical anatomy of the lumbar epidural space. *J Anat* 1985; **141**:211-217.

Partridge BL, Katz J, Benirschke K. Functional anatomy of the brachial plexus sheaths. *Anesthesiology* 1987; **66**:743-747.

Perlas A, Chan V. Ultrasound-Assisted Nerve Blocks. *NYSORA article* 2008 [cited 19 January 2009]: Available from: URL: http://www.nysora.com/peripheral_nerve_blocks/ultrasound-guided_techniques/3063-ultrasound_assisted_nerve_blocks.html.

Pither CE, Raj PP, Ford DJ. The use of peripheral nerve stimulators for regional anesthesia. A review of experimental characteristics, technique and clinical applications. *Reg Anesth* 1985; **10**:49-58.

Ponde VC. Continuous infraclavicular brachial plexus block: A modified technique to better secure catheter position in infants and children. *Anesth Analg* 2008; **106**:94-96.

Quinnell RC, Stockdale HR. The use of in vivo lumbar discography to assess the clinical significance of the position of the intercrestal line. *Spine* 1983; **8**:305-307.

Raj PR, Montgomery SJ, Nettles D, Jenkins MT. Infraclavicular brachial plexus block – A new approach. *Anesth. Analg* 1973; **52**:897-904.

Raj PR. Infraclavicular approach to brachial plexus anesthesia. *Reg Anesth Pain Med* 1997; **1**:169-177.

Ramamurthi RJ, Krane EJ. Local anesthetic pharmacology in pediatric anesthesia. *Tech Reg Anesth Pain Manag* 2007; **11**:229-234.

Rapp H, Grau T. Ultrasound-guided regional anesthesia in pediatric patients. *Reg Anesth Pain Manag* 2004; **8**:179-198.

Reich A, Strumper D. Lumbar and thoracic epidural anaesthesia in children. *Best Pract Res Clin Anaesth* 2000; **14(4)**:731-743.

Reid MF, Harris R, Phillips PD, Barker I, Pereira NH, Bennet NR. Day-case herniotomy in children. A comparison of ilio-inguinal nerve block and wound infiltration for postoperative analgesia. *Anaesthesia* 1987; **42**:658-661.

Render CA. The reproducibility of the iliac crest as a marker of lumbar spine level. *Anaesthesia* 1996; **51**:1070-1071.

Renshaw TS. Sacral agenesis - A classification and review of twenty-three cases. *J Bone Joint Surg Am* 1978; **60(3)**:373-383.

Reynolds F. Damage to the conus medullaris following spinal anaesthesia. *Anaesthesia* 2001; **56(3)**:238-247.

Reynolds F. Logic in the safe practice of spinal anaesthesia (editorial). *Anaesthesia* 2000; **55**:1045-1046.

Rodrigues I. A anestesia peridural no paciente pediaÂ trico. *Revista Brasileira de Anestesiologia* 1964; **14**:116-120 [Abstract].

Rodríguez J, Bárcena M, Lagunilla J, Álvarez J. Increased success rate with infraclavicular brachial plexus block using a dual-injection technique. *J Clin Anesth* 2004a; **16**:2510256.

Rodríguez J, Taboada-Muñiz M, Bárcena M, Álvarez J. Median versus musculocutaneous nerve response with single-injection infraclavicular coracoid block. *Reg Anesth Pain Med* 2004b; **29**:534-538.

Rojansky N, Fasouliotis SJ, Ariel I, Nadjari M. Extreme caudal agenesis. Possible drug-related etiology? *J Reprod Med* 2002; **47(3)**:241-245.

Ronchi L, Rosenbaum D, Athouel A, Lemaitre JL, Bermon F, de Villepoix C, Le Normand Y. Femoral nerve blockade in children using bupivacaine. *Anesthesiology* 1989; **70(4)**:622-624.

Rosario DJ, Jacob S, Luntley J, Skinner PP, Raftery AT. Mechanism of femoral nerve palsy complicating percutaneous ilioinguinal field block. *Br J Anaesth* 1997; **78**:314-316.

Rosario DJ, Skinner PP, Raftery AT. Transient femoral nerve palsy complicating preoperative ilioinguinal nerve blockade for inguinal herniorrhaphy. *Br J Surg* 1994; **81**: 897.

Rossi A, Gandolfo C, Morana G, Piatelli G, Ravegnani M, Consales A, *et al.* Current classification and imaging of congenital spinal abnormalities. *Sem Roent* 2006; **41(4)**:250-273.

Roy-Shapira A, Amoury RA, Ashcraft KW, Holder TM, Sharp RJ, Transient quadriceps paresis following local inguinal block for postoperative pain control. *J Ped Surg* 1985; **20(5)**:554-555.

Rozenberg B, Tischler S, Glick A. Abdominal subcutaneous emphysema: an unusual complication of lumbar epidural block. *Can J Anaesth* 1988; **35(3)**:325.

Russell SCS, Doyle E. Recent advances: Paediatric anaesthesia. *BMJ* 1997; **314**:201-203.

Ruston FG. Epidural anaesthesia in infants and children. *Can Anaesth Soc J* 1954; **1**:37-43.

Ruston FG. Epidural anaesthesia in paediatric surgery: present status at the Hamilton General Hospital. *Can Anaesth Soc J* 1964; **11**:12-18.

Saberski LR, Kondamuri S, Osinubi OY. Identification of the epidural space: is loss of resistance to air a safe technique? A review of the complications related to the use of air. *Reg Anesth* 1997; **22(1)**:3-15.

Sadler TW. *Langman's Medical Embryology* (10th ed.). Philadelphia: Lippencott Williams & Wilkens, 2006.

Saifuddin A, Burnett JD, White J. The variation of position of the conus medullaris in an adult population. *Spine* 1998; **23**:1452–1456.

Saint-Maurice C. Indications and limitations of regional anesthesia in pediatric practice. In: Dalens BJ (ed.). *Regional Anesthesia in Infants, Children, and Adolescents*. London: Williams & Wilkens, 1995:127-131.

Salazar CH, Espinosa W. Infraclavicular brachial plexus block: Variation in approach and results in 360 cases. *Reg Anesth Pain Med* 1999; **24(5)**:411-416.

Sandhu NS, Capan LM. Ultrasound-guided infraclavicular brachial plexus block. *Br J Anaesth* 2002; **89**:254-259.

Sandhu NS, Sidhu DS, Capan LM. The cost comparison of infraclavicular brachial plexus block by nerve stimulator and ultrasound guidance (letter to editor). *Anesth Analg* 2004; **98**:267-268.

Scheuer L, Black S. *Developmental Juvenile Osteology*. Oxford: Elsevier Academic Press, 2000.

Schulte-Steinberg O, Rahlfs VW. Caudal anaesthesia in children and spread of 1% lignocaine: a statistical study. *Br J Anaesth* 1970; **42**:1093-1099.

- Schulte-Steinberg O. Blocks of the upper limb. In: Saint-Maurice C, Schulte-Steinberg O (eds.). *Regional Anaesthesia in Children*. Norwalk, Connecticut: Appleton & Lange/Mediglobe, 1990:127-138.
- Schulte-Steinberg O. Ilioinguinal and iliohypogastric nerve block. In: Saint-Maurice C, Schulte Steinberg O (eds.). *Regional Anaesthesia in Children*. Norwalk, Connecticut: Appleton & Lange/Mediglobe, 1990:155-156.
- Schulte-Steinberg O. Regional anaesthesia for children. *Ann Chir Gynaecol* 1984; **73**:158-165.
- Schwartz N, Eisenkraft JB. Probable venous air embolism during epidural placement in the infant. *Anesth Analg* 1993; **76**:1136-1138.
- Senoglu N, Senoglu M, Oksuz H, Gumusalan Y, Yuksel KZ, Zencirci B, Ezberci M, Kizilkanat E. Landmarks of the sacral hiatus for caudal epidural block: an anatomical study. *Br J Anaesth* 2005; **95(5)**:692–695.
- Serpell MG, Millar FA, Thomson MF. Comparison of lumbar plexus block versus conventional opioid analgesia after total knee replacement. *Anaesthesia* 1991; **46(4)**: 275-277.
- Sethna NF, Berde CB. Pediatric regional anesthesia. In: Gregory GA (ed.). *Paediatric Anaesthesia*. Volume 1. 2nd ed. New York: Churchill Livingstone Inc., 1989:647-678.
- Sethna NF, Berde CB. Pediatric regional equipment. *Int Anesthesiol Clin* 1992; **30**: 163-76.
- Shandling S, Steward D. Regional analgesia for postoperative pain in pediatric outpatient surgery. *J Pediatr Surg* 1980; **15**:477-480.

- Shanks CA. Four cases of unilateral epidural analgesia. *Br J Anaesth* 1968; **40**:999-1002.
- Silva CA Jr. *Pediatric regional anesthesia* (Free Paper), ASRA 2nd International Symposium of Regional Anesthesia Williamsburg, USA, 1988.
- Sims JK. A modifications for landmarks for infraclavicular approach to the brachial plexus. *Anesth Analg* 1977; **56**:554-555.
- Singelyn FJE. Continuous peripheral nerve blocks in infants and children. *Tech Reg Anesth Pain Manage* 2002; **6**:108-114.
- Singh A. Unilateral epidural anesthesia: Case report. *Anaesthesia* 1967; **22**:147-148.
- Small GA. Brachial plexus anesthesia in children. *JAMA* 1950; **147**:1648-1651.
- Smith BAC, Jones SEF. Analgesia after herniotomy in a paediatric day unit. *BMJ* 1982; **285**:1466.
- Smith C, Green RM. Pediatric vascular injuries. *Surgery* 1981; **90(1)**:20-31.
- Spear RM, Deshpande JK, Maxwell LG. Caudal anesthesia in the high-risk infant. *Anesthesiology* 1988; **69**:407-409.
- Spiegel P. Caudal anesthesia in pediatric surgery. *Anesth Analg* 1962; **41**:218-221.
- Standring S, Ellis Hit, Healy JC *et al.* (eds.). *Gray's Anatomy: The Anatomical Basis of Clinical Practice*. Edinburgh: Elsevier, Churchill Livingstone; 2005.

- Steffen P, Seeling W, Essig A, Stiepan E, Rockemann MG. Bacterial contamination of epidural catheters: Microbiological examination of 502 epidural catheters used for postoperative analgesia. *J Clin Anesth* 2004; **16**:92-97.
- Stitz MY, Sommer HM. Accuracy of blind versus fluoroscopically guided caudal epidural injection. *Spine* 1999; **24**:1371–1376.
- Stojonovic MP. Basic pain management interventions using fluoroscopy: Targets and optimal imaging of lumbar spine. *Tech Reg Anesth Pain Manag* 2007; **11**:55-62.
- Stow PJ, Scott A, Phillips A, White JB. Plasma bupivacaine concentrations during caudal analgesia and ilioinguinal-iliohypogastric nerve block in children. *Anaesthesia* 1988; **43**:650-3.
- Striebel HW, Wilker E. Postoperative pain therapy following total endoprosthetic surgery on the hip using a continuous 3-in-1 blockade. *Anesthesiol Intensiv Med* 1993; **28(3)**: 168-173.
- Sun LS, Li G, Dimaggio C, Byrne M, Rauh V, Brooks-Gunn J, Kakavouli A, Wood A. Anesthesia and neurodevelopment in children: time for an answer? *Anesthesiology* 2008; **109(5)**:757-61. Coinvestigators of the Pediatric Anesthesia Neurodevelopment Assessment (PANDA) Research Network.
- Suraseranivongse S, Chowvanayotin S, Pirayavaraporn S, Kongsayreepong S, Gunnaleka P, Kraiprasit K, Petcharatana S, Montapaneewat T. Effect of bupivacaine with epinephrine wound instillation for pain relief after pediatric inguinal herniorrhaphy and hydrocelectomy. *Reg Anesth Pain Med* 2003; **28(1)**:24-28.
- Széll K. Local anaesthesia and inguinal hernia repair: a cautionary tale. *Ann R Coll Surg Engl* 1994; **76(2)**:139-140.

Tame SJ, Burstal R. Investigation of the radiological relationship between iliac crests, conus medullaris and vertebral level in children. *Paediatr Anaesth*. 2003; **13(8)**:676-680.

Tame SJ, Burstal R. Investigation of the radiological relationship between iliac crests, conus medullaris and vertebral level in children. *Paediatr Anaesth*. 2003; **13(8)**:676-680.

Thompson GE, Rorie DK. Functional anatomy of the brachial plexus sheaths. *Anesthesiology* 1983; **59**:117-122.

Ting PH, Antonakakis JG. Evidence-based review of ultrasound imaging for regional anesthesia. *Sem Anesth Periop Med Pain* 2007; **26**:218-228.

Tobias J: Continuous femoral nerve block to provide analgesia following femur fracture in a paediatric ICU population. *Anaesth Intensive Care* 1994; **22**:616-618.

Tobias JD, Haun SE, Helfaer M, Nichols DG. Use of continuous caudal block to relieve lower-extremity ischemia caused by vasculitis in a child with meningococemia. *J Pediatr* 1989; **115**:1019-1021.

Tobias JD. Brachial plexus anaesthesia in children. *Paediatr Anaesth* 2001; **11**:265-275.

Tondare AS, Nadkarni AV. Femoral nerve block for fractured shaft of femur. *Can Anaesth Soc J* 1982; **29(3)**: 270-271.

Trotter C, Martin P, Youngson G, Johnston G. A comparison between ilioinguinal-iliohypogastric nerve block performed by anaesthetist or surgeon for postoperative analgesia following groin surgery in children. *Paed Anaesth* 1995; **5(6)**: 363-7.

- Trotter M. Variations of the sacral canal: their significance in administration of caudal analgesia. *Anesth Analg* 1947; 26:192-197.
- Tsui BC, Tarkkila P, Gupta S, Kearney R. Confirmation of caudal needle placement using nerve stimulation. *Anesthesiology* 1999; **91**:374–378.
- Tsui BCH. Equipment for regional anesthesia in children. *Tech Reg Anesth Pain Manag* 2007; **11**:253-246.
- Tsui BCH. Innovative approaches to neuraxial blockade in children: The introduction of epidural nerve root stimulation and ultrasound guidance for epidural catheter placement. *Pain Res Manage* 2006; **11(3)**:173-180.
- Tuominen MK, Pitkänen MT, Numminen MK, Rosenberg PH. Quality of axillary brachial plexus block-comparison of success rate using perivascular and nerve stimulator techniques. *Anaesthesia* 1987; **42**:20-22.
- Tyrrel-Gray H. A study of spinal anesthesia in children and infants. *Lancet* 1909; **2**:913-917.
- Urmey WF, Talts KH, Sharrock NE. One hundred percent incidence of hemidiaphragmatic paresis associated with interscalene brachial plexus anesthesia as diagnosed by ultrasonography. *Anesth Analg* 1991; **72**:498-503.
- Usubiaga JE, Wikinski JA, Usubiaga LE. Epidural pressure and its relation to spread of anesthetic solution in epidural space. *Anesth Analg* 1967; **46**:440-446.
- Vaisman J. Pelvic hematoma after ilioinguinal nerve block for orchialgia. *Anesth Analg* 2001; **92**:1048-1049.

- Van Schoor A, Boon JM, Bosenberg AT, Abrahams PH, Meiring JH. Anatomical considerations of the paediatric ilioinguinal / iliohypogastric nerve block. *Paediatr Anaesth* 2005, **15**:371-377.
- Van Schoor A. Paediatric regional anaesthetic procedures: Clinical anatomy competence, pitfalls and complications [Masters dissertation]. Pretoria, University of Pretoria; 2004.
- Vara Lopez R. La Raquianestesia en la infancia (experiencia personal en cuatrocientos treinta y ocho casos). *Medicina Espan ola* 1942; **8**:242-250 [Abstract].
- Vater M, Wandless J. Caudal or dorsal nerve block? A comparison of two local anaesthetic techniques for postoperative analgesia following day care circumcision. *Acta Anaesthes Scand* 1985; 29:175-179.
- Visan A, Vloka JD, Koenigsamen J, Hadzic A. Peripheral nerve stimulators technology. *Tech Reg Anesth Pain Manag* 2002; **6(4)**:155-157.
- Vloka JD, Hadzic A, Drobnik L, Ernest A, Reiss W, Thys DM. Anatomical landmarks for the femoral nerve block: A comparison of four needle insertion sites. *Anesth Analg* 1999; **89**:1467-1470.
- Vloka JD, Hadzic A, Mulcare R, Lesser JB, Kitain E, Thys DM. Femoral and genitofemoral nerve blocks versus spinal anesthesia for outpatients undergoing long saphenous vein stripping surgery. *Anesth Analg* 1997; **84(4)**: 749-752.
- Vloka JD, Hadzic A, Shih H, Birnbach DJ. A national survey on practice patterns in the use of peripheral nerve stimulators in regional anesthesia. *The Internet Journal of Anesthesiology* 1999; **3(4)** [cited 19 January 2009]; Available from: URL:<http://www.ispub.com/journals/IJA/Vol3N4/pns.htm>.

- Von Bahr V. Local anesthesia for herniorrhaphy. In: Eriksson E (ed.). Illustrated Handbook in Local Anesthesia. Philadelphia: WB Saunders, 1979:52-54.
- Weber S. Caudal anesthesia complicated by interosseous injection in a patient with ankylosing spondylitis. *Anaesthesiology* 1985; 63:716-717.
- Wee L, Stokes MA. Bladder exstrophy in a neonate at risk of transient myasthenia gravis: a role of remifentanyl and epidural analgesia. *Br J Anaesth* 1999; **82**:774-776.
- Welborn LG, Ramirez N, Oh TH, Ruttimann UE, Fink R, Guzzetta P, Epstein B. Postanesthetic Apnea and Periodic Breathing in Infants. *Anesthesiology* 1986; **65**:658-661.
- Whiffler K. Coracoid block-A safe and easy technique. *Br J Anaesth* 1981; 53:845-848.
- Wilder RT. Local Anaesthetics for the paediatric patient. *Pediatr Clin North Am* 2000; **47**:545-587.
- Williams RK, McBride WJ, Abajian JC. Combined spinal and epidural anaesthesia for major abdominal surgery in infants. *Can J Anaesth* 1997; **44**:511-514.
- Willschke H, Marhofer P, Bosenberg A, Johnston S, Wanzel O, Cox SG, Sitzwohl C, Kapral S. Ultrasonography for ilioinguinal/iliohypogastric nerve blocks in children. *Br J Anaesth* 2005; **95**:226-230.
- Wilson DA, Prince JR. MR imaging determination of the location of the normal conus medullaris throughout the childhood. *AJR* 1989; **152**:1029-1032.

Wilson JL, Brown DL, Wong GY, Ehman RL, Cahill DR. Infraclavicular brachial plexus block: parasagittal anatomy important to the coracoid technique. *Anesth Analg* 1998; **87**:870-873.

Winnie AP, Ramamurthy S, Durrani Z, Radonjic R. Interscalene cervical plexus block: A single injection technique. *Anesth Analg* 1975; **54(3)**:370-375.

Winnie AP, Ramamurthy S, Durrani Z. The inguinal paravascular technic of lumbar plexus anesthesia: the "3-in-1 block". *Anesth Analg* 1973; **52(6)**:989-996.

Winnie AP. Regional anesthesia. *Surg Clin North Am* 1975; **55**:861-892.

Wolf S, Schneble F, Troger J. The conus medullaris: Time of ascendance to normal level. *Pediatr Radiol* 1992; **22(8)**:590-592.

Wood CE, Goresky GV, Klassen KA, Kuwahara B, Neil SG. Complications of continuous epidural infusions for postoperative analgesia in children. *Can J Anaesth* 1994; **41**:613-620.

Yaster M, Maxwell LG. Pediatric regional anesthesia. *Anesthesiology* 1989; **70**:324-338.

Yazigi A, Jabbour K, Jebara SM, Haddad F, Antakly MC. Bilateral ilioinguinal nerve block for ambulatory varicocele surgery. *Ann Fr Anesth Reanim* 2002; **21(9)**:710-712 [Abstract].

Yeoman PM, Cooke R, Hain WR. Penile block for circumcision?- A comparison with caudal blockade. *Anaesthesia* 1983; **38**:862-866.

Yoon JS, Sim KH, Kim SJ, Kim WS, Koh SB, Kim B. The feasibility of color Doppler ultrasonography for caudal epidural steroid injection. *Pain* 2005; **118**:210–214.

Zarzur E. Anatomic studies of the human lumbar ligamentum flavum. *Anesth Analg* 1984; **63**:499-502.

Zhan ZG. Single shot epidural anesthesia in pediatric surgery. Abstracts 108, *World Congress of Anesthesiologists*, The Hague, Netherlands, 1992; p.877.

Appendices

Appendix A: Materials required when performing a local anaesthesia or regional block in children (Dalens, 1999)

Block Procedure	Recommended Device	Alternate Device
Intradermal wheals	Intradermal needles (25 G, 25 mm long)	-
Local infiltration and field blocks	Standard IM needles (21-23 G, 25-50 mm long)	-
Compartment blocks (fascia iliaca, penile, rectus sheath, peribulbar blocks)	21-23 G short (25-50 mm) and short bevel	Epidural needles (especially Tuohy needles for intercostal block) Neonatal spinal needle
Peripheral mixed nerve blocks and plexus blocks	Insulated 21-23 G short bevel needles of appropriate length (depending on block procedure and patient's size) Nerve stimulator (0.5-1 mA)	Unsheathed needles with the same characteristics connected to a nerve stimulator (0.5-1 mA)
Spinal anaesthesia	Spinal needle (24-25 G; 30, 50 or 100 mm long, Quincke bevel, stylet)	Neonatal lumbar tap needle (22 G, 30-50 mm long) Whitacre spinal needle
Caudal anaesthesia	Short (25-30 mm) and short bevel needle with stylet	Neonatal epidural needle (intraoperative catheter insertion) Occasionally: spinal needle IV short catheter: not recommended
Epidural anaesthesia	Tuohy needle (22 G and 30 mm long, 20 G and 50 mm long, 19-18 G and 80-90 mm long); LOR syringe and medium; Epidural catheter	Crawford, Whitacre, or Sprotte epidural needles appropriately sized; LOR* syringe and medium Epidural catheter

*LOR = Loss of Resistance

Appendix B: Questionnaire used during the survey of regional anaesthetic procedures.

The questionnaire was developed after an extensive literature review and also by means of feedback obtained from anaesthesiologists who completed a pilot questionnaire while attending a regional anaesthesia workshop at the Department of Anatomy, University of Pretoria (see Table B1). This pilot study provided useful information on shaping the questionnaire. Every data-item on the questionnaire was given a numerical value for all eight questions. The data for every procedure was then entered into the Excel® statistical program.

Table B1: Example of questionnaire given to anaesthesiologists.

Questions

1. I **perform this procedure** in my practice.
2. **How many times** did you perform this procedure in the **past year?**
3. The performance of this procedure is **important in my practice situation.**
4. I feel **comfortable to perform** this procedure.
5. I find **difficulty to perform** this procedure due to the following **reason/s:** (order in level of importance)
6. I met the following **complication/s** and have the following **difficulties** when performing the procedure (number in order of frequency)
7. The improvement of **critical anatomy knowledge necessary** to perform this procedure will **reduce difficulties and complications.**
8. Improvement of **anatomy knowledge** necessary for the procedure will **increase my confidence** in performing the procedure.

	1	2	3	4	5	6	7	8	
Paediatric caudal epidural block	Yes	More than 20	Essential	Very comfortable	Knowledge of the procedure itself	Difficulty palpating landmarks for needle insertion	Injection into sacral bone marrow	Strongly agree	Strongly agree
		10-20	Desirable but not essential	Fairly comfortable	Equipment necessary for the procedure	Difficulty piercing the SC ligament	Vascular puncture	Agree	Agree
	No	5-10	Useful	Uncomfortable	Practical skills to perform the procedure	Dural puncture	Subarachnoid injection	Disagree	Disagree
		Less than 5	Not necessary	Very uncomfortable	Regional anatomy knowledge	Misplacement into soft tissue or rectum (pelvic viscera)		Strongly disagree	Strongly disagree

After an extensive search of the literature, a total of 17 paediatric regional anaesthetic procedures were selected for the survey (see Table B2).

Table B2: List of 17 paediatric regional anaesthetic procedures included in the questionnaire.

Paediatric regional anaesthetic procedures	
Neuraxial/central blocks	
1.	Caudal epidural block
2.	Spinal anaesthesia
3.	Lumbar epidural block
4.	Thoracic epidural block
Peripheral nerve blocks	
1.	Infraclavicular brachial plexus block
2.	Supraclavicular brachial plexus block
3.	Femoral nerve block
4.	Lateral femoral cutaneous nerve block
5.	“3-in-1” block
6.	Fascia iliaca block
7.	Psoas compartment block
8.	Sciatic nerve block: Anterior approach
9.	Sciatic nerve block: Posterior approach
10.	Sciatic nerve block: Lateral approach
11.	Ilio-inguinal/iliohypogastric nerve block
12.	Penile block
13.	Intercostal block

Appendix C: Results of survey into paediatric regional anaesthesia in South Africa.

Procedures were scored to best represent the selection criteria of the study, portraying a block that is performed, has anatomically related difficulties and complications associated with it, and where improvement of anatomical knowledge will make a difference in reducing difficulties and complications and increase confidence of performance. The five “problem” procedures are shown in Table C1.

Table C1: Procedures that scored the highest points, according to the scoring option.

Procedure	Score	Incidence of Performance
Femoral nerve block	9/12	22.5%
Brachial plexus block	9/12	22.5%
Caudal epidural block	8/12	63.75%
Ilio-inguinal/iliohypogastric nerve block	8/12	26.25%
Lumbar epidural block	8/12	20%

The results from the questionnaires were analysed and the importance, comfort levels and possible difficulties that an anaesthesiologist may experience when performing one of the five “problem” procedures is summarised in Table C.2.

Table C2: Importance rating, comfort levels and possible difficulties associated with the most frequently performed procedures.

Procedure	% that believe block to be important	% that feel comfortable performing the block	% that has difficulties with...			
			knowledge of procedure	necessary equipment	practical skill	clinical anatomy knowledge
Caudal epidural block	80.4%	90.2%	9.8%	21.6%	15.7%	15.7%
Lumbar epidural block	43.8%	75%	0%	37.6%	18.8%	18.8%
Brachial plexus block	44.4%	72.3%	27.8	22.3%	50%	33.3%
Femoral nerve block	72.2%	77.8%	22.3%	22.3%	27.8%	22.3%
Ilio-inguinal/iliohypogastric nerve block	66.7%	80.9%	19.1%	9.5%	14.3%	19.1%

The specific anatomically related complications associated with each of the five “problem” procedures, as well as the frequency of occurrence is summarised in Table C3.

Table C3: Complications experienced during the performance of the five “problem” procedures.

Caudal epidural block		Lumbar epidural block		Brachial plexus block		Femoral nerve block		Ilio-inguinal/ iliohypogastric nerve block	
Complication	%	Complication	%	Complication	%	Complication	%	Complication	%
Difficulty palpating landmarks for needle insertion	47.1%	Difficulty locating needle insertion site	12.5%	Difficulty palpating landmarks for needle insertion	39.0%	Difficulty locating needle insertion site	39.0%	Difficulty in visualising position of the nerves	33.4%
Injection into sacral bone marrow	29.4%	Dural puncture	37.5%	Vascular puncture	44.4%	Vascular puncture	44.4%	Nerve trauma	23.8%
Difficulty piercing the SC ligament	33.3%	Lesions to IV discs and ligaments	6.3	Nerve trauma	11.2%	Nerve trauma	10.2%	Blocking of femoral nerve	14.1%
Vascular puncture	25.5%	Trauma of the spinal cord and nerve roots	12.5%	Pneumothorax	5.6%			Partial or incomplete block	61.9%
Dural puncture	17.7%	Vascular puncture	6.3%						
Sub - arachnoid injection	11.8%	Misplacement of epidural catheter	18.8%						
Misplacement into soft tissue or rectum (pelvic viscera)	23.5%								

* SC = Sacrococcygeal

* IV = Intervertebral

Participating anaesthesiologists were also asked to score whether they (1) Strongly agreed, (2) Agreed, (3) Disagreed or (4) Strongly disagreed with the statements: *Increased clinical anatomy knowledge will decrease complications* (see Figure C1) and *Increased clinical anatomy knowledge will increase confidence* (see Figure C2).

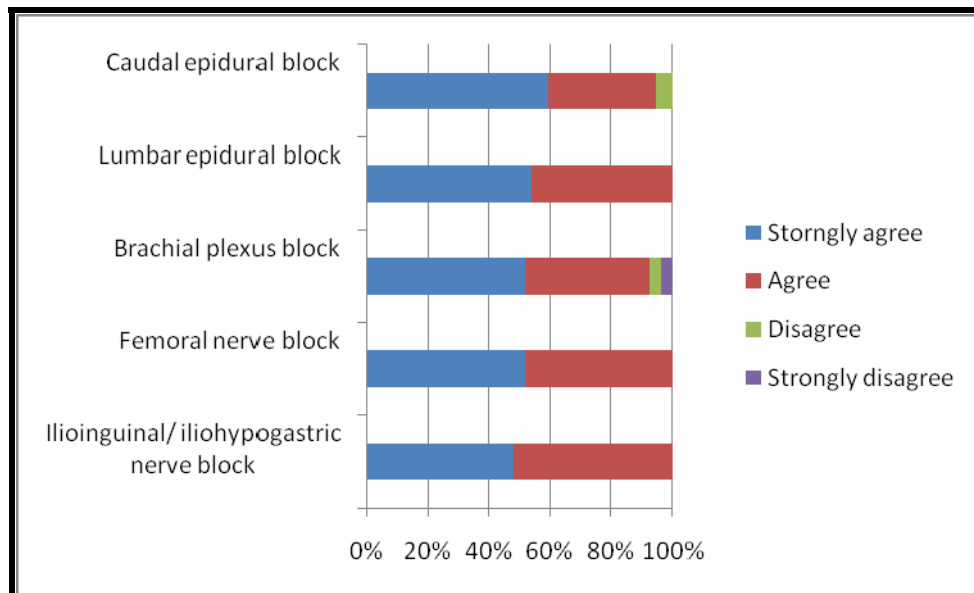


Figure C1: Importance of clinical anatomy knowledge in decreasing complications.

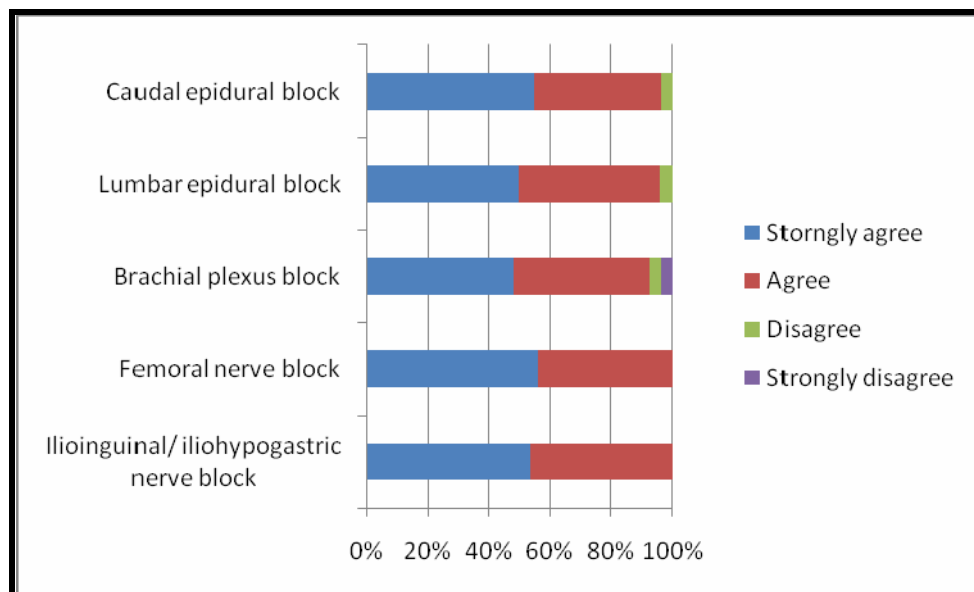


Figure C2: Importance of clinical anatomy knowledge in increasing comfort levels.