

University of Pretoria etd – Ide, A (2005)

THE HISTOPATHOLOGY OF LIONS (*Panthera leo*) SUFFERING FROM
CHRONIC DEBILITY IN THE KRUGER NATIONAL PARK

BY

ANNALIZE IDE

Submitted in partial fulfilment of the requirements
for the degree

MASTER OF VETERINARY MEDICINE (PATHOLOGY)

in the

FACULTY OF VETERINARY SCIENCE
UNIVERSITY OF PRETORIA

JANUARY 2002

This dissertation is dedicated to
Africa and her
magnificent wildlife –
may they be preserved for generations to come.

ACKNOWLEDGEMENTS

I wish to thank the laboratory staff at the Department of Pathology, Faculty of Veterinary Science, University of Pretoria for processing, sectioning and staining the histopathology samples; Eleanor Stylianides and Prof. Moritz van Vuuren from the Department of Veterinary Tropical Diseases, Faculty of Veterinary Science, University of Pretoria for the serology; Anita Michel from the Onderstepoort Veterinary Institute for Mycobacterial culture; Prof Suzanne Kennedy-Stoskopf from the Department of Microbiology, Pathology and Parasitology at North Carolina State University, USA, for the monoclonal antibodies used in the immunohistochemistry and valuable advice with regard the immunohistochemical technique; Marianna Rossouw, previously of the Department of Pathology, Faculty of Veterinary Science, University of Pretoria for technical assistance with necropsies and sample collection, as well as her perseverance in perfecting the immunohistochemical technique; colleagues at the Department of Pathology, Faculty of Veterinary Science, University of Pretoria for valuable discussion and advice; Drs Dewald Keet and Roy Bengis and staff of the State Veterinary Office in Skukuza, Kruger National Park for invaluable help with necropsies and sample collection; Prof Joop Boomker for advice and discussion on the various parasites; Dr Jaco van der Lugt for discussion of the ocular pathology.

I would also like to thank colleagues and friends in Britain: My employers, Peter and Lorraine Finn for their patience and CPD time given to me in order to finish this dissertation; Dr David Shearer for his support and very valuable advice, as well as crucial scientific input and help with the photography; Tanya McDaniel for proofreading of the manuscript.

Last, but not least I wish to thank my parents for their understanding and constant support, as well as their unfailing believe in my capability of completing this endless task, and my husband James who has been married to me and this project for the past five and a half years – need I say any more?

I realise how privileged I was to have had the opportunity to base this research project on that most magnificent “King of Beasts”.

CONTENTS

	Page
SUMMARY.....	1
KEY TERMS.....	3
INTRODUCTION AND LITERATURE REVIEW	
1. Background.....	4
2. A review of diseases described in lions (<i>Panthera leo</i>).....	5
2.1. Respiratory System.....	5
2.2. Gastrointestinal System and Pancreas.....	6
2.3. Liver.....	9
2.4. Musculoskeletal System.....	9
2.5. Cardiovascular System.....	9
2.6. Endocrine System.....	9
2.7. Urinary System.....	10
2.8. Reproductive System.....	10
2.9. Integumentary System.....	10
2.10. Nervous System and Eyes.....	10
2.11. Haematopoetic and Lymphoid System.....	12
MATERIALS AND METHODS	
1. Histopathology.....	15
1.1. Tissue for descriptive histopathology in animals suffering from chronic debility.....	15
1.2. Tissue for descriptive histopathology in clinically healthy animals.....	15
1.3. Technique.....	15
2. Immunohistochemistry.....	16
2.1. Tissue for immunohistochemistry from clinically healthy lions and lions suffering from chronic debility.....	16
2.2. Technique.....	16
3. Serology.....	18
3.1. Feline Immunodeficiency Virus Serology.....	18
4. Microbiology.....	18
4.1. Mycobacterial Culture.....	18
RESULTS	
HISTOPATHOLOGY.....	19
1. Changes in the lymphoid organs.....	19
1.1. Lymph node changes.....	19
1.1.1. Overview of general lymph node changes.....	22
1.1.2. Specific lymph node changes.....	24
1.1.2.1. Superficial cervical lymph nodes.....	24
1.1.2.2. Mandibular lymph nodes.....	25
1.1.2.3. Axillar lymph nodes.....	26
1.1.2.4. Inguinal lymph nodes.....	27
1.1.2.5. Popliteal lymph nodes.....	28

	Page
1.1.2.6. Bronchial lymph nodes.....	29
1.1.2.7. Mesenteric lymph nodes.....	30
1.2. Splenic changes.....	30
1.3. Tonsillar changes.....	31
1.4. Thymic changes.....	31
2. Pulmonary changes.....	32
3. Gastro-intestinal changes.....	34
3.1. Glossal changes.....	34
3.2. Gastric changes.....	34
3.3. Small intestinal changes.....	35
3.4. Large intestinal changes.....	36
4. Pancreas.....	36
5. Bone marrow changes.....	36
6. Renal changes.....	37
7. Cutaneous lesions.....	38
8. Ocular lesions.....	40
9. Skeletal muscle changes.....	41
10. Myocardial changes.....	41
11. Hepatic changes.....	42
12. Central nervous system changes.....	43
13. Thyroid.....	44
IMMUNOHISTOCHEMISTRY.....	45
SEROLOGY FOR FELINE IMMUNODEFICIENCY VIRUS.....	48
MYCOBACTERIAL CULTURE.....	48
DISCUSSION.....	49
REFERENCES.....	60

LIST OF FIGURES

	Page
FIGURE 1: Lymph node.....	I
FIGURE 2: Lymph node.....	I
FIGURE 3: Lymph node.....	II
FIGURE 4: Lymph node.....	II
FIGURE 5: Lymph node.....	III
FIGURE 6: Lymph node.....	III
FIGURE 7: Lymph node.....	IV
FIGURE 8: Lymph node.....	IV
FIGURE 9: Lung.....	V
FIGURE 10: Lung.....	V
FIGURE 11: Lung.....	VI
FIGURE 12: Lung.....	VI
FIGURE 13: Stomach.....	VII
FIGURE 14: Small intestine.....	VII
FIGURE 15: Small intestine.....	VIII
FIGURE 16: Bone marrow.....	VIII
FIGURE 17: Kidney.....	IX
FIGURE 18: Kidney.....	IX
FIGURE 19: Skin.....	X
FIGURE 20: Skin.....	X
FIGURE 21: Eye.....	XI
FIGURE 22: Eye.....	XI
FIGURE 23: Skeletal muscle.....	XII
FIGURE 24: Skeletal muscle.....	XII
FIGURE 25: Liver.....	XIII
FIGURE 26: Spinal cord.....	XIII
FIGURE 27: Spinal cord.....	XIV
FIGURE 28: Cerebrum.....	XIV
FIGURE 29: Lymph node – Immunohistochemical staining.....	XV
FIGURE 30: Lymph node – Immunohistochemical staining.....	XV
FIGURE 31: Lymph node – Immunohistochemical staining.....	XVI
FIGURE 32: Lymph node – Immunohistochemical staining.....	XVI

LIST OF TABLES

	Page
Table 1.1(a): Lymph node changes – summary of various changes as a percentage of total number of cases evaluated.....	i
Table 1.1(b): Lymph node changes – general atrophy or hyperplasia....	ii
Table 1.2: Lymph node changes – Superficial cervical (prescapular)	iii
Table 1.3: Lymph node changes – Mandibular.....	iv
Table 1.4: Lymph node changes – Axillar.....	v
Table 1.5: Lymph node changes – Inguinal.....	vi
Table 1.6: Lymph node changes – Popliteal.....	vii
Table 1.7: Lymph node changes – Bronchial.....	viii
Table 1.8: Lymph node changes – Mesenteric.....	ix
Table 2: Pulmonary changes.....	x
Table 3.1: Gastric changes.....	xi
Table 3.2: Small intestinal changes.....	xii
Table 3.3: Colonic changes.....	xiii
Table 4: Bone marrow changes.....	xiv
Table 5: Renal changes.....	xv
Table 6: Skeletal muscle changes.....	xvi
Table 7: Myocardial changes.....	xvii
Table 8: Hepatic changes.....	xviii
Table 9: Central nervous system changes.....	xix
Table 10.1: Immunoperoxidase – Superficial cervical lymph node.....	xx
Table 10.2: Immunoperoxidase – Mandibular lymph node.....	xx
Table 10.3: Immunoperoxidase – Axillar lymph node.....	xxi
Table 10.4: Immunoperoxidase – Inguinal lymph node.....	xxi
Table 10.5: Immunoperoxidase – Popliteal lymph node.....	xxii
Table 10.6: Immunoperoxidase – Bronchial lymph node.....	xxii
Table 10.7: Immunoperoxidase – Mesenteric lymph node.....	xxiii
Table 11: FIV serology results.....	xxiv
Table 12: Mycobacterial culture results.....	xxv
Table 13: Summary of important histopathological changes.....	xxvi

Studies on the health status of lions (*Panthera leo*) in the Kruger National Park (KNP) have revealed certain lions suffering from chronic debility (“poor doers”). Clinical signs include chronic emaciation, renal failure and chronic bacterial infections. The diagnosis of *Mycobacterium bovis* in KNP lions in 1995 raised the question of whether these “poor doer” lions were suffering from tuberculosis. Tests confirmed tuberculosis in some cases, but no aetiology for the poor condition was found in a large percentage of the animals tested. Extensive literature review failed to reveal reports of similar findings of chronic debility in free living lion populations, although various disease outbreaks and infectious diseases of lions are described. These are briefly reviewed.

Surveys have confirmed that the majority of the KNP lions are serologically positive for feline immunodeficiency virus (FIV), the clinical importance of which is questioned as a possible cause of immunosuppression in lions.

Tissue samples from eleven lions suffering from chronic debility and six clinically healthy lions were studied by light microscopy. Changes in the various organ systems were reported and tabulated with reference to degree and relevance. Frozen lymph node samples from some animals in both groups were collected for immunohistochemical staining for T and B lymphocytes and CD4 and CD8 subsets. In some cases serology was done for FIV using a Puma Lentivirus ELISA and a Puma Lentivirus Western Blot technique. Mycobacterial culture results were available for some animals.

The histopathological features varied, but notable changes were seen in the lymph nodes. These included generalized lymphoid hyperplasia (predominantly affecting clinically healthy lions), progressing through combined hyperplasia and atrophy in different nodes to lymphoid atrophy affecting most of the lions suffering from chronic debility. These are non-specific findings seen in various systemic diseases, including canine distemper virus infection and toxoplasmosis, but they have also been described in domestic cats suffering from FIV infection and humans with HIV. Further findings in lymph node sections included mineral deposition and multifocal cystic spaces.

University of Pretoria etd – Ide, A (2005)

Other important histopathological changes included chronic interstitial pneumonia, renal amyloidosis, chronic interstitial nephritis, Wallerian degeneration of the spinal cord, encephalomalacia and anterior uveitis. Two animals suffered from multifocal, multisystemic granulomatous inflammation. *Mycobacterium bovis* was cultured from one of these cases, but no apparent aetiology could be found in the other. Eosinophilia was a consistent finding in many tissues and most likely related to the high parasite load in many of the animals. Parasites found included *Hepatozoon* spp., microfilaria, cestodes, nematodes and trematodes and *Sarcocystis* spp. and *Trichinella* spp.

Immunohistochemical staining for B and T lymphocytes and CD4 and CD8 subsets showed a normal distribution of the staining pattern within the lymph node sections, although the samples were all from FIV positive lions.

The histopathology in both study groups was of a non-specific nature and not indicative of any particular disease syndrome, although many of the changes are similar to those described in domestic cats infected with FIV. There are indications of possible immunocompromise in the “poor doer” lions, which warrants further investigation.

University of Pretoria etd – Ide, A (2005)
KEY TERMS

Lions, *Panthera leo*, chronic debility, feline immunodeficiency virus, histopathology, lymph nodes, *Mycobacterium bovis*, immunohistochemistry, immunocompromise.

1. Background

Ongoing studies on the health status of lions (*Panthera leo*) in one of South Africa's major game reserves, the Kruger National Park (KNP), Mpumalanga Province, have revealed a number of lions from both gender suffering from chronic debility. Over the past few years a number of lions in the KNP were found to be suffering from various clinical conditions, such as chronic emaciation, renal failure and chronic bacterial infections, affecting mainly the skin and lungs (personal communication: Dr D.F. Keet and Prof. N.P.J. Kriek). These animals became known as the so-called "poor doer" lions. During 1995 three lions suffering from tuberculosis, caused by *Mycobacterium bovis*, were culled in the KNP.²² Subsequently an investigation of "poor doer" lions was launched to test the hypothesis that these animals were suffering from tuberculosis. Of the 20 animals examined, only two were infected with tuberculosis (personal communication: Dr D.F. Keet and Prof. N.P.J. Kriek). No aetiology for the poor condition in the remaining 18 lions was found.

Since the conclusion of the previous investigation, a further number of "poor doer" lions from the Kruger Park were necropsied by pathologists from the Department of Pathology, Faculty of Veterinary Science, University of Pretoria and veterinary surgeons from the State Veterinary Services, Skukuza, KNP. Although tuberculosis was confirmed in some of these animals by means of histopathological examination and mycobacterial culture, a specific cause of the chronic debility in many of them could not be determined at necropsy or by histopathological examination.

A number of serological surveys in the KNP have confirmed that the majority of KNP lions are serologically positive for feline immunodeficiency virus (FIV).^{49,51,58} The clinical significance of FIV infection in free-ranging lions has never been investigated and is questioned as a possible cause of immunosuppression in KNP lions.

An extensive review of the literature failed to reveal any reports of similar findings of chronic debility in any free-living lion populations. However, various disease outbreaks and infectious diseases affecting both free-ranging and captive lions (*Panthera leo*) are discussed below.

Munson highlights the potential dangers of introducing non-indigenous infectious agents from relocated free-ranging and released captive-bred wildlife on the indigenous wildlife in an area.³³ She also states the importance of characterising the microflora and disease susceptibility of both the introduced and indigenous species, as well as knowledge of the current health status and prevalence of diseases in any particular wildlife population. Such a minimum database on disease prevalence is sadly lacking for most wildlife species.³³ Macdonald reflects on the potentially devastating consequences of transmission of diseases traditionally found in our domestic pets to wildlife populations.²⁸ Specific diseases mentioned include canine distemper virus, rabies, feline infectious peritonitis (FIP) and feline immunodeficiency virus (FIV).²⁸

2. A review of diseases described in lions (*Panthera leo*)

2.1. Respiratory System

Tuberculosis caused by *Mycobacterium bovis* has been described in captive lions and since 1995 also in free-ranging lions in the KNP.^{21,22} It appears that, in the latter case, the lions become infected by eating *Mycobacterium bovis*-infected African buffalo (*Syncerus caffer*) carcasses.^{21,22} In some of the first cases described, macroscopic lesions in the lungs were areas of consolidation, containing multiple fibrous, but thin-walled cavities filled with mucoid fluid.^{21,22} Smears from these lesions revealed acid-fast bacilli.^{21,22} Histologically the lesions were of granulomatous pneumonia, with an absence of multinucleated giant cells.^{21,22} Examination of the lymph nodes of the affected lions showed atrophy, but no evidence of tuberculosis.^{21,22} *Mycobacterium bovis* was cultured from the lung lesions and restriction fragmentation length polymorphism (PCR) analysis showed the isolates to be similar to the most common KNP buffalo type (Ls-01).^{21,22}

Bacterial pneumonia has been described as the cause of death in a six-year-old captive male lion.³⁰ The animal suffered from a pyogranulomatous pneumonia caused by Gram-negative, non-acid fast bacteria, characterised as EF-4 (fermentative group).³⁰

Blastomycosis was diagnosed as the cause of a pyogranulomatous lesion at the bifurcation of the trachea in a fourteen-year-old captive lioness.³⁰ Lesions were also present in the lung parenchyma and cerebrum.³⁰ Fluorescent antibody tests confirmed the cause of the lesions to be *Blastomyces dermatitidis*.³⁰

An outbreak of **feline herpesvirus-1** (feline rhinotracheitis) has been described in captive wild felids, including a lion.³⁰ Necropsy findings included catarrhal rhinitis, tonsillitis, swollen tracheal and bronchial mucosae and pulmonary emphysema or congestion.³⁰ There are no reports of this disease in free-ranging lions.³⁰

Serological surveys confirmed the presence of antibodies to **feline herpesvirus-1** in 91% of KNP lions in 1991⁴⁸ and 100% of the same population in 1997.⁵⁸ 67% of lions in the Etosha National Park, Namibia, tested positive in 1993⁵⁰ and 96% and 98%, respectively, in Botswana and the Umfolozi Game Reserve, South Africa, in 1997.⁵⁸ The current perception is that feline herpesvirus infection in free-ranging lions is benign.^{30,58}

Multifocal, necrotizing interstitial pneumonia has been described in two lions that died with acute disseminated **toxoplasmosis** in a zoo in Nigeria.³⁵

Canine distemper virus infection causes a mild, multifocal interstitial pneumonia in infected lions.^{34,45}

2.2. Gastrointestinal System and Pancreas

In 1973 an outbreak of **feline panleukopenia** was described in a pride of 18 captive lions in a lion park in Australia.^{30,52} Clinical signs were consistent with feline panleukopenia and post mortem examination of two of the cases confirmed fibrinous enteritis, with gross thickening of the mucosa and muscularis.⁵² Histologically there

University of Pretoria etd – Ide, A (2005)

was extensive fibrinous necrosis of the gastric, intestinal and colonic mucosa, with deep bacterial invasion.⁵² Feline panleukopenia virus was isolated from the spleens and intestines of both cases.⁵² Subsequently feline panleukopenia virus was isolated from a lioness, which was one of 19 young lions that died during an outbreak in a Japanese wildlife park in 1994.^{30,31} Histological evaluation showed enterocyte necrosis and distention of crypts with cellular debris and mucus. Numerous intranuclear inclusion bodies were present in crypt enterocytes.³¹

Serological surveys for antibodies against **feline panleukopenia virus** (or an antigenically related parvovirus) confirmed 84% positivity in KNP lions in 1991,⁴⁸ but no positivity in 32 animals tested from the same population in 1997.⁵⁸ No lions from the Etosha National Park were positive.⁵⁰ 3% and 5% tested positive from Botswana and the Umfolozi Game Reserve, respectively, in 1997.⁵⁸

A strain of **feline calicivirus** was isolated from swabs taken from some animals in a group of, amongst others, 17 African lions in a Japanese safari park.¹⁹ These animals showed clinical signs of acute vesicular formation on the tongue and snout.¹⁹ Previous serological surveys for **feline calicivirus** reported the absence of antibodies in lions from the KNP⁴⁸ and Etosha National Park.⁵⁰ In 1997 a low average percentage (5%) of positivity was noted in lions from three southern African wildlife parks (KNP, Botswana and Umfolozi).⁵⁸

A series of cases of oral papillomatosis affecting the ventral tongue of captive and wild asian lions (*Panthera leo persica*) has been described.⁵³ A **feline papillomavirus** with a different epitope conservation pattern and genomic DNA restriction pattern from the domestic cat cutaneous papillomavirus was isolated from these cases.⁵³ Histologically the tongue lesions were of small sessile or papillomatous lesions comprising hyperplastic keratinocytes, with the hyperplastic epithelium occasionally supported by fibrovascular stalks.⁵⁴ The stratum granulosum was prominent, with koilocytic atypia of individual cells in the stratum spinosum and granulosum.⁵⁴ Condensed cytoplasmic inclusions were present within degenerating keratinocytes and immunohistochemistry demonstrated papillomavirus antigens within the nuclei of the koilocytes.⁵⁴

Feline infectious peritonitis (FIP) has been reported in a lioness.³⁰ The virus that causes FIP is antigenically similar to feline enteric coronavirus, making interpretation of serological results difficult.^{30,58} The results only indicate exposure to a coronavirus.⁵⁸ Previous serological studies failed to show antibodies against coronavirus in lions from the KNP,⁴⁸ but showed low (3%) positivity in Etosha National Park.⁵⁰ Studies done in 1997 revealed positive results in 15% of lions in the KNP, 25% in Botswana, 7% in the Umfolozi Game Reserve and 80% in captive lions.⁵⁸

Histological examination of gastric samples from lions in the Etosha National Park, Namibia, showed the presence of **gastric spiral bacteria** in 30% of the animals examined.²⁴ The spiral bacteria were located extracellularly in the fundic and pyloric glands, as well as apparently intracellularly within parietal cells in the fundic region.²⁴ The bacteria had histologic and ultrastructural characteristics consistent with species in the genus *Helicobacter* or *Helicobacter*-like organisms.²⁴ Histologically, the mild to moderate lymphocytic gastritis noted did not differ significantly between infected and uninfected individuals.²⁴ Thus, the bacteria are regarded as commensals or opportunistic pathogens.²⁴ In a study of gastric samples from various captive exotic carnivores, *Helicobacter pylori*-like organisms (HPLO) were found in 90% of the lions examined, while large *Helicobacter*-like (HLO) organisms were found in 3 lions (in coexistence with HPLOs).¹⁸ Histopathological changes associated with HPLO and HLO colonization were the formation of mucosal lymphoid follicles, as well as lymphoplasmacytic and neutrophilic infiltration of the gastric mucosa associated with HPLO infection.¹⁸ This study concluded that HPLOs and HLOs may be an important cause of chronic gastritis in tigers and lions.¹⁸

Coccidia have been reported from captive and free-ranging lions.^{7,30} Various *Isospora* spp. have been identified, but no signs of associated disease have been reported.^{7,30}

The most important **nematodes** described in the intestinal tract of lions are *Trichinella spiralis* (in the smooth muscle layers), various hookworms (*Galonchus perniciosus*, *Ancylostoma* spp.) and the ascarids *Toxocara canis* and *T.cati*, as well as *Toxascaris leonina*.⁷ **Cestodes** include a wide variety of species from the genus

Taenia.⁷ Infection with the cestode *Spirometra* spp. has been reported from Tanzania.³¹ A single **trematode** found in the intestines of a lion appears to have been an incidental finding.⁷ There are no reports of disease or death in lions directly related to intestinal parasites.

No diseases directly affecting the pancreas have been described.

2.3. Liver

No references to diseases primarily affecting the hepatobiliary system of lions were found. Large areas of hepatic necrosis have been described in two lions that died of acute disseminated toxoplasmosis in a zoo in Nigeria.³⁵

2.4. Musculoskeletal System

Intramuscular **sarcocysts** have been noted in skeletal muscles and glossal muscle of lions.^{7,24} Evaluation of sarcocysts found in the hind limb skeletal muscles and glossal muscle of a group of necropsied lions from the Etosha National Park, Namibia, confirmed ultrastructural features consistent with *Sarcocystis felis*.²⁴ There was no inflammatory response associated with these sarcocysts.²⁴

2.5. Cardiovascular System

No references to diseases primarily affecting the cardiovascular system of lions were found.

2.6. Endocrine System

No references to diseases primarily affecting the endocrine system in lions were found.

2.7. Urinary System

No references to diseases primarily affecting the urinary system in lions were found. However, renal amyloidosis is mentioned as an incidental necropsy finding in a lion suffering from tuberculosis.²²

2.8. Reproductive System

No references to diseases primarily affecting the reproductive system of lions were found.

2.9. Integumentary System

No references to diseases primarily affecting the skin of lions were found.

2.10. Nervous System and Eyes

Canine distemper virus is a well-documented killer of various exotic wildlife species, including lions – both captive and free-ranging.^{1,2,34,45,60} The most devastating distemper epidemic in free-ranging lions occurred in the Serengeti in East Africa in 1994.^{1,2,34,45} Approximately one third of the lion population in this ecosystem died as a result.^{34,45} Clinically the lions presented with neurological signs^{34,45,60} and marked dyspnoea.³⁴ Many lions also became notably emaciated and appeared unthrifty.³⁴ At necropsy the most notable gross findings were traumatic wounds, lymphadenopathy and emaciation.³⁴ Consistent histopathological findings in these lions were mild, multifocal interstitial pneumonia, nonsuppurative encephalitis and lymphoid depletion of lymph nodes and spleen.^{34,45} The encephalitis was characterised by neuronal necrosis affecting the hippocampus and parahippocampus, as well as gliosis.³⁴ The pulmonary lesions comprised Type II pneumocyte hyperplasia and rare syncytial cell formation.³⁴ Rare intranuclear and intracytoplasmic viral inclusion bodies were found in the lymphocytes, astrocytes, hippocampal neurons, Type II pneumocytes, bile ducts and epididymal epithelium.^{34,45} Immunohistochemical staining confirmed canine distemper virus (CDV) infection in tissues by means of anti-CDV monoclonal antibodies.^{34,45}

University of Pretoria etd – Ide, A (2005)

Serological testing of various southern African lion populations indicated widespread canine distemper virus infection – 6% in the KNP and 26% in Botswana in 1997.⁵⁸ However, to date, no catastrophic mortalities pointing towards CDV infection has been reported in lions in southern Africa, suggesting that these animals are capable of mounting a protective immune response before the virus migrates into the central nervous system.⁵⁸

Acute disseminated **toxoplasmosis** is described as the cause of death of two lions from a group of five in Jos Zoological Gardens in Nigeria.³⁵ Both animals showed multifocal necrotizing interstitial pneumonia, with thickening of the alveolar septa and infiltration of neutrophils and macrophages.³⁵ *Toxoplasma gondii* tachyzoites were present in the bronchiole walls, macrophages and extracellular spaces.³⁵ Extensive necrosis was present in the liver, spleen and mesenteric lymph nodes and numerous free and intracellular tachyzoites were seen in these organs.³⁵ The intestinal tract and Peyer's patches showed focal necrosis and mononuclear cell infiltration.³⁵ Multifocal encephalitis was most severe in the cerebrum and midbrain, with necrosis and infiltration of macrophages, mononuclear cells and neutrophils affecting the white and grey matter.³⁵ There was also scattered perivascular cuffing with mononuclear cells and neutrophils.³⁵ *T. gondii* oocysts were present in the faeces of these animals and serum samples tested positive for *T. gondii* antibodies with the Sabin-Feldman dye test and the microtitre test technique.³⁵

Of 66 lions from the Etosha National Park tested with a commercial indirect immunofluorescence assay, 98% tested positive for antibodies to toxoplasma.⁵⁰ A serological survey of the prevalence of toxoplasma in lions from different geographical areas in South Africa showed high levels of antibodies to this parasite.³⁰

Encephalitozoon cuniculi has been reported from a litter of lion cubs born at a breeding centre in the Lowveld of Limpopo Province, South Africa (personal communication: Dr P.S. Rogers).

Greenwood reported an outbreak of **botulism** in a group of six circus lions fed broiler chickens that had been unrefrigerated for 48 hours.¹⁵ Clinical signs included hind limb ataxia and paresis, followed by recumbency, immobility and ataxia.¹⁵

University of Pretoria etd – Ide, A (2005)

There was paralysis of the extraocular muscles and nictitating membrane, as well as pupillary dilatation and inability to swallow.¹⁵ Botulism caused by *Clostridium botulinum* type C was diagnosed and appropriate supportive therapy instituted.¹⁵ A single lioness died and was found to have 50-80 mouse lethal doses of botulinum toxin per ml serum.¹⁵

Retinal degeneration has been described in two **feline immunodeficiency virus (FIV)** seropositive lions.²³ (and personal communication: Prof. S. Kennedy-Stoskopf) The most common ophthalmic manifestation of FIV in domestic cats is retinal degeneration, with lesions present multifocally, irregularly and located peripherally.²³

2.11. Haematopoietic and Lymphoid System

A currently widely researched virus in captive and free-ranging wild felids is **feline immunodeficiency virus (FIV)**, due to the fact that widespread seropositivity for this virus has been reported.^{4,8,9,23,25,27,36,37,38,42,49,51,56,57} To date no convincing evidence of this virus causing clinical disease in free-ranging wild felidae has been found, however, neither are there sufficient data available to dismiss the virus as a possible cause of clinical disease in wild felids.^{4,8,9,36,56,57}

In a pilot study to compare the T-helper (CD4+) and T-suppressor (CD8+) cell ratios in FIV positive and negative lions, the CD4:CD8 ratio for FIV positive lions was much lower than in FIV negative lions.⁵¹ As the FIV positive lions were younger than the negative lions, it is speculated that there may be an age influence on the numbers of circulating leukocytes.⁵¹ Evaluation of the numbers of CD4+ positive cells (the cells mainly affected by immunodeficiency viruses) shows a significant decrease in CD4+ cells in FIV positive domestic cats.⁵¹ However, in FIV positive and negative lions, the mean percentages were very similar.⁵¹ Thus, although the CD4:CD8 ratios in FIV positive lions appeared to be adversely affected, the numbers of CD4+ and CD8+ cells did not appear to be decreased significantly.⁵¹ These findings are reflected in a study where domestic cats were infected with strains of lion and puma lentiviruses.⁵⁶ The CD4+ counts in the infected cats remained above 400/ml throughout the study and did not fall below 400/ml as occurs in domestic cats with FIV infection.⁵⁶

[University of Pretoria etd – Ide, A \(2005\)](#)

In 1991 FIV was diagnosed in a captive African lion in a zoo in Italy by means of PCR.⁴² The clinical signs and haematologic abnormalities noted in this animal were reasonably nonspecific, but resembled those frequently reported in FIV-infected domestic cats (generalized lymphadenopathy and recurrent infections).⁴² Histopathological changes in various organs, such as lymph node follicular atrophy, sinus histiocytosis and increased plasma cells in the lymph nodes, as well as diffuse interstitial infiltration of lymphocytes and plasma cells in the kidneys, liver and lungs, are also features commonly noted in domestic cats with advanced FIV-infection.⁴²

In 1994 it was reported by Kennedy-Stoskopf *et al*²³ that ophthalmological examination in two FIV-positive captive African lions in the United States showed retinal degeneration.²³ This is a common ophthalmic manifestation of FIV infection in domestic cats.²³ Other clinical signs compatible with FIV infection, reported in the above survey of FIV-positive lions, included chronic gingivitis, periodic behaviour changes and myeloproliferative disease.²³ Ophthalmological examination of the retinas of FIV-positive lions in the KNP in 1995 showed that some of these animals suffered from retinal degeneration and chronic retinitis (personal communication: Prof. S. Kennedy-Stoskopf).

During December 1997 two captive FIV-positive African lions died in zoos in the United States (personal communication: Prof. S. Kennedy-Stoskopf). In one of these, atrophic lymph nodes were noted, as well as endogenous lipid pneumonia and hepatic cysts (personal communication: Prof. S. Kennedy-Stoskopf). Necropsy results for the second animal were not available. Thus, although not conclusive at this stage, there is some preliminary evidence to suggest that FIV in African lions may not be a benign infection.^{4,23} Of further concern in the context of the population involved in this current study, is the fact that the seroprevalence of FIV in KNP lions is estimated to be in excess of 80%.^{30,49,58}

Various surveys in free-ranging lion populations of southern Africa failed to detect any seropositivity to **feline leukaemia virus (FeLV)**.^{49,50,58}

University of Pretoria etd – Ide, A (2005)

Compared to their prey species, lions appear to be more resistant to **anthrax**, caused by *Bacillus anthracis* and deaths are comparatively uncommon.³⁰ The primary site of anthrax infection in lions appears to be the pharyngeal lymph nodes.³⁰

Necropsy findings in animals that succumbed from anthrax are variable degrees of facial oedema, subcutaneous oedema and fat necrosis, ascites, serosal congestion, oedema of the stomach wall and pancreas, epi- and endocardial haemorrhage and emphysema of the parotid salivary glands.⁵⁵

Babesia spp.,^{7,26} *Hepatozoon* spp.^{7,29,30} and *Trypanosoma* spp.⁷ have been reported from various free-living lion populations.

1. HISTOPATHOLOGY

1.1. Tissue for descriptive histopathology in animals suffering from chronic debility:

Archived tissue (formalin-fixed and/or paraffin-embedded) from eleven (11) Kruger National Park (KNP) lions suffering from chronic debility and necropsied at an earlier date, was available in the Department of Pathology, Faculty of Veterinary Science, University of Pretoria. A pre-determined set of tissue samples from a further 6 KNP lions suffering from chronic debility was collected by the researcher or Dr D. F. Keet (State Veterinarian, Skukuza, KNP) during necropsy of these animals. These animals were immobilized with a combination of zolazepam and tiletamine hydrochloride (Zolital®) and then euthanased by means of intravenous sodium pentobarbitone (Euthanaze®) overdose. All samples were collected and fixed in 10% neutral buffered formalin.

1.2. Tissue for descriptive histopathology in clinically healthy animals:

A pre-determined set of tissue samples from six (6) clinically healthy KNP lions was collected at necropsy by the researcher. These animals were culled as a result of escape from a tuberculosis positive area (KNP) into a tuberculosis free area outside the borders of the park, or as a result of being a threat to local communities. The animals were immobilized with a combination of zolazepam and tiletamine hydrochloride (Zolital®) and then euthanased by means of intravenous sodium pentobarbitone (Euthanaze®) overdose. All samples were collected and fixed in 10% neutral buffered formalin.

1.3. Technique

Tissue samples that were not already embedded in paraffin wax were sectioned, processed and embedded in paraffin wax using the standard method. Sections were cut at a thickness of 5µm and routinely stained with haematoxylin and eosin. These

sections were examined by light microscopy. In sections where special staining was required, these were done by the standard methods, e.g. Ziehl-Neelsen, Periodic Acid Schiff, Gram Twort and Thioflavine T.^{3,39}

2. IMMUNOHISTOCHEMISTRY

2.1. Tissue for immunohistochemistry from clinically healthy lions and lions suffering from chronic debility

Where possible, samples for immunohistochemical evaluation were collected from fresh lymph nodes from some of the clinically healthy lions, as well as from some of the lions suffering from chronic debility.

The collection was done under field conditions using the following technique:

An aluminium chuck was cooled in liquid nitrogen for a few seconds and the surface covered with Tissue-Tek O.C.T. compound (Sakura, Finetek USA Inc. Torrance, CA, USA). Sections of 3mm thickness were cut from fresh lymph node tissue and gently pressed into the Tissue-Tek O.C.T. compound on the chuck (1 section per chuck). The section was then covered with Tissue-Tek O.C.T. compound and quickly immersed in cooled isopentane for 10-20 seconds. The isopentane was cooled in a stainless steel jug immersed in liquid nitrogen. The snap frozen sections (still on the chucks) were then individually wrapped in heavy-duty aluminium foil. These samples were kept frozen in sealed plastic bags in a container with liquid nitrogen until they could be transferred to an ultra low freezer, where they can be stored indefinitely at -85°C.

2.2. Technique

The primary monoclonal antibodies used in this study were supplied by Prof. Suzanne Kennedy-Stoskopf from the Department of Microbiology, Pathology and Parasitology at North Carolina State University, USA. These monoclonal antibodies were mouse hybridoma supernatants. The following antibodies were used: 572, anti-

feline T lymphocyte; MAE 38, anti-feline CD4; 117, anti-feline CD8 (beta chain) and B5, anti-feline and -canine B lymphocyte.

Sections of $\pm 7\mu\text{m}$ thick were cut on a Microm cryostat at -16°C . These were immediately fixed in cold acetone (4°C) for 10 minutes. Sections were air dried and stored in a Nu Air ultra low freezer at -85°C in sealed plastic slide mailers in a sealed plastic bag. A small amount of silica crystals was added to prevent condensation.

Prior to staining, the sections were removed from the ultra low freezer and left in a humidified container to reach room temperature. Sections were fixed in cold acetone for 10 minutes and washed in phosphate buffered saline (PBS) at pH 7.6 for 5 minutes. The sections were then blocked in 1% H_2O_2 in methanol for 30 minutes and again washed in PBS (2 x 5 minutes). Excess fluid was wiped off and the sections were blocked in a 1:10 dilution of normal rabbit serum (Rabbit anti-cat R-9133, Sigma Chemical Co., St Louis, USA) in PBS for 20 minutes. Excess fluid was wiped off around the sections and the sections were incubated overnight with the various primary antibodies as described above (1:10 dilution with PBS). Sections were again washed in PBS (2 x 5 minutes) and incubated with the secondary antibody (Rabbit anti-mouse Eo354, Dako A/S, Glostrup, Denmark) for 45 minutes (1:250 dilution in PBS). The secondary antibody was washed off in PBS (2 x 5 minutes) and slides dried around the sections. A tertiary antibody (avidin-biotin complex), Vectastain Elite ABC kit (Vector laboratories Inc., Burlingame, CA, USA) was added and sections were again washed in PBS (2 x 5 minutes). The sections were then incubated for 8 minutes in DAB 3,4,3',4'- tetra aminobiphenyl hydrochloride (BDH Laboratory Supplies, Poole, Dorset, UK) - 30mg/100ml PBS, with 4 drops of 3% H_2O_2 added just before incubation. Sections were washed in distilled water and stained with haematoxylin (Lilly-Mayer) for 20 seconds, whereafter they were dehydrated, cleared and mounted according to the standard technique.

The stained sections were evaluated under a light microscope. Evaluation of staining intensity in different zones in the stained lymph nodes was done by subjective interpretation of the stained sections under a light microscope. This, was a qualitative, descriptive evaluation and staining intensity in the different microarchitectural zones of the nodes was graded as 0 - no staining, 1+ - staining of

scattered single cells in a zone, 2+ - staining of at least 50% of the cells in a specific zone, 3+ - staining of most of the cells in a particular zone.

3. SEROLOGY

3.1. Feline Immunodeficiency Virus Serology

Serology for Feline Immunodeficiency Virus (FIV) antibodies was done by the Department of Veterinary Tropical Disease, Faculty of Veterinary Science, University of Pretoria. The blood samples were collected fresh from immobilized animals that were going to be euthanased as a result of suffering from chronic debility or from clinically healthy lions that were being culled for the reasons given above. In some of the archived cases frozen serum samples were available.

The serology was done using a puma lentivirus ELISA technique and a puma lentivirus Western Blot technique. The Western Blot was done by a standard technique and the ELISA was done according to a technique described.⁵⁹

4. MICROBIOLOGY

4.1. Mycobacterial Culture

Culture for *Mycobacterium* spp. was done by standard techniques at the Onderstepoort Veterinary Institute.²⁰

Tissue for culture was collected into sterile containers during necropsy of some of the KNP lions suffering from chronic debility, as well as some of the clinically healthy lions. Samples for culture included fresh lung and/or lymph node tissue (bronchial and/or mesenteric lymph nodes), as well as tissue from apparently diseased organs as noted during necropsy. Tissue samples were refrigerated after collection and mycobacterial culture was done as soon as possible after collection.

RESULTS

HISTOPATHOLOGY

Histopathological evaluation of a pre-determined set of organ samples showed consistent changes in certain organ systems. These changes will be discussed in order of importance, starting with the most significant. As many changes affected samples from both clinically healthy lions and lions suffering from chronic debility, the cases were numbered 1 – 23, where the first six cases were clinically healthy animals and cases 7 – 23 were suffering from debility.

1. Changes in the lymphoid organs

1.1. Lymph node changes

To simplify interpretation, the lymph node changes were categorised. These categories included:

- Cortical follicular hyperplasia;
- “Cortical atrophy”, or rather thinning of the cortex relative to the paracortex and medulla;
- Paracortical hyperplasia, or expansion;
- Paracortical atrophy;
- Medullary plasmacytosis;
- Sinus histiocytosis;
- Infiltration of polymorphonuclear leukocytes (PMNLs - neutrophils and eosinophils);
- Erythrophagocytosis;
- Accumulation of pigment or crystals;
- Presence of cystic spaces and/or dilated sinuses;
- Parasites;
- Multinucleate giant cells;
- Granulomatous inflammation.

Cortical follicular hyperplasia:

[University of Pretoria etd – Ide, A \(2005\)](#)

Follicular hyperplasia was subjectively interpreted as an increase in primary and secondary follicles, with expanded germinal centres containing lymphocytes in various stages of blast transformation (Figure 1). This is a B cell response.

Cortical atrophy:

Atrophy was interpreted as thinning of the lymph node cortex relative to the paracortex and medulla (Figure 2).

Paracortical hyperplasia:

This pattern was characterised by expansion of the T cell zone of the lymph node (Figure 1).

Paracortical atrophy:

This was interpreted as depletion of the paracortical area of the lymph node (Figure 2).

Medullary plasmacytosis:

This was interpreted as an increase in the number of plasma cells present in the medullary cords (Figure 3).

Sinus histiocytosis:

This reactive pattern was characterised by distension and increased prominence of the sinuses (generally medullary), as a result of hypertrophy of the lining endothelium and infiltration by increased numbers of sinus histiocytes (Figure 3).

Infiltration of PMNLs:

This was characterised by random infiltration of the lymph node by neutrophils and/or eosinophils (Figure 5).

Erythrophagocytosis:

This was characterised by phagocytosis of erythrocytes by sinus histiocytes.

Accumulation of pigment or crystals:

[University of Pretoria etd – Ide, A \(2005\)](#)

Pigment accumulation was characterised by predominantly intracellular (sinus histiocytes) accumulation of a dark brown, coarsely granular intracytoplasmic pigment (Figure 3). This was confirmed to be haemosiderin with Perl's Prussian blue stain³ for iron in some sections. The crystalline material was predominantly present in macrophages and multinucleate giant cells and was mildly refractive and mildly birefringent with polarised light (Figure 4).

Presence of cystic spaces and/or dilated sinuses:

A peculiar finding in many of the lymph node samples evaluated was the presence of single to multiple variable-sized "cystic" spaces predominantly involving the cortex and paracortex and occasionally the medulla (Figure 7). In most cases there was indiscriminate loss of the normal lymph node architectural features in the affected areas, with abrupt transition from normal lymph node tissue to irregular cystic spaces. The spaces varied from very small to up to 10mm in diameter and were irregular in shape. Some of the spaces were partially lined by endothelial cells resembling those lining the lymph node sinuses (Figure 8). Although many of the spaces had lost their content in processing, many contained faintly eosinophilic material and generally few mixed viable lymphocytes, eosinophils, neutrophils and histiocytes in various combinations (Figure 8). In some cases microfilarial parasitic remnants and multinucleate giant cells were also present in the cystic spaces (Figure 8).

Variable dilatation of subcapsular and medullary sinuses was also noted – occasionally in association with cystic spaces as described above.

Parasites:

The only parasites noted were remnants of microfilarial larvae (Figure 5).

Multinucleate giant cells:

These cells were characterised by accumulation of clusters of large reactive histiocytic cells, containing more than one nucleus and with or without intracytoplasmic crystalline material (Figure 5).

Granulomatous inflammation:

This was interpreted as focal to multifocal areas of indiscriminate infiltration and/or distortion of the lymph node tissue by clusters of reactive macrophages with or without multinucleate giant cells and admixed neutrophils and/or eosinophils (Figure 6).

1.1.1. Overview of general lymph node changes (Tables 1.1(a) & (b))

In order to simplify the results in this section a brief introductory overview of the combined general changes noted in the various lymph nodes from different sites will be given. Lymph node atrophy was a prominent change in a large percentage of lymph nodes from all sites (Figure 2). Cortical atrophy of a moderate to severe degree was present in a total of 38% of cases. Moderate to severe paracortical atrophy was present in 34% of cases. In many lymph nodes there was concurrent atrophy of the cortex and paracortex. However, in occasional cases, the paracortical atrophy was seen in conjunction with mild to moderate cortical hyperplasia. Moderate to marked follicular hyperplasia was seen in 16% of cases and only 3% of cases showed concurrent paracortical hyperplasia (Figure 1).

Comparing the changes in lymph nodes from various sites of the same animal, there appears to be a general trend towards either generalized lymph node hyperplasia or atrophy. Although variable in degree, predominantly generalized hyperplasia was a feature in the lymph nodes from Cases nos. 1, 2, 4, 6, 7, 8 and 23. Mild to severe atrophy was the predominant feature in the nodes from Cases nos. 5, 9, 11, 12, 13, 14, 15, 16, 17, 18, 19, 20, 21 and 22. A mixed picture of atrophy and hyperplasia was present in Cases nos. 3 and 10.

Moderate to severe plasmacytosis of the medullary cords was present in 31% of cases (Figure 3). Although medullary plasmacytosis involved both atrophic and hyperplastic lymph nodes, it was more predominant in atrophic nodes. 45% of all cases showed marked sinus histiocytosis, involving both atrophic and hyperplastic nodes (Figure 3). Mild to moderate erythrophagocytosis was present in 19% of these cases.

University of Pretoria etd – Ide, A (2005)

Prominent infiltration of eosinophils, variably involving all areas of the lymph nodes, was present in 47% of cases. In many of these cases the eosinophil infiltration was associated with microfilarial parasite remnants (Figure 5). Neutrophil infiltration was present in 16% of cases. Combined infiltration by neutrophils and eosinophils was noted in 9% of cases. Haemosiderin pigmentation, predominantly involving the medullary histiocytes, was present in 15% of cases (Figure 3). In 17% of cases there was mild to marked, multifocal accumulation of crystalline grey-black pigment – both intracellularly within histiocytes and extracellularly (Figure 4). In many of these cases the pigment accumulation was associated with mild to moderate granulomatous inflammation, with admixed multinucleate giant cells. Intracytoplasmic khaki-brown, lipofuscin-like pigment was present in histiocytes in 1% of cases.

Multifocal cystic spaces of varying sizes involving all areas of the lymph nodes were present in 66% of cases (Figure 7). Concurrent dilatation of sinuses was also present in most of these cases. These changes were noted in both atrophic and hyperplastic nodes.

Microfilarial parasitic remnants were present in 14% of cases. In most cases the presence of these parasitic remnants was associated with variable eosinophilia of the nodes, and/or multifocal microgranulomas comprising reactive macrophages and multinucleate giant cells (Figure 5). In a few of the nodes the inflammatory reaction elicited by the parasitic presence was minimal.

Mild, to severe, multifocal granulomatous inflammation was present in 22% of cases (Figure 6). In most of these cases the inflammatory response included multinucleate giant cells. However, in some cases scattered multinucleate giant cells in the absence of significant granulomatous inflammation were present. Although the granulomatous inflammation in most cases was associated with either microfilarial parasites and/or crystalline pigment, there were some cases where no obvious causative agent was noted. In particular Cases nos. 9 and 19 seemed to show granulomatous inflammation in the absence of a visible causative agent, affecting multiple lymph nodes. No acid-fast organisms were demonstrated in these inflammatory foci with Ziehl-Neelsen staining.³

1.1.2. Specific lymph node changes

1.1.2.1. Superficial cervical lymph nodes (Table 1.2)

Superficial cervical (prescapular) lymph node samples from all 23 cases were evaluated. In 61% (14/23) of the lymph nodes there was moderate to severe atrophy of the cortex and moderate to severe paracortical atrophy was noted in a similar percentage of cases – both in nodes with cortical hyperplasia (1/14), but predominantly in those with cortical atrophy (13/14). Moderate expansion of the cortex by follicular hyperplasia was present in 17% (4/23) of cases. No paracortical hyperplasia was noted in any of these samples. Moderate to marked plasmacytosis of the medullary cords was present in 26% (6/23) of cases and involved both atrophic (5/6) nodes and hyperplastic nodes (1/6). Moderate to severe sinus histiocytosis was present in 39% (9/23) of cases – four instances in hyperplastic nodes and five in atrophic nodes. Mild to moderate erythrophagocytosis by medullary histiocytes was present in 30% (7/23) of cases.

In 43% (10/23) of cases there was mild to marked infiltration by eosinophils, indiscriminately involving the capsule, cortex, paracortex, subcapsular and medullary sinuses and medullary cords. 22% (5/23) of cases had mild, multifocal neutrophil infiltration and in 13% (3/23) of cases there was a mild to moderate, multifocal mixed infiltrate. Mild intracytoplasmic haemosiderin pigmentation (confirmed with Perl's Prussian blue stain³ in some cases) was present in the medullary histiocytes in 30% (7/23) of cases. In four of these cases, the haemosiderin pigmentation was associated with erythrophagocytosis. 13% (3/23) of cases showed mild accumulation of fine black granular to crystalline material – predominantly intracytoplasmic in clusters of macrophages, but also extracellularly. These pigment-containing macrophages were randomly scattered throughout.

In 74% (17/23) of cases single to multifocal, variably sized, irregular-shaped cystic spaces were evident. As mentioned previously, these spaces resulted from indiscriminate loss of lymph node architectural structures and were generally partially lined by endothelial cells similar to those lining the sinuses, suggesting that these spaces possibly originated from dilated sinuses. The spaces contained generally scant

numbers of variable combinations of lymphocytes, eosinophils, neutrophils and histiocytes, as well as faintly eosinophilic proteinaceous fluid. In most cases there was also concurrent (occasionally in the absence of cystic spaces) dilatation of subcapsular and/or medullary sinuses.

Scattered microfilarial parasites were present in 9% (2/23) of cases. In one of these cases (No. 4) the parasites were contained within multifocal granulomas comprising large epithelioid macrophages, multinucleate giant cells and eosinophils. In this case numerous eosinophils were scattered throughout the lymph node. In Case no.14 only scattered parasitic remnants were present and there was no associated inflammation. There was also no evidence of eosinophilia in the rest of this node.

In two cases (Nos. 9 & 19) there were multifocal, small granulomas scattered throughout. These granulomas comprised epithelioid macrophages (both cases) and multinucleate giant cells (only Case no. 9). The granulomas were not associated with parasites or pigment. In Case no. 16 there was multifocal infiltration of macrophages and associated multinucleate cells containing crystalline pigment.

1.1.2.2. Mandibular lymph nodes (Table 1.3)

Mandibular lymph node samples from 20 of the 23 cases were available for evaluation. In 40% (8/20) of cases there was moderate to severe cortical atrophy and significant paracortical atrophy was present in 35% (7/20) of cases. Paracortical atrophy was only present in nodes showing cortical atrophy. 25% (5/20) of cases showed follicular hyperplasia and in three of these nodes there was concurrent paracortical hyperplasia. Moderate to severe plasmacytosis of the medullary cords was present in 30% (6/20) of cases and was predominantly seen in atrophic or mildly hyperplastic nodes. Moderate to severe sinus histiocytosis was present in 45% (9/20) of cases – six instances in hyperplastic nodes and three in atrophic nodes. Mild to moderate erythrophagocytosis was present in 25% (5/20) of cases – all of these cases showing significant sinus histiocytosis.

In 55% (11/20) of cases there was mild to severe eosinophil infiltration, involving all areas of the nodes. 15% (3/20) of cases had mild, multifocal neutrophil

infiltration and in 5% (1/20) of cases there was a mild mixed infiltrate. Mild haemosiderin pigmentation was present in the medullary histiocytes in 25% (5/20) of cases – in three cases in association with erythrophagocytosis.

Moderate multifocal infiltration of macrophages containing crystalline brown-black pigment was present in 5% (1/20) of cases.

80% (16/20) of these lymph nodes contained multifocal, variably sized cystic spaces and/or dilated sinuses.

Multifocal parasitic granulomas were present in one case (5%). These were characterised by numerous eosinophils and reactive macrophages surrounding microfilarial parasite remnants. Moderate fibrosis was associated with these parasitic lesions.

In two further cases (Nos. 9 and 19) there was multifocal granulomatous inflammation, not conclusively associated with parasites or pigment/crystalline material. Scattered multinucleate giant cells were present in one of these cases.

1.1.2.3. Axillar lymph nodes (Table 1.4)

Axillary lymph node samples from 20 out of 23 cases were available for histological evaluation. In 30% (6/20) of cases there was moderate to severe atrophy of the lymph node cortex and moderate to severe paracortical atrophy was present in 35% (7/20) of cases – mostly in cases showing moderate to severe cortical atrophy. Moderate to marked follicular hyperplasia was present in 10% (2/20) of cases and moderate concurrent paracortical hyperplasia was present in one of these cases. Moderate to severe medullary plasmacytosis was noted in 25% (5/20) of cases and involved atrophic nodes in four cases and a mildly hyperplastic node in one case. Moderate to severe sinus histiocytosis was present in 35% (7/20) of cases – three instances in hyperplastic nodes and four in atrophic nodes. Mild to moderate erythrophagocytosis was present in 30% (6/20) of cases.

University of Pretoria etd – Ide, A (2005)

In 40% (8/20) of cases there was mild to severe infiltration of eosinophils indiscriminately involving all areas of the nodes. 10% (2/20) of cases showed mild to moderate neutrophil infiltration and in one case mixed infiltration of neutrophils and eosinophils was noted. None of these lymph nodes showed haemosiderin pigmentation. Mild to moderate accumulation of crystalline pigment was present in 30% (6/20) of cases, predominantly intracytoplasmic in clusters of macrophages, randomly scattered within the lymph node tissue.

Single to multiple, variably sized cystic spaces were present in 70% (14/20) of cases, with random involvement of all areas of the nodes. In most of these cases there was concurrent dilatation of sinuses.

Microfilarial parasites were present in 10% (2/20) of cases and associated mild, multifocal granulomatous inflammation was noted in one of these cases. Severe eosinophilia was also present in this particular node (No. 4).

1.1.2.4. Inguinal lymph nodes (Table 1.5)

Inguinal lymph node samples from 13 of the 23 cases were available for evaluation. In 38% (5/13) of cases there was moderate cortical atrophy and moderate paracortical atrophy was noted in 46% (6/13) of cases. In most cases cortical and paracortical atrophy occurred concurrently. Only 15% (2/13) of cases showed significant follicular hyperplasia and there was no evidence of paracortical expansion in any of these nodes. Moderate to severe plasmacytosis of the medullary cords was present in 38% (5/13) of cases and only atrophic nodes showed evidence of plasmacytosis. Moderate to severe sinus histiocytosis was also present in 38% (5/13) of cases and affected both atrophic and hyperplastic nodes. Mild to moderate erythrophagocytosis was present in 23% (3/13) cases – two in cases showing moderate to marked sinus histiocytosis and one in a case with mild sinus histiocytosis.

Mild to severe infiltration of eosinophils was present in 46% (6/13) of cases and involved all areas of the nodes. In 31% (4/13) of cases there was mild to moderate neutrophil infiltration and a mixed infiltrate was present in 8% (1/13) of cases. Mild haemosiderin pigmentation of medullary sinus histiocytes was present in 23% (3/13)

of cases. Mild, multifocal infiltration of macrophages containing crystalline material was present in 8% (1/13) of cases and in 15% (2/13) of cases there was concurrent haemosiderosis and accumulation of macrophages containing crystalline pigment.

In 85% (11/13) of these lymph nodes multifocal cystic spaces and/or dilated sinuses were present.

Microfilarial parasites were present in 38% (5/13) of cases and in all cases there was associated, multifocal granulomatous inflammation, with or without multinucleate giant cells. Mild, multifocal granulomatous inflammation, with multinucleate giant cells, not obviously associated with parasitic remnants, was present in one case (No.12). Although crystalline pigment was present in this case, the granulomatous inflammation was not necessarily associated with this crystalline material.

1.1.2.5. Popliteal lymph nodes (Table 1.6)

Popliteal lymph node samples from 19 of 23 cases were available for evaluation. In 47% (9/19) of cases there was moderate to severe cortical atrophy and 26% (5/19) of cases showed concurrent paracortical atrophy. Moderate to severe follicular hyperplasia was only present in 16% (3/19) of cases and no paracortical hyperplasia was noted. In 53% of cases there was moderate to marked medullary plasmacytosis, involving predominantly atrophic nodes, but also a single hyperplastic node. Moderate to severe medullary sinus histiocytosis was present in 74% (14/19) of cases and involved both atrophic and hyperplastic lymph nodes. Mild erythrophagocytosis was noted in 12% (2/19) cases.

37% (7/19) of cases showed mild to moderate infiltration by eosinophils, indiscriminately involving all areas of the affected nodes. Neutrophil infiltration was present in 12% (2/19) of cases and a mixed infiltrate was present in another 12% (2/19) of cases. Mild intracytoplasmic haemosiderin pigmentation of medullary sinus histiocytes was present in one case. This node also showed mild erythrophagocytosis. In 32% (6/19) of cases there was mild, multifocal accumulation of crystalline black pigment – both intracellularly in macrophages and extracellularly.

Multifocal cystic spaces and/or dilated sinuses were present in 53% (10/19) of cases.

Scattered microfilarial parasites were present in 16% (3/19) of cases and there was associated infiltration of eosinophils in two cases. Mild to moderate multifocal granulomatous inflammation, with associated multinucleate giant cells was present in 32% (6/19) of cases. This inflammation was associated with accumulation of intracytoplasmic crystalline material in most cases.

1.1.2.6. Bronchial lymph nodes (Table 1.7)

Bronchial lymph nodes from 14 of 23 cases were available for evaluation. Moderate to severe cortical atrophy was present in 29% (4/14) of cases and there was concurrent severe paracortical atrophy in 7% (1/14) of cases. In 21% (3/14) of cases there was moderate to severe follicular hyperplasia and concurrent severe paracortical hyperplasia was noted in 7% (1/14) of cases. Moderate medullary plasmacytosis was present in 21% (3/14) of cases and only involved atrophic lymph nodes. In 29% (4/14) of cases there was moderate medullary sinus histiocytosis, with predominant involvement of atrophic nodes. Mild erythrophagocytosis was only present in 14% (2/14) of cases – both cases in nodes showing moderate sinus histiocytosis.

Mild to severe eosinophil infiltration was present in 36% (5/14) of cases, with neutrophil infiltration noted in 14% (2/14) of cases and a mixed infiltrate present in another 14% (2/14) of cases. Mild haemosiderosis was present in 7% (1/14) of cases and multifocal accumulation of intra- and extracellular crystalline pigment was present in a further 14% (2/14) of cases.

Multifocal cystic spaces and/or dilated sinuses were present in 36% (5/14) of cases.

14% (2/14) of cases contained multifocal microfilarial parasites and in one case (No. 21) these were associated with moderate, multifocal granulomatous inflammation and infiltration of numerous eosinophils. Mild to moderate, multifocal

granulomatous inflammation, not obviously associated with parasites or crystalline material, was present in a further two cases (Nos. 9 and 19).

1.1.2.7. Mesenteric lymph nodes (Table 1.8)

Mesenteric lymph node samples from 13 of 23 cases were available for evaluation. Moderate to severe cortical atrophy was present in 23% (3/13) of cases and there was moderate paracortical atrophy in 31% (4/13) of cases – always in cases with mild to severe cortical atrophy. Moderate follicular hyperplasia was only present in 8% (1/13) of cases and there was no evidence of paracortical hyperplasia. Moderate to severe medullary plasmacytosis was noted in 23% (3/13) of cases and was always present in cases with concurrent atrophic changes. In 54% (7/13) of cases there was moderate to severe sinus histiocytosis, involving predominantly atrophic nodes.

In 69% (9/13) of cases there was moderate to severe infiltration of eosinophils, involving all areas of the nodes. Neutrophil infiltration was only present in 8% (1/13) of cases (No. 9). A mixed infiltrate was present in 8% (1/13) of cases. No haemosiderosis or crystalline material was noted in these lymph nodes.

62% (8/13) of these lymph nodes contained multifocal cystic spaces and/or showed cystic dilatation of sinuses.

Microfilarial parasites were present in 8% (1/13) of cases and there was associated mild eosinophil infiltration. Mild, multifocal granulomatous inflammation, with reactive macrophages and neutrophils and not obviously associated with parasites, was present in 8% (1/13) of cases (No. 9).

1.2. Splenic changes

The majority of splenic samples evaluated (87%) showed mild to marked congestion, totally obliterating the splenic architecture in some of the severely congested samples. Most of these animals were euthanased by means of an

intravenous barbiturate overdose and the severe congestion was attributed to this factor.

Scattered neutrophils were noted in five cases (Nos. 1, 2, 4, 5 and 9) and a few eosinophils were present in 4 cases (Nos. 1, 2, 3 and 4). There was also a mild increase in the number of plasma cells present in the red pulp of five cases (Nos. 8, 9, 11, 20 and 21).

In two cases (Nos. 1 and 8) there was mild extramedullary haematopoiesis and mild to moderate haemosiderosis (mostly within macrophages) was present in a further five cases.

Mild to moderate hyperplasia of the lymphoid nodules was noted in three cases (Nos. 6, 8 and 13) and there was mild to moderate atrophy of the lymphoid nodules in five cases (Nos. 9, 11, 16, 17 and 18).

1.3. Tonsillar changes

Tonsillar samples from only four of the 23 cases were available for evaluation. The samples from Cases nos. 6, 22 and 23 showed mild hyperplasia of the tonsillar follicles. The follicular germinal centres comprised large lymphoid cells, with numerous mitotic figures and scattered tingible body macrophages. These latter two findings suggest increased turnover of lymphoid cells. Mild, multifocal infiltration of neutrophils was present in the surface epithelium of Case no. 6, multifocally extending into deeper tissue.

In Case no. 23 there was severe, multifocal to confluent infiltration of neutrophils – occasionally totally obliterating the surface epithelium. In Case no. 22 the deeper tonsillar tissues was expanded by a few dilated cystic spaces, with no obvious lining epithelium and containing mucus and giant cells, as well as showing some dystrophic mineralization. These changes could be related to dilated salivary ducts, with leakage of saliva into adjacent tissue.

Tonsillar follicles in Case no. 8 were mildly atrophic and similar mild infiltration of the surface epithelium by neutrophils was present.

1.4. Thymic changes

Thymic samples from Cases nos. 2, 4, 6, 7, 8 and 23 cases were available for evaluation. In all samples there was evidence of thymic involution. This was characterised by poor differentiation between the cortex and medulla, with the cortex containing numerous tingible body macrophages phagocytosing apoptotic lymphocyte debris. Within the medulla, the Hassle's corpuscles were poorly defined and occasionally mineralized. Multifocal epithelial rosettes were also evident within the medulla.

Since the animals evaluated were all mature animals of various ages, these thymic changes are assumed to be within normal limits of age-associated thymic involution.

2. Pulmonary changes (Table 2)

Interstitial pneumonia of variable severity and distribution was noted in lung samples from 86% (19/22) of cases (lung tissue not available in one case) (Figure 9). The interstitial pneumonia was characterized by expansion of the alveolar walls by a mixed cell population of macrophages, lymphocytes, plasma cells and variable neutrophils and eosinophils (Figure 9). The infiltrate was invariably chronic, with fibroplasia noted in two cases. Epithelialization of the alveolar walls was present in three cases (Figure 10). The lesions were usually multifocal to confluent. In one case (No. 3), multifocal eosinophilic granulomas were present in the foci of interstitial pneumonia. In another case (No.10), there were multifocal areas of more acute interstitial pneumonia, characterized by mild intra-alveolar haemorrhage and fibrin exudation.

In 27% (6/22) of cases there was multifocal to confluent granulomatous pneumonia (Figure 11). In four of these cases the granulomatous pneumonia was severe and characterized by total obliteration of the alveolar spaces by mixed reactive macrophages, accompanied by lymphocytes, plasma cells and neutrophils (Figure 11).

Occasional multinucleate giant cells were present. The remaining two of the six cases were predominantly of interstitial pneumonia, with multifocal areas of moderate granulomatous or pyogranulomatous pneumonia, with associated necrosis in the latter. Three of the cases with granulomatous pneumonia had multifocal irregular-shaped and sized cystic spaces, “lined” by granulomatous inflammatory tissue, with some attempts at connective tissue capsule formation (Figure 12). The cystic spaces contained neutrophils, reactive macrophages and protein-rich fluid. These lesions were interpreted as bronchiectasis with granulomatous bronchiolitis (Figure 12).

Acid-fast staining (Ziehl-Neelsen)³ of samples in four of the cases (two of them cases with severe granulomatous pneumonia) failed to reveal any acid-fast bacteria.

50% (11/22) of cases contained multifocal *Hepatozoon* spp. schizonts within cells in the alveolar walls. Although the parasites were generally present in areas of interstitial pneumonia, they also occurred in areas where no inflammation was noted.

In one case (No.19) occasional microfilarial larvae were present in the alveolar walls. These larvae were not associated with any significant inflammation.

In 59% (13/22) of cases there was mild to moderate, multifocal anthracosilicosis, i.e. accumulation of clusters of macrophages containing phagocytosed intracytoplasmic crystalline material resembling silica (sand). In some cases (especially No.15), mild granulomatous inflammation was associated with the foci of anthracosilicosis.

In Case no.12, the pulmonary parenchyma was focally expanded by a circumscribed, unencapsulated, nodular adenoma, comprising well differentiated cuboidal epithelial cells arranged in tubules and acini, within a moderate fibrous stroma. There was polarization of the neoplastic cells, with nuclei located towards the basement membrane. The cells had abundant, finely vacuolated, eosinophilic cytoplasm and oval nuclei, with indistinct nucleoli. No mitotic figures were present. Some of the acini were dilated with khaki-coloured, granular material and cell debris. This appearance was consistent with an adenoma of the peribronchial glands. There

was no evidence of peripheral infiltration or metastatic spread in the section examined. This was most likely an incidental finding.

3. Gastro-intestinal tract

3.1. Glossal changes

In five of the cases (Nos. 1, 3, 9, 21 and 23) there was mild, multifocal glossitis, characterised by mild, multifocal, mixed, perivascular infiltration of lymphocytes, plasma cells and occasional neutrophils and eosinophils in the lamina propria. In Case no. 9 there was also multifocal ulceration of the surface epithelium, with associated neutrophil infiltration. In Case no. 21 the inflammation was predominantly associated with superficial mixed bacteria. There was also a localised foreign body reaction to a piece of plant material embedded deep in the muscle of the tongue in this case.

3.2. Gastric changes (Table 3.1)

Gastric samples from 47% (8/17) of cases showed evidence of mild chronic gastritis. This was characterised by mild, multifocal proliferation of lymphoid nodules within the superficial and deep lamina propria. These nodules comprised small lymphocytes. In two cases there was mild proliferation of mixed Gram-positive and Gram-negative bacteria in the superficial mucus and extending into the superficial crypts. Only one of these cases showed concurrent mild chronic gastritis. Warthin-Starry staining³ of a number of cases failed to reveal any spirilliform, *Helicobacter*-like, bacteria.

Two of the cases (Nos. 9 and 22) showed evidence of localised granulomatous inflammation affecting the outer muscle layer and extending into the adjacent peritoneum. The inflammatory reaction was characterised by lymphocytes, macrophages, plasma cells and multinucleate giant cells. Although no causative agents were present in these foci, the nature of the inflammatory response was most consistent with a lesion induced by parasitic migration or foreign body penetration.

In one case (No.11), scattered remnants of nematode parasites (*Physaloptera* spp.) were present superficially within the crypts. These were not associated with any significant inflammation and there was no evidence of chronic gastritis in this case. A few *Hepatozoon* spp. schizonts were present in crypt epithelial cells in one case. These were not associated with any inflammation. In two cases (Nos. 9 and 20) numerous protozoal parasites were present in the epithelium of the pyloric part of the stomach (Figure 13). These appeared to belong to the phylum Apicomplexa and represented various sexual and asexual stages of the parasite's life cycle. The parasites were associated with mild lamina propria fibrosis in both cases.

3.3. Small intestinal changes (Table 3.2)

Small intestinal changes were generally mild and included mild lymphocytic plasmacytic enteritis (15%), characterised by a mild increase in lamina propria plasma cells, as well as mild lamina propria fibrosis and mild atrophy of Brunner's glands (Figure 14). A focal parasitic granuloma comprising parasitic remnants, reactive macrophages and multinucleate giant cells was present within the intestinal wall of one case. In another case there was a focally-extensive area of mucosal and submucosal ulceration and deeper necrosis, with severe neutrophil infiltration and fibrin exudation. The lesion was associated with embedded foreign material. Although these changes were consistent with foreign body penetration, there was no evidence of perforation of the muscularis or serosa in my section.

Scattered Gram-positive coccoid and Gram-negative rod-shaped bacteria were present in the surface mucus and deeper in the crypts of some cases (35%). These bacteria did not appear to be associated with any significant inflammation.

Embedded between the villi of five cases were multiple cestode parasites. These parasites were characterised by a thin cuticle, absence of an intestinal tract and body cavity, a few calcareous corpuscles, multiple eggs (not present in an ovarium) and multiple rostral hooks. Scattered nematode parasites were present between the villi of three cases and in one case multiple trematodes were attached to the mucosal surface (Figure 15). Apart from variable lamina propria eosinophilia in most of these cases, the parasites were not associated with any significant pathology (Figure 14).

3.4. Large intestinal changes (Table 3.3)

Colonic changes were mild and consisted of mild colitis (29% of cases), characterised by a mild increase in the lamina propria connective tissue, with concurrent mild atrophy of the colonic crypts and mild infiltration of neutrophils in some cases. In one of the samples (No. 7) was a focally-extensive area of submucosal fibrin exudation and neutrophil infiltration, with associated haemorrhage. This lesion communicated with the mucosal surface by means of a transmucosal tract. Although no foreign body was present in this lesion, the nature of the lesion is consistent with foreign body penetration. In Case no. 9 there was a focal submucosal pyogranuloma, comprising peripheral macrophages and central degenerate eosinophils. Special stains failed to reveal any infectious organisms in this lesion.

Scattered fine rod-shaped bacteria were present within the colonic crypts of two cases. In one of these cases there was mild lamina propria infiltration of neutrophils. However, in the other case, these bacteria were not associated with any significant inflammation.

4. Pancreas

In one case (No. 18) there was a focal area of interstitial infiltration of lymphocytes, neutrophils, macrophages and eosinophils – mild interstitial pancreatitis. There was no concurrent necrosis of pancreatic tissue

5. Bone marrow changes (Table 4)

Bone marrow samples from 13 of 23 cases were available for evaluation. Bone marrow cellularity ranged from normal to increased, with normal to increased numbers of megakaryocytes (Figure 16). A slight decrease in megakaryocyte numbers was only noted in one case (No. 6).

Most of the sections had myeloid:erythroid ratios within normal limits (1:1 - 2:1). However, in three cases there was an increased M:E ratio and in two a decreased ratio. The increased ratio in Cases nos. 9 and 19 was as a result of a decrease in the

erythroid series. This is consistent with anaemia and may be associated with inflammation. The increased ratio in Case no. 11 was as a result of an increase in the myeloid precursors. This marrow also contained increased numbers of mature neutrophils. This may also be associated with inflammation. In the two cases showing decreased M:E ratios, the decrease was as a result of a decrease in the myeloid precursors. This may be associated with bone marrow suppression.

In all the bone marrow samples there was an increased number of mature eosinophils (Figure 16). Increased numbers of mature neutrophils were evident in five cases. Increased numbers of plasma cells were noted in a number of cases. This is consistent with a humoral immune response. Increased lymphocytes were also present in a few cases.

6. Renal changes (Table 5)

Renal samples from all cases were available for evaluation. In some cases there was mild to moderate congestion of the cortico-medullary blood vessels. Eight cases showed evidence of membranous glomerulonephritis (Figure 18). There was thickening of glomerular basement membranes, cellular proliferation in the glomerular tufts and mild infiltration of the glomeruli by scattered eosinophils and occasional neutrophils (Figure 18). The glomerular changes were mild and generally involved only parts of scattered glomeruli (focal, segmental). In one case there was generalized (all glomeruli) segmental involvement. Despite these glomerular changes there was little evidence of proteinuria in the sections evaluated.

In six of the cases evaluated there was mild to marked amyloidosis (confirmed with Thioflavine T stain).³⁸ In the most severely affected case (No.11) there was almost diffuse obliteration of the medulla by amyloid, with only scattered tubules remaining (Figure 17). In four cases (Nos. 14, 17, 18, and 21) there was mild to moderate, multifocal to confluent amyloidosis of the outer medullary interstitium, with collapse of some tubules in affected areas and dilatation of others. In the remaining case (No. 20) there was multifocal obliteration of glomeruli with amyloid. In some of the remaining glomeruli there was dilatation of Bowman's spaces, with accumulation of proteinaceous fluid and pressure atrophy of glomeruli.

University of Pretoria etd – Ide, A (2005)

In Case no. 9 there was moderate, multifocal to confluent chronic interstitial nephritis involving the cortex and medulla (Figure 18). The lesion was characterised by interstitial fibrosis and infiltration by moderate numbers of plasma cells, with fewer macrophages, lymphocytes and neutrophils (Figure 18). Multifocal wedge-shaped cortical fibrosis was present, with associated tubular collapse, dilatation of Bowman's spaces, pressure atrophy of glomeruli and infiltration of plasma cells. These lesions resembled chronic infarcts. In the superficial medulla there was also multifocal to confluent granulomatous inflammation, characterised by obliteration of the normal architecture by infiltration of reactive macrophages and neutrophils (Figure 19). Ziehl-Neelsen staining³ failed to reveal any acid-fast bacteria in this lesion.

In Case no.19 there was also a focally-extensive area of granulomatous inflammation, effacing the medullary architecture. The inflammatory response comprised reactive macrophages, with admixed neutrophils, plasma cells and lymphocytes. Again, acid-fast staining failed to reveal any bacteria.

7. Cutaneous lesions

Skin samples from only a few of the cases evaluated were available for examination. In only three of these cases were there any significant lesions.

Case no. 9: There was mild epidermal acanthosis and orthokeratotic hyperkeratosis. Some epidermal dyskeratosis was also noted. In the dermis there was mild, mononuclear, superficial perivascular inflammation and moderate pigmentary incontinence. These changes were consistent with a mild chronic dermatitis. In the subcutaneous connective tissue there was a focal area of necrosis, with associated mixed inflammation and vascular thrombosis. Ziehl-Neelsen staining³ failed to reveal any acid-fast organisms in this lesion. The cause of this lesion was not apparent, but previous localised trauma (e.g. foreign body penetration), with possible secondary infection was considered. However, this may also have originated as a primary infectious lesion.

[University of Pretoria etd – Ide, A \(2005\)](#)

Case no.19: Focal, superficial granulomatous dermatitis was associated with embedded plant material. The inflammatory response was characterised by reactive macrophages, multinucleate giant cells and neutrophils. In the subcutaneous tissue there was a focally-extensive area of chronic-active cellulitis, characterised by fibroplasia and infiltration of macrophages (some haemosiderin-laden), plasma cells, neutrophils and lymphocytes. Special stains (PAS, ZN and Gram Twort)³ failed to reveal any infectious agents in this lesion and there was no evidence of foreign material. The cause of this lesion was not certain, but localised trauma or migrating foreign material were considered as possibilities. However, an infectious aetiology could not be excluded with certainty.

Case no. 20: There was mild, diffuse fibrosis of the superficial dermis, with associated mild, multifocal to confluent superficial perivascular infiltration of neutrophils, mast cells, macrophages, lymphocytes and plasma cells. Scattered remnants of microfilarial parasites were present in adjacent tissue, but there was no reaction associated with these parasitic remnants. In the deep dermis there was multifocal to confluent, mainly perivascular infiltration of neutrophils, plasma cells and fewer macrophages (some haemosiderin-laden) and lymphocytes. Also mild haemorrhage and fibroplasia, as well as focal neutrophilic vasculitis. As there was no vasculitis in adjacent tissue, the vasculitis present in this area was assumed to be as a result of the cellulitis, rather than the cause.

In another section of the skin from this case there was severe, focally-extensive epidermal ulceration, with associated neutrophilic inflammation and fibrin exudation (Figure 20). Numerous large coccoid bacteria were present in the exudate. Similar coccoid bacteria were also present in superficial hair follicles (Figure 20). These changes were those of a localised superficial pyoderma, with ulceration. Another lesion in the skin of this animal was severe, multifocal to confluent granulomatous deep dermatitis. The inflammatory lesion comprised numerous reactive macrophages, with admixed plasma cells and neutrophils. No infectious agents were demonstrated with PAS, ZN or Gram Twort stain.³

8. Ocular lesions

Samples from both eyes of 18 of the 23 cases examined were available for evaluation.

The samples from Cases nos. 22 and 23 were too autolysed or distorted for interpretation. No abnormalities were noted in either eye from Cases nos. 1, 2, 4, 5, 6, 7, 12, 20 and 21.

Case no. 8 showed mild, focal lymphocytic conjunctivitis in both eyes. In Case no. 3 there was mild, focal lymphoplasmacytic infiltration of the iris of one eye (mild anterior uveitis), whereas the other eye was normal. In Case no. 10 there was mild, multifocal, perivascular lymphoid infiltration in the ciliary body of one eye (mild anterior uveitis) (Figure 21), whereas the other eye was normal. Similarly, one of the eyes from both Cases nos. 11 and 18 showed mild, multifocal, mainly perivascular lymphoplasmacytic infiltration of the iris (mild anterior uveitis). Both the other eyes in these cases were normal or showed artefactual changes.

In one of the eyes from Case no. 9 there were *Trichinella* spp. parasites present in the peri-ocular muscles. There was no reaction associated with these parasites and the rest of this eye, as well as the other eye were normal.

One of the eyes from Case no. 19 showed severe, diffuse infiltration and obliteration of the bulbar conjunctiva, iris, choroid, retina and ciliary body by numerous macrophages, neutrophils, lymphocytes and plasma cells (Figure 22). The posterior chamber contained similar cells and necrotic debris, as well as fibrin (Figure 22). There was hyphaema and the retina had disintegrated. Fragments of the lens capsule were evident. These were curled suggesting rupture of the lens capsule, with release of lens material into the eye. Although the panophthalmitis present in this eye may well have been associated with this ruptured lens, *Mycobacterium bovis* was also cultured from this eye. The other eye from this case showed moderate, focally-extensive infiltration of the choroid by macrophages, neutrophils, lymphocytes and plasma cells (choroiditis/posterior uveitis). There was also

vacuolation of the central part of the optic nerve in this case, suggesting Wallerian degeneration.

9. Skeletal muscle changes (Table 6)

Skeletal muscle samples from 15 cases were evaluated. Most of the samples showed mild, multifocal, interstitial infiltration of plasma cells, lymphocytes, macrophages and occasional neutrophils (Figure 23). In some cases the inflammation was associated with mild degeneration (Figure 23) or necrosis of muscle fibres, with occasional foci of regeneration present in two cases. In all samples the inflammation seemed to be associated with either *Sarcocystis* spp. sarcocysts, *Hepatozoon* spp. (Figure 23) schizonts or *Trichinella* spp. However, in many areas these parasites were present without any significant inflammation, degeneration or necrosis of muscle fibres.

In two cases (Nos. 20 and 22) there was mild, multifocal variation in muscle fibre diameter, with mild angulation of scattered smaller fibres. These changes were consistent with mild muscle fibre atrophy.

In 11 of the 23 cases evaluated, changes were present in samples from the tongue. In most of the samples there were variable *Sarcocystis* spp sarcocysts, *Hepatozoon* spp. schizonts and *Trichinella* spp. present in the striated muscle of the tongue. These parasites were not associated with any significant inflammation. In Cases nos. 7, 8, 10, 11, 22 and 23 there was mild variation in the diameter of some bundles of striated muscle fibres, with angulation of the fibres and increased eosinophilia (Figure 24). These changes are consistent with mild muscle atrophy and the histological nature most suggestive of neurogenic (denervation) atrophy.

10. Myocardial changes (Table 7)

Myocardial samples from all 23 cases were available for evaluation. Multifocal *Hepatozoon* spp. cystozoites and schizonts were present in samples from 21 of these cases. In some areas these parasitic structures elicited mild, multifocal infiltration of plasma cells, lymphocytes and macrophages (mild myocarditis), with occasional

degeneration of scattered myofibres. However, in other areas they seemed to be totally innocuous and not associated with any inflammation.

In two cases (Nos. 11 and 21) there was mild, multifocal to confluent interstitial fibrosis (mostly subendocardial). The presence of increased interstitial connective tissue was confirmed with Masson's Trichrome stain.³ In Case no. 21 the fibrosis was associated with mild myocarditis. However, in Case no.11 there was no concurrent inflammation.

Sarcocystis spp. sarcocysts were present in only one case and were not associated with any inflammation or myofibre degeneration.

11. Hepatic changes (Table 8)

Changes noted in the hepatic tissue samples were generally mild and non-specific. Mild to moderate congestion of sinusoids and blood vessels was present in all samples. This was attributed to euthanasia by means of intravenous barbiturate overdose. In most cases there were multiple, small, disseminated foci of mild inflammation scattered throughout the parenchyma (Figure 25). These inflammatory foci were characterised by macrophages, lymphocytes and plasma cells, with fewer admixed eosinophils and neutrophils (Figure 25). Occasional apoptotic hepatocytes were present in these foci. The cause of this mild, multifocal granulomatous hepatitis was not apparent in the sections examined, but a parasite is a possibility.

In eight cases there was mild, multifocal periportal infiltration of variable numbers of lymphocytes, plasma cells, neutrophils and eosinophils. In a few cases this inflammation was associated with mild periportal fibrosis. The cause of this inflammation was not apparent in my sections, but association with ascending infection from the intestinal tract was a consideration.

In three cases there was evidence of mild, multifocal infiltration of the sinusoids by eosinophils and/or neutrophils. This could be interpreted as a mild reactive hepatitis and may have been associated with systemic infection. In three cases there was also mild, multifocal extramedullary haematopoiesis.

12. Central nervous system changes (Table 9)

Multiple sections of the spinal cord, brain stem, cerebrum and cerebellum from most cases were evaluated. It must be noted that as far as could be ascertained, none of these animals showed clinical signs suggesting pathology of the nervous system.

Mild, multifocal perivascular haemorrhage involving the grey matter of the spinal cord was noted in Cases nos. 3 and 6 and there was similar mild perivascular haemorrhage in the brain stem of Case no. 7, as well as locally in the pia mater covering the cerebellum in this case. There was mild congestion involving the blood vessels in the cerebrum, cerebellum and brain stem in Cases nos. 8 and 10. Multifocal mineralization of the dura mater of the spinal cord was present in Case no. 5. This case also showed multifocal mineralization of the wall of some of the blood vessels of the choroid plexus. There was no associated inflammation. These changes are occasionally seen in older animals and are not of any clinical significance.

Wallerian degeneration (secondary demyelination), characterised by scattered vacuolated spaces containing swollen axons or myelinophages (digestion chambers on longitudinal sections) was present in spinal cord sections from a few cases (Figure 26). In Case no. 20 the changes were moderate and predominantly involved the ventral tracts of the spinal cord. In Cases nos. 6, 18 and 19 the changes were very mild and involved dorsal and lateral tracts (No. 6), and ventral tracts (Nos. 18 and 19).

In Case no. 8 there was a segmental area of the spinal cord, showing moderate, multifocal infiltration of the meninges and surrounding adipose tissue by macrophages, neutrophils and fibroblasts. These changes were consistent with moderate localised meningitis (Figure 27). The cause of this inflammatory lesion was not apparent.

In the cerebrum of Case no. 18 there were multifocal, small, irregular “cystic” spaces containing “gitter cells” (macrophages phagocytosing myelin) and proliferating astrocytes (Figure 28). These changes were consistent with encephalomalacia.

13. Thyroid

Thyroid samples from four of the cases evaluated (Nos. 7, 10, 18 and 23) showed similar mild, multifocal interstitial infiltration of lymphocytes – mild lymphocytic thyroiditis. There was no concurrent atrophy of thyroid follicles or other abnormalities.

Immunohistochemical staining for lymphocyte subsets was done on frozen tissue sections from various lymph nodes of Cases nos. 1, 2, 3, 4, 18, 19 and 20.

The staining pattern and distribution of the various monoclonal antibodies was as follows:

Anti-feline T lymphocyte marker (572):

Staining: Intracytoplasmic, finely granular, evenly distributed, dark brown staining, with clear outlining of the cell margins. Some light brown, non-specific staining of connective tissue was present.

Distribution: Lymph node paracortex and scattered cells in the follicular mantles, follicular centres and medullary cords (Figure 29).

Anti-feline CD4 lymphocyte marker (MAE38):

Staining: Intracytoplasmic, finely granular, evenly distributed, dark brown staining, with clear outlining of the cell margins. Scattered individual cells stain very dark brown. There was some light brown non-specific staining of connective tissue.

Distribution: Lymph node paracortex and scattered cells in the follicular mantles, follicular centres and medullary cords (Figure 30).

Anti-feline CD8 lymphocyte marker (117):

Staining: Intracytoplasmic, evenly distributed, coarsely granular, dark brown staining, with fairly clear outlining of cell margins. Some lighter brown non-specific staining was present in connective tissue.

Distribution: Lymph node paracortex and scattered cells in the follicular mantles, follicular centres and medullary cords (Figure 31).

Anti-B lymphocyte marker (B5):

Staining: Intracytoplasmic, evenly distributed, generally coarsely granular, dark brown staining, with some outlining of the cell margins. Non-specific light brown staining of connective tissue was present.

Distribution: Predominantly follicular centres, with scattered cells in the follicular mantles and medullary cords staining, as well as occasional cells in the paracortex (Figure 32).

Results of the staining intensity and distribution are reported in Tables 10.1 – 10.7.

Although the lymph nodes evaluated ranged from hyperplastic through normal to atrophic, staining patterns and intensity within the different zones were essentially similar. With all the markers, staining in follicular centres was variable depending on whether the follicles were primary (without germinal centres) or secondary (with germinal centres).

The anti-feline T lymphocyte marker showed generally marked staining of the paracortex, regardless of whether the lymph nodes were atrophic, hyperplastic or normal. Mild to moderate staining of scattered cells was present in the follicular mantles, as well as in follicular centres. In the latter, staining in primary follicles (without a germinal centre) was generally absent, fairly diffuse in small secondary follicles, and limited to the pole facing the subcapsular sinus in larger secondary follicles. Moderate staining of scattered cells was present in the medullary cords.

The anti-feline CD4 lymphocyte marker showed generally moderate to marked staining of the paracortex and mild to moderate staining of scattered cells in the follicular mantles and centres. The staining pattern in the follicular centres was similar to that described for the pan-T cell marker above. Staining of cells in the medullary cords was mild to moderate. In the axillar node from Case no. 20 there appeared to be a general decrease in CD4 positive lymphocytes in all zones. This was a severely atrophic lymph node.

The anti-feline CD8 lymphocyte marker showed moderate to marked staining of the paracortex. Staining in the follicular mantle was generally mild, with generally no staining in the follicular centres. This was regardless of whether the nodes were normal, atrophic or hyperplastic. Staining in the medullary cords was mild to moderate.

University of Pretoria etd – Ide, A (2005)

When comparing the cells staining with the pan-T lymphocyte marker, with those staining CD4 and CD8 positive, an interesting observation was that a fairly large population of the T lymphocytes stained CD4 and CD8 negative. This suggests that many of the T lymphocytes in these lion lymph nodes may be gamma/delta T cells or null cells.

The B lymphocyte marker confirmed absence of B lymphocytes in the paracortex, with mild to moderate staining of scattered cells in the follicular mantles. There was marked staining in all follicular centres and moderate to marked staining in the medullary cords.

The distribution of the staining pattern with all cell markers used in this study was as expected in lymph node tissue. Although the lymph nodes used in the immunohistochemistry study were all from FIV positive lions, there was no notable difference in distribution or numbers of the various lymphocyte subsets.

SEROLOGY FOR FELINE IMMUNODEFICIENCY VIRUS (Table 11)

Serological evaluation for feline immunodeficiency virus (FIV) was done on samples from 17 of the 23 cases in this study. The evaluation was done using a puma lentivirus ELISA and a puma lentivirus Western Blot. Previous studies have confirmed that these tests are more reliable in serum samples from lions when compared to the standard domestic cat FIV ELISA or FIV Western Blot (personal communication: Prof. M. van Vuuren).

Of the 17 animals tested 65 % (11/17) tested positive with both tests and 24% (4/17) tested negative with both tests (table 11). In Case no. 15 a negative result was obtained with the ELISA test and an inconclusive result with the Western Blot. Case no. 21 tested positive with the ELISA and negative with the Western Blot.

It is suggested that the puma lentivirus ELISA test is a good screening test for FIV in populations of wild felids where the virus is endemic.⁵⁹ On the other hand the puma lentivirus Western Blot test is a good test for confirmation of infection in borderline cases (personal communication: Prof. M. van Vuuren).

MYCOBACTERIAL CULTURE (Table 12)

Mycobacterial culture was done on lung and/or lymph node samples from 13 of the 23 cases in this study.

Of the 13 cases cultured only Nos. 19 and 20 tested positive, whereas Nos. 1, 5, 6, 7, 8, 9, 10, 11, 21, 22 and 23 all tested negative

This study documents the salient histopathology findings in a group of Kruger National Park (KNP) lions suffering from chronic debility, compared with histopathology findings in a control group of clinically healthy KNP lions. The study also relates these findings to serological evidence of infection with Feline Immunodeficiency Virus (FIV) and evidence of mycobacterial infection. A further part of this study involved immunohistochemical staining to determine the distribution of lymphocyte subsets in frozen lymph node samples from these animals (both clinically healthy animals and animals suffering from chronic debility). To the best of my knowledge this is the first histological study undertaken in such a group of free-living African lions suffering from chronic debility.

The most significant histological changes were noted in the lymphoid organs and predominantly affected the lymph nodes. Although six of the animals in this study appeared clinically healthy, similar changes were present in lymph nodes from clinically healthy animals as well as from animals suffering from chronic debility. The lymph node changes were that of generalized lymphoid hyperplasia (predominantly affecting clinically healthy animals), progressing through combined hyperplasia and atrophy in other animals, to lymphoid atrophy affecting most of the lions suffering from chronic debility. These lymph node changes are consistent with an initial reactive response, affecting primarily the follicular centres and thus representing a B cell response, with apparent progression to depleted nodes. Although the changes are non-specific and may be associated with various conditions: e.g. canine distemper,^{34,45} toxoplasmosis,³⁵ and feline panleukopenia;⁵² similar changes have been described in domestic cats suffering from Feline Immunodeficiency Virus (FIV) infection^{5,10,11,16,17,41,44,47} and in humans suffering from Human Immunodeficiency Virus (HIV) infection.^{6,43,46}

Both hyperplastic and atrophic nodes from some animals showed increased plasma cells in the medullary cords. This is consistent with altered regulation of the B cell response in these animals. Although increased plasma cells is a common finding in reactive lymph nodes, this finding has also been described in lymph nodes from FIV infected domestic cats.^{10,44,47} Another, relatively consistent finding in most

lymph nodes was erythrophagocytosis by the medullary sinus histiocytes. This has also been described in domestic cats with FIV.^{10,44} An interesting finding in this study was that plasmacytosis and erythrophagocytosis predominantly affected lions that tested serologically positive for FIV.

The lymph node changes present in the majority of the lymph nodes from most of the animals in this study are consistent with a compromised immune system.

The presence of cystic spaces and dilated sinuses was a consistent finding in most nodes from both clinically healthy animals and animals suffering from chronic debility. The cause of this cystic dilatation is not certain, but cystic sinus dilatation of lymph nodes is seen with partial blockage of lymph drainage. Most of the animals showed variable infiltration of microfilarial parasites in the lymph nodes. These parasites were usually associated with eosinophilia and occasionally with eosinophilic granulomatous inflammation. It is possible that the parasites may be contributing to partial blockage of draining lymphatics – either through granulomatous inflammation or through the physical presence of the parasites within the draining lymphatics.

Crystalline material (intra- and extracellular) with or without associated granulomatous inflammation was a frequent finding in lymph nodes from many of the animals. The nature and significance of this birefringent crystalline material is not certain, but similar changes have been described in lymph nodes from dogs.¹³ Dogs affected by granulomatous lymphadenopathy associated with mineral deposition also suffered from a range of systemic illnesses. Day *et al*¹³ speculate that the inflammatory response induced by the mineral deposits in the lymph nodes from these animals may trigger altered immunoregulation, with subsequent development of a range of diseases. The clinical significance of this finding in the lymph nodes from free ranging lions is not certain, but it is possible that it may contribute to altered immunoregulation in a similar fashion to that speculated in dogs. Further investigation into the nature and origin of this material may shed some light on the significance of this finding.

Granulomatous inflammation was a relatively common finding in many of the lymph nodes. In most instances it could be attributed to the presence of microfilarial

[University of Pretoria etd – Ide, A \(2005\)](#)

parasites and/or crystalline material. However, in one case (No.19) granulomatous inflammation also affected other organ systems, like the lungs, kidneys, subcutis and eyes. *Mycobacterium bovis* was cultured from various affected organs from this case and the widespread granulomatous inflammation is attributed to disseminated tuberculosis. In another case (No. 9), suffering from multicentric granulomatous inflammation, of no obvious histological cause, no *Mycobacterium* spp. was cultured, and the source of this granulomatous disease is not certain. An infectious aetiology remains most likely. Further investigation using polymerase chain reaction (PCR) technology may reveal an infectious agent, including *Mycobacterium* spp..

Variable lymphoid hyperplasia and atrophy noted in the spleen and tonsils are likely to be a reflection of the changes present in the lymph nodes, although the changes were far less consistent and much milder. Follicular depletion in the spleen has been described in domestic cats with FIV.¹⁷

The granulomatous pneumonia and associated bronchiectasis present in Case no.19 was attributed to *Mycobacterium bovis* infection and formed part of the multicentric tuberculosis described in this animal. However, in a number of other cases, severe granulomatous pneumonia with or without associated bronchiectasis and no apparent cause, was present. A parasitic cause is possible, although no obvious parasites were associated with this inflammation. This type of inflammatory response may also be related to fungal infection (no fungi were demonstrated) or inhalation of foreign material (apart from anthracosilicosis associated with very mild accumulation of macrophages, no other obvious aspirated foreign material was found). As *Mycobacterium bovis* is an increasingly common pathogen in KNP lions,^{21,22} this has to remain the primary differential diagnosis of this granulomatous pneumonia. It is possible that the samples submitted for mycobacterial culture from these lesions were not fully representative, hence the negative culture results.

Chronic interstitial pneumonia was a fairly consistent finding in lung samples. Although *Hepatozoon* spp. schizonts were present in some areas of interstitial pneumonia, they also occurred in non-inflamed areas. It is not certain whether or not these protozoan parasites are the actual cause of the interstitial pneumonia, as chronic interstitial pneumonia may be caused by various different aetiologies, e.g. mild,

multifocal interstitial pneumonia was described in lions suffering from canine distemper virus.^{34,45} Lesions consistent with chronic interstitial pneumonia have also been described in domestic cats suffering from FIV.¹⁰

Mild, predominantly lymphoid, glossitis was noted in a few cases. Although bacterial infection was noted in one of the cases in association with ulceration, this infection may have been secondary. The glossitis may have been attributed to trauma. The glossitis with ulceration was present in a case suffering from severe renal amyloidosis (No. 21) and may have been related to uraemia resulting from chronic renal failure. Chronic glossitis/stomatitis is a common occurrence in domestic cats and has been associated with immunosuppression in cats infected with FIV.^{5,10,40} There was no vesicle formation consistent with feline calicivirus infection, although this virus has been isolated from lions in the KNP previously.⁵⁸ None of the lesions were severe enough to the extent that it would have significantly affected feeding.

The mild tonsillitis noted in a few of cases may have been related to the oral inflammation, or to primary bacterial infection.

Mild chronic gastritis was a relatively consistent finding in most of the animals. This is a relatively non-specific lesion and may be caused by various factors and may also not be of clinical significance. Factors that may be related to development of chronic gastritis in domestic cats include allergic disease, treatment with NSAIDs, mycotic gastritis, parasitic gastritis, toxicity, uraemia and infection with *Helicobacter* spp. bacteria. Of all these, the only likely possible causes in free-ranging lions include, parasites, uraemia and infection with *Helicobacter* spp.. In the animals with chronic gastritis, the renal changes noted (glomerulonephritis and chronic interstitial nephritis) were mild and there were no other changes consistent with uraemia. Only one of the cases with renal amyloidosis had chronic gastritis. In two cases protozoan parasites, apparently belonging to the phylum Apicomplexa were associated with signs of mild chronic gastritis. It appears that these parasites may be significant, and further identification and determination of the role of these parasites in chronic gastritis may be of value. Faecal shedding of coccidian oocysts has been reported from captive and free-ranging lions, but has not been deemed clinically significant.^{7,30} Although Warthin Starry staining³ failed to reveal *Helicobacter*-like bacteria in the

gastric samples, the possibility of *Helicobacter* spp. infection in these cases cannot be excluded completely, as it is possible that the samples may not have been fully representative. In a previous study, gastric spiral bacteria were found in 30% of lions in the Etosha National Park and were regarded as commensals.²⁴ However, another study involving captive wild felids concluded that *Helicobacter pylori*-like and *Helicobacter*-like organisms may be an important cause of chronic gastritis in lions.¹⁸ Based on this evidence, the possibility of *Helicobacter*-like organisms being a cause of chronic gastritis in KNP lions should be further investigated.

Mild lymphocytic plasmacytic enteritis was present in 15% of cases. This is a very non-specific finding, which can be associated with an underlying immune mechanism in domestic cats. Non-specific chronic diarrhoea and lymphocytic plasmacytic enteritis have been associated with FIV infection in domestic cats.^{5,10,17,47} Mild colitis noted in many of the cases is another non-specific finding, but has also been described in domestic cats infected with FIV.^{17,47}

Bone marrow changes included a decrease in the erythroid series in Cases nos. 9 and 19. These two cases both showed granulomatous inflammation in various organs and *Mycobacterium bovis* was isolated from No.19. This suggests that the decrease in erythroid series may be related to chronic inflammation in these two cases. An increase in myeloid precursors noted in Case no. 11 may well have been the result of an increased demand for neutrophils in circulation, associated with inflammation (although no obvious inflammatory focus was noted in the tissue samples evaluated from this case). A decrease in myeloid precursors was present in Cases nos. 21 and 22, however, there was a marginal increase in mature neutrophils. Haematology results for these cases were not available to determine if there was a circulating neutropenia. The bone marrow picture in these cases was suggestive of a consumptive neutropenia. A similar bone marrow picture has been seen in domestic cats infected with FIV.¹¹ It should be noted however that serological testing for FIV in Case no. 21 gave an inconclusive result (positive with the ELISA and negative with the Western Blot) and there was a negative result on both tests for Case no. 22. This suggests that there may have been another cause for these bone marrow changes and it may be worthwhile evaluating further bone marrow samples and blood samples from KNP lions to determine if similar changes can be attributed to a specific cause. The

increased number of mature eosinophils present in the bone marrow sections of many of the cases is attributed to the fairly heavy parasite burdens in most of these animals (e.g. microfilaria and intestinal cestodes, nematodes and trematodes).

Glomerulonephritis noted in some cases could not be attributed to any specific underlying condition and occurred in both FIV positive and negative lions, as well as in lions infected with *Mycobacterium bovis* and those not infected. The glomerulonephritis was mild and there was no evidence of significant proteinuria in the renal sections, suggesting that this may have been an incidental finding, rather than a clinically significant one. Renal amyloidosis was a feature in six cases. In most of these cases the amyloid deposition was medullary, as is most commonly seen in domestic cats. Glomerular amyloidosis was a feature in the single one of these cases with *Mycobacterium bovis* infection (No. 20). The amyloidosis was most likely of the reactive systemic type. Renal amyloidosis has been reported as an incidental necropsy finding in a lion suffering from tuberculosis.²² Splenic amyloidosis has been described in domestic cats suffering from FIV, in concurrence with marked lymphoid follicular atrophy.¹⁷

Chronic interstitial nephritis was only present in Case no. 9, which also showed multifocal chronic infarction and granulomatous nephritis (in conjunction with multifocal granulomatous inflammation affecting various other organ systems). Various infectious agents - both viral and bacterial may cause chronic interstitial nephritis - but an infectious agent is very rarely identified in naturally occurring disease. Chronic interstitial nephritis is a feature of domestic cats infected with FIV.¹⁷

Chronic dermatitis, granulomatous dermatitis, pyoderma and cellulitis were noted in samples from a few cases evaluated. These lesions were essentially non-specific, although granulomatous dermatitis affected one lion with tuberculosis (No.19) and one case had multifocal granulomatous disease of uncertain aetiology (No. 9). Chronic dermatitis may be caused by various factors, e.g. bacterial infection, parasites, allergic disease or trauma. However, non-specific chronic dermatitis has also been described in domestic cats suffering from FIV- usually as a result of secondary infection.⁵

University of Pretoria etd – Ide, A (2005)

The most significant ocular changes present in cases where eye samples were available for evaluation, were lymphocytic conjunctivitis and non-suppurative anterior uveitis. Nonsuppurative uveitis may be a manifestation of immune-mediated uveitis, ocular trauma, viral and mycotic uveitis, phacolytic uveitis, *Leishmania* spp, infection and uveitis accompanying intraocular neoplasia. Non-suppurative lymphocytic plasmacytic conjunctivitis and/or anterior uveitis have been described in domestic cats infected with FIV.^{5,11,14,40,41} The severe granulomatous panophthalmitis in Case no. 19 was attributed to infection with *Mycobacterium bovis*, which was isolated from the affected eye.

Mild, multifocal mononuclear inflammation was present in liver samples from most cases. The infiltrates were generally randomly scattered throughout the parenchyma, but involved the periportal areas in some sections. This non-specific multifocal inflammation was mild and unlikely to have been clinically significant. Although it may have resulted from parasitic infection, similar changes have been described in liver sections from domestic cats infected with FIV.¹⁰

Changes in the skeletal muscle were mild and generally consisted of mild inflammatory changes associated with various parasites present (*Sarcocystis* spp., *Hepatozoon* spp. and *Trichinella* spp.). The cause of mild atrophy of skeletal muscle fibres in two cases was not apparent, but these changes were unlikely to have been clinically significant. Of more concern is the presence of mild, but relatively consistent, atrophy of striated muscle fibres in the tongue samples of 6 of the cases. The nature of the atrophy is most suggestive of denervation atrophy. This type of muscle atrophy may be related to injury of the nerve supplying the affected muscle group, and less frequently, lesions of the spinal cord or brain. Although there is evidence of mild Wallerian degeneration in the spinal cord sections from some cases evaluated, these changes did not correlate with cases suffering from atrophy of the glossal muscles. The cause of this denervation atrophy is not apparent, but it is possible that this may have affected feeding in these animals and further investigation into an underlying cause is advisable, including evaluation of the nerves innervating the tongue muscle (N. hypoglossus – 12th cranial nerve) for any evidence of pathology.

University of Pretoria etd – Ide, A (2005)

Wallerian degeneration (secondary demyelination) was present in spinal cord sections from a few cases. This lesion was mild and generally appeared to be segmental and variably involved dorsal, lateral and ventral tracts. The cause of this demyelination was not evident, but possible considerations include heavy metal toxicity, trauma or an idiopathic condition. Although none of the animals in this study showed obvious clinical neurological deficits, the changes were mild and may not have presented as clinical signs as yet. These changes are some cause for concern and should be borne in mind if any evidence of unexplained neurological disease is noted in this lion population. Unfortunately no peripheral nerve samples were available for evaluation in this study, but future histological assessment of peripheral nerves should be considered in any further studies undertaken in this lion population.

Multifocal encephalomalacia was noted in Case no. 18. This is a non-specific finding in the central nervous system and may be related to various causes, e.g. trauma, vascular accidents or inflammation. More specifically, it is seen in thiamine deficiency, salt poisoning, mycotoxicosis and lead poisoning in domestic animals and has been described in toxoplasmosis in lions.³⁵

Although 6% of KNP lions tested positive for canine distemper virus (CDV) in a previous study,⁵⁸ there were no histological changes consistent with CDV infection in the animals in this study. Although there is serological evidence of toxoplasma in various lion populations in South Africa,³⁰ there was no histological evidence of toxoplasmosis in any of the animals in this study. However, the possibility of these conditions causing clinical disease in the KNP lions cannot be excluded. Immunohistochemical staining for toxoplasma oocysts and canine distemper virus inclusion bodies in nervous tissue from KNP lions should be undertaken to evaluate the clinical significance of these pathogens.

The lymphocytic thyroiditis in four cases was mild and multifocal and there was no obvious concurrent atrophy of thyroid follicles. However, lymphocytic thyroiditis in domestic animals may be a cause of hypothyroidism and it may be worthwhile evaluating thyroid hormone levels in free-ranging lions to determine if there is any evidence of hypothyroidism.

University of Pretoria etd – Ide, A (2005)

The parasite load - intestinal nematodes, cestodes and trematodes, as well as protozoa and microfilaria - in these animals was generally fairly high. This may be a normal feature in free-ranging lions, but there is a possibility that the load may be higher than normal as a result of immunocompromise.

Immunohistochemical staining of frozen lymph node sections of some of the animals were done to determine if there were any abnormalities in the ratio and distribution of lymphocyte subsets. We have managed to successfully perform immunohistochemical staining to differentiate lion T lymphocytes and B lymphocytes, as well as distinguish between helper (CD4+) and cytotoxic/suppressor (CD8+) T lymphocytes. No significant changes in the ratios or distribution of the cell subtypes were noted in this study, although it should be noted that all the animals that were included in the immunohistochemical study were serologically positive for FIV. These findings reflect those of a previous study on the CD4:CD8 ratio in FIV positive and negative lions, where there did not appear to be a significant decrease in the numbers of these cells in FIV positive lions.⁵¹ However, further immunohistochemical studies comparing lymph nodes from FIV positive and FIV negative lions should be undertaken to confirm these findings.

The animals labelled as “poor doers” in this particular study were suffering from vague illthrift, which could not be attributed to any specific pathological process by histology. A similar clinical presentation of vague illthrift has been reported in domestic cats infected with FIV.^{40,41,47} In domestic cats feline immunodeficiency virus infection is divided into five stages. The first or acute stage presents clinically as cyclic neutropenia, fever and lymphadenopathy.^{16,41} The mortality rate in this stage is low, but animals go on to become lifelong carriers of the virus.⁴¹ The second stage is an asymptomatic carrier (AC) stage during which no clinical signs are evident, but some immunologic abnormalities evolve.^{16,41} Immunologic abnormalities noted during this stage include a decrease in the number of circulating CD4+ T lymphocytes, depression of the CD4+:CD8+ T lymphocyte ratio and decreased lymphocyte blastogenic response to pokeweed mitogen and conA.⁴¹ The third stage involves persistent generalized lymphadenopathy (PGL) and is characterised by vague signs of disease including recurrent fever, leukopenia, anaemia, unthriftiness, anorexia, weight loss and non-specific behavioural

changes.^{16,41} Stage four involves the so-called AIDS related complex (ARC) and generally involves chronic secondary infections of one or more parts of the body.^{16,41} Animals generally present with weight loss, chronic enteritis, chronic upper respiratory tract disease, chronic gingivitis/stomatitis, chronic skin infections and sometimes lymphadenopathy.^{16,41} Cats in stage four of the disease usually decline over months or years to eventually develop a condition analogous to human AIDS.^{16,41} These cats often have severe weight loss and opportunistic infections of multiple body sites, as well as anaemia and pancytopenia.^{16,41} Opportunistic infections which have been associated with FIV infection include rodent poxvirus, feline calicivirus, FeLV, feline herpesvirus, toxoplasmosis, *Streptococcus canis* infection, cryptococcosis, candidiasis, generalized demodectic or notoedric mange, mycobacteriosis and haemobartonellosis.⁴¹ Miscellaneous disorders which have been related to FIV infection in domestic cats include: 1) neurological abnormalities, which can represent a direct effect of the virus on brain cells, or a manifestation of opportunistic infection; 2) inflammatory disease of the eye (predominantly anterior uveitis); 3) renal disease; 4) immunologically mediated disorders (Coombs-positive anaemia and arthritis) and 5) various malignancies (lymphoma, myeloproliferative disease, various solid carcinomas and sarcomas).^{12,41}

Previous serological studies undertaken in the lion population of the KNP,^{30,49,58} as well as this current study have confirmed that there is a high seroprevalence of FIV in these lions. Another finding confirmed in this study is the presence of tuberculosis, caused by *Mycobacterium bovis* in some of these animals. Tuberculosis in free-ranging lions in the KNP was confirmed for the first time in 1995.²² The predominant source of infection is infected African buffalo (*Syncerus caffer*) carcasses.^{21,22} Since 1995 the prevalence of tuberculosis in the KNP lion population has been steadily increasing (personal observation and personal communication: Dr D.F Keet), as confirmed by tuberculin testing. The question arises as to whether the presence of FIV infection in this lion population may be making the lions more susceptible to *Mycobacterium bovis* infection, as would have been the case otherwise.

University of Pretoria etd – Ide, A (2005)

In conclusion, the histopathological changes found in both clinically healthy animals, as well as animals suffering from chronic debility in this study group, are generally of a similar, non-specific nature and not consistent with any one disease syndrome. Although many of the changes are similar to changes described in domestic cats infected with feline immunodeficiency virus – predominantly those in the AIDS related complex (ARC) stage of the disease – the changes are sufficiently non-specific so as not to confirm the clinical significance of seropositivity for FIV in these lions. However, histological changes in many of the “poor doer” animals in this study are consistent with a compromised immune system. The cause and significance (if any) of this immunocompromise is not certain, but the fact that most of these animals were serologically positive for FIV raises the suspicion that FIV in free ranging African lions may not be a totally innocuous infectious agent. Future assays of lymphocyte function in this population of lions may reflect more adequately on the nature of the immunocompromise present.

1. Anderson E C 1995. Morbillivirus infections in wildlife (in relation to their population biology and disease control in domestic animals). *Veterinary Microbiology* 44:319-332.
2. Appel M J G, Summers BA 1995. Pathogenicity of morbilliviruses for terrestrial carnivores. *Veterinary Microbiology* 44: 187-191.
3. Bancroft J D, Stuenens A 1996. Theory and Practice of Histological Techniques, 4th edition, Churchill Livingstone Inc., Hong Kong.
4. Barr M C, Calle P P, Roelke M E, Scott F W 1989. Feline immunodeficiency virus infection in nondomestic felids. *Journal of Zoo and Wildlife Medicine* 20: 265-272.
5. Bennett M, Smyth N R 1992. Feline immunodeficiency virus: A brief review. *British Veterinary Journal* 148: 399-412.
6. Biberfeld P, Porwit-Ksiazek A, Böttiger B, Morfeldt-Månsson L, Biberfeld G 1985. Immunohistopathology of lymph nodes in HLTV-III infected homosexuals with persistent adenopathy or AIDS. *Cancer Research (Supplement)* 45: 4665s-4670s.
7. Boomker J, Penzhorn B L, Horak I G 1997. Parasites of lions (*Panthera leo*) and leopards (*Panthera pardus*): A documentation. *Proceedings of a Symposium on lions and leopards as game ranch animals: Wildlife Group of the South African Veterinary Association, Onderstepoort, South Africa, 24-25 October 1997*:131-142.
8. Brown E W, Miththapala S, O'Brien S J 1993. Prevalence of exposure to feline immunodeficiency virus in exotic felid species. *Journal of Zoo and Wildlife Medicine* 24: 357-364.
9. Brown E W, Yuhki N, Packer C, O'Brien S J 1994. A lion lentivirus related to feline immunodeficiency virus: Epidemiologic and phylogenetic aspects. *Journal of Virology* 68: 5953-5968.
10. Brown P J, Hopper C H, Harbour D A 1991. Pathological features of lymphoid tissues in cats with natural feline immunodeficiency virus infection. *Journal of Comparative Pathology* 104: 345-355.

11. Callanan J J, Thompson H, Toth S R, O'Neil B, Lawrence C E, Willett B, Jarrett O 1992. Clinical and pathological findings in feline immunodeficiency virus experimental infection. *Veterinary Immunology and Immunopathology* 35: 3-13.
12. Callanan J J, Jones B A, Irvine J, Willett B J, McCandlish I A P, Jarrett O 1996. Histologic classification and immunophenotyping of lymphosarcoma in cats with naturally and experimentally acquired feline immunodeficiency virus infection. *Veterinary Pathology* 33: 264-272.
13. Day M J, Pearson G R, Lucke V M, Lane S J, Sparks R S J 1996. Lesions associated with mineral deposition in the lymph node and lung of the dog. *Veterinary Pathology* 33: 29-42.
14. English R V, Davidson M G, Nasisse M P, Jamieson V E, Lappin M R 1990. Intraocular disease associated with feline immunodeficiency virus infection in cats. *Journal of the American Veterinary Medical Association* 196: 1116-1119.
15. Greenwood A G 1985. Diagnosis and treatment of botulism in lions. *Veterinary Record* 117: 58-60.
16. Ishida T, Tomoda I 1990. Clinical staging of feline immunodeficiency virus infection. *Japanese Journal of Veterinary Science* 52: 645-648.
17. Ishida T, Taniguchi A, Matsumura S, Washizu T, Tomoda I 1992. Long-term clinical observations on feline immunodeficiency virus infected asymptomatic carriers. *Veterinary Immunology and Immunopathology* 35: 15-22.
18. Jakob W, Stolte M, Valentin A, Schröder H D 1997. Demonstration of *Helicobacter pylori*-like organisms in the gastric mucosa of captive exotic carnivores. *Journal of Comparative Pathology* 116: 21-33.
19. Kadoi K, Kiryu M, Iwabuchi M, Kamata H, Yukawa M, Inaba Y 1997. A strain of calicivirus isolated from lions with vesicular lesions on the tongue and snout. *New Microbiology* 20: 141-148.
20. Keet D F, Kriek N P J, Huchzermeyer H, Bengis R G 1994. Advanced tuberculosis in an African buffalo (*Syncerus caffer*). *Journal of the South African Veterinary Association* 65: 79-83.
21. Keet D F, Kriek N P J, Penrith M -L, Michel A, Huchzermeyer H 1996. Tuberculosis in buffaloes (*Syncerus caffer*) in the Kruger National Park: spread of the disease to other species. *Onderstepoort Journal of Veterinary Research* 63: 239-244.

University of Pretoria etd – Ide, A (2005)

22. Keet D F, Kriek N P J, Penrith M-L, Michel A 1997. Tuberculosis in lions and cheetahs. *Proceedings of a Symposium on lions and leopards as game ranch animals: Wildlife Group of the South African Veterinary Association, Onderstepoort, South Africa, 24-25 October 1997*: 151-156.
23. Kennedy-Stoskopf S, Gebhard D G, English R V, Spelman L H, Briggs M 1994. Clinical implications of feline immunodeficiency virus infection in African lions (*Panthera leo*): Preliminary findings. *Proceedings of the American Association of Zoo Veterinarians and Association of Reptilian and Amphibian Veterinarians Annual Conference, Pittsburgh, USA, 22-27 October 1994*: 345-346.
24. Kinsel M J, Briggs M B, Venzke K, Forge O, Murnane R D 1998. Gastric spiral bacteria and intramuscular sarcocysts in African lions from Namibia. *Journal of Wildlife Diseases* 34: 317-324.
25. Letcher J D, O'Conner T P 1991. Incidence of antibodies reacting to feline immunodeficiency virus in a population of Asian lions. *Journal of Zoo and Wildlife Medicine* 22: 324-329.
26. Lopez-Rebollar L M, Penzhorn B L, De Waal D T, Lewis B D 1999. A possible new piroplasm in lions from the Republic of South Africa. *Journal of Wildlife Diseases* 35: 82-85.
27. Lutz H, Isenbügel E, Lehmann R, Sabapara R H, Wolfensberger C 1992. Retrovirus infection in non-domestic felids: serological studies and attempts to isolate a lentivirus. *Veterinary Immunology and Immunopathology* 35: 215-224.
28. Macdonald D W 1996. Conservation biology. Dangerous liaisons and disease. *Nature* 379: 6564.
29. McCully R M, Basson P A, Bigalke R D, De Vos V, Young E 1975. Observations on naturally acquired hepatozoonosis of wild carnivores and dogs in the Republic of South Africa. *Onderstepoort Journal of Veterinary Research* 42: 117-133.
30. Meltzer D G A 1997. Disease overview of large felids. *Proceedings of a Symposium on lions and leopards as game ranch animals: Wildlife Group of the South African Veterinary Association, Onderstepoort, South Africa, 24-25 October 1997*: 143-150.
31. Mochizuki M, Hiragi H, Sueyoshi M, Kimoto Y, Takeishi S, Horiuchi M, Yamaguchi R 1996. Antigenic and genomic characteristics of parvovirus isolated from a lion (*Panthera leo*) that died of feline panleukopaenia. *Journal of Zoo and Wildlife Medicine* 27: 416-420.

32. Müller-Graf C D, Woolhouse M E, Packer C 1999. Epidemiology of an intestinal parasite (*Spirometra* spp.) in two populations of African lions (*Panthera leo*). *Parasitology* 118: 407-415.
33. Munson L 1991. Strategies for integrating pathology into single species conservation programs. *Journal of Zoo and Wildlife Medicine* 22: 165-168.
34. Munson L, Roelke-Parker M E, Carpenter M, O'Brien S J, Mwamengele G L M, Packer C, Appel M J G 1997. Canine distemper in East African lions (*Panthera leo*). *Proceedings of a Symposium on lions and leopards as game ranch animals: Wildlife Group of the South African Veterinary Association, Onderstepoort, South Africa, 24-25 October 1997*: 157-162.
35. Ocholi R A, Kalejaiye J O, Okewole P A 1989. Acute disseminated toxoplasmosis in two captive lions (*Panthera leo*) in Nigeria. *Veterinary Record* 124: 515-516.
36. Olmsted R A, Langley R, Roelke M E, Goeken R M, Adger-Johnson D, Goff J P, Albert J P, Packer C, Laurenson M K, Caro T M, Scheepers L, Wildt D E, Bush M, Martenson J S, O'Brien S J 1992. Worldwide prevalence of lentivirus infection in wild feline species: Epidemiologic and phylogenetic aspects. *Journal of Virology* 66: 6008-6018.
37. Osofsky S A, Hardy W D, Hirsch K J 1994. Serologic evaluation of free-ranging lions (*Panthera leo*), leopards (*Panthera pardus*) and cheetas (*Acinonyx jubatus*) for feline lentivirus and feline leukemia virus in Botswana. *Proceedings of the American Association of Zoo Veterinarians and Association of Reptilian and Amphibian Veterinarians Annual Conference, Pittsburgh, USA, 22-27 October 1994*: 398-402.
38. Osofsky S A, Hirsch K J, Zuckerman B S, Hardy W S 1996. Feline lentivirus and feline oncovirus status of free-ranging lions (*Panthera leo*), leopards (*Panthera pardus*), and cheetahs (*Acinonyx jubatus*) in Botswana: a regional perspective. *Journal of Zoo and Wildlife Medicine* 27: 453-467.
39. Pearse A E G 1984. Histochemistry Theoretical and Applied Vol 2, 4th edition Churchill Livingstone Inc., Hong Kong.
40. Pedersen N C, Yamamoto J K, Ishida T, Hansen H 1989. Feline immunodeficiency virus infection. *Veterinary Immunology and Immunopathology* 21: 111-129.
41. Pedersen N C, Barlough J E 1991. Clinical overview of feline immunodeficiency virus. *Journal of the American Veterinary Medical Association* 199: 1298-1305.

42. Poli A, Abramo F, Cavicchio P, Bandecchi P, Ghelardi E, Pistello M 1995. Lentivirus infection in an African lion: a clinical, pathologic and virologic study. *Journal of Wildlife Diseases* 31: 70-71.
43. Racz P, Tenner-Racz K, Van Vloten F, Schmidt H, Dietrich M, Gluckman J C, Letvin N L, Janossy G 1990. Lymphatic tissue changes in AIDS and other retrovirus infections: tools and insights. *Lymphology* 23: 85-91.
44. Rideout B A, Lowenstine L J, Hutson C A, Moore P F, Pedersen N C 1992. Characterization of morphologic changes and lymphocyte subset distribution in lymph nodes from cats with naturally acquired feline immunodeficiency virus infection. *Veterinary Pathology* 29: 391-399.
45. Roelke-Parker M E, Munson L, Packer C, Kock R, Cleaveland S, Carpenter M, O'Brien S J, Popischil A, Hofmann-Lehmann R, Lutz H, Mwamengele G L M, Mgasa M N, Machange G A, Summers B A, Appel M J G 1996. A canine distemper epidemic in Serengeti lions (*Panthera leo*). *Nature* 379: 441-445.
46. Schuurman H-J, Kluin P M, Meijling F H J G, Van Unnik J A M, Kater L 1985. Lymphocyte status of lymph node and blood in acquired immunodeficiency syndrome (AIDS) and AIDS-related complex disease. *Journal of Pathology* 147: 269-280.
47. Sparger E E 1993. Current thoughts on feline immunodeficiency virus infection. *Veterinary Clinics of North America: Small Animal Practice* 23: 173-191.
48. Spencer J A 1991. Survey of antibodies to feline viruses in free-ranging lions. *South African Journal of Wildlife Research* 21: 59-61.
49. Spencer J A, Van Dijk AA, Horzinek M C, Egberink H F, Bengis R G, Keet D F, Morikawa S, Bishop D H L 1992. Incidence of feline immunodeficiency virus reactive antibodies in free-ranging lions of the Kruger National Park and the Etosha National Park in Southern Africa detected by recombinant FIV p24 antigen. *Onderstepoort Journal of Veterinary Research* 59: 315-322.
50. Spencer J A, Morkel P 1993. Serological survey of sera from lions in the Etosha National Park. *Suid-Afrikaanse Tydskrif vir Natuurnavorsing* 23: 60-61.
51. Spencer J A, Bouic P D, Espie I, Colly L 1995. A comparison between T-helper (CD4) and T-suppressor (CD8) cell ratios in FIV positive and negative lions (*Panthera leo*) and domestic cats (*Felis catus*). *South African Journal of Wildlife Research* 25: 111-112.

52. Studdert M J, Kelly C M, Harrigan K E 1973. Isolation of panleucopaenia virus from lions. *Veterinary Record* 93: 156-159.
53. Sundberg J P, Montali R J, Bush M, Phillips L G, O'Brien S J, Jenson A B, Burk R D, Van Ranst M 1996. Papillomavirus-associated focal oral hyperplasia in wild and captive asian lions (*Panthera leo persica*). *Journal of Zoo and Wildlife Medicine* 27: 61-70.
54. Sundberg J P, Van Ranst M, Montali R, Homer B L, Miller W H, Rowland P H, Scott D W, England J J, Dunstan R W, Mikaelian I, Jenson A B 2000. Feline papillomas and papillomaviruses. *Veterinary Pathology* 37: 1-10.
55. Tubbesing U H 1997. An outbreak of anthrax amongst wild carnivore species held in captivity. *Proceedings of a Symposium on lions and leopards as game ranch animals: Wildlife Group of the South African Veterinary Association, Onderstepoort, South Africa, 24-25 October 1997*: 163-167.
56. VandeWoude S, O'Brien S J, Hoover E A 1997. Infectivity of lion and puma lentiviruses for domestic cats. *Journal of General Virology* 78: 759-800.
57. VandeWoude S, O'Brien S J, Langelier K, Hardy W D, Slattery J P, Zuckerman E E, Hoover E A 1997. Growth of lion and puma lentiviruses in domestic cat cells and comparisons with FIV. *Virology* 233: 185-192.
58. Van Vuuren M, Stylianides E, Du Rand A 1997. The prevalence of viral infections in lions and leopards in Southern Africa. *Proceedings of a Symposium on lions and leopards as game ranch animals: Wildlife Group of the South African Veterinary Association, Onderstepoort, South Africa, 24-25 October 1997*: 168-173.
59. Van Vuuren M, Stylianides E, Kania S S, Zuckerman E E, Hardy W D (Jr) 2001. Evaluation of an indirect enzyme-linked immunosorbent assay for the detection of feline immunodeficiency virus-reactive antibodies in wild felids, employing a puma lentivirus-derived synthetic peptide antigen. *Onderstepoort Journal of Veterinary Research*, submitted.
60. Wood S L, Thomson G W, Haines D W 1995. Canine distemper virus-like infection in a captive African lioness. *Canadian Veterinary Journal* 36: 34-35.

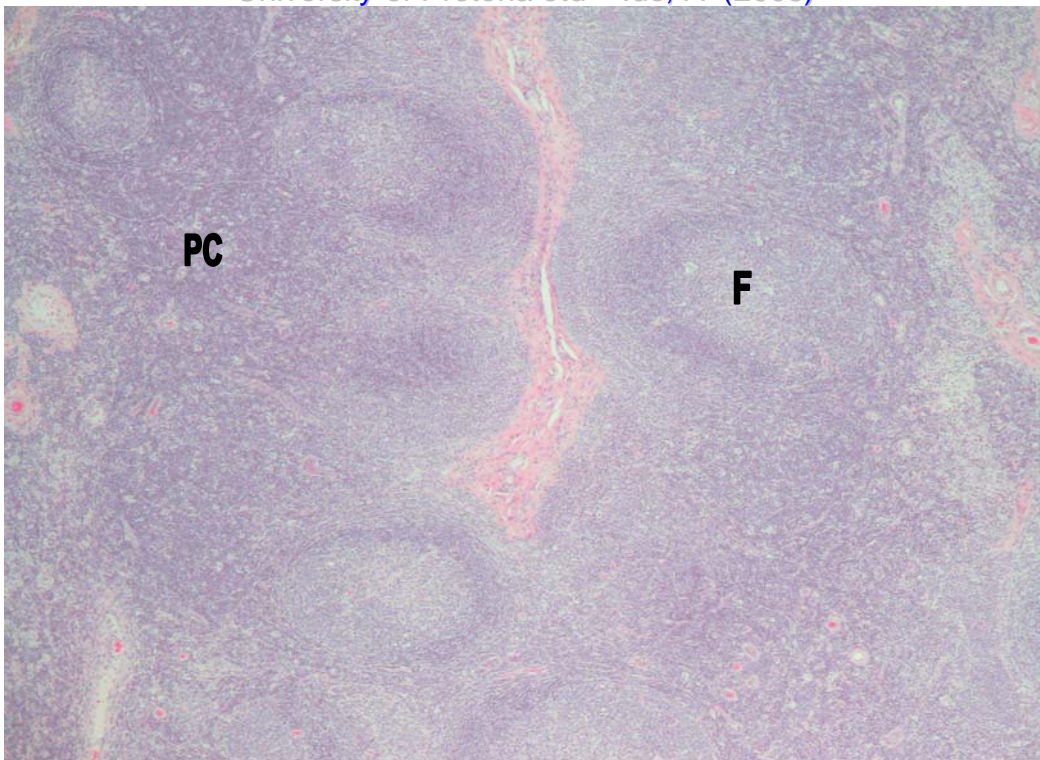


Figure 1: Lymph node – Follicular hyperplasia, with expansion of the follicular germinal centres (F) by large blast cells. Paracortical hyperplasia, with expansion of the paracortex (PC) by small lymphocytes. HE 40x

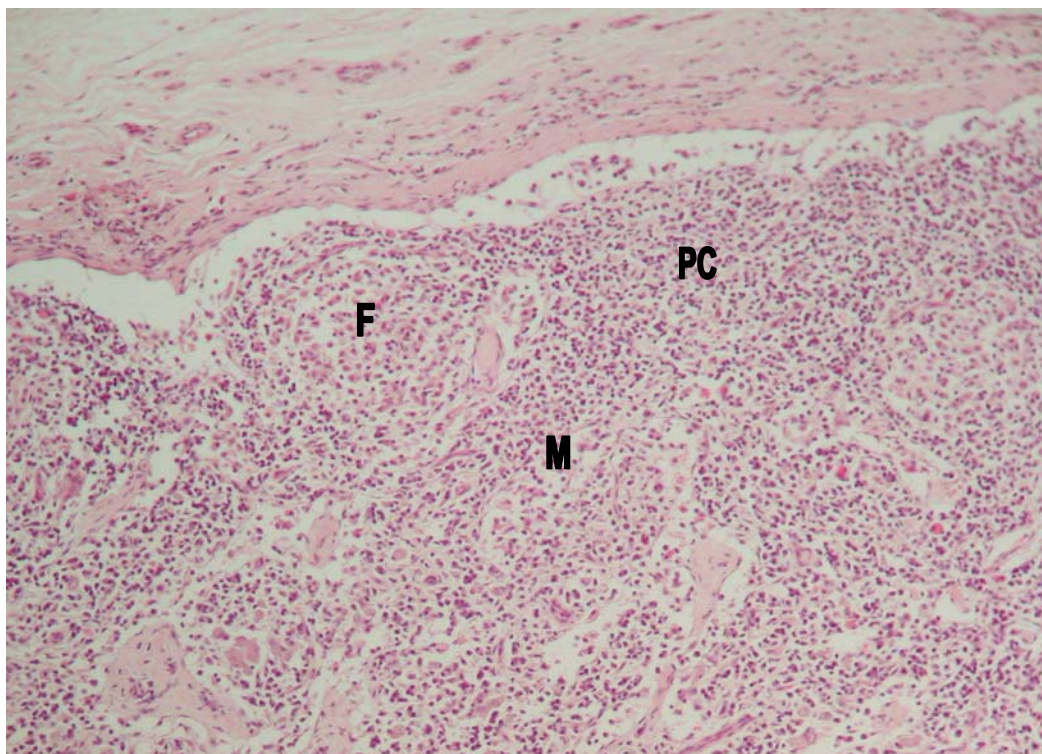


Figure 2: Lymph node – Cortical follicular (F) and paracortical (PC) atrophy, with narrowing of the cortex relative to the medulla (M). HE 100x

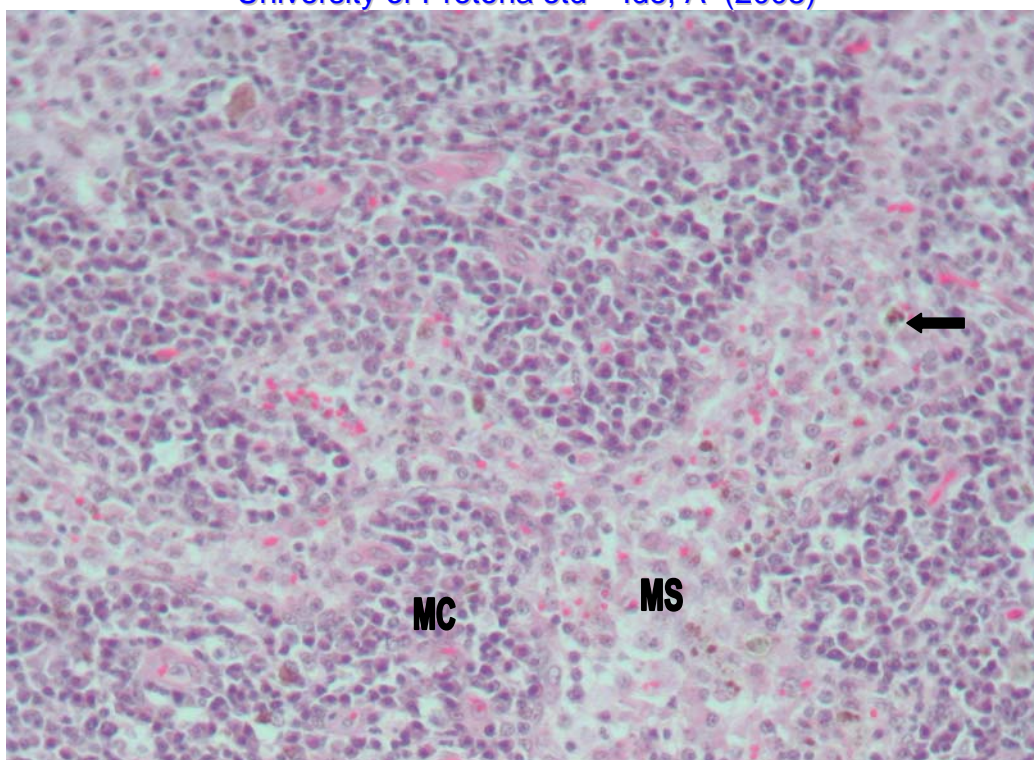


Figure 3: Lymph node – Plasmacytosis of the medullary cords (MC) and sinus histiocytosis of the medullary sinuses (MS). There is also intracytoplasmic haemosiderin accumulation (arrow). HE 200x

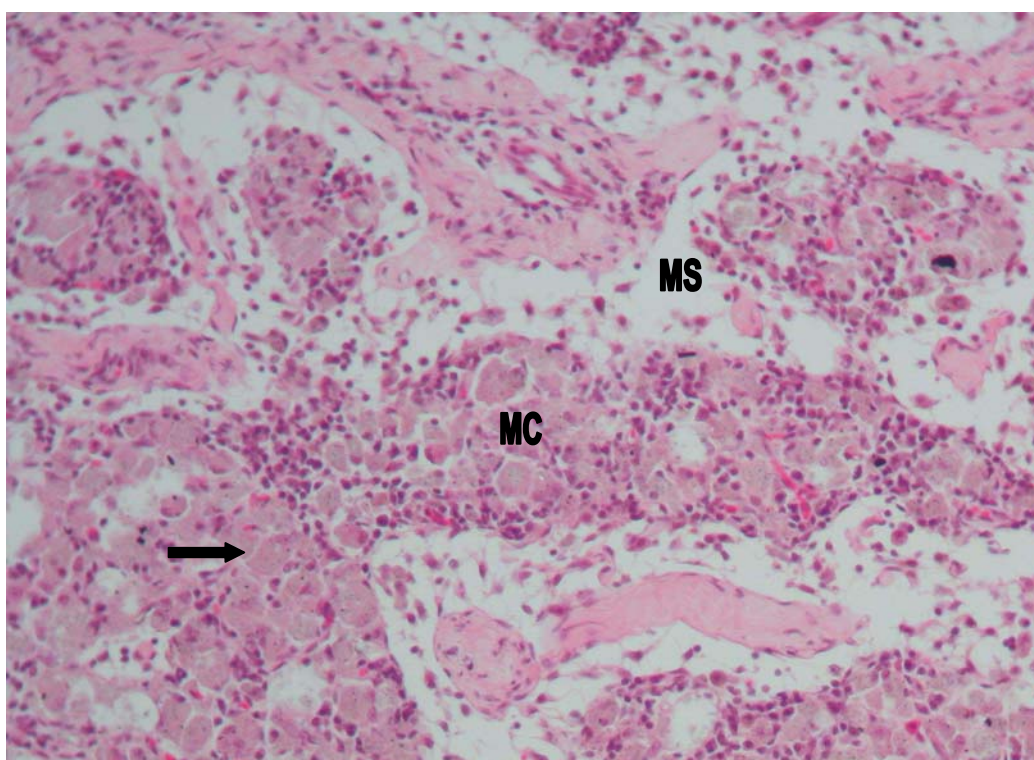


Figure 4: Lymph node – Mineral deposition (arrow) in macrophages within the medullary cords (MC). MS = Medullary sinuses. HE 200x

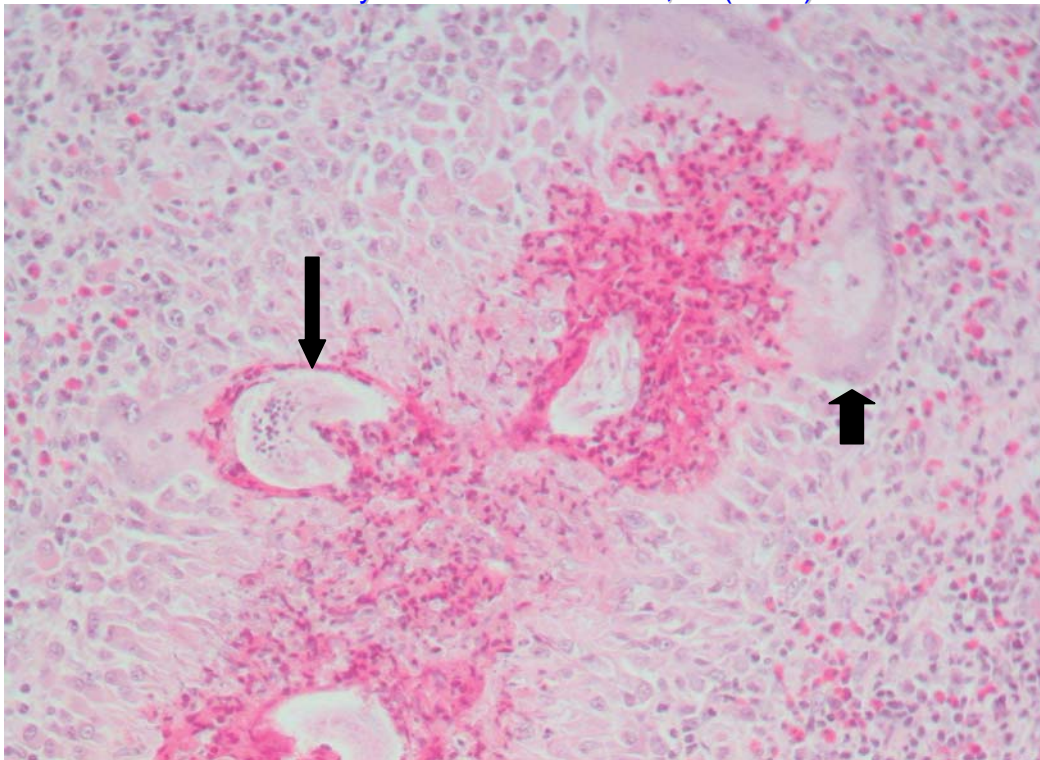


Figure 5: Lymph node – Eosinophilic granuloma with multinucleate giant cells (short arrow), associated with microfilaria larvae (long arrow). HE 100x

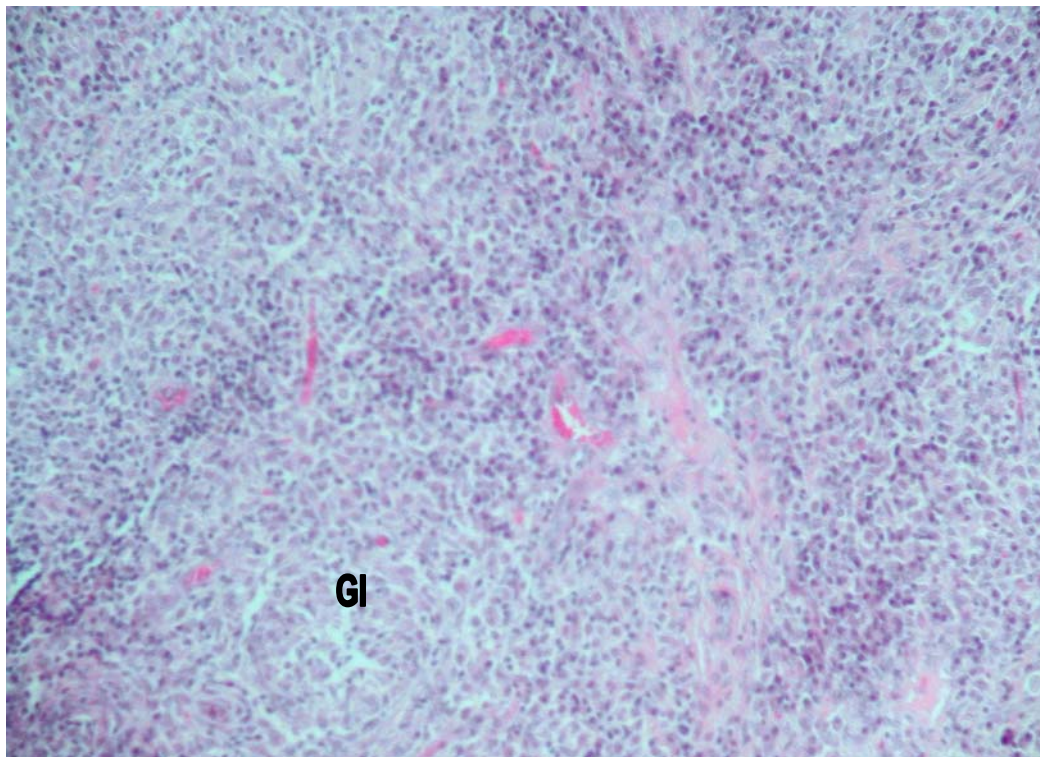


Figure 6: Lymph node – Effacement of the normal lymph node architecture by multifocal to confluent granulomatous inflammation (GI). HE 100x

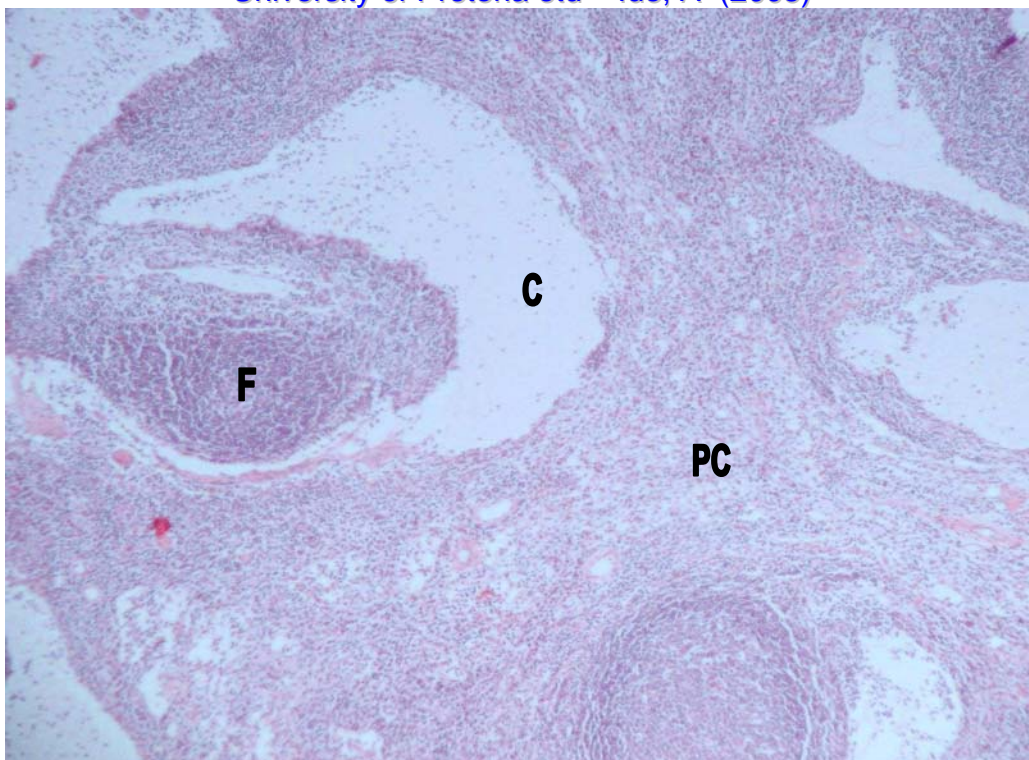


Figure 7: Lymph node – Multifocal cystic spaces (C) expanding the cortex and paracortex (PC) and incorporating lymphoid follicles (F). HE 40x

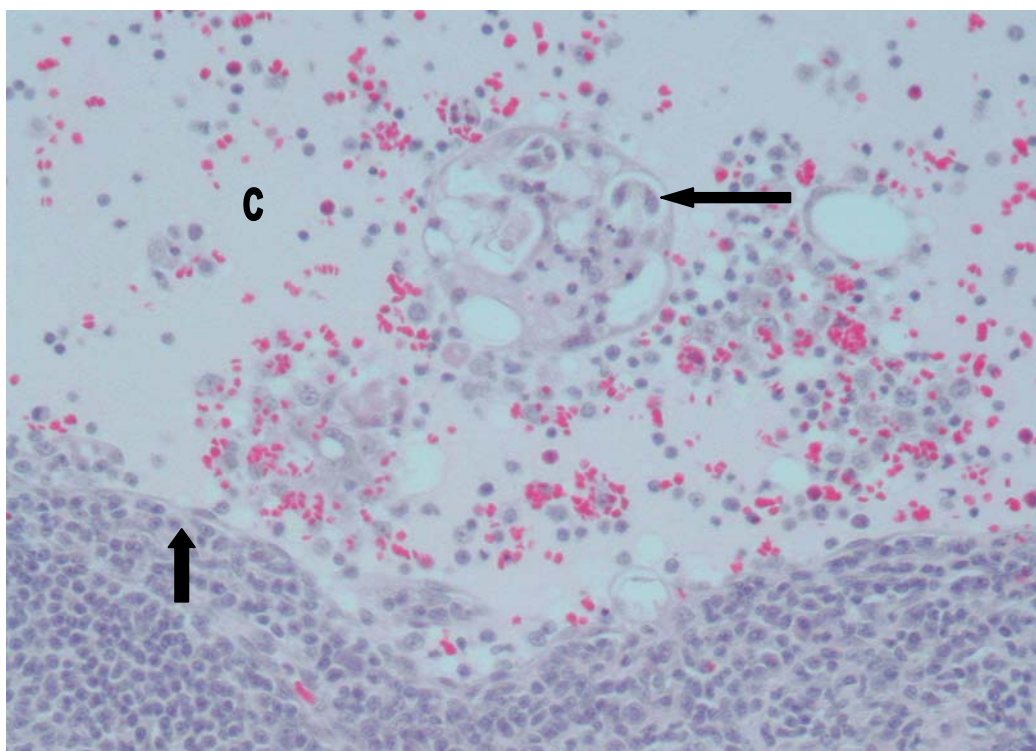


Figure 8: Lymph node – Higher magnification of a cystic space (C), demonstrating an epithelial lining (thick arrow) and content consisting of microfilaria (thin arrow), histiocytes, plasma cells, lymphocytes, eosinophils and histiocytes. HE 200x

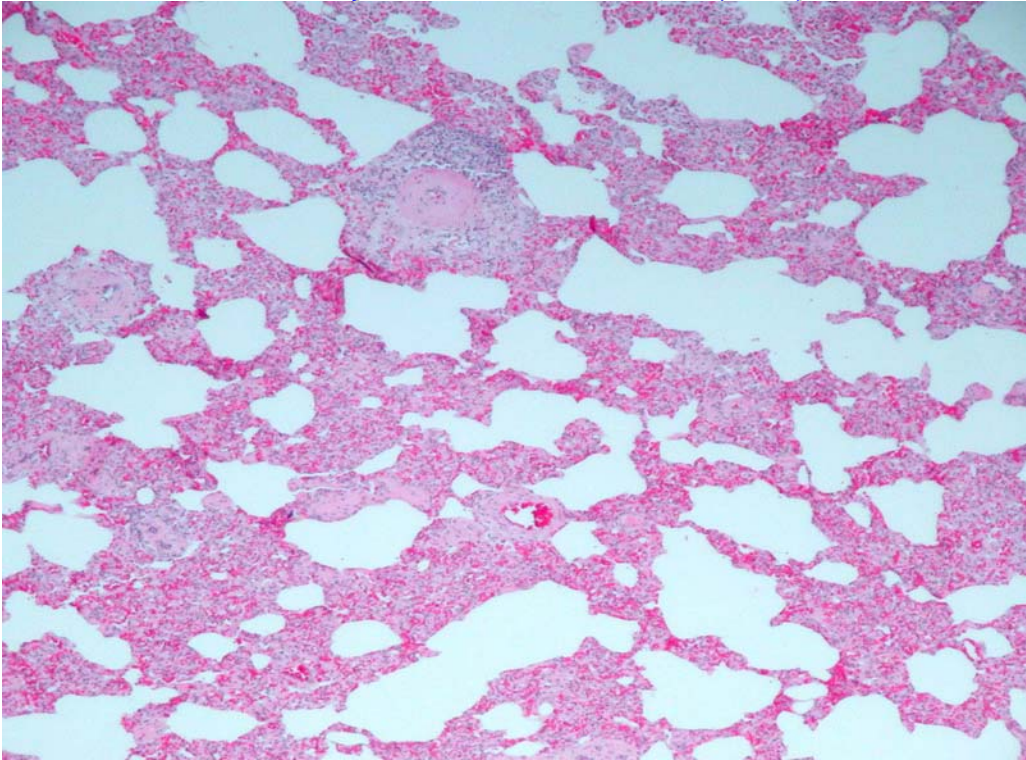


Figure 9: Lung – Chronic interstitial pneumonia with expansion of the alveolar walls by a mixed cell population. HE 40x

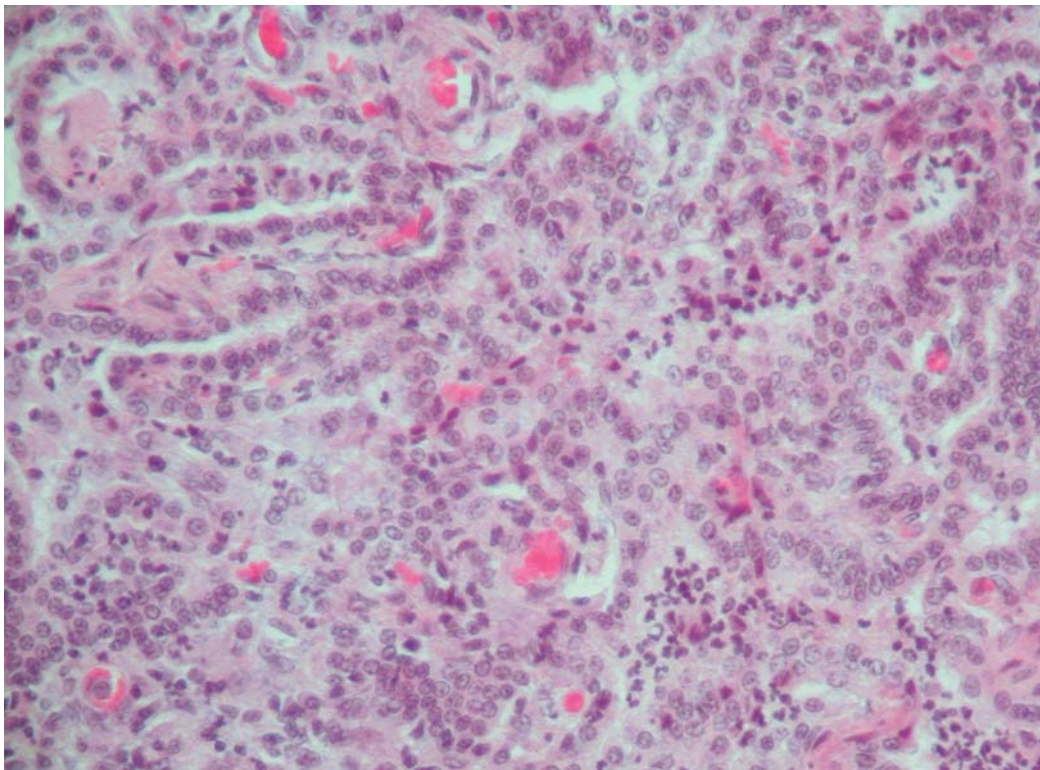


Figure 10: Lung – Chronic interstitial pneumonia with epithelialization as a result of proliferation of type II pneumocytes. There is associated neutrophil infiltration in the alveolar spaces. HE 200x

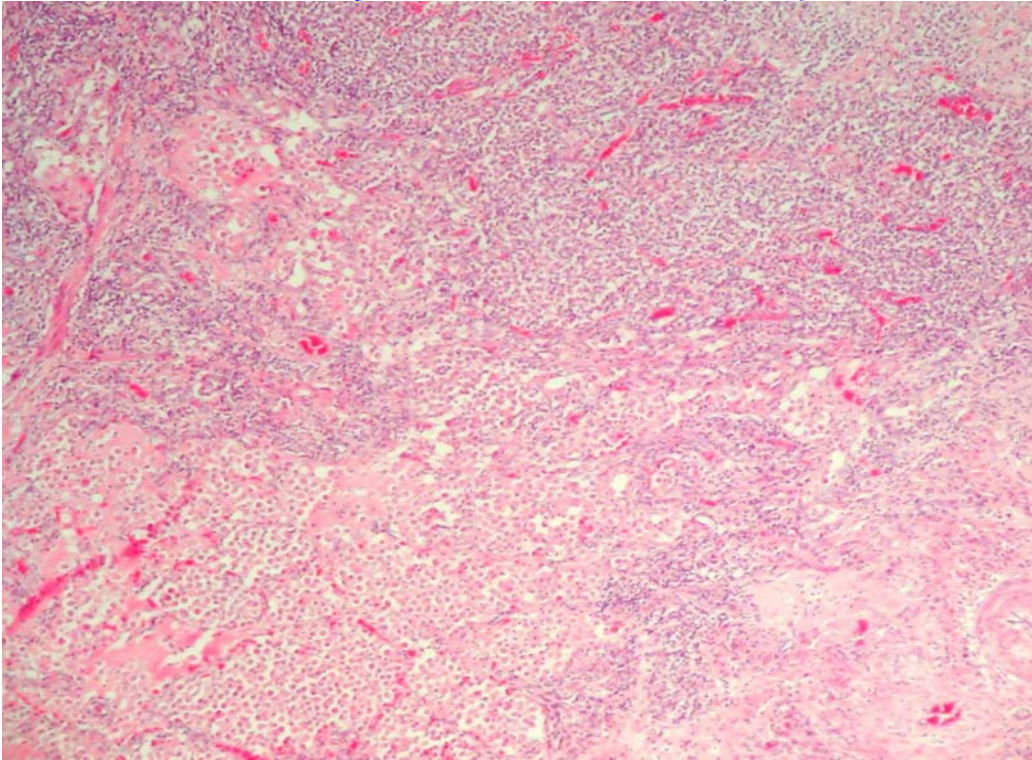


Figure 11: Lung – Granulomatous pneumonia, characterized by effacement of the normal pulmonary architecture by an infiltrate of reactive macrophages and admixed lymphocytes, plasma cells and neutrophils. HE 40x

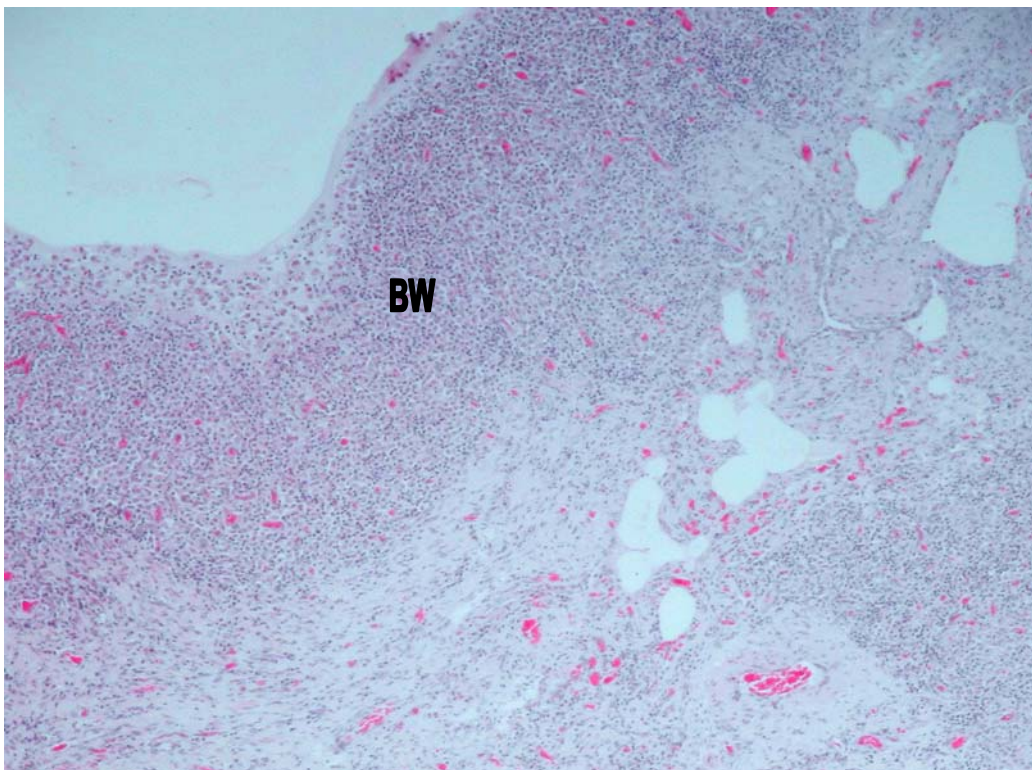


Figure 12: Lung – Granulomatous pneumonia and bronchiectasis, with granulomatous bronchiolitis. BW = Bronchiolar wall. HE 40x

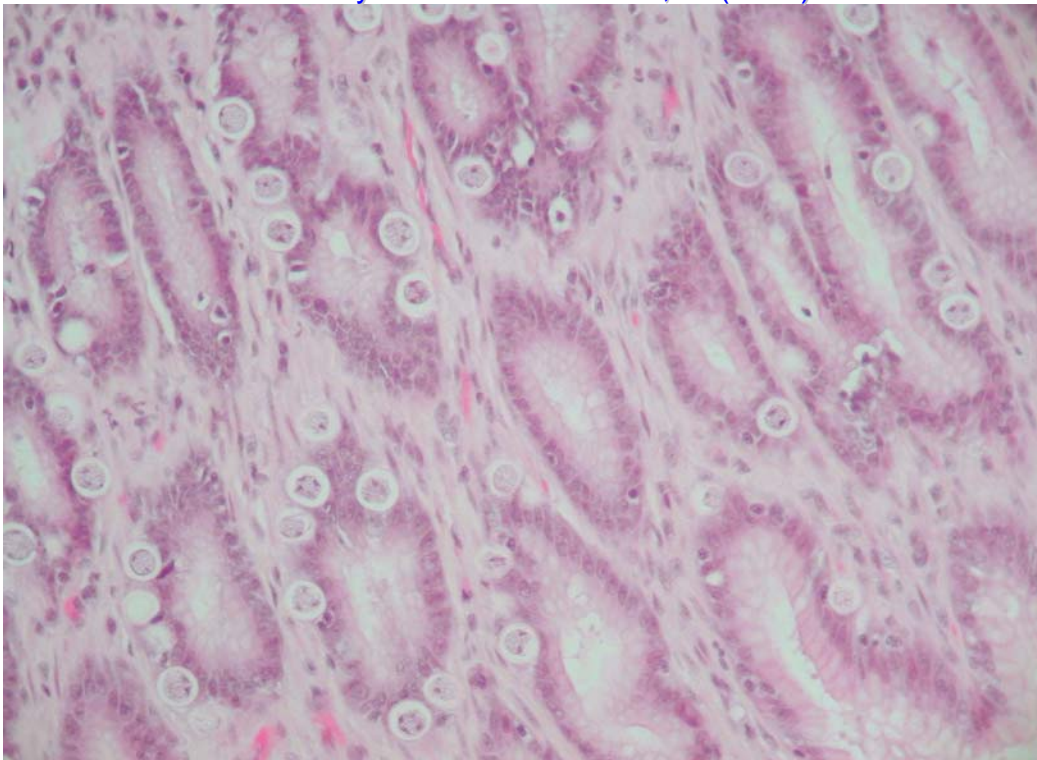


Figure 13: Stomach – Various stages of a protozoal parasite in the epithelial cells of the pyloric glands. HE 200x

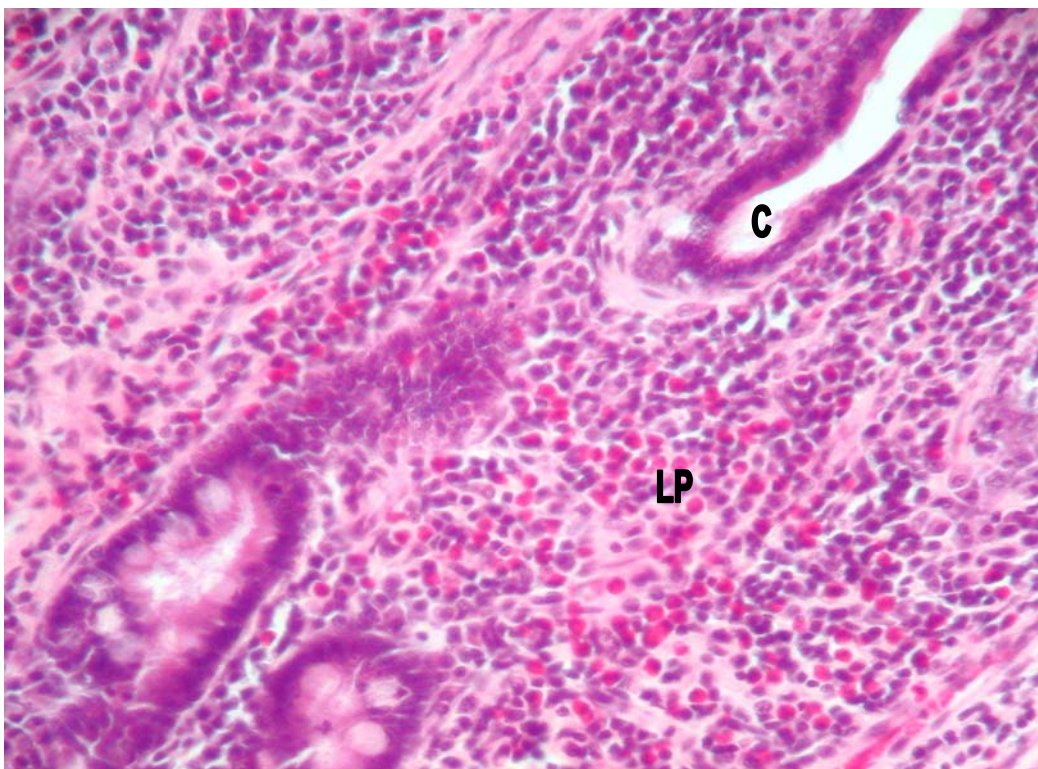


Figure 14: Small intestine – Lymphocytic plasmacytic enteritis, characterized by expansion of the lamina propria (LP) by increased numbers of plasma cells and lymphocytes, as well as numerous eosinophils. C = Crypts. HE 200x

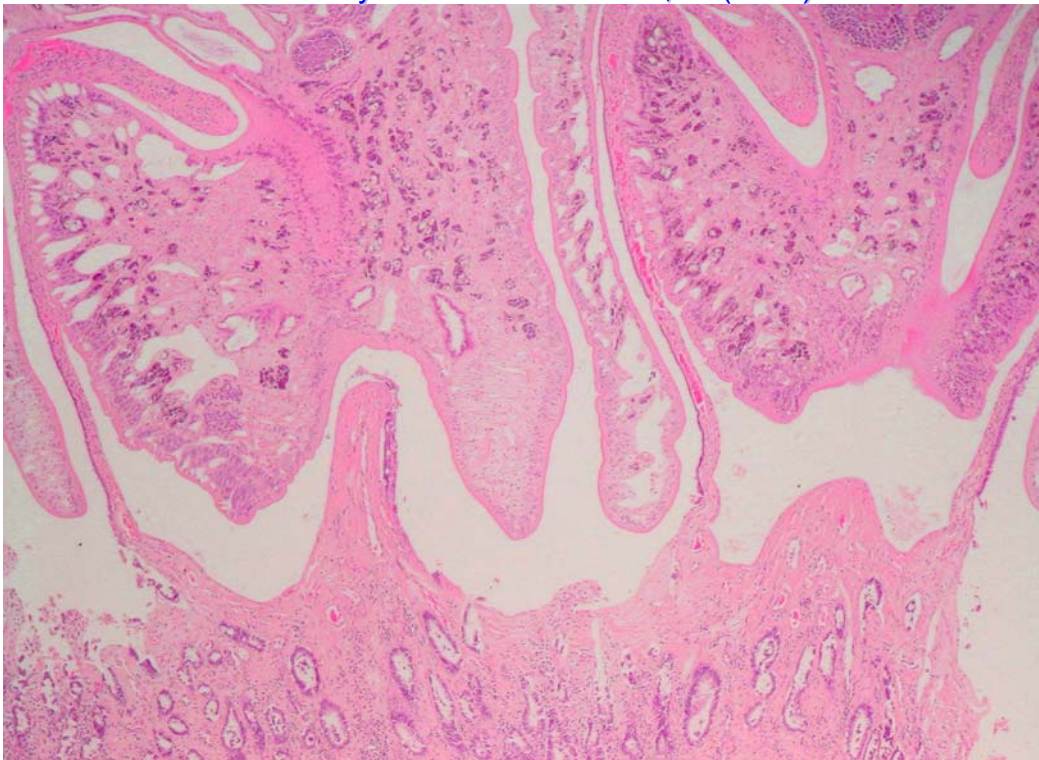


Figure 15: Small intestine – Two trematodes attached to the small intestinal mucosa surface. HE 40x

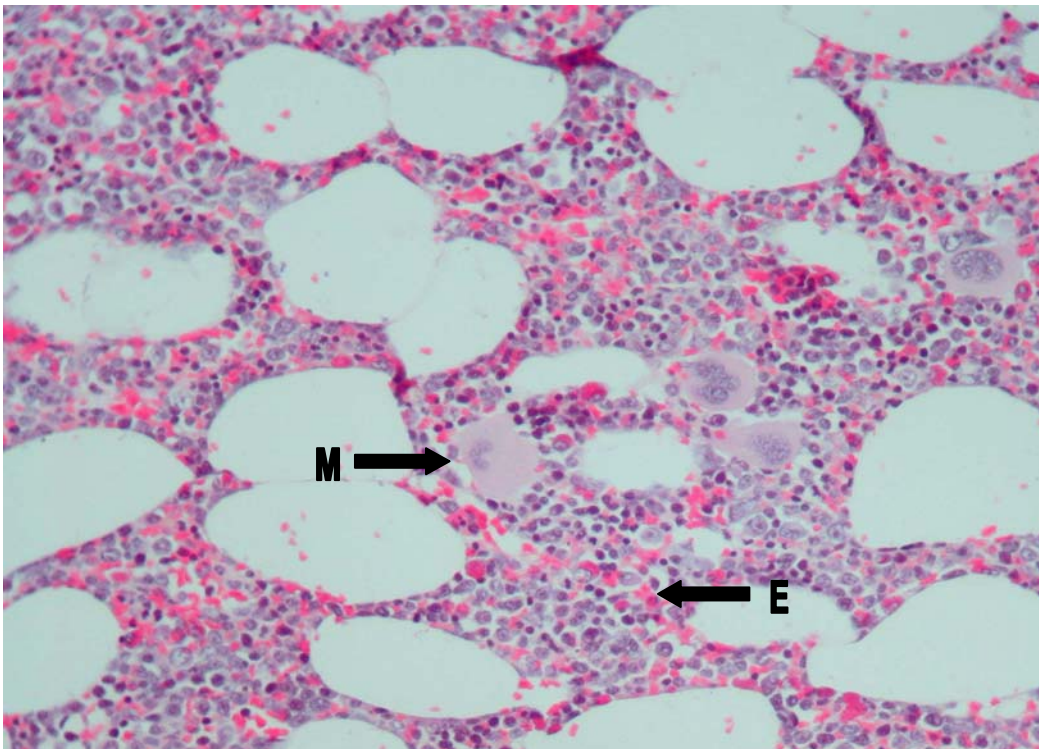


Figure 16: Bone marrow – The M:E ratio is 3:1 and there are increased numbers of eosinophils (E). Megakaryocyte (M) numbers in this fleck are within normal limits. HE 200x

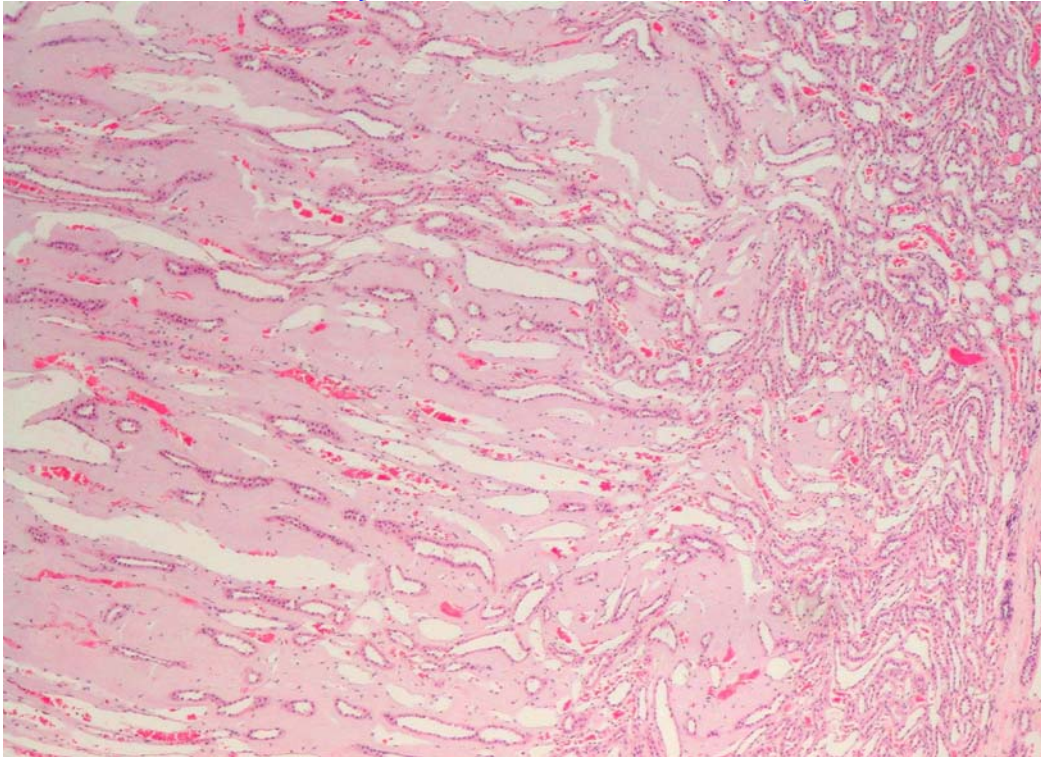


Figure 17: Kidney – Renal medullary amyloidosis with expansion of the medullary interstitium by homogenous intercellular eosinophilic material. HE 40x

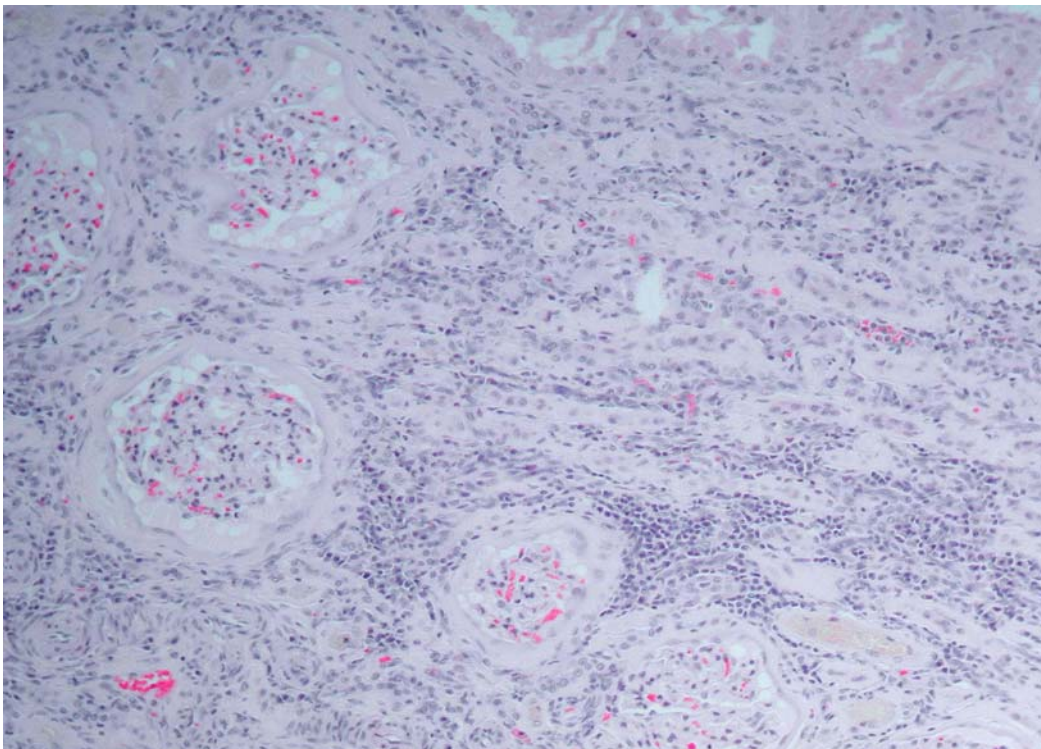


Figure 18: Kidney – Membranous glomerulonephritis, with thickening of the glomerular basement membranes and cellular proliferation in the glomerular tufts. Chronic interstitial nephritis, with interstitial fibrosis and infiltration of plasma cells and lymphocytes. HE 100x

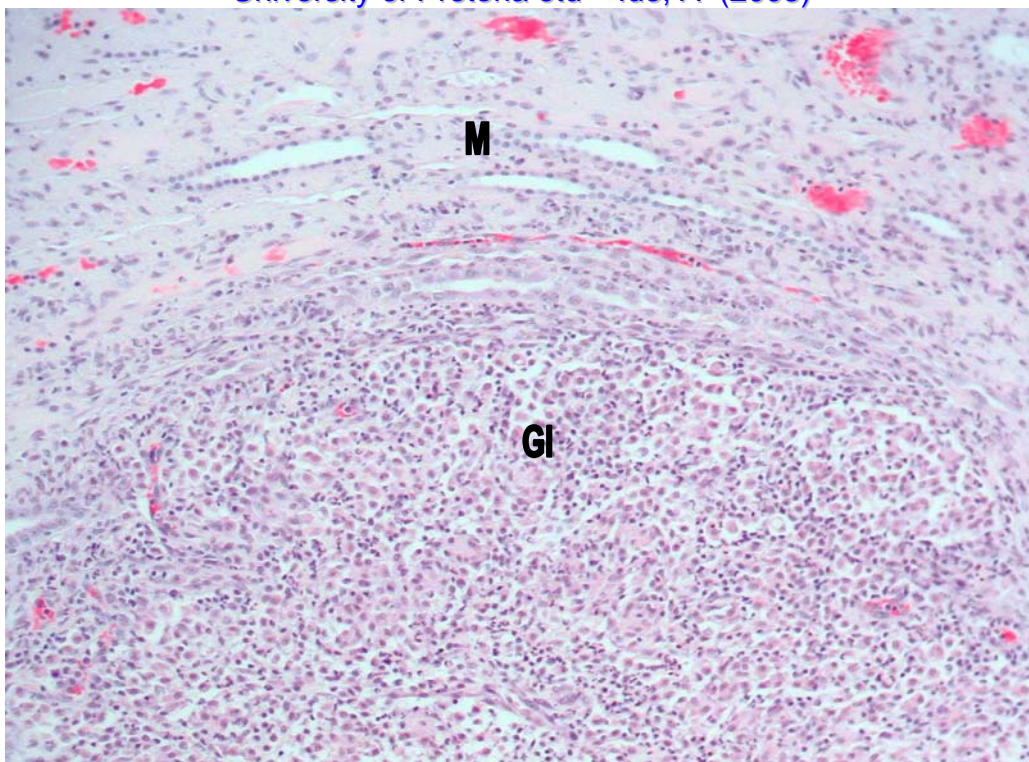


Figure 19: Kidney – Focally-extensive granulomatous nephritis (GI) within the medulla (M). The inflammatory response is characterized by macrophages with admixed plasma cells, lymphocytes and neutrophils. HE 100x

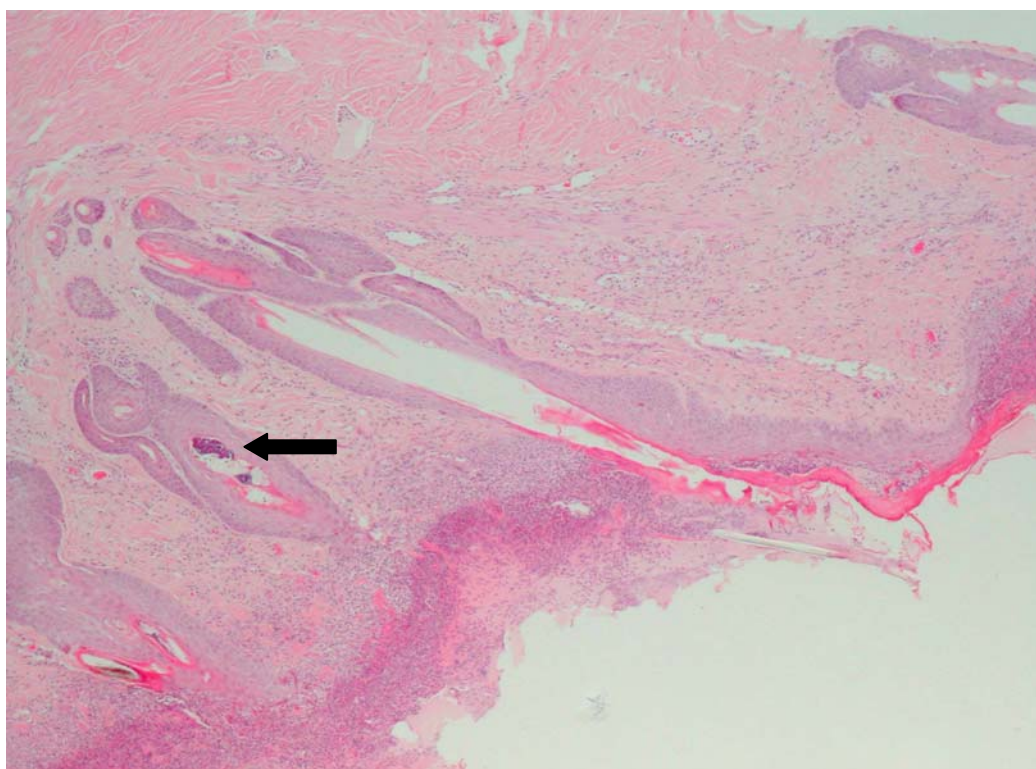


Figure 20: Skin – Ulcerative dermatitis, with multifocal bacterial folliculitis (arrow). HE 40x

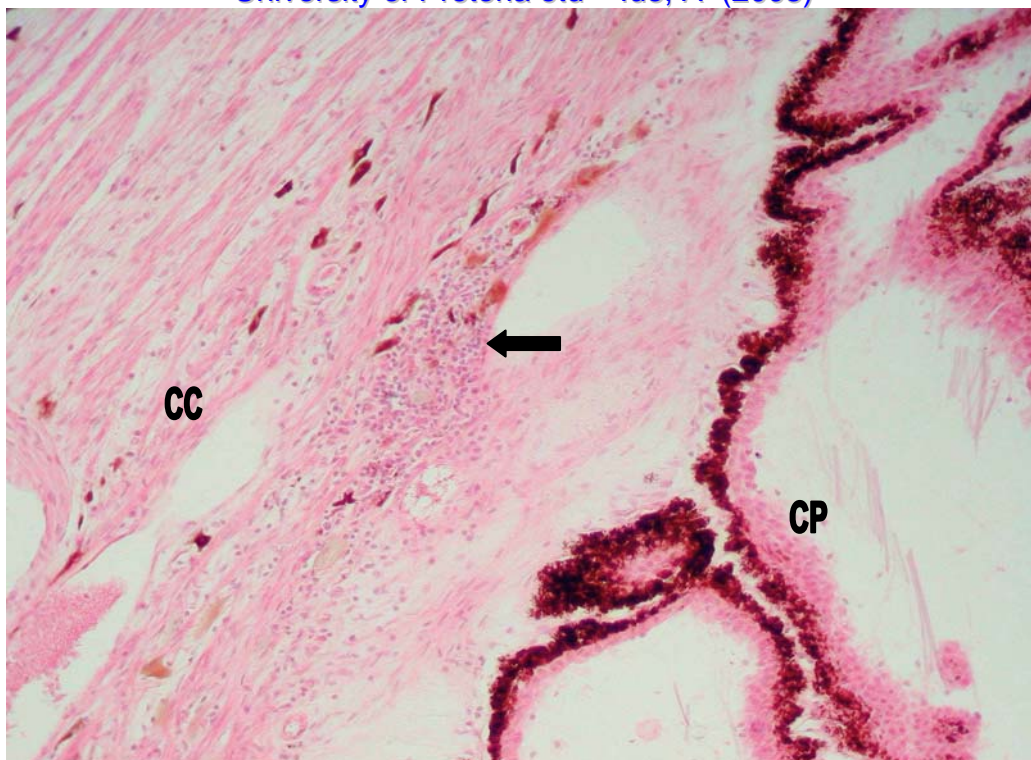


Figure 21: Eye – Anterior uveitis, characterized by mild lymphocytic infiltration (arrow) in the ciliary cleft (CC). CP = Ciliary processes. HE 40x

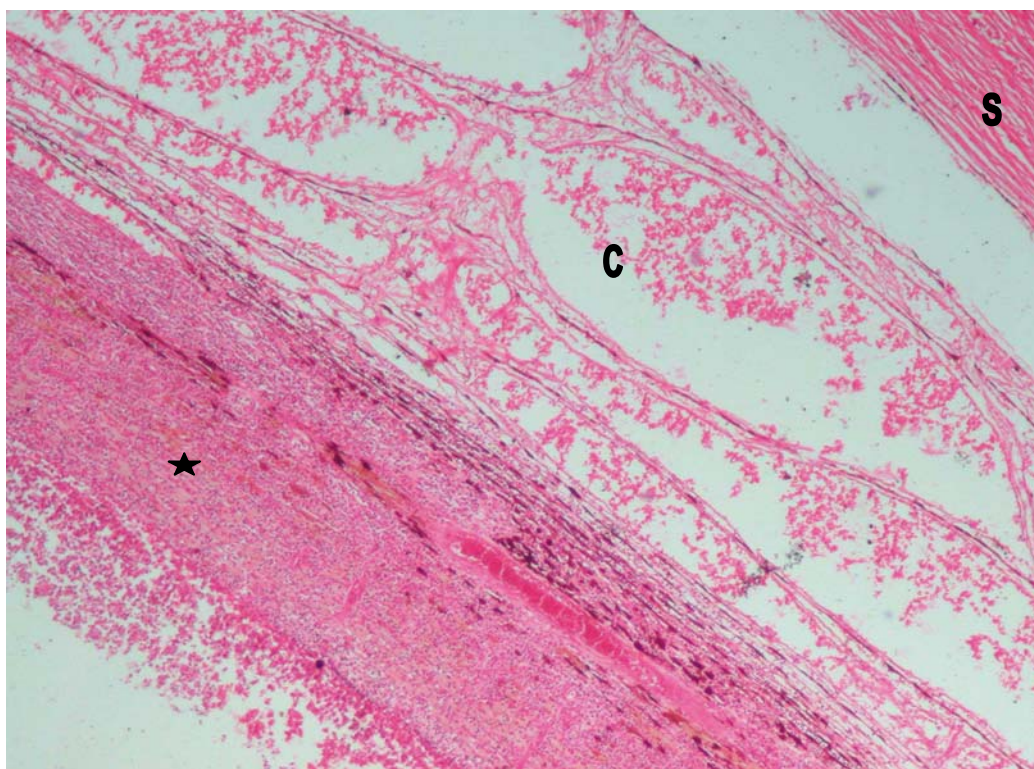


Figure 22: Eye – Granulomatous panophthalmitis, with infiltration of the choroid (C) by mixed inflammatory cells and an inflammatory exudate (star) adhering to and filling the posterior chamber. S = Sclera. HE 40x

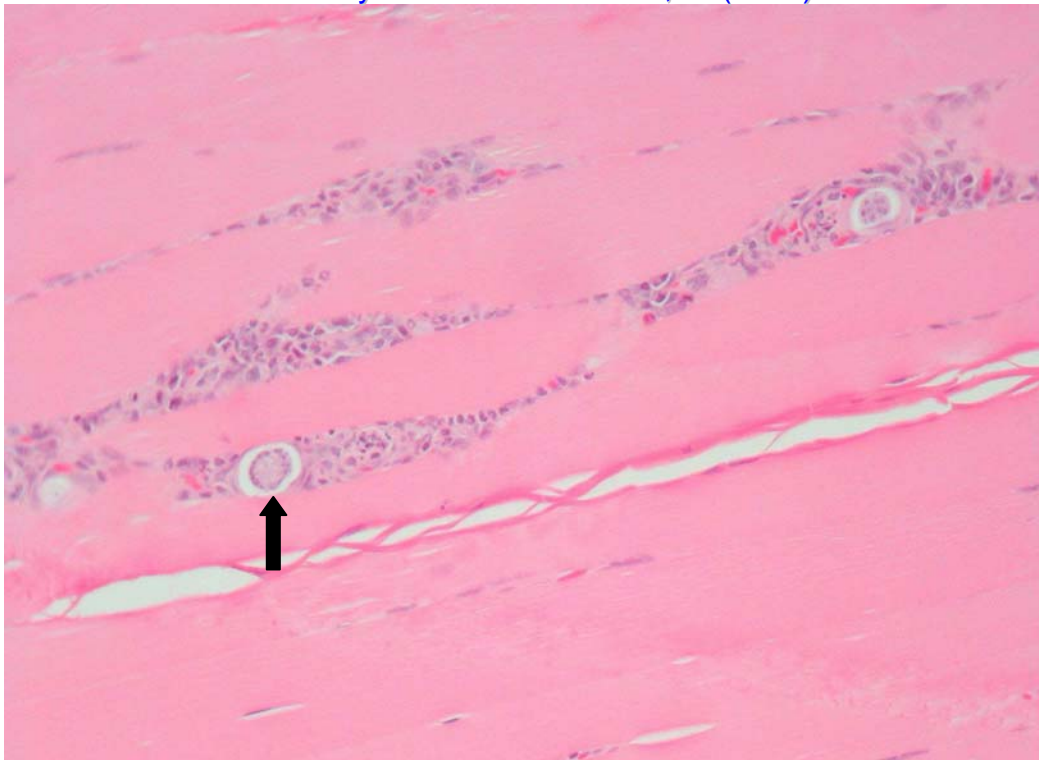


Figure 23: Skeletal muscle – Multifocal muscle fibre degeneration and inflammation associated with *Hepatozoon* spp. schizonts (arrow). HE 200x

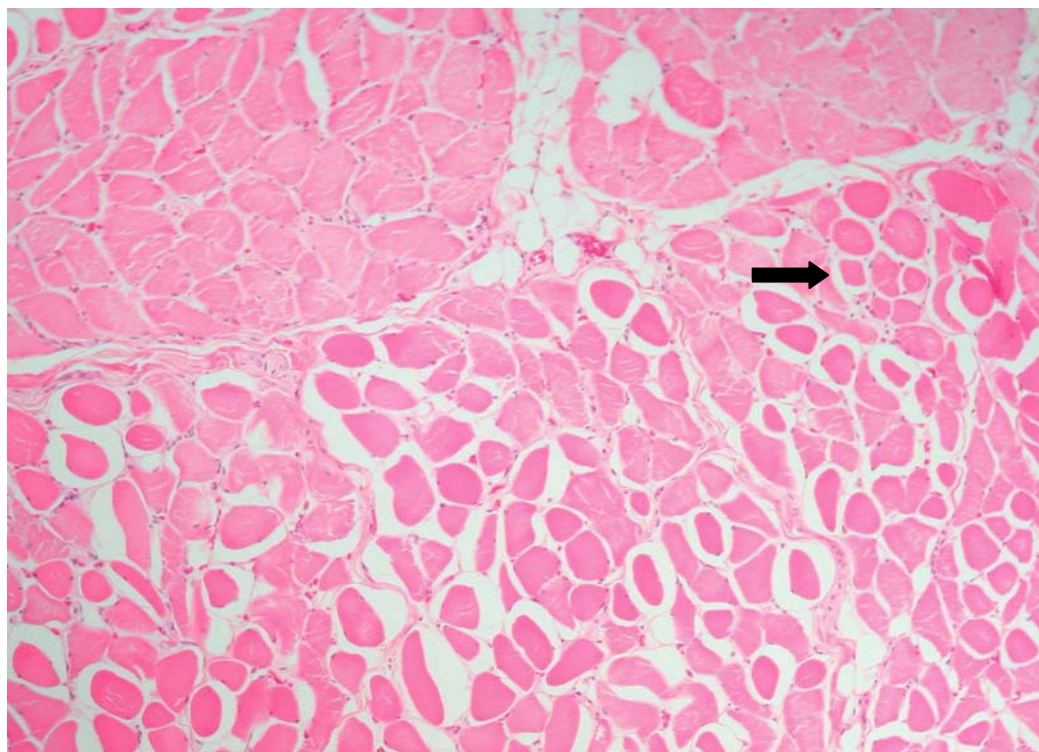


Figure 24: Skeletal muscle (glossal) – Mild muscle fibre atrophy with variation in muscle fibre diameter and angulation and increased eosinophilia of multifocal fibres (arrow). HE 100x

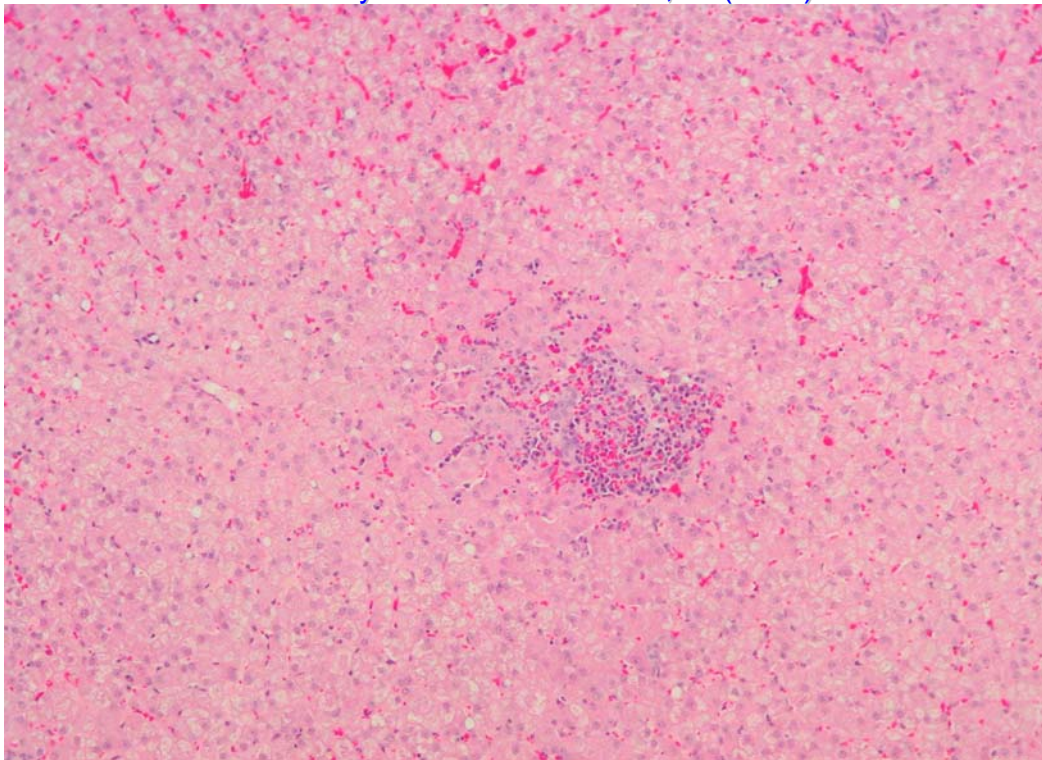


Figure 25: Liver – Focal granulomatous inflammation, comprizing macrophages, lymphocytes, plasma cells and eosinophils. HE 100x

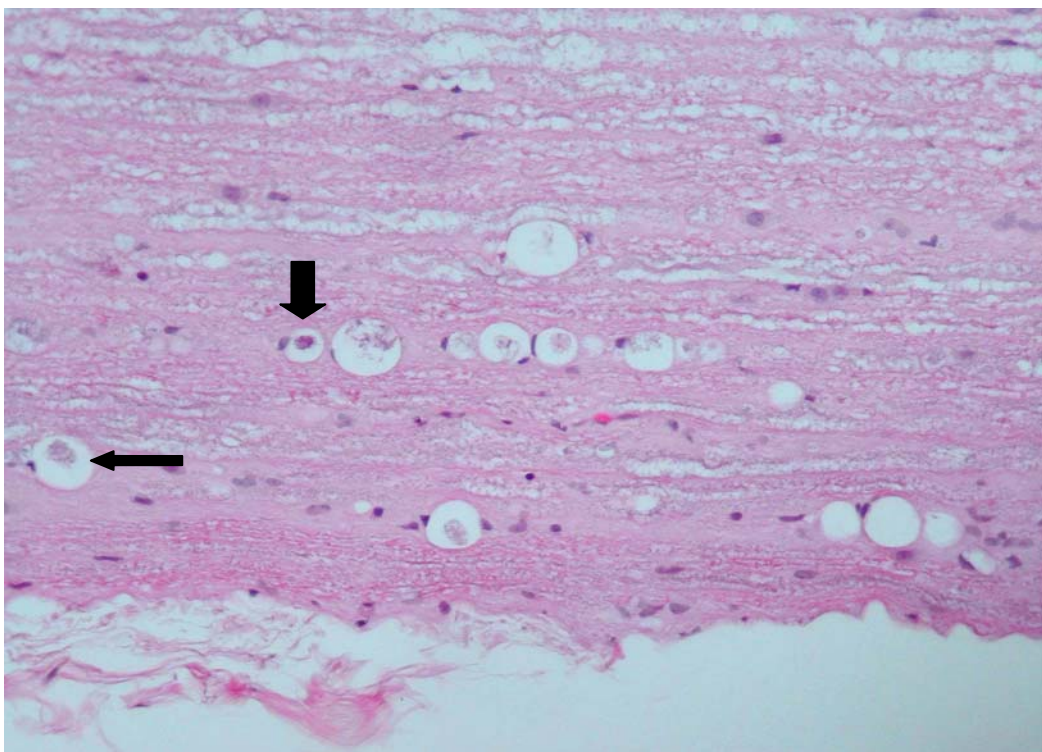


Figure 26: Spinal cord – Wallerian degeneration, with multifocal digestion chambers containing swollen axons (long arrow) and myelinophages (short arrow). HE 200x

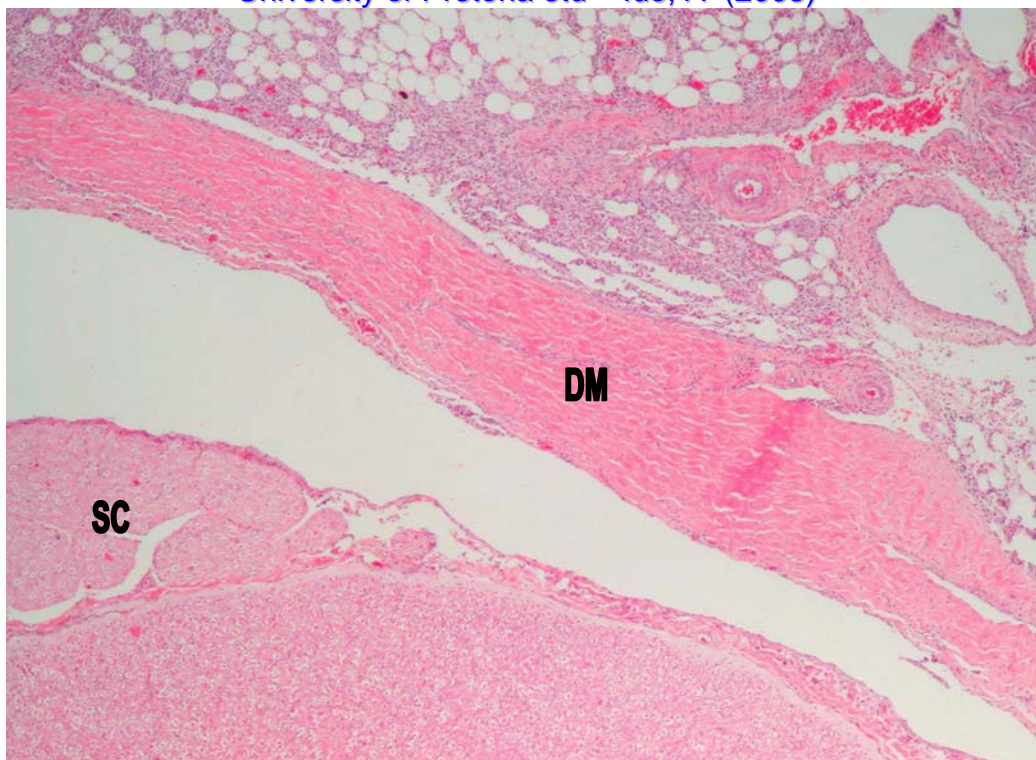


Figure 27: Spinal cord – Meningitis, with infiltration of the dura mater (DM) and adjacent adipose tissue by mixed inflammatory cells. SC – Spinal cord. HE 40x

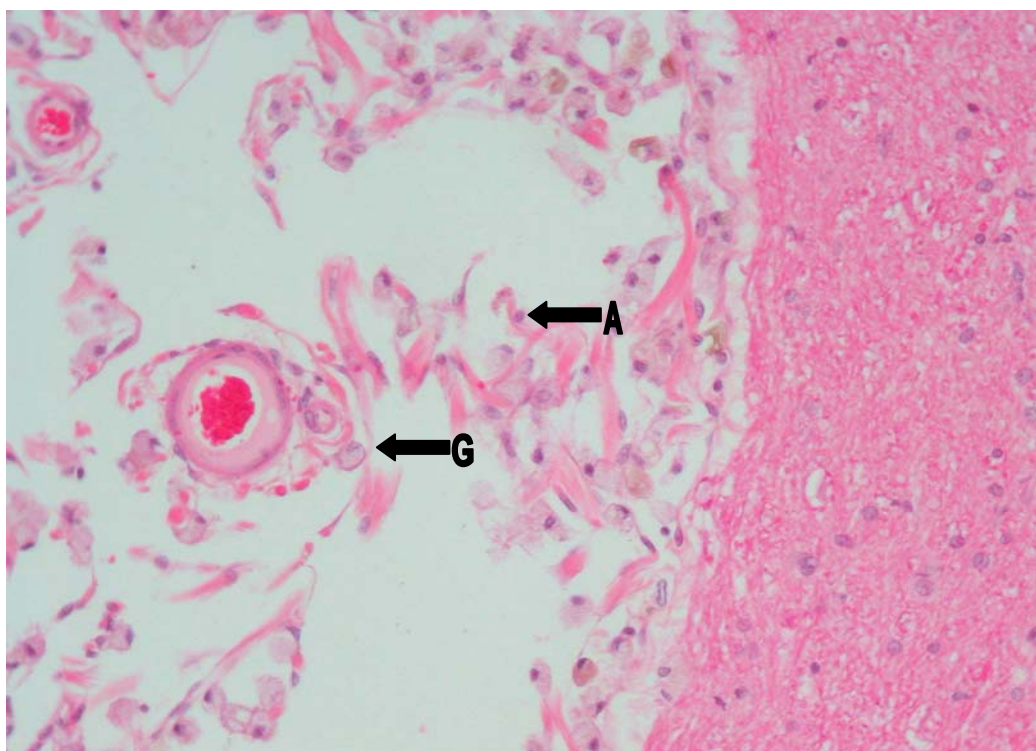


Figure 28: Cerebrum – Focal encephalomalacia, characterized by an irregular space containing “gitter cells” (G) and proliferating astrocytes (A). HE 200x

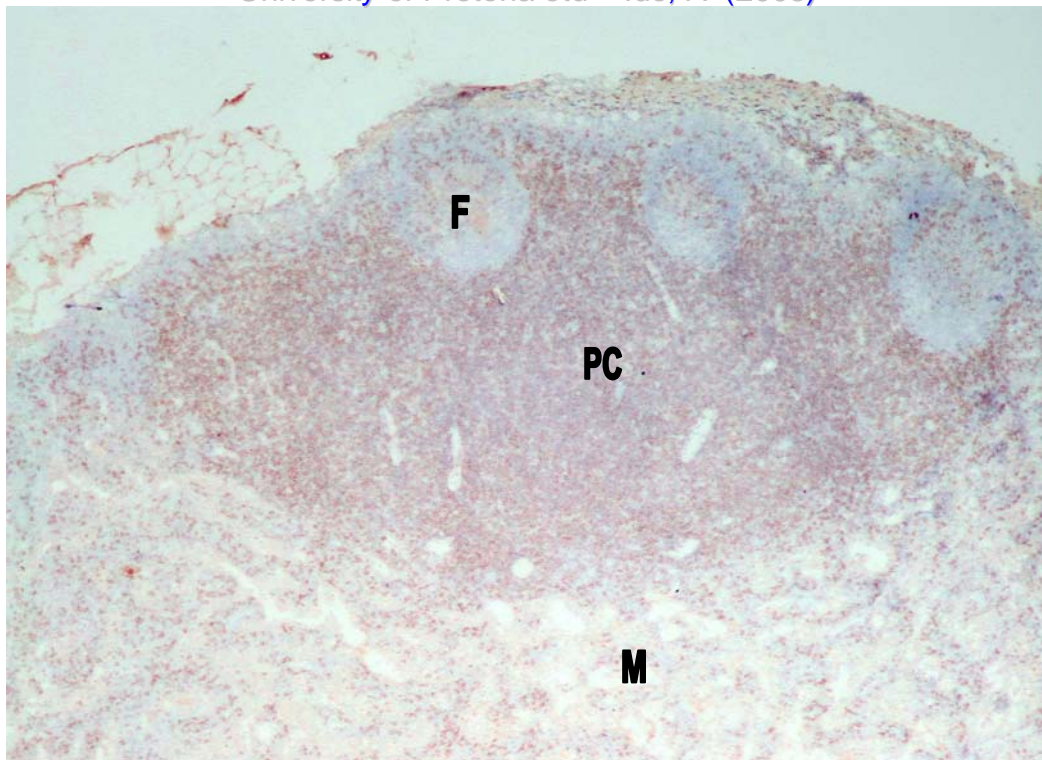


Figure 29: Lymph node – Immunohistochemical staining of a frozen section for T lymphocytes. There is moderate staining in the paracortex (PC), with scattered cells staining in the follicles (F) and medulla (M). 40x

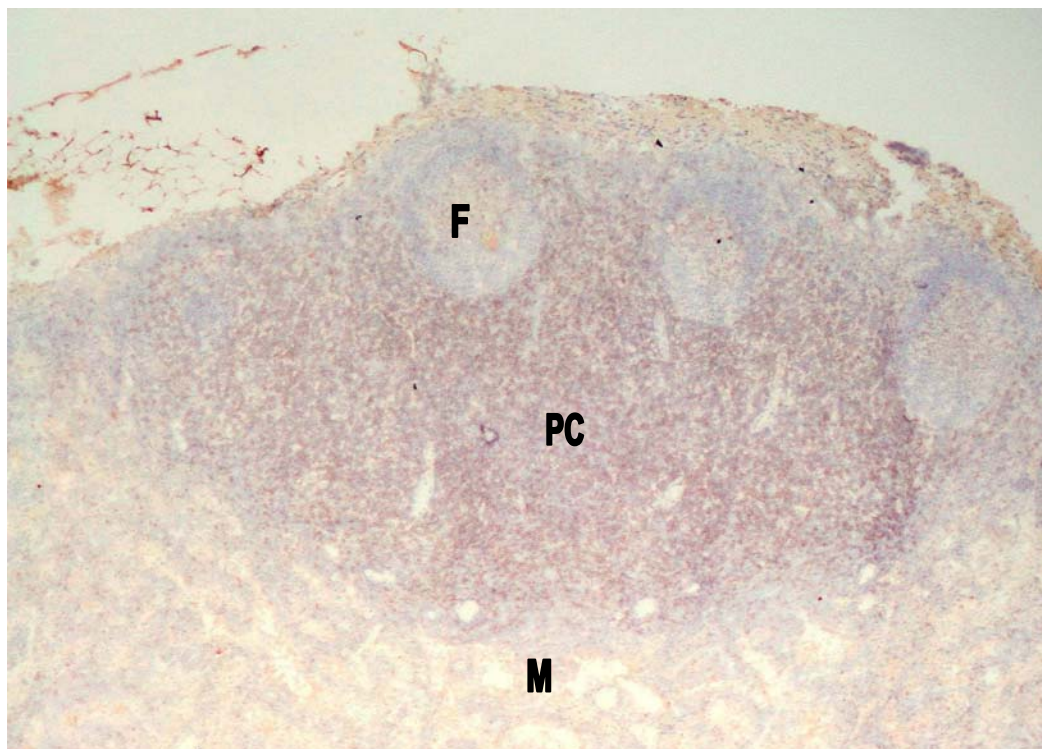


Figure 30: Lymph node – Immunohistochemical staining of a frozen section for CD4 T lymphocytes. There is again moderate staining in the paracortex (PC), with fewer cells staining in the follicles (F) and medulla (M). 40x

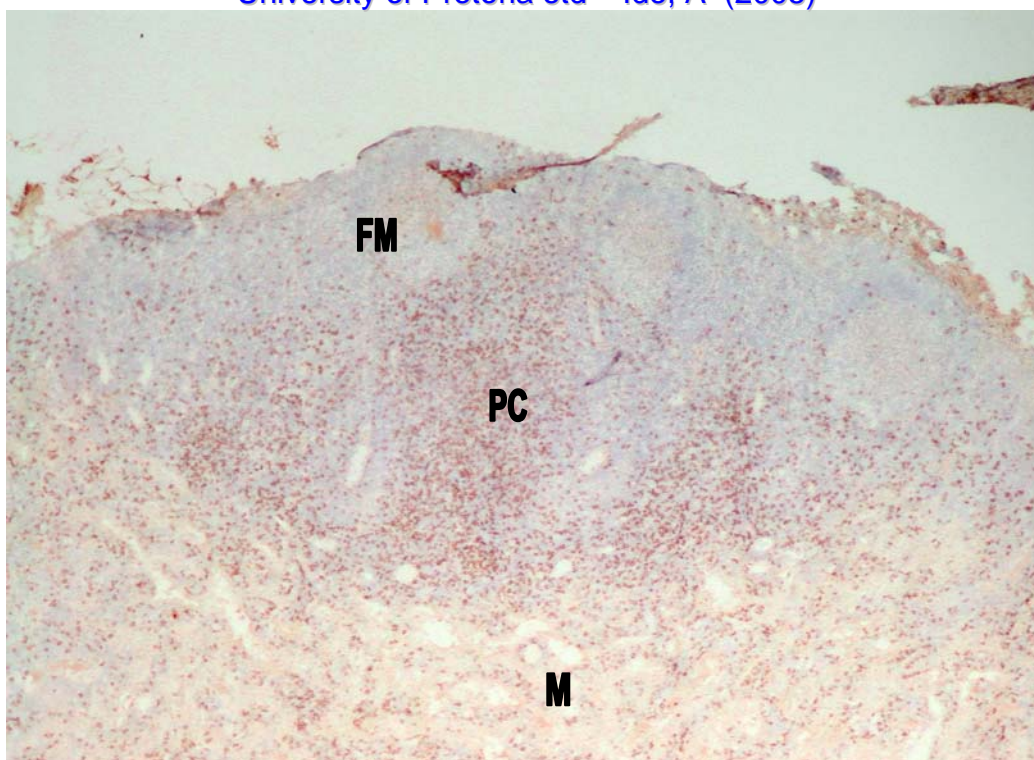


Figure 31: Lymph node – Immunohistochemical staining of a frozen section for CD8 T lymphocytes. There is scattered staining in the paracortex (PC), as well as some staining in the follicular mantle (FM) zone and medulla (M). 40x

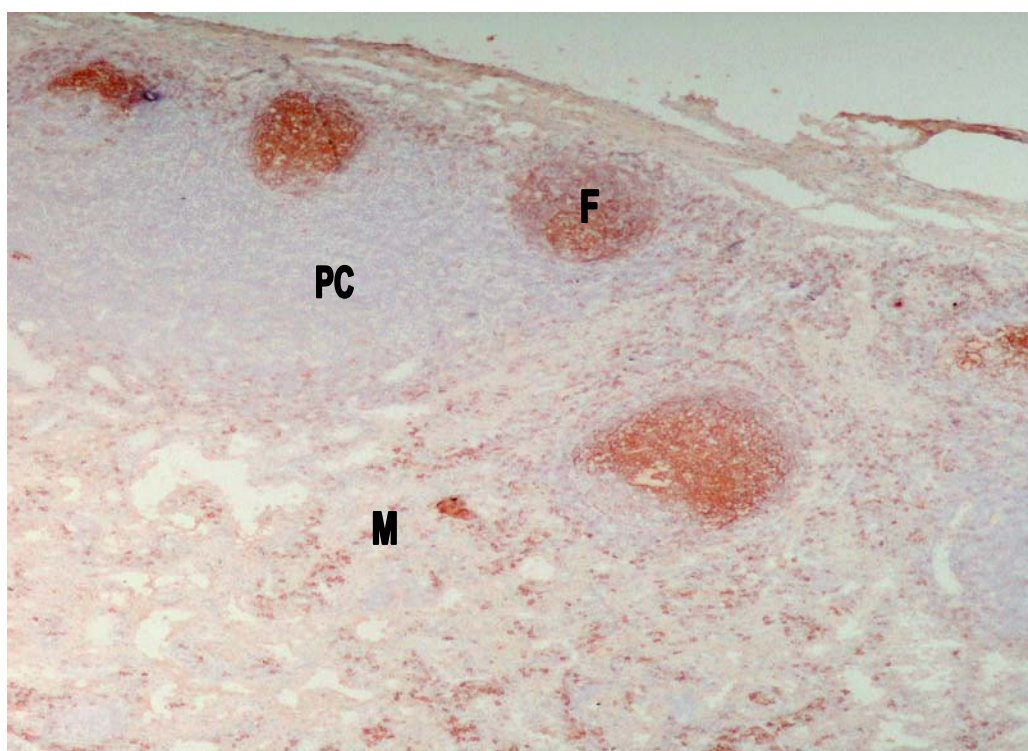


Figure 32: Lymph node – Immunohistochemical staining of a frozen section for B lymphocytes. There is intense staining of the follicles (F) and scattered cells within the medulla (M) are staining, as well as a few cells in the paracortex (PC). 40x

TABLE 1.1(a): LYMPH NODE CHANGES – summary of various changes as a percentage of total number of cases evaluated.

CORTEX	CORTEX	P/C	P/C	M/P	S/H	PMNLs			EPS	PIGM/CRYS			CYSTS/DS	PARASITES	MNGCs	GRANULOMATOUS
F/H	ATROPHY	HYPERPL	ATROPHY			E	N	N/E		H	C	?L				INFLAMMATION
16%	38%	3%	34%	31%	45%	47%	16%	9%	19%	15%	17%	1%	66%	14%	15%	22%

F/H	Follicular hyperplasia	E	Eosinophils
P/C	Paracortical	N	Neutrophils
Hyperpl.	Hyperplasia	H	Haemosiderin
S/H	Sinus histiocytosis	C	Crystalline material
PMNLs	Polymorphonuclear leukocytes	?L	Possibly lipofuscin
EPS	Erythrophagocytosis		
PIGM/CRYS	Pigment or crystalline material		
DS	Dilated sinuses		
MNGCs	Multinucleate giant cells		

TABLE 1.1(b): LYMPH NODE CHANGES – general atrophy or hyperplasia

ANIMAL NUMBER	PRESCAPULAR LNN.	MANDIBULAR LNN.	AXILLAR LNN.	INGUINAL LNN.	POPLITEAL LNN.	BRONCHIAL LNN.	MESENTERIC LNN.
1	A++	H+++	H+++	H+++	H+++	NTA	A+
2	H+	H+++	A+	NTA	H++	H+	A+
3	H++	NTA	A+	A+	A++	H+++	A+
4	H++	H++	H++	NTA	H+	H+	A+
5	A++	A++	A++	NTA	A++	A++	A++
6	H+	H++	H+	H+++	H++	H++	A+
7	H++	H+	H+	H++	H+	H+	A+
8	H+	H+	H+	H+	A+	H+	NTA
9	A++	A++	A++	A+	A+	A+	H+
10	H+	H+	H+	A++	A++	NTA	NTA
11	A++	A++	A++	A++	A+	NTA	NTA
12	A++	A++	A++	A++	A++	NTA	NTA
13	A++	NTA	NTA	NTA	NTA	NTA	NTA
14	A++	H+	A++	NTA	NTA	NTA	NTA
15	A++	A++	A+	NTA	NTA	NTA	NTA
16	A++	A++	NTA	NTA	NTA	NTA	NTA
17	A+++	A+++	NTA	NTA	A+++	A+++	NTA
18	A++	A+	H+	NTA	A++	NTA	A+
19	A+	H+	A+	A++	A++	A++	NTA
20	A+++	A+	A+++	A++	A++	A++	A+++
21	A++	NTA	A+	A+	A++	H++	A+
22	A+++	A++	H+	A+	A+	A+	A++
23	H++	H++	H+	NTA	H+	-	H++

Lnn. Lymph nodes
A Atrophy
H Hyperplasia
NTA No tissue available for histopathology
+ Mild
++ Moderate
+++ Severe

TABLE 1.2: LYMPH NODE CHANGES – Superficial cervical (prescapular)

ANIMAL NUMBER	CORTEX F/H	CORTEX ATROPHY	P/C HYPERPL.	P/C ATROPHY	M/P	S/H	PMNLs	ERYTHRO= PHAGOCYTOSIS	PIGMENT/ CRYSTALS	CYSTS/ DILATED SINUSES	PARASITES	MNGCs	GRANULOMATOUS INFLAMMATION
1	-	++	-	++	+++	+	E++/N+	+	H+	-	-	-	-
2	+	-	-	+	-	+	E++	-	-	+	-	-	-
3	++	-	-	-	-	++	E++	-	-	+	-	-	-
4	++	-	-	++	++	+++	E+++	++	-	+	M++	+	+
5	-	++	-	++	++	++	E+	-	H+	+	-	-	-
6	+	-	-	+	-	+	E+	-	-	+	-	-	-
7	++	-	-	+	+	++	E++/N+	+	-	++	-	-	-
8	+	-	-	+	+	+	E+	+	H+	+	-	-	-
9	-	++	-	++	+	++	N+	-	-	++	-	+	+
10	+	-	-	+	+	++	E+	-	-	+	-	-	-
11	-	++	-	++	-	+	-	-	?L+	+	-	-	-
12	-	++	-	++	+	+	E+/N+	+	-	+	-	-	-
13	-	++	-	+	-	++	E++	-	-	-	-	-	-
14	-	++	-	++	+	+	N+	+	H+	++	M+	-	-
15	-	++	-	++	+	+	-	-	C+	+	-	-	-
16	-	++	-	++	+	+	-	-	C+	-	-	+	-
17	-	+++	-	+++	++	+	-	-	H+	+	-	-	-
18	-	++	-	++	+	+	E+	+	H+/C+	+++	-	-	-
19	-	+	-	+	+	++	N+	-	-	++	-	-	++
20	-	+++	-	+++	+	+	-	-	-	-	-	-	-
21	-	++	-	++	++	++	E+	-	-	-	-	-	-
22	-	+++	-	++	++	-	N+	-	-	-	-	-	-
23	++	-	-	-	+	+	N+	-	H+	++	-	-	-

+	Mild	F/H	Follicular hyperplasia	E	Eosinophils
++	Moderate	P/C	Paracortical	N	Neutrophils
+++	Severe	Hyperpl.	Hyperplasia	H	Haemosiderin
		M/P	Medullary plasmacytosis	M	Microfilaria
		S/H	Sinus histiocytosis	C	Crystalline material
		PMNLs	Polymorphonuclear leukocytes	?L	Possibly lipofuscin
		MNGs	Multinucleate giant cells		

TABLE 1.3: LYMPH NODE CHANGES - Mandibular

ANIMAL NUMBER	CORTEX F/H	CORTEX ATROPHY	P/C HYPERPL.	P/C ATROPHY	M/P	S/H	PMNLs	ERYTHRO= PHAGOCYTOSIS	PIGMENT/ CRYSTALS	CYSTS/ DILATED SINUSES	PARASITES	MNGCs	GRANULOMATOUS INFLAMMATION
1	+++	-	++	-	-	++	E++	+	-	-	-	-	-
2	+++	-	++	-	-	-	E++	-	-	+	-	-	-
3	NTA	NTA	NTA	NTA	NTA	NTA	NTA	NTA	NTA	NTA	NTA	NTA	NTA
4	++	-	+	-	-	++	E+++	+	H+	++	-	-	-
5	-	++	-	++	++	++	E+/N+	-	-	-	-	-	-
6	++	-	-	-	+	++	E+	-	-	+	-	-	-
7	+	-	-	+	-	+	E++	-	-	+	-	-	-
8	+	-	-	+	+++	+++	E+	-	H+	+	-	-	-
9	-	++	-	++	++	+++	N+	-	-	+	-	+	++
10	+	-	-	+	-	++	E+	-	-	+	-	-	-
11	-	++	-	++	-	-	-	-	C++	+	-	-	-
12	-	++	-	++	-	-	E+	-	-	+	-	-	-
13	NTA	NTA	NTA	NTA	NTA	NTA	NTA	NTA	NTA	NTA	NTA	NTA	NTA
14	+	-	-	-	++	+	E+	-	-	++	M+	-	+
15	-	++	-	+	-	-	E++	-	-	+	-	-	-
16	-	++	-	+++	-	+	-	-	-	+	-	-	-
17	-	+++	-	+++	+	-	-	-	H+	-	-	-	-
18	-	+	-	+	++	++	E++	++	H+	+++	-	-	-
19	+	-	-	+	+	++	-	+	-	+	-	-	+
20	-	+	-	+	++	++	N+	+	H+	+	-	-	-
21	NTA	NTA	NTA	NTA	NTA	NTA	NTA	NTA	NTA	NTA	NTA	NTA	NTA
22	-	++	-	++	+	+	N+	-	-	-	-	-	-
23	++	-	-	-	-	+	-	-	-	+	-	-	-

+	Mild	F/H	Follicular hyperplasia	E	Eosinophils
++	Moderate	P/C	Paracortical	N	Neutrophils
+++	Severe	Hyperpl.	Hyperplasia	H	Haemosiderin
NTA	No tissue available for histopathology	M/P	Medullary plasmacytosis	M	Microfilaria
		S/H	Sinus histiocytosis	C	Crystalline material
		PMNLs	Polymorphonuclear leukocytes	?L	Possibly lipofuscin
		MNGs	Multinucleate giant cells		

TABLE 1.4: LYMPH NODE CHANGES - Axillar

ANIMAL NUMBER	CORTEX F/H	CORTEX ATROPHY	P/C HYPERPL.	P/C ATROPHY	M/P	S/H	PMNLs	ERYTHRO= PHAGOCYTOSIS	PIGMENT/ CRYSTALS	CYSTS/ DILATED SINUSES	PARASITES	MNGCs	GRANULOMATOUS INFLAMMATION
1	+++	-	++	-	-	+++	E++/N+	+++	-	+	M+	-	-
2	+	+	-	+	++	++	E++	+	-	-	-	-	-
3	-	+	-	-	+	-	E+	+	-	+	-	-	-
4	++	-	+	-	-	++	E+++	+	-	++	M+	+	+
5	-	++	-	+++	+++	++	E+	-	-	-	-	-	-
6	+	-	-	+	+	++	E+	-	-	+	-	-	-
7	+	-	-	+	-	+	E++	-	-	+	-	-	-
8	+	-	-	+	-	-	E+	-	-	+	-	-	-
9	-	++	-	++	+++	+++	N++	-	-	-	-	-	++
10	+	-	-	+	-	-	-	-	-	+	-	-	-
11	-	++	-	++	-	+	-	-	?L+	+	-	-	-
12	-	++	-	+	+	++	-	-	C+	+	-	-	-
13	NTA	NTA	NTA	NTA	NTA	NTA	NTA	NTA	NTA	NTA	NTA	NTA	NTA
14	-	++	-	++	-	+	-	-	C+	++	-	-	-
15	-	+	-	+	-	-	-	-	C++	+	-	+	-
16	NTA	NTA	NTA	NTA	NTA	NTA	NTA	NTA	NTA	NTA	NTA	NTA	NTA
17	NTA	NTA	NTA	NTA	NTA	NTA	NTA	NTA	NTA	NTA	NTA	NTA	NTA
18	+	-	-	+	++	+	N+	-	C++	-	-	-	+
19	-	+	-	++	++	+	-	+	-	-	-	-	+++
20	-	+++	-	++	+	-	-	-	C++	-	-	+	-
21	-	+	-	++	+	+	E++	+	C++	+	-	-	-
22	+	-	-	+	-	-	-	-	-	++	-	-	-
23	+	-	-	+	+	+	-	-	-	+	-	-	-

+	Mild	F/H	Follicular hyperplasia	E	Eosinophils
++	Moderate	P/C	Paracortical	N	Neutrophils
+++	Severe	Hyperpl.	Hyperplasia	H	Haemosiderin
NTA	No tissue available for histopathology	M/P	Medullary plasmacytosis	M	Microfilaria
		S/H	Sinus histiocytosis	C	Crystalline material
		PMNLs	Polymorphonuclear leukocytes	?L	Possibly lipofuscin
		MNGCs	Multinucleate giant cells		

TABLE 1.5: LYMPH NODE CHANGES - Inguinal

ANIMAL NUMBER	CORTEX F/H	CORTEX ATROPHY	P/C HYPERPL.	P/C ATROPHY	M/P	S/H	PMNLs	ERYTHRO= PHAGOCYTOSIS	PIGMENT/ CRYSTALS	CYSTS/ DILATED SINUSES	PARASITES	MNGCs	GRANULOMATOUS INFLAMMATION
1	+++	-	-	-	-	+++	E+++	++	-	++	M+	+	+
2	NTA	NTA	NTA	NTA	NTA	NTA	NTA	NTA	NTA	NTA	NTA	NTA	NTA
3	-	+	-	+	+	+++	E++	-	-	++	M++	++	+
4	NTA	NTA	NTA	NTA	NTA	NTA	NTA	NTA	NTA	NTA	NTA	NTA	NTA
5	NTA	NTA	NTA	NTA	NTA	NTA	NTA	NTA	NTA	NTA	NTA	NTA	NTA
6	+	-	-	+	-	-	E+	-	-	+	M+	+	+
7	++	-	-	+	+	+	E++	+	H+	++	-	-	-
8	+	-	-	+	-	-	E+	-	-	+	-	-	-
9	-	+	-	+	+	+	N+	-	-	++	-	-	-
10	-	++	-	++	+++	++	E++	-	H+	+	M+	-	+
11	-	++	-	++	-	+	E+/N+	-	-	-	-	-	-
12	-	++	-	++	++	+	-	-	C+	-	-	+	+
13	NTA	NTA	NTA	NTA	NTA	NTA	NTA	NTA	NTA	NTA	NTA	NTA	NTA
14	NTA	NTA	NTA	NTA	NTA	NTA	NTA	NTA	NTA	NTA	NTA	NTA	NTA
15	NTA	NTA	NTA	NTA	NTA	NTA	NTA	NTA	NTA	NTA	NTA	NTA	NTA
16	NTA	NTA	NTA	NTA	NTA	NTA	NTA	NTA	NTA	NTA	NTA	NTA	NTA
17	NTA	NTA	NTA	NTA	NTA	NTA	NTA	NTA	NTA	NTA	NTA	NTA	NTA
18	NTA	NTA	NTA	NTA	NTA	NTA	NTA	NTA	NTA	NTA	NTA	NTA	NTA
19	-	++	-	+	++	++	-	-	H+/C+	++	M+	-	++
20	-	++	-	++	++	+	N++	-	H+	+++	-	-	-
21	+	-	-	++	++	++	N+	+	H+/C+	++	-	-	-
22	+	-	-	++	+	-	N+	-	-	+	-	-	-
23	NTA	NTA	NTA	NTA	NTA	NTA	NTA	NTA	NTA	NTA	NTA	NTA	NTA

+	Mild	F/H	Follicular hyperplasia	E	Eosinophils
++	Moderate	P/C	Paracortical	N	Neutrophils
+++	Severe	Hyperpl.	Hyperplasia	H	Haemosiderin
NTA	No tissue available for histopathology	M/P	Medullary plasmacytosis	M	Microfilaria
		S/H	Sinus histiocytosis	C	Crystalline material
		PMNLs	Polymorphonuclear leukocytes	?L	Possibly lipofuscin
		MNGs	Multinucleate giant cells		

TABLE 1.6: LYMPH NODE CHANGES - Popliteal

ANIMAL NUMBER	CORTEX F/H	CORTEX ATROPHY	P/C HYPERPL.	P/C ATROPHY	M/P	S/H	PMNLs	ERYTHRO= PHAGOCYTOSIS	PIGMENT/ CRYSTALS	CYSTS/ DILATED SINUSES	PARASITES	MNGCs	GRANULOMATOUS INFLAMMATION
1	+++	-	-	+	-	+++	E+/N+	-	C+	-	M+	+	+
2	++	-	-	+	+	++	E+	-	-	-	-	-	-
3	-	++	-	++	-	++	E+	-	-	+	M+	+	-
4	+	-	-	-	-	++	E++	-	-	-	-	-	-
5	-	++	-	++	++	++	N+	-	-	-	-	-	-
6	++	-	-	+	+++	++	E+	-	-	+	-	-	-
7	+	-	-	+	+	++	E++	+	-	+	-	-	-
8	-	+	-	+	+++	++	E+	-	-	++	-	-	-
9	-	+	-	+	++	++	N+	-	-	+	-	-	-
10	-	++	-	-	-	++	E+	-	-	+	-	-	-
11	-	+	-	-	+	++	E++/N+	-	-	+	-	-	-
12	-	++	-	++	++	+	-	-	C+	-	-	+	+
13	NTA	NTA	NTA	NTA	NTA	NTA	NTA	NTA	NTA	NTA	NTA	NTA	NTA
14	NTA	NTA	NTA	NTA	NTA	NTA	NTA	NTA	NTA	NTA	NTA	NTA	NTA
15	NTA	NTA	NTA	NTA	NTA	NTA	NTA	NTA	NTA	NTA	NTA	NTA	NTA
16	NTA	NTA	NTA	NTA	NTA	NTA	NTA	NTA	NTA	NTA	NTA	NTA	NTA
17	-	+++	-	+++	++	-	-	-	C+	-	-	-	+
18	-	++	-	+	++	++	-	-	C+	+	-	+	+
19	-	++	-	+	++	++	-	+	H+	+	M+	+	++
20	-	++	-	++	+	+	-	-	C+	-	-	+	++
21	-	++	-	+	++	-	-	-	C+	-	-	-	-
22	-	+	-	+	++	-	-	-	-	-	-	-	-
23	+	-	-	-	-	++	-	-	-	+	-	-	-

+	Mild	F/H	Follicular hyperplasia	E	Eosinophils
++	Moderate	P/C	Paracortical	N	Neutrophils
+++	Severe	Hyperpl.	Hyperplasia	H	Haemosiderin
NTA	No tissue available for histopathology	M/P	Medullary plasmacytosis	M	Microfilaria
		S/H	Sinus histiocytosis	C	Crystalline material
		PMNLs	Polymorphonuclear leukocytes	?L	Possibly lipofuscin
		MNGs	Multinucleate giant cells		

TABLE 1.7: LYMPH NODE CHANGES - Bronchial

ANIMAL NUMBER	CORTEX F/H	CORTEX ATROPHY	P/C HYPERPL.	P/C ATROPHY	M/P	S/H	PMNLs	ERYTHRO= PHAGOCYTOSIS	PIGMENT/ CRYSTALS	CYSTS/ DILATED SINUSES	PARASITES	MNGCs	GRANULOMATOUS INFLAMMATION
1	NTA	NTA	NTA	NTA	NTA	NTA	NTA	NTA	NTA	NTA	NTA	NTA	NTA
2	-	-	+	-	-	-	-	-	-	-	-	-	-
3	+++	-	+++	-	-	-	E+	-	-	+	-	-	-
4	+	-	-	-	-	++	E++	-	-	+	-	-	-
5	-	++	-	-	-	+	E+/N+	-	-	-	-	-	-
6	++	-	-	-	-	+	E++/N+	-	-	-	M+	-	-
7	+	-	-	-	-	++	E+	+	-	-	-	-	-
8	+	-	-	+	-	-	E+	-	-	+	-	-	-
9	-	-	-	+	++	++	N+	+	-	++	-	-	+
10	NTA	NTA	NTA	NTA	NTA	NTA	NTA	NTA	NTA	NTA	NTA	NTA	NTA
11	NTA	NTA	NTA	NTA	NTA	NTA	NTA	NTA	NTA	NTA	NTA	NTA	NTA
12	NTA	NTA	NTA	NTA	NTA	NTA	NTA	NTA	NTA	NTA	NTA	NTA	NTA
13	NTA	NTA	NTA	NTA	NTA	NTA	NTA	NTA	NTA	NTA	NTA	NTA	NTA
14	NTA	NTA	NTA	NTA	NTA	NTA	NTA	NTA	NTA	NTA	NTA	NTA	NTA
15	NTA	NTA	NTA	NTA	NTA	NTA	NTA	NTA	NTA	NTA	NTA	NTA	NTA
16	NTA	NTA	NTA	NTA	NTA	NTA	NTA	NTA	NTA	NTA	NTA	NTA	NTA
17	-	+++	-	+++	++	-	-	-	C+	-	-	-	-
18	NTA	NTA	NTA	NTA	NTA	NTA	NTA	NTA	NTA	NTA	NTA	NTA	NTA
19	-	++	-	+	++	++	-	-	H+	-	-	-	++
20	-	++	-	+	+	+	N+	-	C+	-	-	-	-
21	++	-	-	+	+	+	E+++	-	-	+	M+	+	++
22	-	+	-	+	-	-	-	-	-	-	-	-	-
23	-	-	-	-	-	+	-	-	-	-	-	-	-

+	Mild	F/H	Follicular hyperplasia	E	Eosinophils
++	Moderate	P/C	Paracortical	N	Neutrophils
+++	Severe	Hyperpl.	Hyperplasia	H	Haemosiderin
NTA	No tissue available for histopathology	M/P	Medullary plasmacytosis	M	Microfilaria
		S/H	Sinus histiocytosis	C	Crystalline material
		PMNLs	Polymorphonuclear leukocytes	?L	Possibly lipofuscin
		MNGs	Multinucleate giant cells		

TABLE 1.8: LYMPH NODE CHANGES – Mesenteric

ANIMAL NUMBER	CORTEX F/H	CORTEX ATROPHY	P/C HYPERPL.	P/C ATROPHY	M/P	S/H	PMNLs	ERYTHRO= PHAGOCYTOSIS	PIGMENT/ CRYSTALS	CYSTS/ DILATED SINUSES	PARASITES	MNGCs	GRANULOMATOUS INFLAMMATION
1	-	+	-	++	-	++	E+	-	-	-	-	-	-
2	-	+	-	++	++	-	E+	-	-	-	-	-	-
3	-	+	-	-	-	++	E+	-	-	+	-	-	-
4	-	+	-	+	-	++	E+	-	-	+	-	-	-
5	-	++	-	+	-	+	E+	-	-	+	-	-	-
6	-	+	-	+	-	+++	E++	-	-	-	-	-	-
7	-	+	-	++	++	++	E+	-	-	+	-	-	-
8	NTA	NTA	NTA	NTA	NTA	NTA	NTA	NTA	NTA	NTA	NTA	NTA	NTA
9	+	-	-	+	+	+	N+	-	-	+	-	-	+
10	NTA	NTA	NTA	NTA	NTA	NTA	NTA	NTA	NTA	NTA	NTA	NTA	NTA
11	NTA	NTA	NTA	NTA	NTA	NTA	NTA	NTA	NTA	NTA	NTA	NTA	NTA
12	NTA	NTA	NTA	NTA	NTA	NTA	NTA	NTA	NTA	NTA	NTA	NTA	NTA
13	NTA	NTA	NTA	NTA	NTA	NTA	NTA	NTA	NTA	NTA	NTA	NTA	NTA
14	NTA	NTA	NTA	NTA	NTA	NTA	NTA	NTA	NTA	NTA	NTA	NTA	NTA
15	NTA	NTA	NTA	NTA	NTA	NTA	NTA	NTA	NTA	NTA	NTA	NTA	NTA
16	NTA	NTA	NTA	NTA	NTA	NTA	NTA	NTA	NTA	NTA	NTA	NTA	NTA
17	NTA	NTA	NTA	NTA	NTA	NTA	NTA	NTA	NTA	NTA	NTA	NTA	NTA
18	-	+	-	+	+	++	E++/N+	-	-	++	-	-	-
19	NTA	NTA	NTA	NTA	NTA	NTA	NTA	NTA	NTA	NTA	NTA	NTA	NTA
20	-	+++	-	++	-	-	-	-	-	+	-	-	-
21	-	+	-	+	+	+	E+	-	-	++	M+	-	-
22	-	++	-	+	+++	++	E+	-	-	-	-	-	-
23	++	-	-	-	-	+	-	-	-	-	-	-	-

+	Mild	F/H	Follicular hyperplasia	E	Eosinophils
++	Moderate	P/C	Paracortical	N	Neutrophils
+++	Severe	Hyperpl.	Hyperplasia	H	Haemosiderin
NTA	No tissue available for histopathology	M/P	Medullary plasmacytosis	M	Microfilaria
		S/H	Sinus histiocytosis	C	Crystalline material
		PMNLs	Polymorphonuclear leukocytes	?L	Possibly lipofuscin
		MNGs	Multinucleate giant cells		

TABLE 2: PULMONARY CHANGES

ANIMAL NUMBER	INTERSTITIAL PNEUMONIA	GRANULOMATOUS PNEUMONIA	BRONCHIECTASIS	PARASITES	ANTHRASILICOSIS	NEOPLASIA	ZN STAIN	MYCOBACTERIAL CULTURE
1	-	+++	-	-	-	-	Negative	Negative
2	+	-	-	H	+	-	-	-
3	+	-	-	H	+	-	Negative	-
4	+	-	-	H	-	-	-	-
5	+	-	-	H	-	-	-	Negative
6	+	-	-	H	-	-	-	Negative
7	+++	+++	+++	-	++	-	-	Negative
8	++	-	-	H	-	-	Negative	Negative
9	+	+++	+++	H	+	-	Negative	Negative
10	++	-	-	-	++	-	-	Negative
11	NTA	NTA	NTA	NTA	NTA	NTA	NTA	Negative
12	+	-	-	H	+	Adenoma	-	-
13	++	-	-	-	+	-	-	-
14	+	-	-	-	++	-	-	-
15	++	++	-	-	+	-	-	-
16	++	-	-	-	++	-	-	-
17	++	+	-	H	+	-	-	-
18	+	-	-	-	+	-	-	-
19	-	+++	+++	H/M	-	-	-	Positive
20	++	-	-	-	+	-	-	Positive
21	+	-	-	-	-	-	-	Negative
22	+	-	-	H	-	-	-	Negative
23	-	-	-	-	-	-	-	Negative

+ Mild
 ++ Moderate
 +++ Severe
 NTA No tissue available for histopathology
 H *Hepatozoon* spp.
 M *Microfilaria*

TABLE 3.1: GASTRIC CHANGES

ANIMAL NUMBER	CHRONIC GASTRITIS	BACTERIA	PROTOZOA	GRANULOMATOUS INFLAMMATION	NEMATODES	HEPATOZOON
1	Yes	-	-	-	-	-
2	Yes	-	-	-	-	-
3	-	-	-	-	-	-
4	Yes	-	-	-	-	-
5	-	-	-	-	-	-
6	Yes	-	-	-	-	-
7	Yes	Yes	-	-	-	-
8	NTA	NTA	NTA	NTA	NTA	NTA
9	-	Yes	Yes	Yes	-	-
10	-	-	-	-	-	-
11	-	-	-	-	Yes	-
12	NTA	NTA	NTA	MTA	NTA	NTA
13	NTA	NTA	NTA	NTA	NTA	NTA
14	-	-	-	-	-	-
15	NTA	NTA	NTA	NTA	NTA	NTA
16	NTA	NTA	NTA	NTA	NTA	NTA
17	Autolysed	Autolysed	Autolysed	Autolysed	Autolysed	Autolysed
18	-	-	-	-	-	Yes
19	-	-	-	-	-	-
20	Yes	-	Yes	-	-	-
21	-	-	-	-	-	-
22	Yes	-	-	Yes	-	-
23	Yes	-	-	-	-	-

NTA No tissue available for histology

TABLE 3.2: SMALL INTESTINAL CHANGES

ANIMAL NUMBER	BACTERIA	EOSINOPHILIA	L/PL ENTERITIS	PARASITIC GRANULOMA	FB PENETRATION	CESTODES	TREMATODES	NEMATODES	MICROFILARIA
1	+	+	-	-	-	-	-	-	-
2	+	++	-	-	-	-	-	-	-
3	++	+	-	-	-	+	-	-	-
4	++	++	-	-	-	++	-	-	-
5	-	+	-	-	-	+	-	-	-
6	-	+	-	-	-	++	-	-	-
7	++	-	-	-	-	-	-	-	-
8	-	-	-	-	-	-	-	-	-
9	+	-	+	+	-	-	-	-	-
10	-	-	+	-	-	-	-	+	-
11	-	-	-	-	-	-	+	-	-
12	+	-	-	-	-	-	-	-	-
13	NTA	NTA	NTA	NTA	NTA	NTA	NTA	NTA	NTA
14	-	+	-	-	+	-	-	+	-
15	-	-	-	-	-	-	-	+	-
16	NTA	NTA	NTA	NTA	NTA	NTA	NTA	NTA	NTA
17	Autolysed	Autolysed	Autolysed	Autolysed	Autolysed	Autolysed	Autolysed	Autolysed	Autolysed
18	-	-	-	-	-	-	-	-	-
19	-	-	+	-	-	+	-	-	+
20	-	-	-	-	-	-	-	-	-
21	-	-	-	-	-	-	-	-	-
22	-	+	-	-	-	-	-	-	-
23	-	-	-	-	-	-	-	-	-

+ Mild
 ++ Moderate
 +++ Severe
 L/PL Lympho-plasmacytic
 FB Foreign body
 NTA No tissue available for histology

TABLE 3.3: COLONIC CHANGES

ANIMAL NUMBER	MILD COLITIS	FB PENETRATION	GRANULOMATOUS INFLAMMATION	BACTERIA
1	-	-	-	-
2	NTA	NTA	NTA	NTA
3	NTA	NTA	NTA	NTA
4	NTA	NTA	NTA	NTA
5	-	-	-	-
6	+	-	-	-
7	-	+	-	+
8	-	-	-	-
9	+	-	+	-
10	-	-	-	-
11	+	-	-	-
12	NTA	NTA	NTA	NTA
13	NTA	NTA	NTA	NTA
14	-	-	-	-
15	NTA	NTA	NTA	NTA
16	NTA	NTA	NTA	NTA
17	Autolysed	Autolysed	Autolysed	Autolysed
18	-	-	-	-
19	-	-	-	-
20	-	-	-	-
21	-	-	-	-
22	+	-	-	+
23	-	-	-	-

+ Mild
 FB Foreign body
 NTA No tissue available for histology

TABLE 4: BONE MARROW CHANGES

ANIMAL NUMBER	CELLS	MEGAKARYOCYTES	M:E	EOSINOPHILS	NEUTROPHILS	PLASMA CELLS	LYMPHOCYTES
1	↑	↑	2:1	+++	N	N	N
2	N	N	1:1	++	N	N	N
3	↑	↑	2:1	+++	N	N	N
4	N	N	1:1	+++	↑(mature)	N	N
5	NTA	NTA	NTA	NTA	NTA	NTA	NTA
6	N	↓	1:1	++	N	N	N
7	NTA	NTA	NTA	NTA	NTA	NTA	NTA
8	↑	N	2:1	++	N	N	N
9	↑	N	3:1(↓ RBC's)	++	N	↑	↑
10	NTA	NTA	NTA	NTA	NTA	NTA	NTA
11	N	N	3:1(↑ myeloid prec)	++	↑(mature)	↑	↑
12	NTA	NTA	NTA	NTA	NTA	NTA	NTA
13	NTA	NTA	NTA	NTA	NTA	NTA	NTA
14	NTA	NTA	NTA	NTA	NTA	NTA	NTA
15	NTA	NTA	NTA	NTA	NTA	NTA	NTA
16	NTA	NTA	NTA	NTA	NTA	NTA	NTA
17	NTA	NTA	NTA	NTA	NTA	NTA	NTA
18	NTA	NTA	NTA	NTA	NTA	NTA	NTA
19	↑	↑	3:1	++	N	↑	↑
20	N	N	1:1	+++	↑(mature)	↓	N
21	↑	N	1:5(↓ myeloid prec)	+++	↑(mature)	↑	N
22	N	N	1:4(↓ myeloid prec)	++	↑(mature)	↑	N
23	↑	↑	2:1	+++	N	↑	N

Cells Total number of cells ++ Moderate numbers
M:E Myeloid:erythroid ratio (2:1 = normal) +++ High numbers
↑ Increased
↓ Decreased
N Normal
RBCs Red blood cells
Myeloid prec Myeloid precursors
NTA No tissue available

TABLE 5: RENAL CHANGES

ANIMAL NUMBER	CONGESTION	GLOMERULONEPHRITIS	CIN	INFARCTION	GRANULOMATOUS NEPHRITIS	AMYLOIDOSIS
1	-	-	-	-	-	-
2	-	MGN (GS)	-	-	-	-
3	+	MGN (FS)	-	-	-	-
4	-	-	-	-	-	-
5	+	-	-	-	-	-
6	++	-	-	-	-	-
7	+	-	-	-	-	-
8	+	-	-	-	-	-
9	-	MGN (FS)	++	Chronic	++	-
10	+	-	-	-	-	-
11	+	MGN (FS)	-	-	-	Med. +++
12	-	-	-	-	-	-
13	-	-	-	-	-	-
14	-	-	-	-	-	Med. ++
15	-	-	-	-	-	-
16	-	-	-	-	-	-
17	-	-	-	-	-	Med. +
18	-	-	-	-	-	Med. +
19	-	MGN (FS)	-	-	++	-
20	-	MGN (FS)	-	-	-	Glom. +
21	-	MGN (FS)	-	-	-	Med. +
22	-	MGN (FS)	-	-	-	-
23	+	-	-	-	-	-

CIN Chronic interstitial nephritis + Mild
 MGN Membranous glomerulonephritis ++ Moderate
 FS Focal segmental +++ Severe
 GS Generalized segmental
 Med. Medullary
 Glom. Glomerular

TABLE 6: SKELETAL MUSCLE CHANGES

ANIMAL NUMBER	MYOSITIS	DEGENERATION	REGENERATION	ATROPHY	NECROSIS	SARCOCYSTIS	HEPATOZOON	TRICHINELLA
1	-	-	Multifocal	-	-	Yes	-	-
2	Mild	-	-	-	-	Yes	Yes	-
3	Mild	-	-	-	-	Yes	Yes	-
4	Mild	-	-	-	-	Yes	-	-
5	-	-	-	-	-	Yes	Yes	Yes
6	-	-	-	-	-	-	Yes	-
7	NTA	NTA	NTA	NTA	NTA	NTA	NTA	NTA
8	Moderate	-	Multifocal	-	Multifocal	-	-	-
9	-	-	-	-	-	Yes	Yes	Yes
10	NTA	NTA	NTA	NTA	NTA	NTA	NTA	NTA
11	-	-	-	-	-	Yes	Yes	Yes
12	NTA	NTA	NTA	NTA	NTA	NTA	NTA	NTA
13	NTA	NTA	NTA	NTA	NTA	NTA	NTA	NTA
14	NTA	NTA	NTA	NTA	NTA	NTA	NTA	NTA
15	NTA	NTA	NTA	NTA	NTA	NTA	NTA	NTA
16	NTA	NTA	NTA	NTA	NTA	NTA	NTA	NTA
17	NTA	NTA	NTA	NTA	NTA	NTA	NTA	NTA
18	Mild	Mild	-	-	-	-	-	Yes
19	Mild	Mild	-	-	-	-	-	Yes
20	Mild	Mild	-	Mild	-	Yes	Yes	Yes
21	-	-	-	-	-	Yes	-	-
22	-	-	-	Mild	-	Yes	Yes	-
23	Mild	Mild	-	-	-	Yes	Yes	-

NTA No tissue available for histopathology

TABLE 7: MYOCARDIAL CHANGES

ANIMAL NUMBER	MYOCARDITIS	DEGENERATION	FIBROSIS	SARCOCYSTIS	HEPATOZOON
1	Mild	Multifocal	-	-	Yes
2	-	-	-	-	Yes
3	-	-	-	-	Yes
4	Mild	-	-	-	-
5	Mild	Multifocal	-	-	Yes
6	Mild	-	-	-	Yes
7	Mild	-	-	-	Yes
8	-	Multifocal	-	-	Yes
9	Mild	-	-	-	Yes
10	Mild	Multifocal	-	-	Yes
11	-	-	Multifocal	-	-
12	-	-	-	-	Yes
13	Mild	-	-	-	Yes
14	-	-	-	-	Yes
15	Mild	-	-	-	Yes
16	Mild	Multifocal	-	-	Yes
17	-	-	-	Yes	Yes
18	Mild	-	-	-	Yes
19	-	-	-	-	Yes
20	-	-	-	-	Yes
21	Mild	Multifocal	Multifocal	-	Yes
22	Mild	-	-	-	Yes
23	Mild	Multifocal	-	-	Yes

TABLE 8: HEPATIC CHANGES

ANIMAL NUMBER	CONGESTION	REACTIVE HEPATITIS	EMH	GRANULOMATOUS INFLAMMATION	PORTAL INFLAMMATION
1	++	-	+	-	-
2	++	-	-	-	-
3	++	+	+	+	-
4	++	-	-	+	-
5	+	+	-	-	+
6	+	-	-	+	-
7	++	-	-	-	+
8	+	-	-	-	-
9	+	-	-	+	+
10	+	-	+	+	-
11	++	-	-	-	-
12	+	-	-	+	-
13	+	-	-	-	+
14	+	-	-	+	-
15	+	-	-	+	-
16	+	-	-	+	-
17	+	-	-	-	-
18	+	-	-	+	+
19	+	-	-	+	+
20	+	+	-	+	+
21	+	-	-	+	+
22	+	-	-	+	-
23	+	-	-	+	-

EMH Extramedullary haematopoiesis

+ Mild

++ Moderate

TABLE 9: CENTRAL NERVOUS SYSTEM CHANGES

ANIMAL NUMBER	SPINAL CORD	BRAIN		
		CEREBRUM	CEREBELLUM	BRAIN STEM
1	N	N	N	N
2	N	NTA	NTA	NTA
3	Mild perivasc. haemorr. (GM)	N	N	N
4	N	N	N	N
5	M/f mineralization of DM + mild cong.	N	N	M/f mineral. Of bvs in choroid plexus
6	Very mild Wall degen (dors + lat tracts) + mild periv. haemorr. (GM)	N	N	N
7	N	N	Mild haemorr. In pia mater	M/f small haemor. (perivasc)
8	Mild m/f meningitis	Mild cong	Mild cong	Mild cong
9	N	N	N	N
10	N	Mild cong	Mild cong	Mild cong
11	N	N	N	N
12	NTA	NTA	NTA	NTA
13	NTA	NTA	NTA	NTA
14	NTA	NTA	NTA	NTA
15	NTA	NTA	NTA	NTA
16	NTA	N	NTA	NTA
17	N	N	N	N
18	Very mild Wall. degen. (mostly ventral tracts)	M/f malacia	N	N
19	Very mild Wall. degen. (mostly ventral tracts)	N	N	N
20	Moderate Wall. degen. (mostly ventral tracts)	N	N	N
21	N	N	N	N
22	N	N	N	N
23	N	N	N	N

GM	Grey matter	dors	dorsal	perivasc	perivascular
DM	Dura mater	lat	lateral	haemor	haemorrhage
M/f	Multifocal	Wall degen	Wallerian degeneration		
N	Normal	cong	congestion		
NTA	No tissue available for histology	bvs	blood vessels		

TABLE 10.1: IMMUNOPEROXIDASE – Superficial cervical (prescapular) lymph node

ANIMAL NUMBER	PAN-T				CD4				CD8				ANTI-B			
	PC	FM	FC	MC	PC	FM	FC	MC	PC	FM	FC	MC	PC	FM	FC	MC
1	-	-	-	-	-	-	-	-	-	-	-	-	-	-	-	-
2	3+	2+	2+	2+	3+	1+	2+	1+	2+	1+	0	1+	0	1+	3+	2+
3	3+	2+	2+	2+	3+	1+	1+	1+	3+	1+	0	2+	0	2+	3+	3+
4	3+	2+	2+	2+	2+	0	1+	1+	1+	0	0	2+	0	1+	3+	2+
18	3+	2+	2+	2+	2+	1+	0	1+	2+	1+	1+	2+	0	1+	2+	2+
19	3+	2+	1+	2+	2+	1+	1+	2+	2+	1+	1+	2+	0	1+	3+	2+
20	3+	2+	1+	2+	3+	1+	1+	2+	2+	1+	1+	2+	0	1+	2+	2+

TABLE 10.2: IMMUNOPEROXIDASE – Mandibular lymph node

ANIMAL NUMBER	PAN-T				CD4				CD8				ANTI-B			
	PC	FM	FC	MC	PC	FM	FC	MC	PC	FM	FC	MC	PC	FM	FC	MC
1	-	-	-	-	-	-	-	-	-	-	-	-	-	-	-	-
2	-	-	-	-	-	-	-	-	-	-	-	-	-	-	-	-
3	-	-	-	-	-	-	-	-	-	-	-	-	-	-	-	-
4	-	-	-	-	-	-	-	-	-	-	-	-	-	-	-	-
18	3+	1+	1+	2+	3+	1+	1+	1+	2+	1+	0	1+	0	1+	3+	2+
19	3+	2+	1+	2+	2+	1+	1+	2+	2+	1+	1+	2+	1+	1+	2+	2+
20	3+	2+	2+	2+	3+	1+	0	1+	2+	1+	0	2+	0	1+	2+	3+

Pan – T	Anti-felineT lymphocyte marker (572)	PC	Paracortex
CD4	Anti-feline CD4 lymphocyte marker (MAE38)	FM	Follicular mantle
CD8	Anti-feline CD8 lymphocyte marker (117)	FC	Follicular centre
Anti-B	Anti-B lymphocyte marker (B5)	MC	Medullary cords
0	No staining	-	No staining done
1+	Mild staining		
2+	Moderate staining		
3+	Marked staining		

TABLE 10.3: IMMUNOPEROXIDASE – Axillar lymph node

ANIMAL NUMBER	PAN-T				CD4				CD8				ANTI-B			
	PC	FM	FC	MC	PC	FM	FC	MC	PC	FM	FC	MC	PC	FM	FC	MC
1	-	-	-	-	-	-	-	-	-	-	-	-	-	-	-	-
2	-	-	-	-	-	-	-	-	-	-	-	-	-	-	-	-
3	-	-	-	-	-	-	-	-	-	-	-	-	-	-	-	-
4	-	-	-	-	-	-	-	-	-	-	-	-	-	-	-	-
18	-	-	-	-	-	-	-	-	-	-	-	-	-	-	-	-
19	3+	2+	2+	2+	2+	1+	1+	1+	2+	0	0	1+	0	1+	3+	2+
20	3+	2+	1+	2+	1+	1+	1+	1+	2+	1+	0	1+	0	0	2+	2+

TABLE 10.4: IMMUNOPEROXIDASE – Inguinal lymph node

ANIMAL NUMBER	PAN-T				CD4				CD8				ANTI-B			
	PC	FM	FC	MC	PC	FM	FC	MC	PC	FM	FC	MC	PC	FM	FC	MC
1	-	-	-	-	-	-	-	-	-	-	-	-	-	-	-	-
2	-	-	-	-	-	-	-	-	-	-	-	-	-	-	-	-
3	-	-	-	-	-	-	-	-	-	-	-	-	-	-	-	-
4	-	-	-	-	-	-	-	-	-	-	-	-	-	-	-	-
18	2+	2+	1+	2+	2+	1+	0	2+	2+	1+	0	2+	0	1+	2+	3+
19	-	-	-	-	-	-	-	-	-	-	-	-	-	-	-	-
20	3+	2+	2+	2+	3+	2+	1+	1+	2+	1+	0	2+	0	1+	3+	3+

Pan – T	Anti-felineT lymphocyte marker (572)	PC	Paracortex
CD4	Anti-feline CD4 lymphocyte marker (MAE38)	FM	Follicular mantle
CD8	Anti-feline CD8 lymphocyte marker (117)	FC	Follicular centre
Anti-B	Anti-B lymphocyte marker (B5)	MC	Medullary cords
1	No staining	-	No staining done
1+	Mild staining		
2+	Moderate staining		
3+	Marked staining		

TABLE 10.5: IMMUNOPEROXIDASE – Popliteal lymph node

ANIMAL NUMBER	PAN-T				CD4				CD8				ANTI-B			
	PC	FM	FC	MC	PC	FM	FC	MC	PC	FM	FC	MC	PC	FM	FC	MC
1	3+	2+	2+	2+	3+	2+	1+	1+	2+	1+	1+	2+	0	1+	3+	2+
2	3+	2+	2+	2+	3+	1+	2+	2+	3+	1+	1+	2+	0	2+	3+	2+
3	3+	1+	1+	2+	3+	1+	1+	1+	3+	1+	0	2+	0	1+	3+	2+
4	3+	2+	1+	2+	3+	1+	2+	2+	3+	1+	0	2+	0	2+	3+	3+
18	3+	1+	1+	2+	3+	1+	1+	2+	2+	0	0	2+	0	1+	3+	3+
19	3+	2+	2+	2+	2+	1+	1+	1+	2+	1+	0	1+	0	1+	3+	2+
20	3+	2+	2+	2+	2+	1+	2+	2+	2+	1+	0	1+	0	1+	3+	3+

TABLE 10.6: IMMUNOPEROXIDASE – Bronchial lymph node

ANIMAL NUMBER	PAN-T				CD4				CD8				ANTI-B			
	PC	FM	FC	MC	PC	FM	FC	MC	PC	FM	FC	MC	PC	FM	FC	MC
1	-	-	-	-	-	-	-	-	-	-	-	-	-	-	-	-
2	-	-	-	-	-	-	-	-	-	-	-	-	-	-	-	-
3	-	-	-	-	-	-	-	-	-	-	-	-	-	-	-	-
4	-	-	-	-	-	-	-	-	-	-	-	-	-	-	-	-
18	3+	2+	1+	3+	2+	1+	1+	1+	2+	0	0	2+	0	1+	3+	3+
19	-	-	-	-	-	-	-	-	-	-	-	-	-	-	-	-
20	3+	2+	2+	2+	3+	1+	2+	2+	2+	1+	0	2+	0	1+	3+	3+

Pan – T	Anti-felineT lymphocyte marker (572)	PC	Paracortex
CD4	Anti-feline CD4 lymphocyte marker (MAE38)	FM	Follicular mantle
CD8	Anti-feline CD8 lymphocyte marker (117)	FC	Follicular centre
Anti-B	Anti-B lymphocyte marker (B5)	MC	Medullary cords
2	No staining	-	No staining done
1+	Mild staining		
2+	Moderate staining		
3+	Marked staining		

TABLE 10.7: IMMUNOPEROXIDASE – Mesenteric lymph node

ANIMAL NUMBER	PAN-T				CD4				CD8				ANTI-B			
	PC	FM	FC	MC	PC	FM	FC	MC	PC	FM	FC	MC	PC	FM	FC	MC
1	3+	2+	2+	2+	3+	2+	1+	1+	2+	1+	1+	2+	0	1+	3+	3+
2	3+	2+	1+	2+	3+	1+	2+	2+	2+	1+	0	2+	0	1+	3+	2+
3	3+	2+	1+	2+	3+	1+	1+	1+	2+	1+	0	2+	0	1+	3+	3+
4	-	-	-	-	-	-	-	-	-	-	-	-	-	-	-	-
18	3+	2+	1+	2+	3+	1+	0	1+	2+	1+	0	2+	0	1+	3+	3+
19	3+	2+	2+	2+	3+	2+	2+	2+	3+	1+	1+	2+	0	1+	3+	2+
20	3+	2+	1+	2+	3+	2+	0	1+	2+	1+	1+	2+	0	1+	3+	3+

Pan – T	Anti-felineT lymphocyte marker (572)	PC	Paracortex
CD4	Anti-feline CD4 lymphocyte marker (MAE38)	FM	Follicular mantle
CD8	Anti-feline CD8 lymphocyte marker (117)	FC	Follicular centre
Anti-B	Anti-B lymphocyte marker (B5)	MC	Medullary cords
3	No staining	-	No staining done
1+	Mild staining		
2+	Moderate staining		
3+	Marked staining		

TABLE 11: FIV SEROLOGY RESULTS

ANIMAL NUMBER	PUMA LENTIVIRUS ELISA	PUMA LENTIVIRUS WESTERN BLOT
1	Positive	Positive
2	Positive	Positive
3	Positive	Positive
4	Positive	Positive
5	Positive	Positive
6	Positive	Positive
7	NSA	NSA
8	NSA	NSA
9	NSA	NSA
10	NSA	NSA
11	NSA	NSA
12	Positive	Positive
13	Negative	Negative
14	Positive	Positive
15	Negative	Inconclusive
16	Negative	Negative
17	NSA	NSA
18	Positive	Positive
19	Positive	Positive
20	Positive	Positive
21	Positive	Negative
22	Negative	Negative
23	Negative	Negative

NSA No serum available

TABLE 12: MYCOBACTERIAL CULTURE RESULTS

ANIMAL NUMBER	MYCOBACTERIAL CULTURE
1	Negative
2	NTC
3	NTC
4	NTC
5	Negative
6	Negative
7	Negative
8	Negative
9	Negative
10	Negative
11	Negative
12	NTC
13	NTC
14	NTC
15	NTC
16	NTC
17	NTC
18	NTC
19	Positive
20	Positive
21	Negative
22	Negative
23	Negative

NTC No tissue cultured

TABLE 13: SUMMARY OF IMPORTANT HISTOPATHOLOGICAL CHANGES

ANIMAL NUMBER	IMMUNE SYSTEM	BONE MARROW	PULMONARY	GASTRO-INTESTINAL	RENAL	CUTANEOUS	OCULAR	SKELETAL MUSCLE	MYOCARDIUM	HEPATIC	CNS	THYROID
1 (N1)	Lnn hy,E,N, M,+C Spl N,E,EMH	↑Cells,E	+++ Gran pneum H	Chr gastr SI E + Glossitis	N/A	NTA	N/A	S	+ Myocarditis & degen H	EMH	N/A	NTA
2 (N2)	Lnn hy,E,+C Spl N,E Thy invol	E	+ Interst pneum H	Chr gastr SI E	MGN (GS)	NTA	N/A	+ Myositis S,H	H	N/A	N/A	NTA
3 (N3)	Lnn hy & atr, E,+C,M, GI Spl E	↑Cells,E	+ Interst pneum H	SI E, Cest + Glossitis	MGN (FS)	NTA	+ Ant uveitis	+ Myositis S,H	H	+ React hepat EMH, GI	Sp c haemor	NTA
4 (N4)	Lnn hy,E,+C, M,GI;Spl N,E Thy invol	E,N	+ Interst pneum H	Chr gastr SI E, Cest	N/A	NTA	N/A	+ Myositis S	+ Myocarditis	GI	N/A	NTA
5 (N5)	Lnn atr, E, N, +C Spl N	NTA	+ Interst pneum H	SI E, Cest	N/A	N/A	N/A	S, H, T	+ Myocarditis with degen H	+ React hepat Portal inflam	Mineral of Sp c DM & bvs of CP	N/A
6 (N6)	Lnn hy, E, N, +C, M; Spl fol hy; Thy invol; Ton fol hy,N	E	+ Interst pneum H	Chr gastr SI E, Cest + Colitis	N/A	NTA	N/A	H	+ Myocarditis H	GI	+ WD & Sp c haemor	N/A
7 (PD1)	Lnn hy, E, N, +C Thy invol	NTA	+++ Interst pneu +++ Gran pneum +++ Bronch	Chr gastr Colonic FB penetr	N/A	NTA	N/A	Atr of glossal muscle	+ Myocarditis, H	Portal inflam	Haemor in Cerebel PM & Bst	Lympho thyroiditis
8 (PD2)	Lnn hy, E, +C; Spl fol hy, EMH, pl c; Thy invol; Ton fol atr,N	↑Cells, E	++ Interst pneum H	N/A	N/A	NTA	+ Lympho conjunct	++ Myos with necr & degen Atr glo mus	M/f degen H	N/A	+ M/f mening of sp c	N/A
9 (PD3)	Lnn atr, N, +C, GI Spl fol atr, N, pl c	↑Cells, E, pl c, L,↓ rbc	+++ Gran pneum +++ Bronch + Interst pneum H	St GI, bact, P L/pl ent & p gran;Colon GI; ulc glossitis	MGN (FS);chr inf;CIN;GI	Chr derm; Cellulitis	<i>Trichinella</i> – no reaction	S, H, T	+ Myocarditis H	GI; portal inflam	N/A	N/A
10 (PD4)	Lnn hy & atr, E,+C,M, GI	NTA	++ Interst pneum H	L/pl ent; Nemat	N/A	NTA	+ Ant uveitis	Atr glossal muscle	+ Myocarditis with degen H	EMH; GI	+ Cong	Lympho thyroiditis
11 (PD5)	Lnn atr, E, N,+C, Cryst Spl fol atr, pl c	E,N,pl c, L, ↑ myeloid prec	NTA	St Nemat; SI tremat; + Colitis	MGN (FS);+++ Amyloid	NTA	+ Ant uveitis	S, H, T Atr glossal muscle	M/f fibrosis	N/A	N/A	NTA
12 (PD6)	Lnn atr, E, N +C, Cryst, GI	NTA	+ Interst pneum Adenoma H	N/A	N/A	NTA	N/A	NTA	H	GI	NTA	NTA

TABLE 13 (continued): SUMMARY OF IMPORTANT HISTOPATHOLOGICAL CHANGES

ANIMAL NUMBER	IMMUNE SYSTEM	BONE MARROW	PULMONARY	GASTRO-INTESTINAL	RENAL	CUTANEOUS	OCULAR	SKELETAL MUSCLE	MYOCARDIUM	HEPATIC	CNS	THYROID
13 (PD7)	Lnn atr, E Spl fol hy	NTA	++ Interst pneum	NTA	N/A	NTA	NTA	NTA	+ Myocarditis H	Portal inflamm	NTA	NTA
14 (PD8)	Lnn atr, E, N, +C, M, Cryst, GI	NTA	+ Interst pneum	SI E, FB penetr, Nemat	++ Amyloid	NTA	NTA	NTA	H	GI	NTA	NTA
15 (PD9)	Lnn atr, E, +C Cryst	NTA	++ Interst pneum ++Gran pneum	SI Nemat	N/A	NTA	NTA	NTA	+ Myocarditis H	GI	NTA	NTA
16 (PD10)	Lnn atr, +C, Cryst Spl fol atr	NTA	++ Interst pneum	NTA	N/A	NTA	NTA	NTA	+ Myocarditis with m/f degen H	GI	N/A	NTA
17 (PD11)	Lnn atr, +C, Cryst, GI Spl fol atr	NTA	++ Interst pneum + Gran pneum H	NTA	+ Amyloid	NTA	NTA	NTA	S, H	N/A	N/A	NTA
18 (PD12)	Lnn atr, E, N, ++C, Cryst, GI Spl fol atr	NTA	+ Interst pneum	St H + Interstitial pancreatitis	+ Amyloid	NTA	+ Ant uveitis	+ Myositis with degen T	+ Myocarditis H	GI; + portal inflamm	+ WD (Sp c) M/F malacia in Cerebrum	Lympho thyroiditis
19 (PD13)	Lnn atr, N, +C, M, Cryst, GI	↑Cells, E, pl c, L, ↑ myeloid prec	+++ Gran pneum +++ Bronch H, M	SI L/pl enteritis, Cest, M	MGN (FS) GI	Granuloma- tous Cellulitis	Granuloma- tous Panophthal- mitis	+ Myositis with degen T	H	GI; + portal inflamm	+ WD (Sp c)	NTA
20 (PD14)	Lnn atr, N, ++C, Cryst, GI Spl pl c	E, ↑ mature neutrophils	++ Interst pneum	Chr gastr, P	MGN (FS) + Amyloid	Chr derm; pyoderma Cellulitis	N/A	+ Myos with degen & atr S, H, T	H	React hepat; GI; + portal Inflamm	++ WD (Spc)	N/A
21 (PD15)	Lnn atr, E, ++C, Cryst, M Spl pl c	↑Cells, E, pl c, N ↓ myeloid prec	+ Interst pneum	+ Glossitis with superficial bacteria	MGN (FS) + Amyloid	N/A	N/A	S	+ Myocarditis with degen & fibrosis H	GI; + portal inflamm	N/A	N/A
22 (PD16)	Lnn atr, N, E, +C Ton fol hy, +C	E, N, pl c ↓ myeloid prec	+ Interst pneum H	Chr gastr, GI SI E + Colitis, bact	MGN (FS)	N/A	NTA	+ atr, S, H Atr glossal muscle	+ Myocarditis H	GI	N/A	N/A
23 (PD17)	Lnn hy, N, +C Ton fol hy, N Thy invol	↑Cells, E, pl c	N/A	Chr gastritis + Glossitis	N/A	N/A	NTA	+ Myos with degen. S, H Atr glossal muscle	+ Myocarditis with degen H	GI	N/A	Lympho thyroiditis

+	Mild	CP	Choroid plexus	Hepat	Hepatitis	N	Neutrophils	Sp c	Spinal cord
++	Moderate	Cryst	Crystalline material	hy	Hyperplasia	N/A	No abnormalities	Spl	Splenic
+++	Severe	degen	Degeneration	inf	Infarction	necr	Necrosis	St	Stomach
Ant	Anterior	derm	Dermatitis	inflamm	Inflammation	Nemat	Nematodes	T	Trichinella
atr	Atrophy	DM	Dura Mater	Interst	Interstitial	NTA	No tissue available	Thy	Thymic
bact	Bacteria	E	Eosinophils	invol	Involution	P	Protozoa	Ton	Tonsillar
Bronch	Bronchiectasis	EMH	Extramedullary haematopoiesis	L	Lymphocytes	penetr	Penetration	Tremat	Trematodes
Bst	Brain stem	FB	Foreign body	Lnn	Lymph nodes	p gran	Parasitic granuloma	ulc	Ulcerative
bvs	Blood vessels	fol	Follicular	L/pl	Lymphoplasmacytic	pl c	Plasma cells	WD	Wallerian
C	Cystic spaces	FS	Focal segmental	Lympho	Lymphocytic	PM	Pia mater		Degeneration
Cerebel	Cerebellar	gastr	Gastritis	M	Microfilaria	pneum	Pneumonia		
Cest	Cestodes	GI	Granulomatous inflammation	mening	Meningitis	prec	Precursors		
Chr	Chronic	Gran	Granulomatous	M/f	Multifocal	rbc	Red blood cells		
CIN	Chronic interstitial nephritis	GS	Generalized segmental	Mineral	Mineralization	React	Reactive		
Cong	Congestion	H	Hepatozoon	MGN	Membranous	S	Sarcocysts		
conjunct	Conjunctivitis	haemor	Haemorrhage		glomerulonephritis	SI	Small intestine		