

The osteology of the African elephant (*Loxodonta africana*): vertebral column, ribs and sternum

A.J. BEZUIDENHOUT and C.D. SEEGERs

Department of Anatomy, Faculty of Veterinary Science, University of Pretoria
Private Bag X4, Onderstepoort, 0110 South Africa

ABSTRACT

BEZUIDENHOUT, A.J. & SEEGERs, C.D. 1995. The osteology of the African elephant (*Loxodonta africana*): vertebral column, ribs and sternum. *Onderstepoort Journal of Veterinary Research*, 63:131–147

The vertebral column, sternum and ribs of the African elephant were studied and illustrated. In the cervical series, the vertebrae are characterized by very short (compressed) vertebral bodies and short spinous processes. There are 20–21 thoracic vertebrae that carry ribs, and three lumbar vertebrae. The neural arches of the five sacral vertebrae fuse with each other as well as with the wings of the ilium, while the intervertebral discs do not ossify and the vertebral bodies remain separate. There are 19–21 caudal vertebrae. In the latter, the neural arches of only the first five to six vertebrae fuse dorsally, the vertebral foramina of the other vertebrae as well as the vertebral canal remain open dorsally.

The body of the first rib is greatly expanded while that of the last three to four ribs are reduced. The cartilages of the first six ribs articulate with the sternum, the last five to six ribs do not bear costal cartilages and are not attached to the costal arch.

The sternum consists of five sternabrae that form three approximately equal, but separate, segments. The first segment is formed by the first sternabra, the second segment is formed by the second to fourth sternabrae and the last segment is formed by the fifth sternabra. The first and second sternabrae articulate with each other by means of a synovial joint, the second to fourth sternabrae are fused to each other and the fourth and fifth sternabrae are loosely attached to each other by connective tissue.

Keywords: African elephant, *Loxodonta africana*, osteology, ribs, sternum, vertebral column

INTRODUCTION

Blair (1709) published the first account of the osteology of an elephant. He dissected, studied and measured the bones, including the vertebrae, sternum and ribs, which he obtained from an adult female elephant of unknown age or species. A summary of the number of vertebrae and various aspects of the ribs and sternum reported in the literature for the African and Indian elephant, is given by Güssgen (1988). Eales (1929), Sikes (1971), Wissdorf, Bach,

Leopold-Keighley & Kristensson (1987) and Wissdorf & Bach (1988) also contributed to the existing literature on various aspects of the vertebrae, ribs and sternum. Most authors agree that there are seven cervical vertebrae, but they differ on the number of thoracic, lumbar, sacral and caudal vertebrae present in the African and Indian elephant. Some authors also group the thoracic and lumbar vertebrae together as thoraco-lumbar, stating that the thoracic vertebrae carry ribs and the lumbar vertebrae don't. Eales (1929) states that the difference between the vertebral columns of the African and Indian elephant lies in the thoracic and sacral regions. According to Sikes

(1971), individual variations occur in the vertebral formula of the African elephant.

None of the existing publications, however, contains accurate descriptions or illustrations of the various vertebrae, ribs or sternum. The present study was therefore undertaken to document and illustrate these bones of the African elephant.

MATERIALS AND METHODS

For the present study, the entire vertebral column, sternum and ribs of a 27-year-old female animal was collected and cleaned at the abattoir of the Kruger National Park, South Africa, during the yearly culling period. During the same period, representative samples of all the vertebral series from male and female animals of varying ages, as well as the sternums and ribs from an additional five animals were also collected and cleaned.

The entire skeleton of a mature bull in the collection of the Zoology Department of the University of Pretoria, as well as the vertebral column of an old bull obtained from a local artist, were available for study. A minimum of seven vertebrae in each series were studied.

Fairly marked individual variation was noted and therefore representative examples of each bone (except C6 and C7) were illustrated from at least two aspects to ensure easy identification.

RESULTS

Cervical vertebrae (*Vertebrae cervicales*)

There were seven cervical vertebrae in the specimens examined. Their articular processes are far apart and the vertebral bodies are craniocaudally shortened or compressed, resulting in a relatively short neck. The spinous processes are short and the transverse processes of C1–C6 have transverse foramina. The spinous processes increase in length cranially to caudally, the transverse processes enlarge, the bodies elongate, the articular processes are placed more horizontally and the vertebral foramina change from dome-shaped to triangular in outline.

C1, Atlas (Fig. 1, 2)

The atlas consists of two dorsal arches (*Arcus dorsalis*), two lateral masses (*Massa lateralis*), and two ventral arches (*Arcus ventralis*). All the components unite to surround the vertebral foramen (*Foramen vertebrale*).

The vertebral foramen is constricted along its ventral third, dividing it into a larger dorsal part that con-

tains the spinal cord, and a smaller ventral part that contains the dens of the axis.

The united ventral arches bear a small tubercle (*Tuberculum ventrale*), along the caudoventral mid-line and an articular surface (*Fovea dentis*), dorsally, for the dens of the axis.

The dorsal arches complete the vertebral foramen dorsally. A large, flattened, rough area represents the dorsal tuberculum (*Tuberculum dorsale*). The dorsal tuberculum is divided by a prominent ridge into a larger, smoother cranial part and a smaller, rougher caudal part. A slightly raised ridge separates the left and right halves of the tuberculum. There is no dorsal spine on the atlas.

The lateral masses form the largest part of the atlas. Each lateral mass bears a transverse process or wing (*Ala atlantis*), and articular surfaces for the condyles of the occipital bone cranially, and for the axis, caudally. The wings of the atlas are fairly small and they lie ventrally to the part of the vertebral foramen that contains the spinal cord. Each wing is perforated by a transverse foramen (*Foramen transversarium*). The ventral surfaces of the wings are flattened and do not bear a fossa atlantis. The cranial articular surfaces (*Fovea articularis cranialis*), are ellipsoidal and somewhat crescent-shaped. They are arranged vertically and are not confluent with each other. Caudally, the atlas bears three articular surfaces for articulation with the axis. Centrally, there is an articular surface for the dens (vide supra) and laterally there are two rounded surfaces (*Fovea articularis caudalis*), for articulation with the articular facets of the axis. The latter two surfaces are placed vertically and slightly obliquely in a craniocaudal direction. A shallow groove separates the articular surfaces dorsally from the wing of the atlas and prominent tubercles are present ventrally to the lateral articular surfaces. In young animals, the three caudal articular surfaces are separated from each other, but in older animals, they are confluent. The large lateral vertebral foramen (*Foramen vertebrale laterale*), lies craniodorsally to the wing of the atlas and is connected to the transverse foramen by a shallow groove.

C2, Axis (Fig. 3–5)

The axis consists of a body, ventrally, and vertebral arches, dorsally. On lateral view, the body is pyramidal in outline and approximately twice as long as that of the other cervical vertebra. Cranially, it bears the dens (*Dens*), and two articular surfaces. The dens is 3–4 cm long, pointed and has an articular surface for the atlas, ventrally, a roughened apex for ligamentous attachment, and a rounded, smooth dorsal surface. Lateral to the dens, the body bears two roundish, flat, articular surfaces for articulation with the atlas. The articular surfaces face craniolaterally

(are placed obliquely in a craniocaudal direction) and are continuous along their ventromedial borders with the articular surface of the dens. The caudal extremity of the body is large, round, slightly concave, and has four protruberances along its ventral margin. Two low ridges, one dorsal and one ventral, are present along the dorsal and ventral mid-lines of the body. The ventral ridge and the two central tubercles represent the ventral crest (*Crista ventralis*).

The transverse processes (*Processus transversus*), are attached to the body. They are triangular in outline and have caudolateral-facing apices. They contain the large, transverse foramina that lie opposite the caudal border of the body.

The vertebral arch bounds the vertebral foramen laterally and dorsally. Caudally, it bears two articular processes and dorsally, the spinous process. The spinous process (*Processus spinosus*), is low, rough and tuberosus. Its cranial border has a rough prominence and its caudal border is divided. The division is deep in young animals and tends to close in old animals, especially ventrally. The caudal articular processes (*Processus articularis caudalis*), have articular surfaces which are rectangular in outline, flattened and are ventro-caudolateral facing. Rough ridges are present along the dorsolateral borders of the articular surfaces. Deep grooves or notches (*Incisura vertebralis caudalis*), are present caudally, between the vertebral arch and the caudal extremity of the body. Shallow notches (*Incisura vertebralis cranialis*), are present cranially, between the vertebral arch and the articular surfaces for the atlas.

C3–5 (Fig. 6–8)

Cervical vertebrae 3–5 differ from each other only in the length of the spinous process. The description that follows is that of C4.

The body is round and very compressed (short). Its cranial extremity is convex around the periphery, but slightly concave, centrally. The caudal extremity is concave and the concavity is deeper ventrally than it is dorsally. The vertebral arches bear cranial and caudal articular facets and a short spinous process. The roof of the vertebral foramen is dome-shaped, while the floor is more or less flat (horizontal). The cranial articular facets bear articular surfaces medially, and large, flat tubercles, laterally. The articular surfaces are rectangular in outline, slightly S-shaped and placed obliquely so that they are craniomedial and slightly dorsal facing. Similarly, the caudal articular facets bear S-shaped articular surfaces that are ventrolateral facing to accommodate the cranial articular surfaces of the following vertebra and large tubercles, dorsomedially. A short, narrow and laterally flattened spinous process is present dorsally to the vertebral arch. The cranial vertebral incisure between the body and the cranial articular facet is

shallow, while the caudal vertebral incisure between the body and the caudal articular facet is deep. The latter forms the major part of the intervertebral foramen.

The transverse processes are short, in cranial view almost rectangular, and contain the large transverse foramina. The foramen reduces the process to a sturdy ventral pedicle, a thinner lateral pedicle and a thin dorsal pedicle. Caudally, a deep groove is present between the transverse process and the vertebral body. The groove extends from the caudal vertebral incisure to the transverse foramen.

C6 (Fig. 9)

The sixth cervical vertebra differs from the preceding vertebrae in that the ventral part of the transverse process is expanded to form a ventral lamina. The lamina ossifies slowly and at 50 years of age, is only partially ossified.

C7 (Fig. 10)

The seventh cervical vertebra differs from the other cervical vertebrae: It bears two articular surfaces (*Fovea costalis caudalis*) ventrolaterally to the caudal extremity of the body, for articulation with the head of the first rib. Its transverse processes lack transverse foramina. Its spinous process is the longest and its body the widest in the cervical series. The articular processes are also more horizontally placed than those of the more cranially situated vertebrae, and the vertebral foramen is almost triangular in outline.

Thoracic vertebrae (*Vertebrae thoracicae*)

There are 20–21 thoracic vertebrae present in the specimens that were examined. The thoracic vertebrae are characterized by the presence of cranial and caudal costal articular facets (with the exception of the last three to four thoracic vertebrae which have only cranial costal facets) and reduced transverse processes that bear articular facets for the tubercles of the ribs (also see ribs). Their spinous processes incline caudally and rapidly increase in length from T1 to T3, and then gradually decrease in length. Furthermore, the proximal extremities of the spinous processes are enlarged, those of T2 and T3 being the largest. The vertebral bodies increase in length but decrease in diameter cranially to caudally in the series. The articular facets are small compared with those of the cervical vertebrae, and are placed closer together. Mamillary processes are present on the last few thoracic vertebrae only. Some of the thoracic vertebrae had uni- or bilateral dorsal vertebral foramina. The description that follows is that of T1 which represents the cranial part of the series, T10, which represents the middle of the series, and T20, which represents the caudal part of the series.

Cranial series, T1 (Fig. 11–13)

The first thoracic vertebra resembles a cervical vertebra in general outline. However, compared with cervical vertebrae, the vertebral body is noticeably smaller in diameter but longer, the spinous process is considerably longer, and the transverse processes are more massive, but without transverse foramina.

The body is somewhat flattened dorsally and ventrally and bears large, concave cranial and caudal costal articular facets. The facets do not encroach onto the cranial and caudal extremities of the body, but are ventrolaterally confluent with each other. The cranial extremity is convex and the caudal extremity, concave.

The vertebral arches consist of two long laminae dorsally and two short pedicles ventrally. Together, they form the lateral walls of the bell-shaped vertebral foramen. The ventrolateral angle of the vertebral foramen forms a deep caudal-vertebral notch that is continuous with a deep groove between the transverse process and the caudal extremity of the vertebral body. The cranial articular facets face dorso-cranially, the caudal ones are placed closer together, facing ventrocaudally. A large, roughened area is present on the laminae between the cranial and caudal articular facets.

The transverse processes are short, but large, and are directed ventrolaterally. Distally, they bear articular facets, *Fovea costalis processus transversi*, for articulation with the tubercles of the ribs. Proximal to the articular surface is an enlarged and rough tubercle.

The spinous process is long (twice the diameter of the vertebral body) and inclines caudally. Its cranial margin is sharp, whereas the caudal margin is wide and grooved proximally, and narrow and sharp, distally. The distal extremity is slightly enlarged.

Middle series, T10 (Fig. 14–16)

The body of the tenth thoracic vertebra is heart-shaped and bears a ventral crest. Its cranial extremity is convex, while the lateral part and the caudal extremity are concave. Compared with T1, the cranial and caudal costal articular surfaces are smaller and are not confluent, the vertebral foramen is rounded and smaller in diameter, and the pedicles of the vertebral arch are as long as the laminae. The transverse processes are sturdy and almost square; they are horizontally placed and bear small costal articular surfaces on the ventral aspect of the caudo-distal angles. The articular facets are small and close to each other, and the articular surfaces of the cranial facets are directed dorsally, while those of the caudal facets are directed ventrally. The spinous process inclines steeply, caudally. Its cranial margin is sharp, the caudal margin is deeply grooved over

most of its length, and the tip is slightly expanded. The cranial vertebral incisure is shallow, whereas the caudal one is deep.

Caudal series, T20 (Fig. 17–19)

The body of the twentieth thoracic vertebra is heart-shaped, but wider and longer than that of T10. The cranial extremity is almost flat, with a shallow central depression, while the caudal extremity is slightly concave. Ventrally, the body bears a low ventral spine and two tubercles close to the caudal extremity. Only cranial costal articular surfaces are present on the body. They lie caudally to the cranial extremity at the junction of the body and the vertebral arches. A distinct tubercle is present on the pedicle of the vertebral arch along the craniodorsal margin of each costal articular surface.

The pedicle of the vertebral arch is as long as the lamina. A large mamillary process (*Processus mamillaris*), is present between the cranial articular facet and the transverse process. The cranial articular facets are slightly S-shaped and sagittally positioned, and the articular surfaces face dorsocranially. The caudal articular facets are shaped to accommodate the cranial facets of the following vertebra and are therefore closer to each other and lie on a plane, dorsally to the cranial articular facets. The cranial vertebral notch is shallow, whereas the caudal notch is deep and lies between the transverse process and the vertebral body. Compared with that of T10, the transverse process is small, it projects caudally, and it does not bear a costal articular facet for the tubercle of the rib. The spinous process is short, wide and is almost vertical. Its cranial border is sharp. The proximal end of the caudal border bears a shallow groove and the distal extremity is slightly enlarged. The vertebral foramen is pear-shaped.

Lumbar vertebrae (*Vertebrae lumbales*) (Fig. 20–22)

There were three lumbar vertebrae in the specimens examined. They closely resemble the last few thoracic vertebrae, but do not bear costal articular facets. The description that follows is that of L2.

The body is almost cubic in outline and bears two tubercles along its ventral surface (these tubercles are present on the vertebral bodies of T20–L2). Its cranial extremity is slightly convex around the periphery, with a shallow central depression. The caudal extremity is slightly concave and its transverse diameter is larger than the vertical diameter.

The articular surfaces of the cranial articular facets face dorsocranially and the latter processes bear large, cranially directed mamillary processes. The caudal articular facets resemble those of the caudal thoracic vertebrae.

The transverse processes are relatively small, dorsoventrally flattened and directed caudolaterally. Contrary to the position in the thoracic vertebrae, the spinous process is short and wide. It inclines caudally, its cranial margin is sharp, the caudal margin bears a shallow groove and the proximal extremity is slightly expanded. The vertebral foramen is triangular to bell-shaped in outline, the cranial-vertebral incisures are shallow and the caudal incisures are deep.

Sacral vertebrae or sacrum (*Os sacrum*) (Fig. 23–26)

There were five sacral vertebrae in the specimens studied. Various parts of the individual vertebrae, to a greater or lesser degree, fuse with each other to form the sacrum. In some specimens, the last lumbar and the first caudal vertebrae, as well as the wing of the ilium, also fuse with the sacral vertebrae. For the following description of the sacrum, specimens consisting of sacral vertebrae only were used.

From cranial to caudal, the bodies of the sacral vertebrae rapidly decrease in size and, to a very limited extent, fuse with each other. Their intervertebral discs are thin and tend not to ossify. The transverse processes fuse with each other and, in old animals, also with the wing of the ilium. All the cranial articular facets bear mamillary processes. The articular surfaces of the first three pairs of articular facets ossify, the remaining pairs ossify only in old animals. In old animals, the articular facets fuse with the wing of the ilium.

In most specimens, the distal ends (tips) of the spinous processes of S2–S4 fuse with each other, forming a median sacral crest (*Crista sacralis mediana*). Although the processes fuse, small interarcuate spaces remain between S2–S3 and S3–S4. The spinous process of the first and last sacral vertebrae are free, and distinct interarcuate spaces are seen between S1–S2 and S4–S5.

The vertebral foramens of successive sacral vertebrae form the sacral canal (*Canalis sacralis*). The canal is triangular in shape and is wide, cranially, but narrows from cranial to caudal, so that the cranial part is about twice the diameter of the caudal part.

Owing to the fusion of the various parts of the sacral vertebrae, the cranial and caudal vertebral notches are transformed into dorsal and ventral sacral foramens. The ventral foramens (*Foramina sacralia ventralia*), are oval to round and of even size, while the dorsal foramens (*Foramina sacralia dorsalia*), vary greatly in size and shape. The first dorsal pair is elongated and irregular in outline, the second pair is greatly reduced and are generally double, the third pair are oval and larger than the preceding pair, while the fourth pair are large and oval.

The sacrum is pyramidal in outline and consists of a base, lateral parts and an apex with dorsal and ventral or pelvic surfaces. The base (*Basis ossis sacri*), is formed by the cranial part of the first sacral vertebra and consists of the cranial extremity with a promontorium (*Promontorium*), and cranial articular facets. The lateral part (*Pars lateralis*), consists of a wing (*Ala sacralis*), and an auricular surface (*Facies auricularis*). The wing is relatively small and is almost vertical. The auricular surface is large, very rough, faces dorsolaterally and is oval in outline. In old animals it contains a second pair of dorsal sacral foramens. The dorsal surface bears the median sacral crest that is formed by the spinous processes, two intermediate crests (*Crista sacralis intermedia*), formed by the articular and mamillary processes, and the dorsal sacral foramens. An intermediate crest is present in old animals only. In younger animals, the processes do not fuse with each other. The pelvic surface (*Facies pelvina*), is smooth, slightly concave and contains the ventral sacral foramens. The apex (*Apex ossis sacri*), is formed by the caudal part of the last sacral vertebra.

Caudal vertebrae (*Vertebrae caudales*) (Fig. 27–30)

There are 19–21 caudal vertebrae in the African elephant. From the first to the last, they progressively lose their processes and neural arches so that finally only rod-like vertebral bodies remain.

The first three to six caudal vertebrae have all the characteristics of a typical vertebra. The neural arches fuse dorsally to form a tuberos spinous process. However, from cranially to caudally, the spinous processes are reduced and disappear between the fourth and the sixth vertebrae. Beyond this point, the neural arches do not fuse, leaving the neural canal open, dorsally. The neural arches become progressively smaller and beyond the twelfth caudal vertebra, are reduced to two low, longitudinal ridges on the dorsal surfaces of the vertebral bodies. Articular facets and surfaces are present only on the cranial aspect of the first caudal vertebra. Caudally to this point, only the vertebral bodies articulate with each other. The transverse processes are also reduced cranially to caudally, and finally remain as two low, longitudinal ridges along the lateral aspects of the vertebral bodies. Haemal processes were not observed, but a median ventral ridge was present beyond the sixteenth to seventeenth caudal vertebrae.

Ribs (*Costae*) (Fig. 31–35)

There are 20–21 pairs of ribs in the African elephant. Of these, the first six pairs are sternal or true ribs (*Costae verae*), and the rest are asternal or false ribs (*Costae spuriae*). The first 15–16 pairs of ribs bear costal cartilages. The costal cartilages of the sternal

ribs articulate directly with the sternum by means of synovial joints, while the costal cartilages of the asternal ribs attach to each other, forming the cartilaginous costal arch (*Arcus costalis*). The last five to six pairs of asternal ribs are not attached to the sternum or costal arch. In some specimens, the last rib resembles a lumbar transverse process and does not carry a costal cartilage.

Each rib consists of a head, (*Caput costae*), a neck (*Collum costae*), and a body, (*Corpus costae*). A rib tubercle (*Tuberculum costae*), is present on each of the first 12–14 pairs of ribs.

The head of the rib articulates with the vertebral body. The heads of the first 17–18 ribs articulate with successive vertebral bodies and the intervertebral discs, while the last few ribs articulate only with the vertebral bodies. The articular surfaces of the first 17–18 ribs are therefore divided into cranial and caudal parts. The cranial part becomes smaller and the caudal part, bigger, cranially to caudally in the series, until only the caudal part remains in the last few ribs. The last few ribs therefore articulate only with the lateral surface of the corresponding vertebral body.

The neck of the rib joins the head with the body. In the first few pairs of ribs, the neck joins the body at right angles, forming acute rib angles. This angle rapidly increases cranially to caudally in the series, to reach 180° at the seventh to eighth rib.

Rib tubercles are present on the dorsal surfaces of the first 12–14 ribs. They are situated at the junction of the neck and body and articulate with the transverse processes of the thoracic vertebrae.

The rib bodies vary greatly in size and shape. The body of the first rib is paddle-shaped. It is flattened lateromedially, the distal half is greatly expanded craniocaudally, its cranial border is rounded, and the caudal border is sharp. The distal, expanded part of the body is attached to the first rib cartilage that articulates with the first sternabra. Cranially to caudally in the series, the rib bodies become longer, narrower and more rounded with a gentle dorsoventral curve. The distal parts of the bodies remain flattened and the cranial and caudal borders bear grooves for the intercostal blood vessels and nerves. Caudally in the series, the caudal grooves become shallower and are absent in the last two to three ribs. In addition, the proximal part of the caudodorsal borders are roughened where muscles attach. The maximum length of the rib bodies are attained at the seventh to eighth rib.

Sternum (*Sternum*) (Fig. 36, 37)

The sternum of the African elephant consists of five sternabrae that, to a greater or lesser degree, fuse

with each other. It is laterally compressed to form a keel. The sternum and its cartilaginous processes are divided into three separate, approximately equal, segments. The first segment is the manubrium, the second consists of sternabrae 2–4 and the third segment is the xiphoid process. The first and second sternabrae articulate with each other by means of a synovial joint, the second to fourth sternabrae fuse with each other to such an extent that the fusion lines can be distinguished only in young animals, and the fourth and fifth sternabrae are attached to each other by connective tissue. Costal facets (*Incisurae costales*), for articulation of the first six pairs of rib cartilages, are present along the dorsolateral surface of the sternum. The costal articular facets of the first pair of ribs are located on the first sternabra, those for ribs 2–4 are located between successive sternabrae, while the facets for ribs 5 are located on the caudal end of the fourth sternabra, and those of ribs 6 on the dorso-cranial surface of the fifth sternabra.

The first sternabra or manubrium (*Manubrium sterni*), is very large. Its cranial half is expanded by a large, cranially directed process, the tip of which bears a small manubrial cartilage. Two rounded facets for articulation with the costal cartilages of the first ribs are located along the middle of the dorsal border of the manubrium.

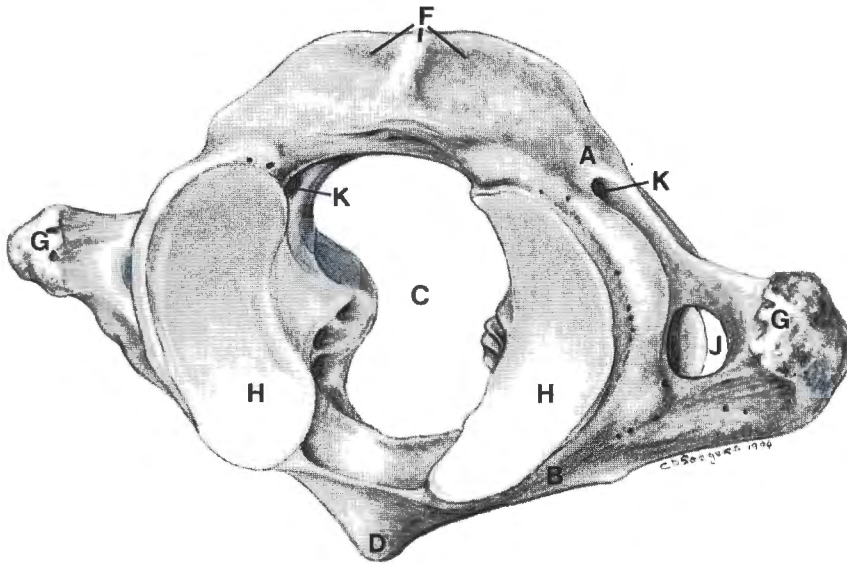
The fifth sternabra or xiphoid process (*Processus xiphoides*), is very small and bears a large, caudally directed xiphoid cartilage. The caudal part of the cartilage is expanded and dorsoventrally flattened, giving it an arrowhead shape.

DISCUSSION

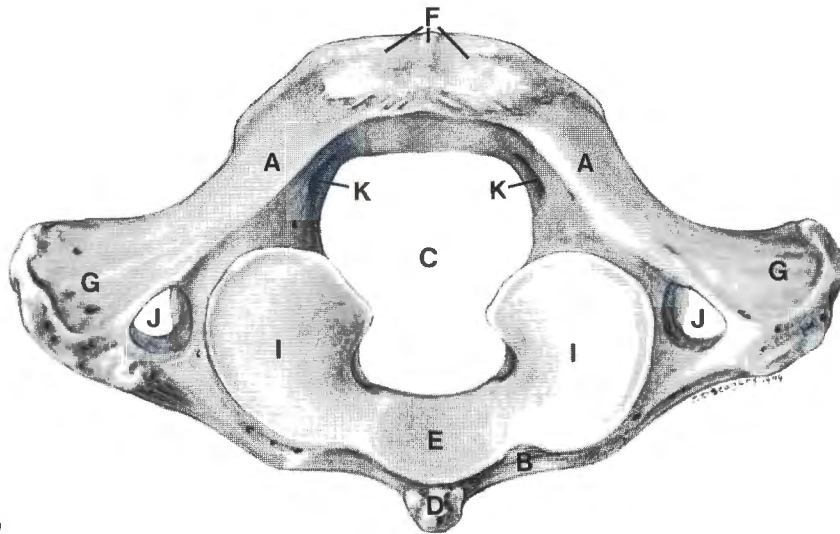
The reported number of thoracic, lumbar, sacral and caudal vertebrae in the elephant varies. The present study agrees with Eales (1929) that there are 20–21 thoracic vertebrae and three lumbar vertebrae in the African elephant. There is, however, a marked difference in the number of sacral vertebrae mentioned in the literature. Eales (1929) and Sikes (1971) describe six sacral vertebrae in the foetus of the African elephant, but only four sacral vertebrae in the adult (Sikes 1971). In the present study, five sacral vertebrae were found in all the specimens that were examined. There was no indication that the sacral vertebrae fused to such an extent that individual vertebrae could not be identified. The last sacral and first caudal vertebrae are very similar in outline. It is therefore conceivable that Eales (1929) and Sikes (1971) mistook the first caudal vertebra for the last sacral vertebra. The reported number of caudal vertebrae also vary greatly. In the present study 19–21 caudal vertebrae were present, while Eales (1929) and Sikes (1971) found 28–33. The reason for this large discrepancy is not clear.

KEYSTO FIG. 1-22

- | | | | |
|---|------------------------------------|---|--|
| A | <i>Arcus dorsalis</i> | N | <i>Crista ventralis</i> |
| B | <i>Arcus ventralis</i> | O | <i>Processus transversus</i> |
| C | <i>Foramen vertebrale</i> | P | <i>Processus spinosus</i> |
| D | <i>Tuberculum ventrale</i> | Q | <i>Processus articularis cranialis</i> |
| E | <i>Fovea dentis</i> | R | <i>Processus articularis caudalis</i> |
| F | <i>Tuberculum dorsale</i> | S | <i>Incisura vertebralis cranialis</i> |
| G | <i>Ala atlantis</i> | T | <i>Incisura vertebralis caudalis</i> |
| H | <i>Fovea articularis cranialis</i> | U | <i>Lamina ventralis</i> |
| I | <i>Fovea articularis caudalis</i> | V | Cartilaginous or unossified part |
| J | <i>Foramen transversarium</i> | W | <i>Fovea costalis cranialis</i> |
| K | <i>Foramen vertebrale laterale</i> | X | <i>Fovea costalis caudalis</i> |
| L | <i>Corpus vertebrae</i> | Y | <i>Fovea costalis processus transversi</i> |
| M | <i>Dens</i> | Z | <i>Processus mamillaris</i> |



1



2

FIG. 1 Atlas, oblique cranial view

FIG. 2 Atlas, caudal view

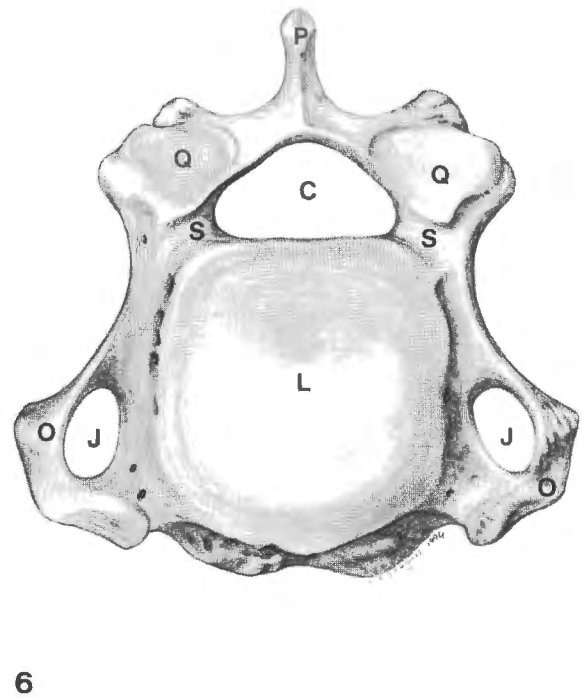
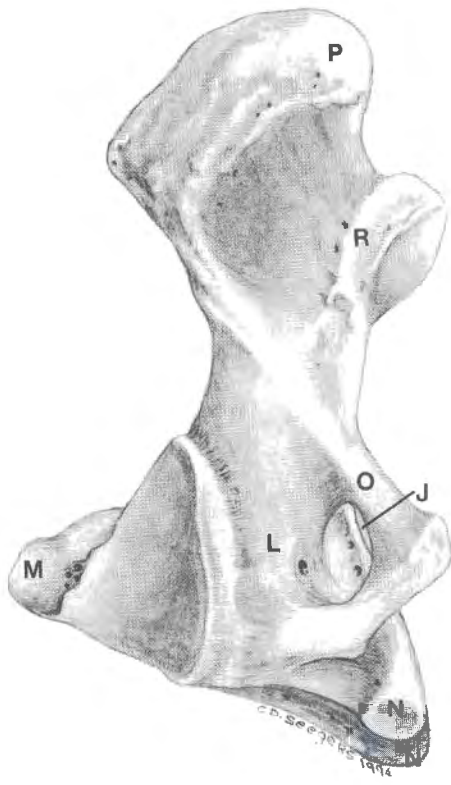
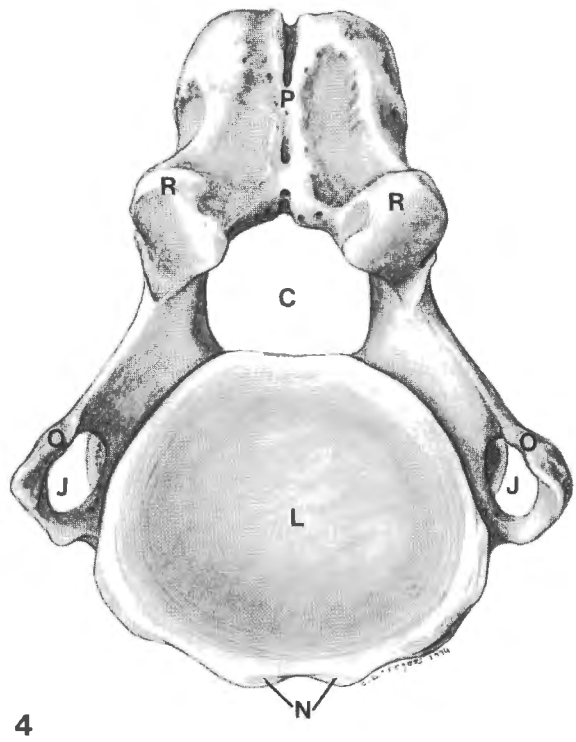
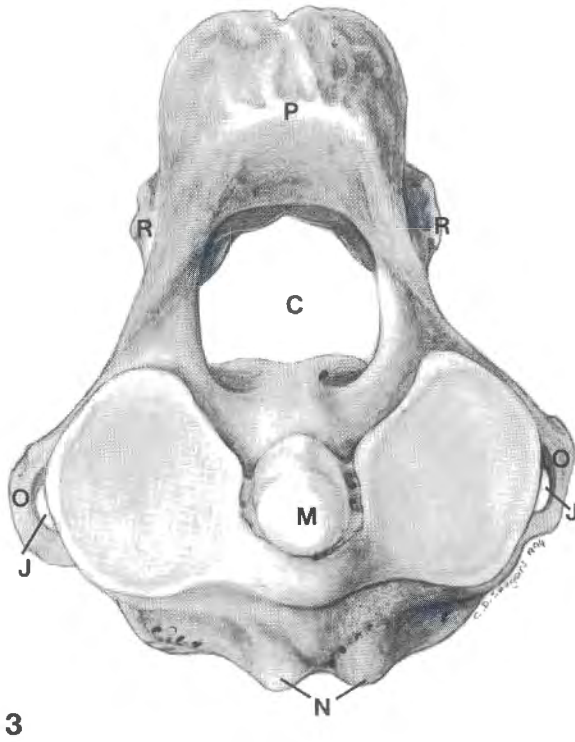
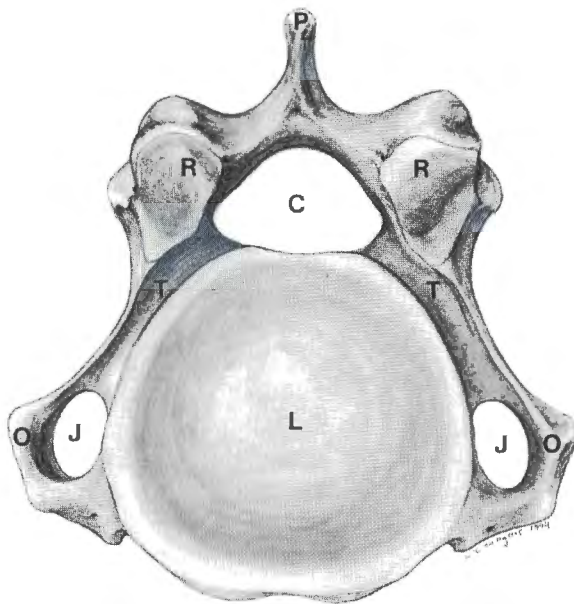
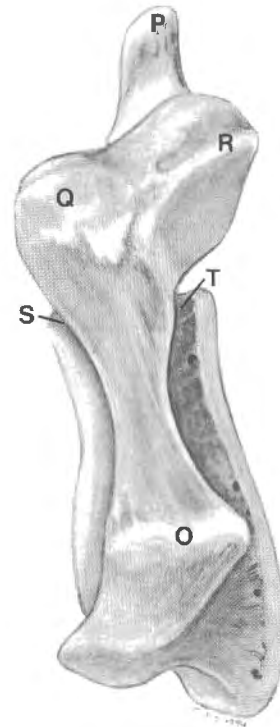


FIG. 3 Axis, cranial view
FIG. 4 Axis, caudal view

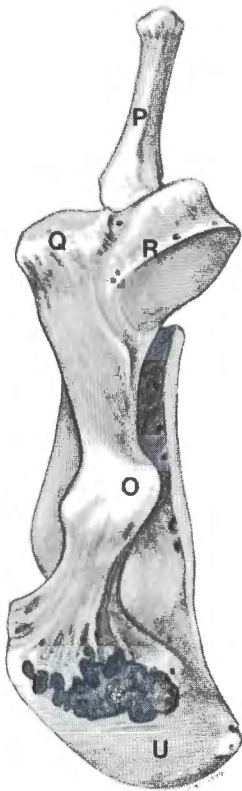
FIG. 5 Axis, left lateral view
FIG. 6 C4, cranial view



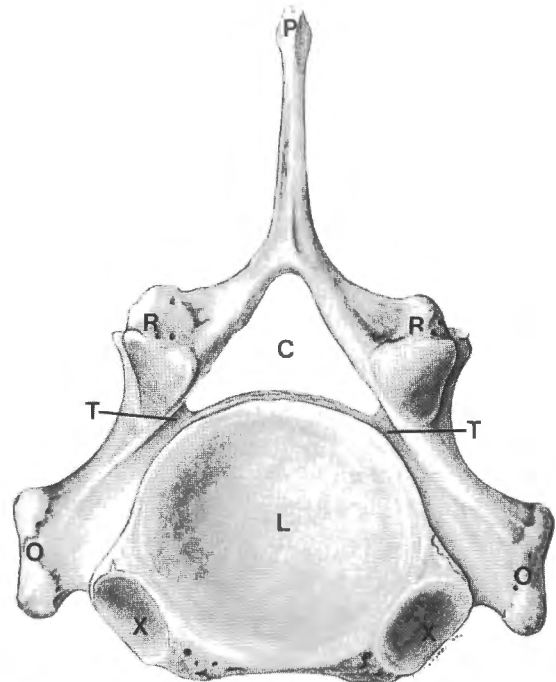
7



8



9



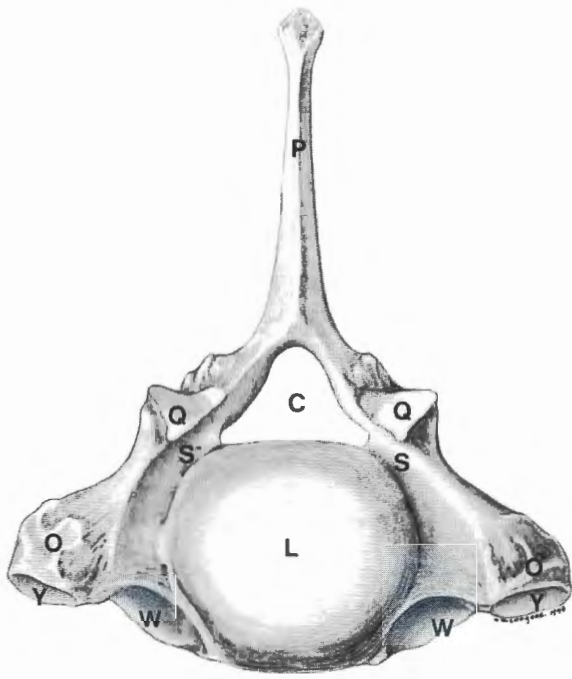
10

FIG. 7 C4, caudal view

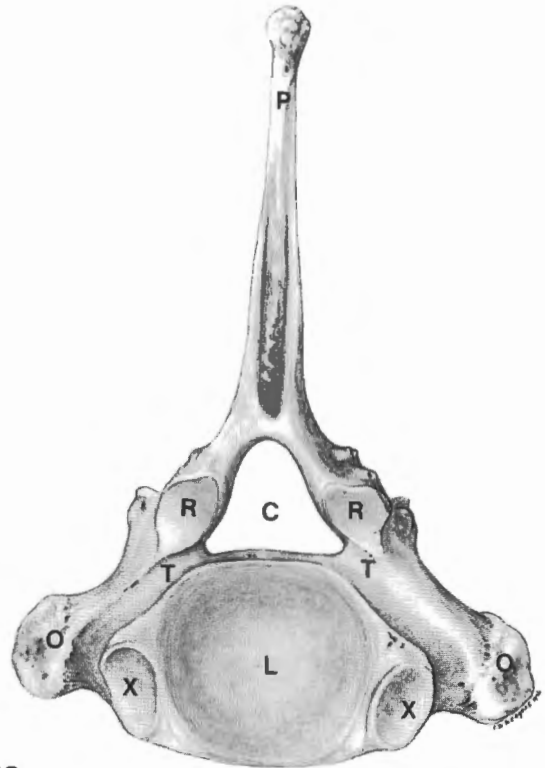
FIG. 8 C4, left lateral view

FIG. 9 C6, left lateral view

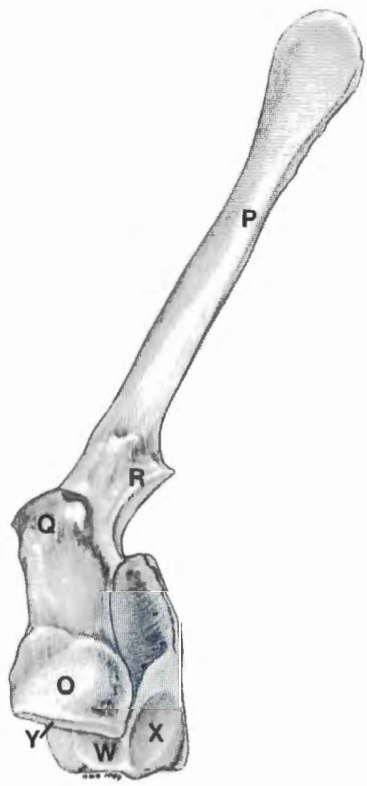FIG. 10 C7, caudal view



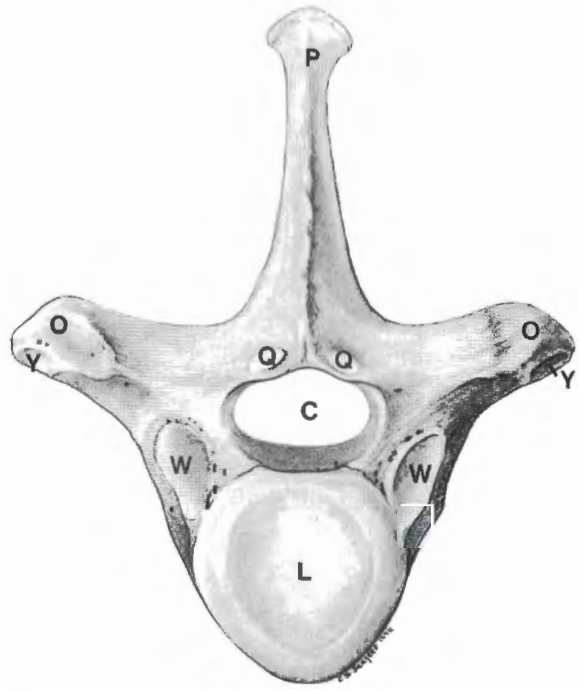
11



12



13



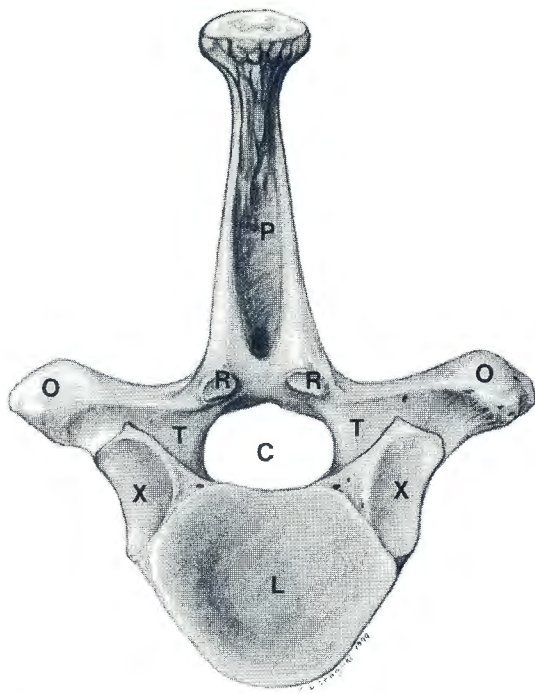
14

FIG. 11 T1, cranial view

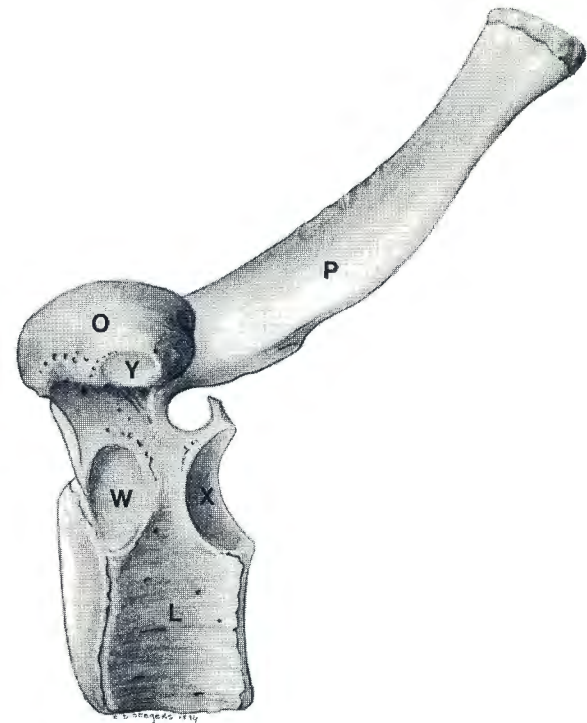
FIG. 12 T1, caudal view

FIG. 13 T1, left lateral view

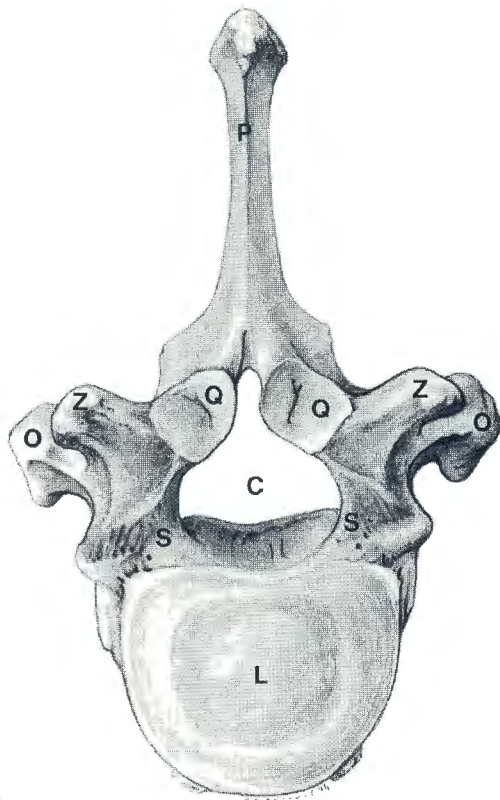
FIG. 14 T10, cranial view



15



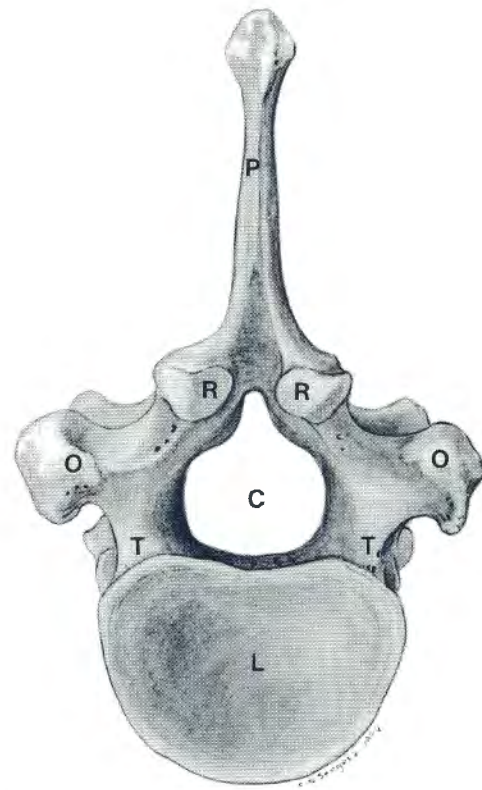
16



17

FIG. 15 T10, caudal view

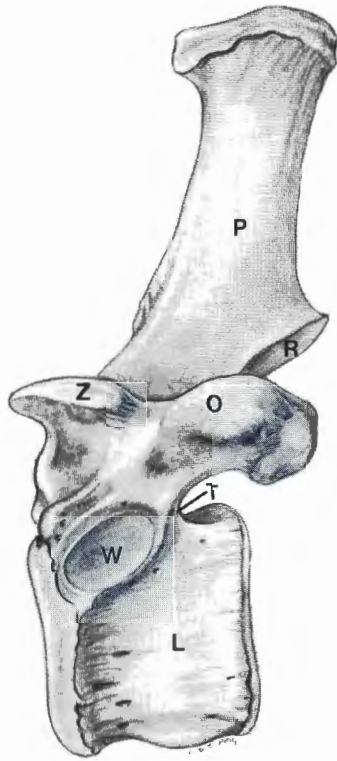
FIG. 16 T10, left lateral view



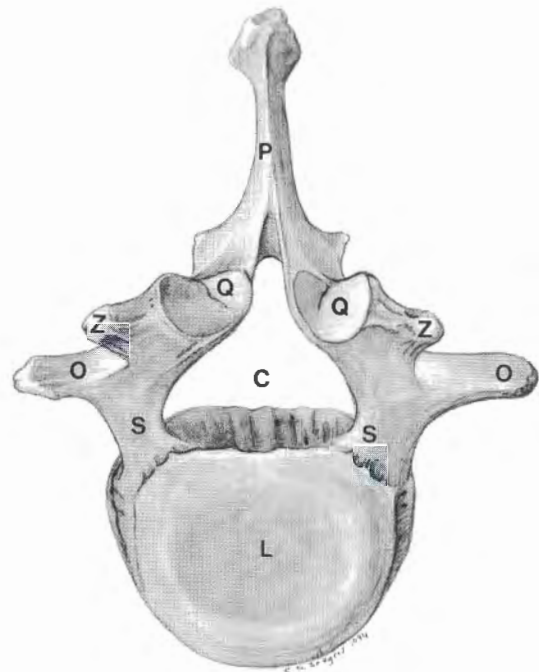
18

FIG. 17 T20, cranial view

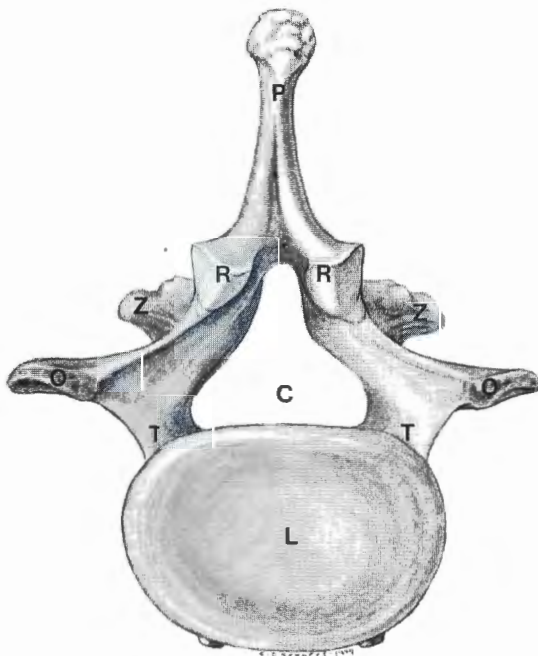
FIG. 18 T20, caudal view



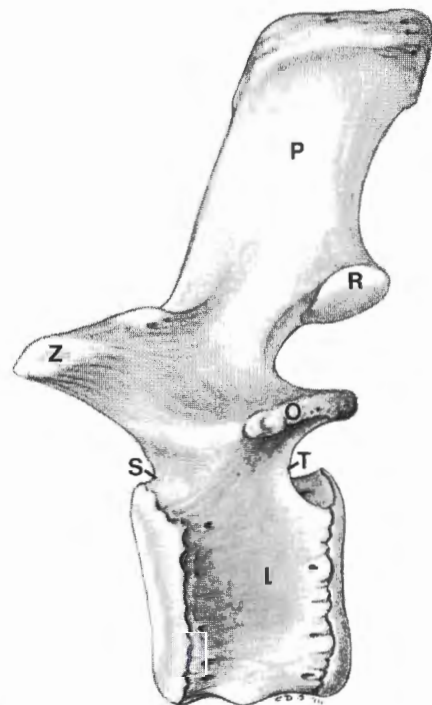
19



20



21



22

FIG. 19 T20, left lateral view

FIG. 20 L2, cranial view

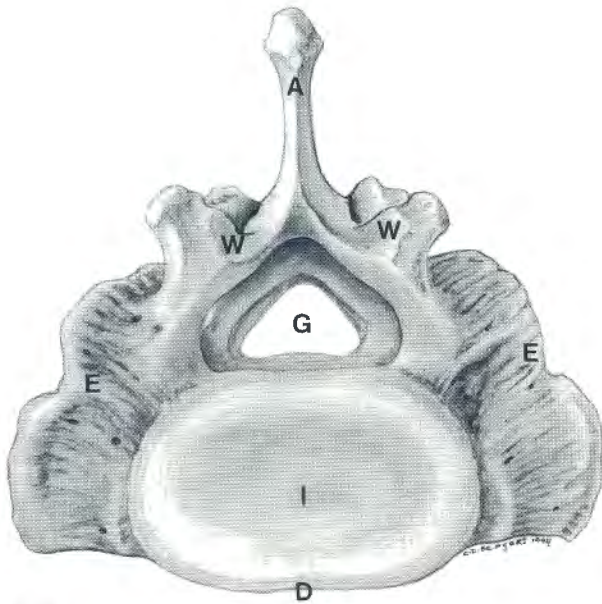
FIG. 21 L2, caudal view

FIG. 22 L2, left lateral view

KEYSTO FIG. 23– 37

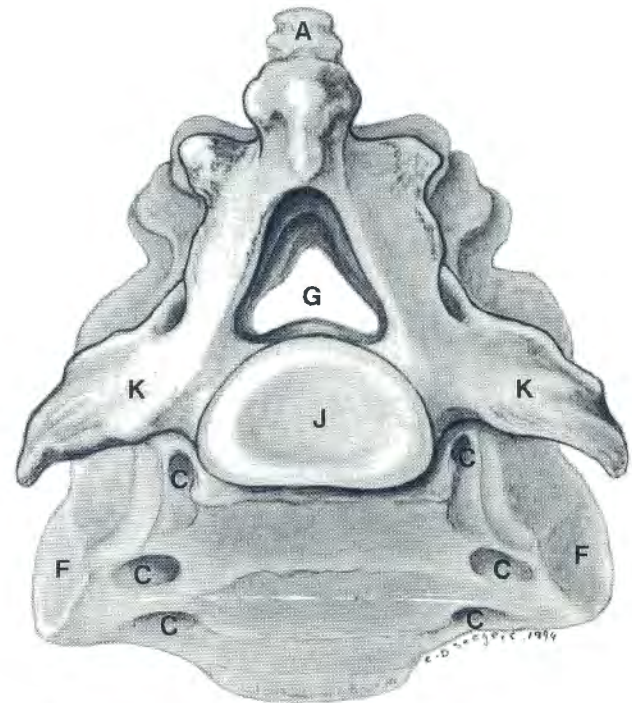
- A *Crista sacralis mediana*
- B *Foramina sacralia dorsalia*
- C *Foramina sacralia ventralia*
- D *Promontorium*
- E *Ala sacralis*
- F *Facies auricularis*
- G *Canalis sacralis*
- H *Crista sacralis lateralis*
- I *Basis ossis sacri*
- J *Apex ossis sacri*
- K *Processus transversus*
- L *Discus intervertebralis*

- M *Corpus vertebrae*
- N *Foramen vertebrale*
- O *Processus spinosus*
- P *Caput costae*
- Q *Collum costae*
- R *Corpus costae*
- S *Manubrium sterni*
- T *Processus xiphoideus*
- U *Cartilago xiphoidea*
- V *Incisurae costales*
- W *Facies articularis cranialis*
- X *Tuberculum costae*



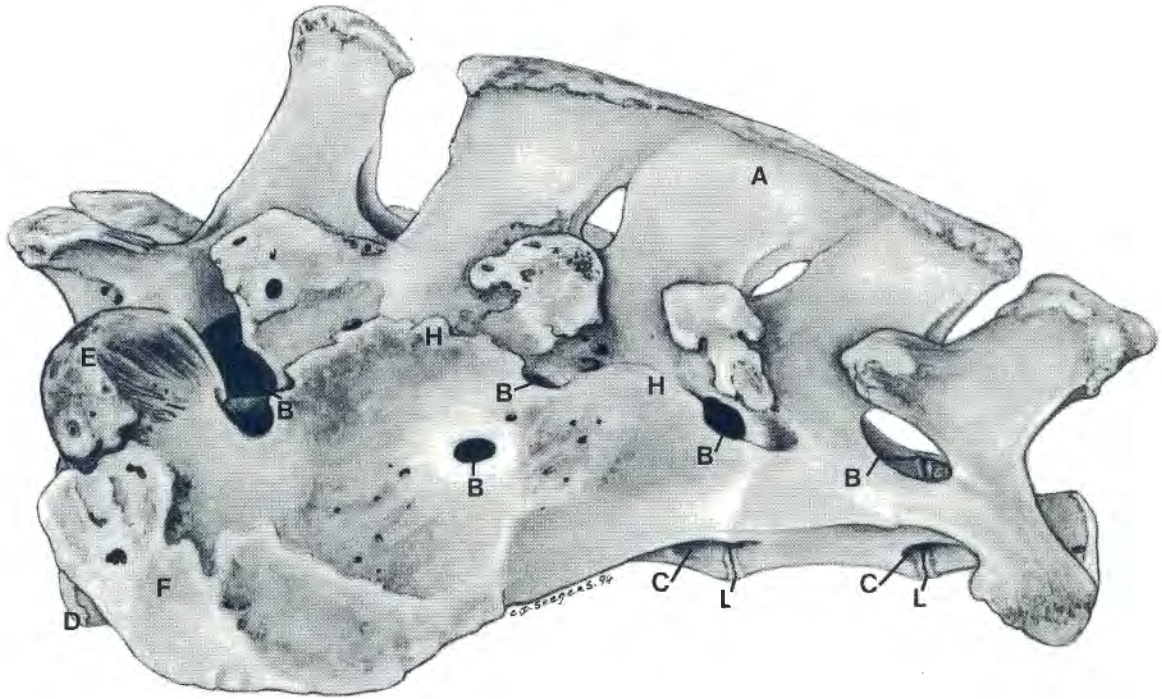
23

FIG. 23 Sacrum, cranial view

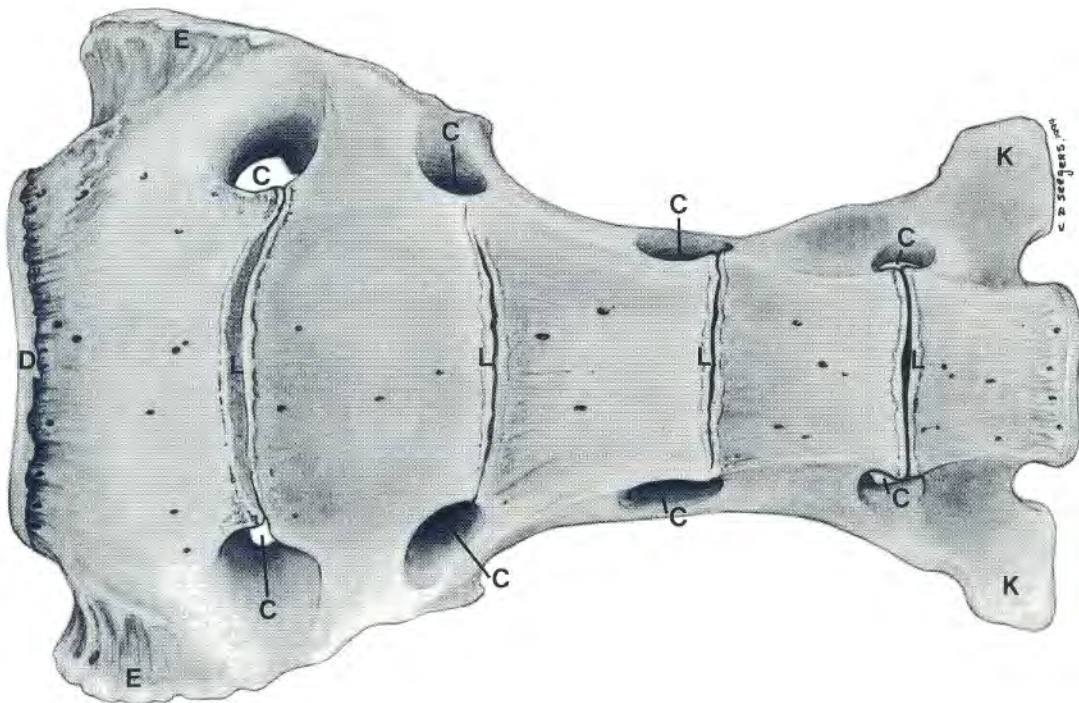


24

FIG. 24 Sacrum, caudal view



25



26

FIG. 25 Sacrum, left lateral view

FIG. 26. Sacrum, ventral view

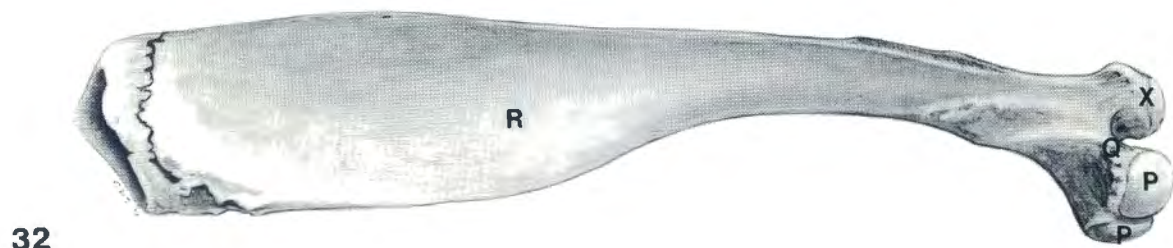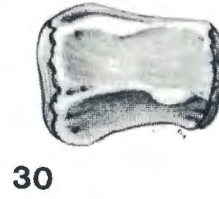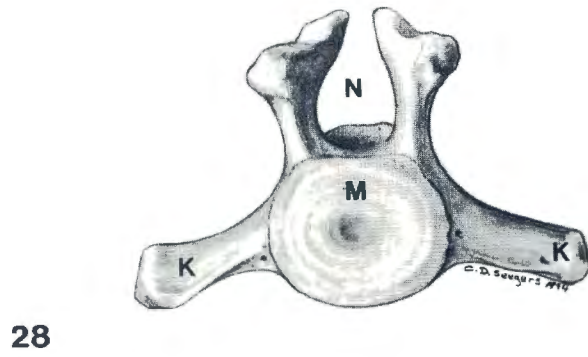
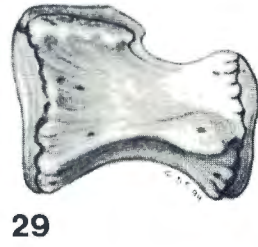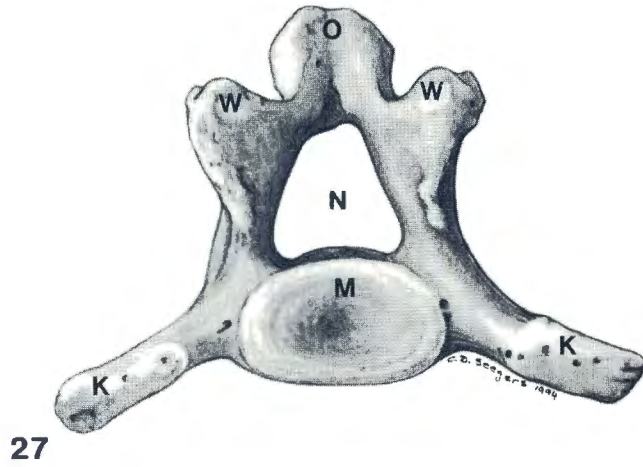


FIG. 27 Cd1, cranial view

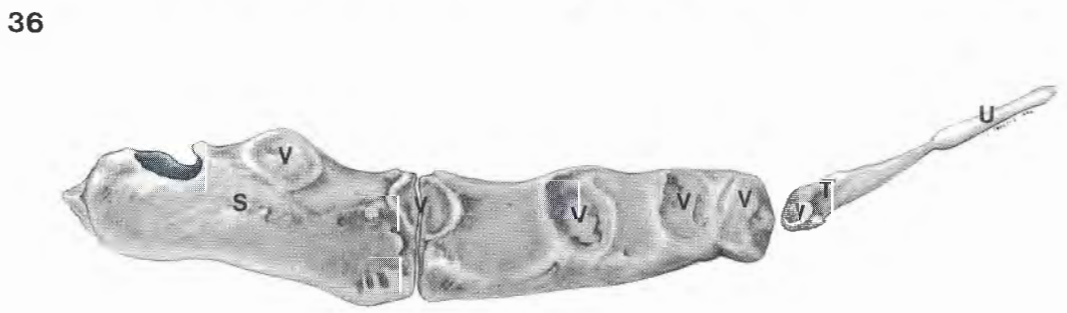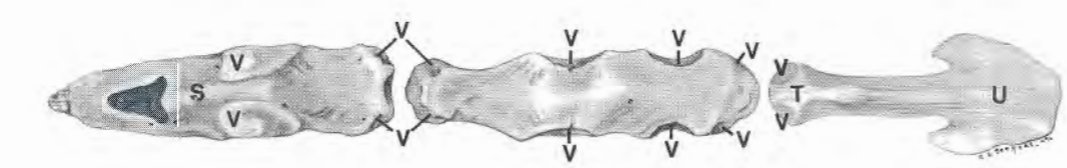
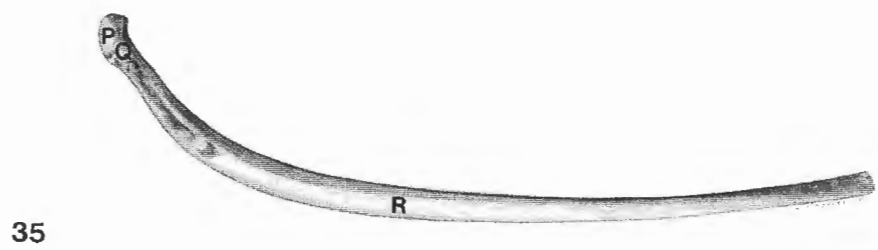
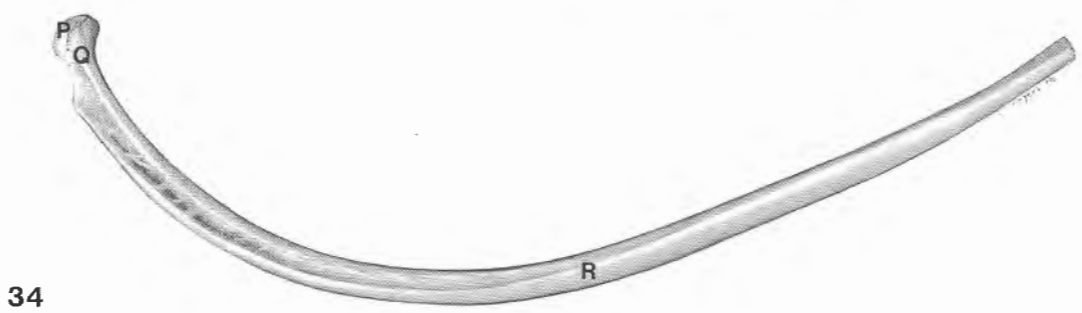
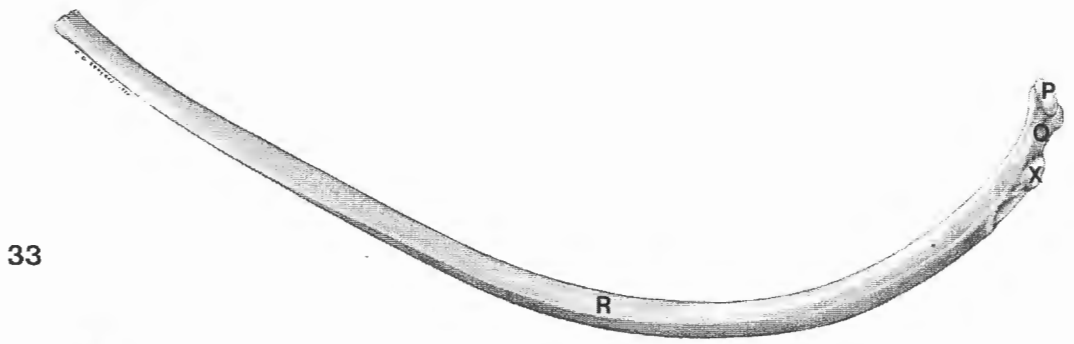
FIG. 28 Cd7, cranial view

FIG. 29 Cd13, left lateral view

FIG. 30 Cd18, left lateral view

FIG. 31 First rib (left), lateral view

FIG. 32 First rib (left), medial view



37

FIG. 33 Ninth rib (right), caudal view
FIG. 34 Ninth rib (right), cranial view
FIG. 35 Last rib (right), cranial view

FIG. 36 Sternum, dorsal view
FIG. 37 Sternum, left lateral view

According to Wissdorf and Bach (1988), the neural arches caudal to the ninth or tenth caudal vertebrae of the Indian elephant, do not fuse dorsally, leaving the neural canal open. In the present study, this was found to be the situation caudally from the fourth to sixth caudal vertebrae, therefore complicating the use of the middle caudal vein for venipuncture.

The present study agrees with Sikes (1971) that cranial and caudal articular facets are present for the heads of the ribs on the first 14–16 thoracic vertebrae, thereafter only the cranial facets are present. Furthermore, the latter author states that only the first thoracic vertebra has facets for the tubercles of the first ribs. In the present study, articular facets for the rib tubercles were present on the first 12–14 thoracic vertebrae.

Blair (1709) states that the sternum of the elephant consists of four bones and that the first eight (four pairs) ribs are attached to the sternum. According to Eales (1929) the sternum of a foetal African elephant consists of three separate segments, the first being the longest. The latter author states that the first segment articulates with the first pair of ribs, while ribs 2–6 articulate with the middle segment and the last segment does not carry facets for ribs. This is in contrast to the present study in which three segments of equal length were found, of which the middle segment carried facets for ribs 2–5 and the last segment carried facets for the sixth pair of ribs.

The number of sternal and asternal ribs present in the elephant varies. According to Blair (1709) there are four pairs of sternal ribs, four pairs of asternal ribs with rib cartilages, and three pairs of asternal ribs without rib cartilages. The present study agrees with Sikes (1971) and Eales (1929) that there are six sternal and 14–15 asternal ribs in the African elephant. However, Eales states that the last four to

five asternal ribs do not carry rib cartilages and are therefore not attached to the sternum. In the present study, the last five to six asternal ribs did not carry rib cartilages.

ACKNOWLEDGEMENTS

The authors would like to thank the Kruger National Park for supplying the material for the study and Heleen Visser and Laura Hope for the photography of the drawings.

REFERENCES

- BLAIR, P. 1709. Osteographia Elephantina, or a full and exact description of all the bones of an elephant which died near Dundee, April 27th 1706, with their several dimensions. *Philosophical Transactions of the Royal Society*, 27:53–168.
- EALES, N.B. 1929. The anatomy of a foetal African elephant, *Elephas africanus (Loxodonta africana)*. III. The contents of the thorax and abdomen, and the skeleton. *Transactions of the Royal Society of Edinburgh*, 56:203–246.
- GÜSSGEN, B. 1988. *Vergleichende Zusammenstellung der Literaturbefunde über die Anatomie des Indischen und Afrikanischen Elefanten als Grundlage für tierärztliches Handeln*. Inaugural Dissertation, Tierärztliche Hochschule, Hannover.
- SIKES, S.K. 1971. The musculo-skeletal system, in *The world naturalist: The natural history of the African Elephant*, edited by R. Carrington. London: Weidenfeld & Nicolson: 52–75.
- WISSDORF, H., BACH, F., LEOPOLD-KEIGHLEY, B. & KRISTINSSON, G. 1987. Anatomische Grundlagen zur Epiduralanaesthetie beim Indischen Elefanten (*Elephas maximus*, Linn. 1758), in *Verhandlungsbericht des 29 Internationalen Symposiums über die Erkrankungen der Zootiere, Cardiff*, edited by R. Ippen & H-D. Schröder. Berlin: Akademie Verlag: 157–165.
- WISSDORF, H. & BACH, F. 1988. Anatomische Grundlagen zur Blutentnahme aus der V. caudalis centralis, dorsal am Schwanz des Indischen Elefanten. *Effem-Forschung für Heimtiernahrung*, Report 26:1–4. *Effem-Forschung für Heimtiernahrung*, Report 26:1–4.