



## Application of ultrasonography in prevalence studies of hydatid cysts in goats in north-western Turkana, Kenya and Toposaland, southern Sudan

E.M. NJOROGÉ<sup>1</sup>, P.M.F. MBITHI<sup>1</sup>, J.M. GATHUMA<sup>1</sup>, T.M. WACHIRA<sup>2</sup>,  
J.K. MAGAMBO<sup>3</sup> and E. ZEYHLE<sup>2</sup>

### ABSTRACT

NJOROGÉ, E.M., MBITHI, P.M.F., GATHUMA, J.M., WACHIRA, T.M., MAGAMBO, J.K. & ZEYHLE, E. 2000. Application of ultrasonography in prevalence studies of hydatid cysts in goats in north-western Turkana, Kenya and Toposaland, southern Sudan. *Onderstepoort Journal of Veterinary Research*, 67:251–255

A study was done to determine the prevalence of hydatid cysts in goats using ultrasonography. A total of 1 390 goats were examined, 43,6 % (606/1390) of them from north-western Turkana, Kenya, and 56,4 % (784/1390) from Toposaland, southern Sudan. Hydatid cysts were visualized in 1,82 % (11/606) of the goats from north-western Turkana and 4,34 % (34/784) of those from Toposaland. Unlike abattoir surveys, the prevalence data obtained in this study were unbiased because entire flocks were examined. The lower prevalence rate of the disease in goats from Turkana was attributed to the hydatid disease control programme in that area, which is absent in Toposaland.

**Keywords:** Goats, hydatid cysts, Kenya, north-western Turkana, prevalence, southern Sudan, Toposaland

### INTRODUCTION

Goats, in Kenya, are a major reservoir of the hydatid cysts of *Echinococcus granulosus* and therefore play an important indirect role in the transmission cycle of hydatidosis to humans (Macpherson, Spoerry, Zeyhle, Romig & Gorfe 1989). The prevalence of hydatid disease in goats has been difficult to establish due to poor reliability of serological tests (Lightowers & Gottstein 1995). The prevalence reports of hydatid cysts in goats based on slaughter surveys are inherently biased since debilitated and sick animals are more likely to be sent for slaughter. To eliminate this bias, a better diagnostic method that includes entire flocks of goats is necessary. Ultrasonography has been used in both diagnosis and mass screening of hydatid disease in human populations (Mac-

pherson, Zeyhle, Romig, Rees & Were 1987; Zeyhle, Magambo, Wachira, Gikandi & Njoroge 1999). It has also proved to be an important diagnostic tool for hydatid cysts in livestock in remote areas where other diagnostic tools are not readily available (Maxson, Wachira, Zeyhle, Fine, Mwangi & Smith 1996; Maxson, Wachira, Zeyhle, Weber, Njoroge & Smith 1998; Njoroge, Mbithi, Gathuma, Maxon, Wachira & Zeyhle 1999). The technique has been used to determine the prevalence of hydatid cysts in the right lung and liver of sheep and goats in one village in Turkana (Maxson *et al.* 1996). However, there has been no attempt to determine the prevalence of the disease in the goats from other areas of Turkana and elsewhere. The aim of this study was to determine the prevalence of hydatid cysts in goats of other villages of Turkana, Kenya and Toposaland, southern Sudan using ultrasonography.

### MATERIALS AND METHODS

The study was carried out in the villages of Lopiding, Aposta, Lokichoggio and Nanam of north-western

<sup>1</sup> University of Nairobi, P.O. Box 29053, Nairobi, Kenya

<sup>2</sup> African Medical and Research Foundation, P.O. Box 30125, Nairobi, Kenya

<sup>3</sup> Jomo Kenyatta University of Agriculture and Technology, P.O. Box 62000, Nairobi, Kenya

Accepted for publication 26 September 2000—Editor

Fig 1 : Map of West Turkana, Kenya and Toposaland, Southern Sudan showing the areas from which the Goats used in the study originated

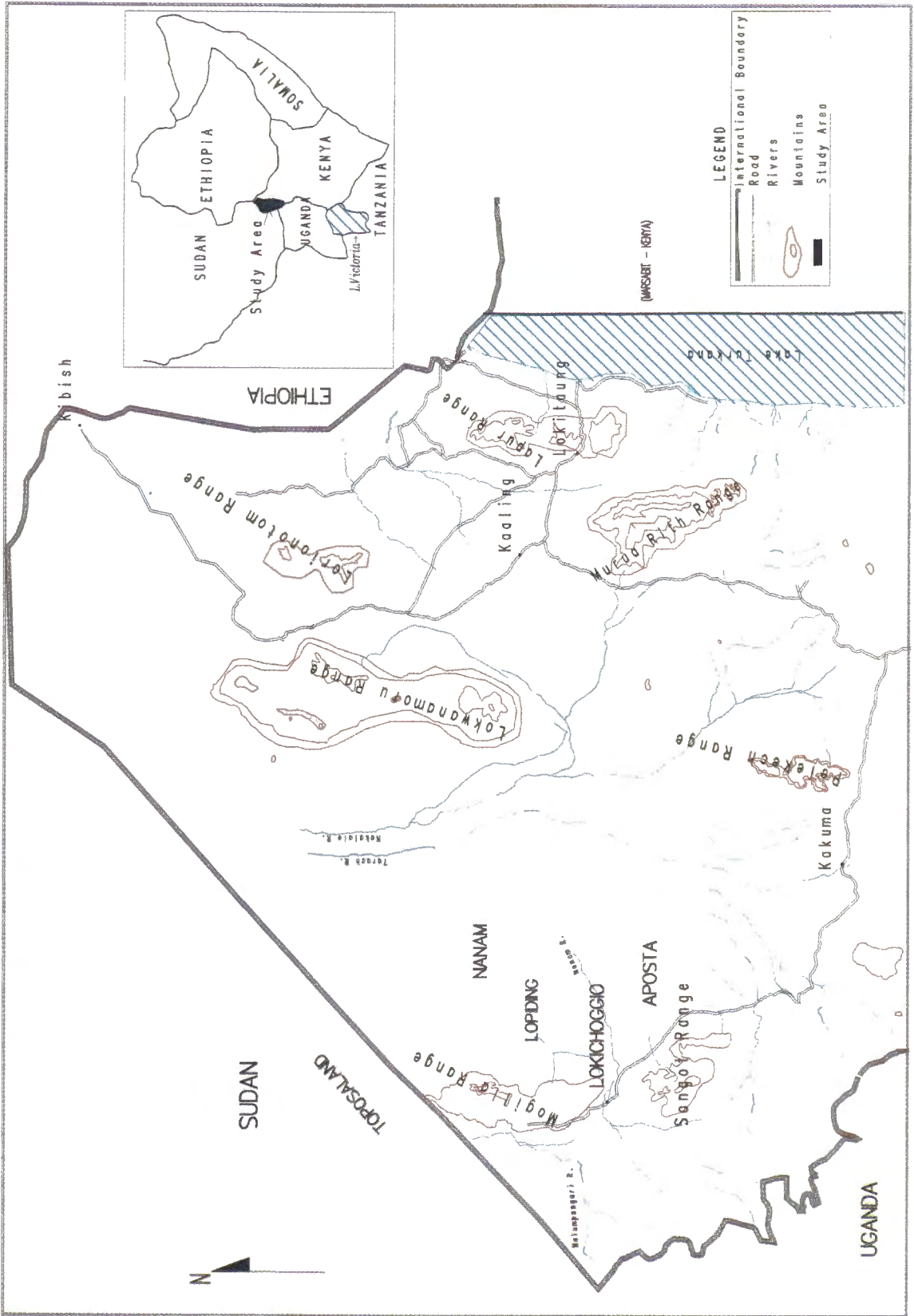


FIG. 1 A map of north-western Turkana, Kenya and Toposaland, southern Sudan showing the areas from which the goats used in the study originated

Turkana (Fig. 1) between the months of May and December 1998. Goats of Toposaland, southern Sudan were examined at the Kenya-Sudan border on their way to be traded at Lokichoggio market, Kenya. All the goats presented were examined. Ultrasound examinations were carried out in the mornings between 07:00–10:00 and early evenings between 17:00–19:00. The animals were allowed to graze between these two periods.

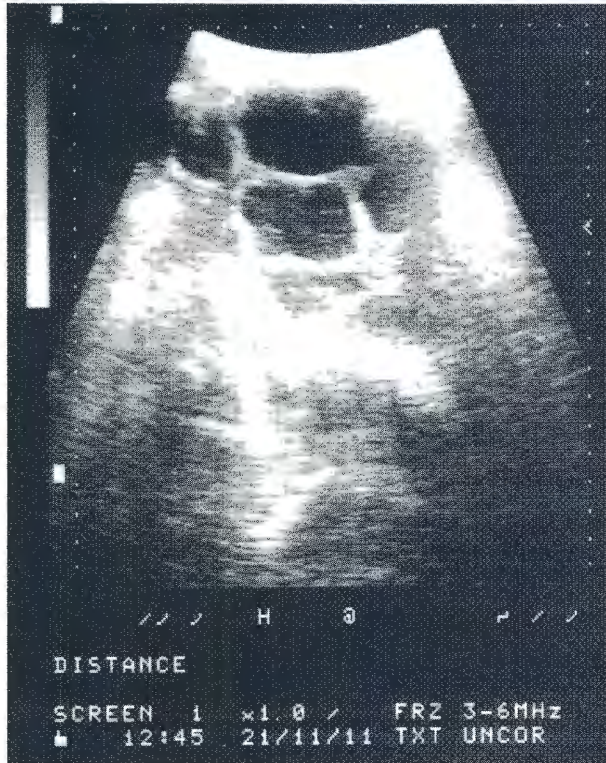


FIG. 2 Multiple unilocular hydatid cysts visualized in a goat from Turkana. The cysts appear as anechoic areas with well defined borders in the scan photograph

The hair was clipped from the right thorax and abdomen of each animal and acoustic coupling gel (Ultrasuoni Gel, Medicap-parma, Italy) applied to the clipped area. Each animal was manually restrained and examined ultrasonographically from the caudal to the cranial part of the clipped area, beginning caudal to the last rib and ending at the seventh intercostal space. Each intercostal space was also examined from dorsal to ventral with the transducer held parallel to the ribs.

Ultrasound examination of the liver and the lung was performed with a real-time B-mode scanner with electronically variable focus (Concept 2, Dynamic Imaging, West Lothian, UK). A 3,5 MHz linear array or a 3,5 MHz microconvex transducer was used depending on the width of the intercostal space. The scanner was powered by a 1,9 kW portable electricity generator (Honda Generator JB 2200, Honda Inc., New York, NY, USA). Static images were recorded on a graphic printer (Sony Graphic Printer, Model UP-850, Sony Corp., Japan). The diagnostic features used to detect hydatid cysts included multiple or single unilocular cysts with a distinct host-parasite wall (Fig. 2), the presence of daughter cysts, multiloculated cysts and separation of the laminated membrane from the cyst wall (Pant & Gupta 1987). The location of each cyst was noted.

## RESULTS

A total of 1 390 goats (746 males and 644 females) was examined, 43,6% (606/1390) being from north-west Turkana, Kenya, and 56,4% (784/1390) from Toposaland, southern Sudan. Of the animals from Turkana, 90,4% (548/606) were females and 9,6% (58/606) were males. Of the animals from Toposaland, 87,8% (688/784) were males and 12,2% (96/784) were females (Table 1).

TABLE 1 Number of goats scanned from villages of north-western Turkana and Toposaland indicating sex of the animal and the organ where hydatid cyst was visualized by use of ultrasound

| Village     | Number scanned |        |       | Hydatid positive |        |      |       |
|-------------|----------------|--------|-------|------------------|--------|------|-------|
|             | Male           | Female | Total | Male             | Female | Lung | Liver |
| Lopiding    | 8              | 264    | 272   | –                | 7      | –    | 7     |
| Aposta      | 3              | 181    | 184   | –                | 1      | –    | 1     |
| Nanam       | –              | 64     | 64    | –                | 1      | –    | 1     |
| Lokichoggio | 47             | 39     | 86    | –                | 2      | –    | 2     |
| Toposaland  | 688            | 96     | 784   | 29               | 5      | 2    | 32    |
| Total       | 746            | 644    | 1 390 | 29               | 16     | 2    | 43    |

In both Toposaland and north-western Turkana, a total of 45 (3,2 %) goats harboured hydatid cysts. Eleven of these goats were from north-western Turkana and 34 were from southern Sudan. Among all the goats harbouring hydatid cysts, 29 (2,1 %) were males and 16 (1,2 %) were females. Hydatid cysts were present in the liver of 43 (3,1 %) animals and in the lungs of two (0,14 %) animals. The cysts were anechoic, round and had well defined borders. Refractive shadows were present at the edges of the cysts.

Among the animals from southern Sudan, the prevalence of the condition was 4,2 % (29/688) in males and 5,2 % (5/96) in females. In the Turkana animals, the prevalence was 2,0 % in females while no cysts were detected in males. The prevalence of hydatid cysts in various villages of Northwest Turkana was: Lopiding 2,5 % (7/184), Aposta 0,6 % (1/184), Lokichoggio 2,6 % (2/86) and Nanam 1,5 % (1/64). The overall prevalence of the disease was 1,82 % in goats from Turkana and 4,34 % in those from southern Sudan.

## DISCUSSION

In previous studies in Turkana District, the prevalence of hydatid cysts in goats was estimated to be < 2 % when using slaughter data (Macpherson, French, Stevenson, Karstad & Arundel 1985), and 2,5 % by ultrasound examination (Maxson *et al.* 1996). Whereas these values are comparable with the prevalence in the present study (1,82 %), they may be biased because debilitated and sick animals are more likely to be sent for slaughter, and ultrasound examination was performed in only one village. In the present study, ultrasound examination was performed in four different villages that were randomly selected and on whole flocks of goats, and the prevalence figures obtained for the condition are therefore more likely to be unbiased.

The prevalence rate of hydatid cysts in goats from north-western Turkana was lower (1,82 %) than that in goats from Toposaland (4,34 %). The lower prevalence in Turkana may be attributed to the hydatid control programme that has been in place from 1983 in that area. For a period of 15 years, control efforts have been directed to community education and mass treatment of dogs (Macpherson & Wachira 1997). These may have contributed to lower infection rates in goats from Turkana villages. Such a control programme is absent in southern Sudan.

In this study, the occurrence of hydatid cysts was much higher in the liver than in the lungs. Previous reports indicate that hydatid cysts have a higher predilection for the lungs than in the liver (Al-Abbassy, Altaif, Jawad & Al-Saqur 1980). In the present study, the prevalence rate of hydatid cysts in the lungs may

be an underestimation because ultrasound is limited in its detection of lesions in the lungs. Air in the lungs reflects sound waves, which interferes with detection of hydatid cysts within the parenchyma. Only hydatid cysts adjacent to the thoracic wall can be visualized.

The prevalence rate of hydatid cysts in animals as determined by ultrasound may be lower than that determined by slaughter because only superficial lung cysts in one lung were visualized. Also, only part of the liver was seen due to superimposition on the part of the lung. However, ultrasound was the only diagnostic tool available in the present study. Additionally, the human population in the study area is entirely dependent on the animals for milk and blood and therefore mass slaughtering to determine the prevalence of hydatid cysts was not feasible. Ultrasonography proved to be a non-invasive and well-accepted technique for prevalence studies of hydatid cysts in goats.

## ACKNOWLEDGEMENTS

We thank DAAD of Germany for providing funds for this study and AMREF, Kenya for providing the ultrasound scanner.

## REFERENCES

- AL-ABBASSY, S.N., ALTAIF, K.I., JAWAD, A.K. & AL-SAQUR, I.M. 1980. The prevalence of hydatid cysts in slaughtered animals in Iraq. *Annals of Tropical Medicine and Parasitology*, 74:185–187.
- LIGHTOWLERS, M.W. & GOTTSTEIN, B. 1995. Immunological diagnosis of *Echinococcus* infection in animals, in *Echinococcus and hydatid disease*, edited by R.C.A. Thompson & A.J. Lymbery, CAB International: 385–391.
- MACPHERSON, C.N.L., FRENCH, C.M., STEVENSON, P., KARSTAD, L. & ARUNDEL, J.H. 1985. Hydatid disease in the Turkana district of Kenya, IV. The prevalence of *Echinococcus granulosus* infections in the dogs, and observations on the role of the dog in the lifestyle of the Turkana. *Annals of Tropical Medicine and Parasitology*, 79:51–61.
- MACPHERSON, C.N.L., ZEYHLE, E., ROMIG, E., REES, P.H. & WERE, J.B.O. 1987. Portable ultrasound scanner versus serology in screening for hydatid cysts in a nomadic population. *Lancet*: ii; 259–261.
- MACPHERSON, C.N.L., SPOERRY, A., ZEYHLE, E., ROMIG, T. & GORFE, M. 1989. Pastoralists and hydatid disease: an ultrasound scanning prevalence survey in East Africa. *Transactions of the Royal Society of Tropical Medicine and Hygiene*, 83:243–247.
- MACPHERSON, C.N.L. & WACHIRA, T.M. 1997. Cystic Echinococcosis in Africa South of the Sahara, in *Compendium on cystic Echinococcosis in Africa and in Middle Eastern Countries with special reference to Morocco*, edited by F.L. Andersen, H. Ouhelli & M. Kachani, Brigham Young University, Provo, UT 84602, USA: 245–277.
- MAXSON, A.D., WACHIRA, T.M., ZEYHLE, E.E., FINE A., MWANGI, T.W. & SMITH, G. 1996. The use of ultrasound to study the prevalence of hydatid cysts in the right lung and liver of sheep and goats in Turkana, Kenya. *International Journal for Parasitology*, 26:1335–1338.

- MAXSON, A.D., WACHIRA, T.M., ZEYHLE, E., WEBER, E., NJOROGÉ, E. & SMITH, G. 1998. Evaluation of diagnostic ultrasound as a mass screening technique for detection of hydatid cysts in the liver and right lung of sheep and goats. *International Journal for Parasitology*, 28:349–353.
- NJOROGÉ, E.M., MBITHI, P.M.F., GATHUMA, J.M., MAXSON, A.D., WACHIRA, T.M., & ZEYHLE, E.E. 1999. Ultrasound in livestock: A contribution to epidemiology of hydatidosis. *Proceedings of the 17th International Conference of the World Association for the Advancement of Veterinary Parasitology*, 15–19 August 1999, Copenhagen, Denmark.
- PANT, C.S. & GUPTA, R.K. 1987. Diagnostic value of ultrasonography in hydatid disease in the abdomen and chest. *Acta Radiologica*, 28:743–745.
- ZEYHLE, E., MAGAMBO, J.K., WACHIRA, J., GIKANDI, A. & NJOROGÉ, E.M. 1999. Hepatic hydatid cysts in a Turkana woman-case report. *African Journal of Health Sciences*, 6:31–32.