
Green Liver Cell Adenoma in a Bovine.

**By G. DE KOCK, M.R.C.V.S., Dr. Med. Vet., and P. J. J. FOURIE,
M.R.C.V.S., Research Officers, Onderstepoort.**

Green Liver Cell Adenoma in a Bovine.

By G. DE KOCK, M.R.C.V.S., Dr. Med. Vet., and P. J. J. FOURIE,
M.R.C.V.S., Research Officers, Onderstepoort.

THIS specimen (No. 6072), a piece of bovine liver about the size of a hand, showing the presence of a circumscribed tumour, was sent in from the abattoirs, Durban, where a great number of animals from Rhodesia and elsewhere are slaughtered for export purposes.

Macroscopically.—The tumour is present in the substance of the liver, but at one place it is associated with the capsule, and can actually be seen on the surface of the organ. The capsule of the liver, over the neoplasm, stands out as a pale greyish-white area, 4 cm. in diameter. Over the tumour the capsule is irregularly thickened and raised above the surface of the liver.

In the substance of the liver it is found to be circumscribed, and sharply marked off from the apparently normal liver tissue by a well-defined fibrous capsule, which varies in thickness from $\frac{1}{2}$ cm. to 2 cm. In the latter thick portion there are several small disseminated, circumscribed neoplasm foci which vary in size from 1 mm. to 4 mm. in diameter. These foci vary in colour from pale greyish-yellow to a pale green (see plate).

The substance of the neoplasm shows a lobulated appearance. The lobules vary in size from those 2 mm. in diameter to elongated ones 1 cm. long. In between the lobules are reddish spots (hæmorrhages) here and there. In places these assume a linear appearance, and occur irregularly throughout the substance of the neoplasm.

The colour is for the most part green, but lighter shades of greyish, and even yellowish green, can be identified. This is well shown in the plate. Red spots, and sometimes red lines (hæmorrhages), occur in an irregular manner throughout the substance of the tumour.

Microscopically.—Shows a *fibrous stroma*, which in some places is more developed than in others. In the stroma is embedded liver parenchyma which varies in size, shape, and distribution. There is no regular conformity to the usual liver structure, i.e. lobules in which one can recognise central veins as such, with Glisson's capsule in the periphery. The distribution and arrangement of the liver cells are most irregular, e.g. in places it is of the nature of acine, in other centres it has a linear arrangement in which no central veins nor Glisson's capsule can be definitely identified. Embedded in this parenchyma are blood spaces varying from small foci, i.e. about the diameter of a few normal liver lobuli, to large blood masses, fairly extensive in size, and recognizable by the naked eye. Their shape is very irregular and their margins are sharply defined, and give the impression that the spaces are lined by endothelium. Such a lining can actually be made out in places.

The liver cells are not typically polygonal as such, but appear to be flat epithelium and smaller than the usual liver cells. They have several nuclei. The nuclei are rounded, have the character of nuclei of liver cells, and are of uniform appearance. A good few nuclei show stages of mitosis. With Sudan III, a large number of cells show the presence of brick-red droplets, varying in size from minute ones to those which almost fill the whole liver cell. Here and there are stern-cells filled with a greenish-yellow granular pigment.

With reference to the pigment occurring in the tumour one recognizes the following peculiarities:—

With the haemalum-eosin stain, in the stroma in places, there are numerous cells of various sizes, and with a large amount of cytoplasm and a small round nucleus. The nucleus has a variable situation in the cell, viz., nucleus is either centrally placed or peripherally placed, or occupies any other intermediate position. The cytoplasm has a regular fine granular yellowish-pink appearance.

In one or two centres there is a collection of a number of these cells. When stained with the Berlin-blue method this pigment in places shows up as haemosidrin, but the majority of these cells are filled to bursting with a yellow-brown granular pigment. Some of these cells as regards their distribution are of the nature of stern-cells.

Pigment in the form of granules is seen in the blood spaces described above. These pigment granules are yellowish-brown in colour with a slight tinge of green, and seem to be associated with cells connected with the ingrowing fibrocytes.

It gives one the impression that these pigment cells associated with the stroma, are fed by broken up blood of the healing out blood spaces. In these spaces with Van Gieson's stain one can actually make out the ingrowing fibrocytes. These are more or less radially arranged towards the centre of the space. This pigment does not stain with Berlin-blue, and with Sudan III shows up as cells filled to bursting with brick-red droplets and yellowish-brown granules. Only here and there is there evidence of haemosidrin; the majority of the pigment is yellowish-brown.

These cells are very irregular in size and shape. Some are very large and spindle-shaped, others are spherical, whereas some are irregularly quadrilateral and others again triangular.

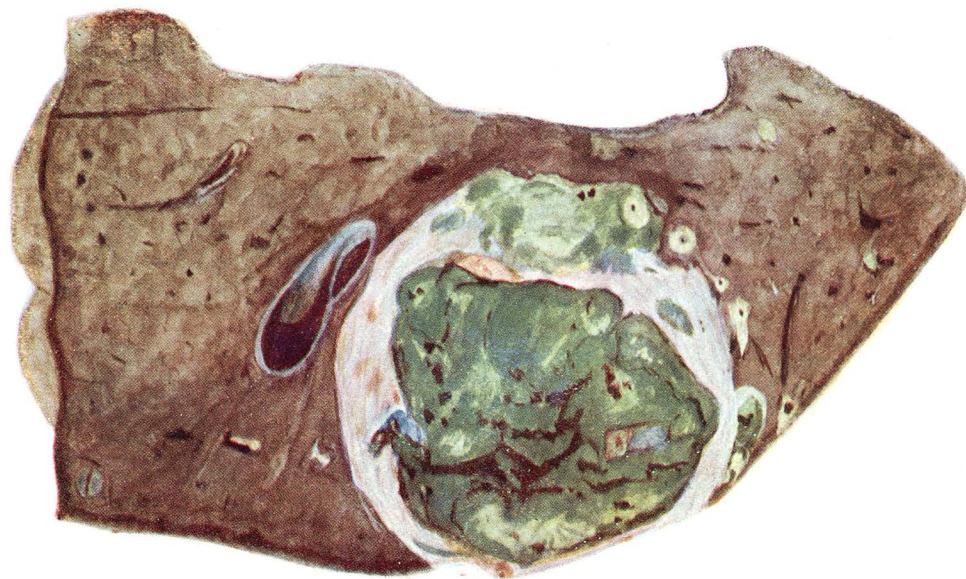
NOTE.—The stroma shows in places extensive round cell infiltration, amongst which there are numerous cells of the nature of eosinophiles, viz., as regards their granules and the polymorphous character of their nuclei. This cellular infiltration in a much widened and irregular stroma is not associated with any proliferation of bile duct epithelium.

DISCUSSION.

This is evidently a liver-cell adenoma, characterized by the formation of blood spaces. These blood spaces are being transformed by ingrowing connective tissue, and associated with it there is a good deal of pigment metabolism. This is mainly of the type of a yellowish-brown pigment. Haemosidrin is present only to a small extent. Undoubtedly this pigment gives the tumour its characteristic

colour. No light could be thrown on the exact nature of the pigment, which is formed by the histiocytes. It is associated with the breaking down of erythrocytes. Besides this pigment, a good deal of fatty substances in the form of droplets are present in the cytoplasm of these phagocytes. One interesting feature about this pigment metabolism is that it is formed in situations, which are free from liver cells, i.e. some distance removed from the liver parenchyma. Joest (on page 191, "Spezielle Path. Anat. des Haustiere," Band II) mentions the occurrence of adenoma hepatis flavum und viride. He maintains that the yellow and green pigment is associated with the functional activities of the adenoma cells, and in view of the fact that the excretion of this pigment is prevented as a result of a much altered system of bile vessels, etc., inhibition is brought about in the tumour tissues, and accounts for the peculiar pigmentation of the tumour. If this is the explanation of the occurrence of pigment in such tumours, why is it not that all liver cell adenomas are so pigmented in view of the obstruction usually met with in connection with their excretory apparatus?

As shown above, in this tumour described by us, no pigment of any description could be identified in connection with the liver cells. The pigment was only observed in connection with the stern-cells and histiocytes associated with actively growing connective tissue in the blood spaces.



Boezart

PLATE I.

Specimen No. 6072. Liver. Bovine. Natural size. Green Adenoma.

Green Adenoma.]

[*De Kock and Fourie.*